

This article is licensed under the Creative Commons Attribution-NonCommercial 4.0 International License (CC BY-NC) (<http://www.karger.com/Services/OpenAccessLicense>). Usage and distribution for commercial purposes requires written permission.

Case Series

Acute Gastric Dilatation: A Cause for Concern

Danial Haris Shaikh^{a, b} Abhilasha Jyala^b Shehriyar Mehershahi^{a, b}
Chandni Sinha^b Sridhar Chilimuri^{a, b}

^aDivision of Gastroenterology, BronxCare Health System, Icahn School of Medicine, Bronx, NY, USA; ^bDepartment of Medicine, BronxCare Health System, Icahn School of Medicine, Bronx, NY, USA

Keywords

Abdominal distention · Acute gastric dilatation · Gastric ischemia · Gastroparesis · Stomach perforation

Abstract

Acute gastric dilatation is the radiological finding of a massively enlarged stomach as seen on plain film X-ray or a computerized tomography scan of the abdomen. It is a rare entity with high mortality if not treated promptly and is often not reported due to a lack of physician awareness. It can occur due to both mechanical obstruction of the gastric outflow tract, or due to nonmechanical causes, such as eating disorders and gastroparesis. Acute hyperglycemia without diagnosed gastroparesis, such as in patients with diabetic ketoacidosis, may also predispose to acute gastric dilatation. Prompt placement of a nasogastric tube can help deter its serious complications of gastric emphysema, ischemia, and/or perforation. We present our experience of 2 patients who presented with severe hyperglycemia and were found to have acute gastric dilation on imaging. Only one of the patients was treated with nasogastric tube placement for decompression and eventually made a full recovery.

© 2021 The Author(s)
Published by S. Karger AG, Basel

Introduction

Acute gastric dilatation (AGD) was first reported by S.E. Duplay in 1833, and although a handful of reports have followed since, no precise definition of this entity is available in the literature. It is generally described as the radiological finding of a massively enlarged stomach, with gas or fluid, as seen on plain film abdominal X-ray (AXR) or computerized tomography (CT) scan of the abdomen. It is a rare condition and is often overlooked by physicians due to a lack of awareness.

AGD can result from either mechanical obstruction or nonmechanical distention of the stomach. Causes of mechanical obstruction include postsurgical strictures/adhesions, pyloric stenosis, gastric volvulus, and superior mesenteric artery syndrome. Nonmechanical etiologies include eating disorders (anorexia/bulimia nervosa, psychogenic polyphagia), Prader-Willi syndrome, medications, electrolyte abnormalities, resuscitation, and gastroparesis [1].

The stomach is considered a thick-walled organ, relative to the rest of the gastrointestinal tract, boasting a rich vascular supply. However, with AGD, the stomach's vascular supply may become compromised, and this can prove fatal if sequelae, such as gastric emphysema, ischemia, and perforation, occur [2]. The focus of treatment is on techniques to decompress the stomach.

Although gastroparesis is known to cause AGD [3, 4], rarely acute hyperglycemia by itself may also predispose to it. This is particularly seen in patients presenting with diabetic ketoacidosis (DKA) or in a hyperosmolar hyperglycemic state, with marked elevations in blood sugar levels. We present our experience of 2 such patients, who presented with severe hyperglycemia and were found to have AGD on imaging. Due to a lack of awareness, only one of the patients was treated promptly with a nasogastric tube (NGT) placement for decompression.

Case Series

Case 1

A 30-year-old male presented to our institute with complaints of nausea, vomiting, decreased oral intake, and diffuse abdominal pain for the past 3 days. He was noted to be lethargic, hypotensive (76/49 mm Hg), and hypoxic (SaO₂ 88%) on presentation and was emergently intubated for airway protection. His comorbidities included type 1 diabetes and end-stage renal disease. He denied any prior symptoms of delayed gastric emptying, such as nausea, postprandial fullness, or early satiety. His surgical history was significant for a right foot trans-metatarsal amputation. He denied the use of tobacco, alcohol, or illicit drugs and had no known drug allergies. On examination, his abdomen was notably distended and bowel sounds were sluggish. No guarding or rigidity was appreciated. Initial lab data revealed a blood glucose of 1,155 mg/dL and a pH of 6.97 with an elevated anion gap. He was started on intravenous (IV) insulin for the treatment of DKA and IV epinephrine for hemodynamic shock. An AXR revealed acute gaseous distention of the stomach (Fig. 1). An NGT was passed which drained over 500 mL of gastric content. A repeat AXR 4 hours later revealed resolution of gastric dilatation, which was confirmed by a CT scan of the abdomen. Upper endoscopy was contemplated but deferred due to the resolution of dilatation. He was monitored in the intensive care unit, and over the next few days his DKA resolved, he was extubated and eventually discharged home.

Case 2

A 59-year-old male was brought to our institute by emergency services for altered mental status and a “very high” blood sugar reading. The patient was unable to provide a history, however, accompanying family members reported periods of confusion and falls for the past 1 day. On presentation, he was hypothermic (94.5°F) but otherwise hemodynamically stable. On examination, his abdomen was distended with decreased bowel sounds and he was noted to have a left lower extremity infected diabetic foot ulcer. Cardiopulmonary exam was within normal limits. His comorbidities included diabetes mellitus and chronic hepatitis C. Past surgical history was notable for a right foot debridement for osteomyelitis. He was a former polysubstance user and had no known drug allergies. Initial labs were significant for hyperglycemia (649 mg/dL), a blood pH of 7.29, a normal anion gap, and leukocytosis (16.2 K/ μ L). He was started on IV insulin for the treatment of hyperosmolar hyperglycemic state and IV antibiotics for his foot ulcer, cultures of which grew *Staphylococcus aureus*. He underwent an AXR which showed marked distention of the stomach (Fig. 2). A follow-up CT of the abdomen confirmed the finding, with no mechanical cause of obstruction identified. He was planned for an upper endoscopy, however, his condition deteriorated. Hospital course was complicated by the development of pneumonia and respiratory failure requiring intubation. He was subsequently started on vasopressors for hemodynamic instability. The patient eventually suffered a cardiac arrest as a likely consequence of septic shock and was unable to be revived. An NGT for decompression was never placed and an autopsy was not performed.

Discussion

Diabetic gastroparesis is a well-known, nonmechanical cause of AGD, as reported in the literature [3–7]. Long-standing diabetes causes autonomic neuropathy and dysfunction of the pacemaker cells of Cajal, which results in delayed gastric emptying, a precursor to AGD [8]. However, hyperglycemia by itself may also delay gastric emptying. The acute elevations in blood glucose suppress the frequency and contraction amplitudes of antral pressure waves while stimulating phasic pyloric pressure waves, resulting in uncoordinated emptying and subsequent gastric distention [9]. We believe the etiology of AGD in both our patients was related to their hyperglycemic state.

Eating disorders are another important cause of nonmechanical AGD. In patients with bulimia nervosa, the stomach remains atonic during prolonged periods of malnutrition, resulting in muscular atrophy. Then, sudden food intake may result in an overfilling of an already weakened stomach which is unable to empty or assist with vomiting, causing AGD. Some authors have also described a mechanism similar to superior mesenteric artery syndrome in patients with eating disorders, where gastric dilation from overeating extrinsically compresses the third part of the duodenum, resulting in obstruction [10].

Mechanical etiologies of AGD include complications of surgery, pyloric stenosis, and gastric volvulus. In fact, any aberrancy that results in complete gastric outlet obstruction may trigger development of AGD. In cases of volvulus, an AXR demonstrates the stomach as a large spherical gas bubble with a disruption in its normal contour. The patient attempts to retch but is unable to do so, and characteristically there is an inability to pass an NGT [11]. Gastric air trapping following anti-reflux surgery and during cardiopulmonary resuscitation is also known to cause AGD [12]. Similarly, esophageal intubations and tracheoesophageal fistulas result in increased air delivery to the stomach, possibly triggering AGD [13].

Clinical features of AGD include nausea, vomiting, succussion splash, poorly localized abdominal pain, and progressive abdominal distention [14]. Vomiting, characteristically, does not provide a feeling of relief. If complications of AGD develop, patients may become extremely sick with ensuing hemodynamic shock and a high likelihood of death [2].

Complications such as ischemia and perforation develop when recognition and treatment of AGD are delayed. Despite the stomach's rich collateral blood supply, when intra-gastric pressure exceeds the gastric venous pressure (usually greater than 20–30 cm H₂O), intramural blood flow is impaired, resulting in ischemia and necrosis of the stomach wall [15]. In experimental canine models, both venous and arterial occlusion were necessary to produce gastric infarction [16]. Gastric emphysema is a sign of ischemia and necrosis, seen radiographically as submucosal lucent streaks. It occurs when gas within the gastric lumen is forced into the gastric wall through a mucosal breach. Although it may be caused by traumatic or obstructive causes, it can also occur in association with gastric distention [17]. In 1885, Revilloid demonstrated that the stomach had to be distended with at least 4 L of fluid before perforation occurred [18]. The location of perforation is most often along the greater curvature, whereas the lesser curvature and pylorus are usually protected from ischemia [2]. Compartment syndrome is another complication of AGD, where the sudden increase in pressure within a closed anatomic space threatens the viability of surrounding tissue and organs [12].

The evaluation of AGD mainly includes imaging, either plain abdominal radiographs or CT of the abdomen. Imaging can reveal an acutely dilated stomach and help identify mechanical obstruction [19]. Acute massive gastric dilatation is thought to be an extreme radiographic variant of AGD, occupying both the width and the length of the abdomen on imaging [2]. An upper endoscopy has value in discerning the etiology of obstruction and assessing the mucosa for ischemic changes. In addition, it provides the benefit of suctioning trapped air. However, perforation must be excluded via appropriate imaging studies before pursuing endoscopy [20].

Early recognition of AGD and immediate decompression via NGT is the mainstay of treatment. A thorough evaluation and management of the underlying etiology should also take place concurrently. Even after decompression, delayed perforation or bleeding is possible. Parenteral proton pump inhibitors may be given adjunctly, to decrease gastric secretions [20]. Surgical exploration is mandatory in patients with signs of obstruction and/or ischemia. The surgical strategy depends on the extent of gastric wall ischemia, the presence of necrosis, and/or perforation [19].

Statement of Ethics

The patients provided written informed consent for publication of the case reports and any accompanying images.

Conflict of Interest Statement

The authors declare that there are no conflicts of interest.

Funding Sources

None to declare.

Author Contributions

D. Shaikh and A. Jyala searched the literature, wrote and revised the manuscript. S. Meher Shahi and C. Sinha edited and revised the manuscript. S. Chilimuri revised and approved the final version and is the article guarantor.

References

- 1 Van Eetvelde E, Verfaillie L, Van De Winkel N, Hubloue I. Acute gastric dilatation causing acute limb ischemia in an anorexia nervosa patient. *J Emerg Med*. 2014 May;46(5):e141–3.
- 2 Moslim MA, Mittal J, Falk GA, Ustin JS, Morris-Stiff G. Acute massive gastric dilatation causing ischaemic necrosis and perforation of the stomach. *BMJ Case Rep*. 2017 Jun;2017:bcr2016218513.
- 3 Bach AG, Surov A. Massive gastric dilatation in a patient with type 2 diabetes. *CMAJ*. 2013 Oct;185(15):E740.
- 4 Amitai M, Yonash M, Amital H. [Acute gastric dilation in a diabetic patient]. *Harefuah*. 1996 Feb;130(4):292–3.
- 5 Ohkuni A, Nakamura T, Sugamata S, Koh S, Torii M, Miyake K, et al. [An autopsy case of gastric carcinoma, followed by acute gastric dilatation after a biopsy, with past history of gastroparesis diabetorum (author's transl)]. *Nihon Shokakibyō Gakkai Zasshi*. 1982 Apr;79(4):988–92.
- 6 Howland WJ, Drinkard RU. Acute diabetic gastric atony: gastroparesis diabetorum. *JAMA*. 1963 Jul;185(3):214–6.
- 7 Ball WR, Sharples AJ. Massive gastric dilation complicating diabetic gastroparesis. *BMJ Case Rep*. 2013 Apr;2013:bcr2013009420.
- 8 Camilleri M, Parkman HP, Shafi MA, Abell TL, Gerson L; American College of Gastroenterology. Clinical guideline: management of gastroparesis. *Am J Gastroenterol*. 2013 Jan;108(1):18–37; quiz 38.
- 9 Schvarcz E, Palmér M, Aman J, Horowitz M, Stridsberg M, Berne C. Physiological hyperglycemia slows gastric emptying in normal subjects and patients with insulin-dependent diabetes mellitus. *Gastroenterology*. 1997 Jul;113(1):60–6.
- 10 Franco-López Á, Badillo S, Contreras J. [Acute gastric dilatation in a bulimic patient; systemic effects]. *Nutr Hosp*. 2012 Jul-Aug;27(4):1364–7.
- 11 Chau B, Dufel S. Gastric volvulus. *Emerg Med J*. 2007 Jun;24(6):446–7.
- 12 Peces R, Vega C, Peces C, Trébol J, González JA. Massive gastric dilatation and anuria resolved with nasogastric tube decompression. *Int Urol Nephrol*. 2010 Sep;42(3):831–4.
- 13 Tessler S, Kupfer Y, Lerman A, Arsura EL. Massive gastric distention in the intubated patient. A marker for a defective airway. *Arch Intern Med*. 1990 Feb;150(2):318–20.
- 14 Leigh TF. Acute gastric dilatation. *JAMA*. 1960 Mar;172(13):1376–81.
- 15 Dewangan M, Khare MK, Mishra S, Marhual JC. Binge Eating Leading to Acute Gastric Dilatation, Ischemic Necrosis and Rupture – A Case Report. *J Clin Diagn Res*. 2016 Mar;10(3):PD06–07.
- 16 Turan M, Şen M, Canbay E, Karadayi K, Yildiz E. Gastric necrosis and perforation caused by acute gastric dilatation: report of a case. *Surg Today*. 2003;33(4):302–4.
- 17 Low VH, Thompson RI. Gastric emphysema due to necrosis from massive gastric distention. *Clin Imaging*. 1995 Jan-Mar;19(1):34–6.
- 18 Kerstein MD, Goldberg B, Panter B, Tilson MD, Spiro H. Gastric infarction. *Gastroenterology*. 1974 Dec;67(6):1238–9.
- 19 Steen S, Lamont J, Petrey L. Acute gastric dilation and ischemia secondary to small bowel obstruction. *Proc Bayl Univ Med Cent*. 2008 Jan;21(1):15–7.
- 20 Maung H, Buxey KN, Studd C, Ket S. Acute gastric dilatation in a bulimic patient. *Gastrointest Endosc*. 2017 Feb;85(2):455–7.

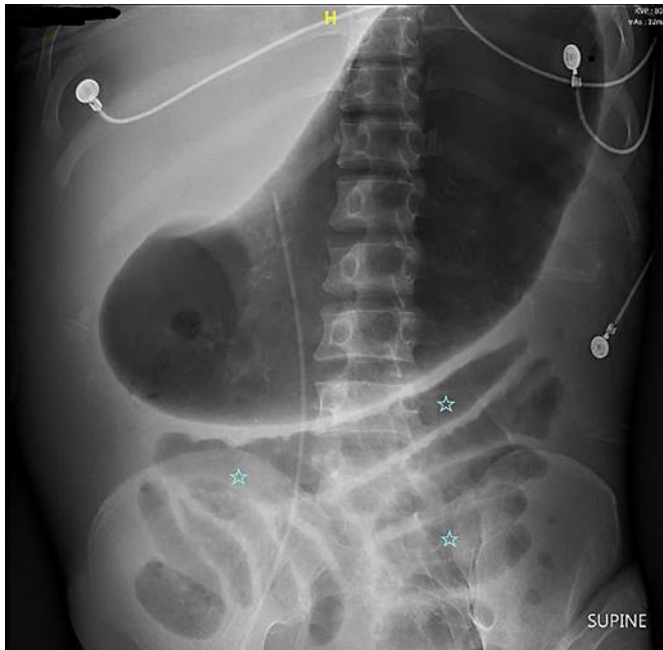


Fig. 1. Supine abdominal X-ray demonstrating gaseous distention of the stomach. Air is also noted within the small intestine (asterisks).

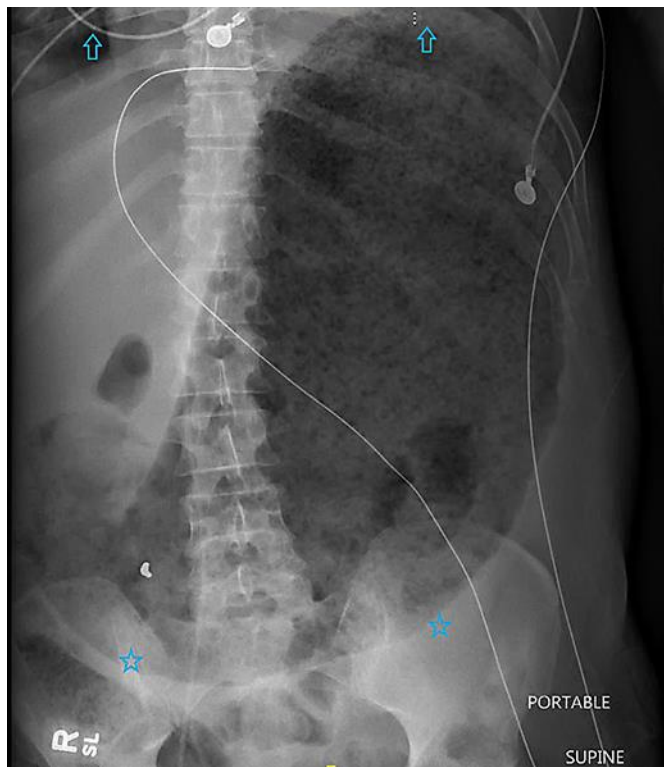


Fig. 2. Supine abdominal X-ray demonstrating a massively distended stomach, occupying the length of the abdomen, from the diaphragm (arrows) to the pelvis (asterisks).