

A Safe and Effective Lip Augmentation Method: The Step-by-Step Φ (Phi) Technique

Evangelos Keramidis, MD,
FEBOPRAS
Stavroula Rodopoulou, MD,
FEBOPRAS
Maria-Ioanna Gavala, MD

Background: The shape and fullness of the lips are essential in facial aesthetics. We describe a safe injection technique of hyaluronic acid (HA), based on the well-known golden number Φ (phi), for lip augmentation.

Methods: The name given to that procedure is “the step-by-step Φ technique.” Firstly, “step-by-step” because we never inject more than 1–1.5 ml of HA in 1 session, and “phi” because we apply the golden ratio 1.618—broadly known as Φ —to identify the proper points for injection. Using a specific caliper, we identified 3–4 points in each upper half of the lip. We injected 0.01–0.05 ml of lower concentration (25 mg/g) HA in these particular areas of the upper lip, from the vermilion border into the vermilion. We took into consideration the existing lip volume to decide the proper amount of HA to be injected in every single site, as lips are often asymmetric. On the lower lip, we use the same caliper to identify again the proper injection points. If necessary, the next 2 sessions are performed at an interval of 15–30 days.

Results: Our technique was performed in 833 patients. Mean age was 30.2 years (range: 18–72 years), and most patients were very satisfied. With this technique, we avoid severe complications such as arterial embolism or venous occlusion and unnatural results. The most common side effects were swelling, redness, and mild pain.

Conclusion: The step-by-step Φ technique is safe, easy to learn and perform, and can provide natural results in lip augmentation. (*Plast Reconstr Surg Glob Open* 2021;9:e3332; doi: 10.1097/GOX.0000000000003332; Published online 2 February 2021.)

INTRODUCTION

Lips are located at the center of the lower face and, together with the eyes and nose, comprise “the triangle of beauty.”^{1,2} According to the American Society of Plastic Surgeons, there is tremendous and ongoing growth in lip augmentation procedures. Specifically, lip injections between botulinum toxin A injections and a variety of soft tissue fillers were part of nearly 2.6 million injection procedures in 2018, with a total increase of 312% between 2000 and 2017.^{3–5} Lip injections can be quick, lunchtime procedures, but the results from less-qualified providers

can often be obvious and unappealing.⁶ The vast majority of severe complications are imputable to unauthorized non-medical injectors,^{7–11} and thus, there is an emerging need in this skyrocketing filler industry for well-trained board-certified plastic surgeons. This article explains and provides an easy way to master a safe and effective lip augmentation technique, the step-by-step Φ (phi) technique, based on and inspired by the Greek golden ratio of beauty.

MATERIALS AND METHODS

In total, 833 patients underwent lip augmentation from June 2013 to March 2019, in our private clinic located in Athens, Greece. Patients enrolled for this study were aged from 18 to 72 years, were in general good health, and were having lip augmentation for the first time. Pre-procedure and post-procedure frontal, profile, and oblique view photographs and videos of the patients were obtained. Following fundamental references to lip anatomy, the golden ratio, and lip aesthetics, we describe the step-by-step Φ technique.

From the Kosmesis Aesthetic Plastic Surgery Center, Athens, Greece. Received for publication September 29, 2020; accepted October 28, 2020.

Presented at 13th Hespras, October 16–19, 2019, Athens, Greece; at Hands-on-Course on hyaluronic acid injections using the “Step by Step Φ Technique,” Bucharest, 2019; at ISAPS Athens, November 24, 2018; and at IMCAS Bangkok, July 13–15, 2018.

Copyright © 2021 The Authors. Published by Wolters Kluwer Health, Inc. on behalf of The American Society of Plastic Surgeons. This is an open-access article distributed under the terms of the Creative Commons Attribution-Non Commercial-No Derivatives License 4.0 (CCBY-NC-ND), where it is permissible to download and share the work provided it is properly cited. The work cannot be changed in any way or used commercially without permission from the journal.

DOI: 10.1097/GOX.0000000000003332

Disclosure: All authors have no financial interest to declare in relation to the content of this article.

Related Digital Media are available in the full-text version of the article on www.PRSGlobalOpen.com.

Key Points in Vascular Lip Anatomy

The inferior (lower lip) and superior labial (upper lip) arteries arise from the facial artery approximately 1.5 mm superolateral to the oral commissure.¹² Anatomic variations are commonly the rule and vary among 3 positions: the superior labial artery is located 78.1% between the orbicularis oris and the oral mucosa, 17.6% intramuscularly, and 2.6% between the skin and the muscle, whereas the inferior labial artery is located 78.1% between the orbicularis oris and the oral mucosa, 17.3% intramuscularly, and 1.7% between the skin and the muscle.¹³ These arteries form a circular vascular network around the mouth and are ordinarily located posterior to the wet-dry border; thus, treating this area should be avoided.¹⁴ Moreover, the superior labial artery is more frequently superficial in the midline; thus, extra caution is needed when treating cupid’s bow area. Both in the upper and lower lip, median areas are important danger zones, whereas paramedian areas are considered safer locations when injecting the filler superficially.¹³ A general rule to ensure safety at most times, as stated in many anatomical studies, is puncturing the lips from the vermilion border and to never inject filler deeper than 2.5 mm at any point.^{12,14–16}

The Metric System

Our technique was developed by using a specific caliper (as shown in Fig. 1) and the golden ratio as a guide. The golden ratio or phi number is symbolized by the Greek letter Φ, as a contribution to Phidias (Φειδίας), the sculptor and architect of the Parthenon, and many other classical era Greek masterpieces. The Phi number, first described as the golden ratio by the Greek mathematician Euclid in the 10th of his 13 books of Elements, is an irrational number of the order 1.618033988 and is obtained when a line a + b is sectioned such that (a + b)/a = 1.618. Over centuries, evidence of its presence in a wide variety of mathematical, biological, and natural systems has been recorded, derived from the idea that it represents the perfect beauty.¹⁷ It has also appeared throughout history in many artistic masterpieces and architectural creations such as Da Vinci’s paintings and the Parthenon, and it is, in brief, an attempt to mathematically and geometrically interpret the captivating mystery of beauty.^{18,19} Undeterred

by its subjective nature,²⁰ we applied this number in our way: to identify the proper points for injection.

Lip Aesthetics

The basic principles of ideal lips include the following: a pronounced cupid’s bow, a well-defined vermilion border, upturned corners of the mouth, fullness in the center that fades out toward the mouth, symmetry between the left and the right sides, philtrum length of 12–15 mm, a thinner upper lip protrusion compared with the larger lower lip, and a balanced upper and lower lip. Specifically, on the frontal view, the ratio of ideal upper lip to lower lip is determined by the golden ratio, which is 1:1.6.^{1,21,22} However, it cannot be ignored that lip aesthetics change throughout history, eras, and races; however, voluptuous lips with an accentuated volume are delightful and very popular as well.^{2,23} Specifically, the current contemporary preferred female-lip ratio has recently been found to be 1:1 in White women.²³ To clarify what is considered the best lip ratio among patients, we conducted a survey in 2008 to evaluate their preferences compared with experts’ opinions and use it as a guiding tool during the patient-doctor consultation process. Figure 2 shows a photo-shopped image of different lips ratios, and each patient (Greek, white women) could choose her preferred lip ratio. Among 700 participants, 70% chose the 0.85:1 ratio, 20% the 1:1, and 6% the 0.65:1. In 2019 we started the same survey again, which is still ongoing, aiming to examine the stability of these results throughout time.

The Step-by-Step Φ Technique

Definition

The step-by-step Φ technique consists of 2 essential parts. The first one is the “step-by-step” because we inject gradually and only 1–1.5 ml of hyaluronic acid (HA) in each session. The next session is 15–30 days after, and the third, if needed, is 15–30 days after the second session. The second part of our technique is the “Φ” because we apply the number Phi ratio to identify the proper injection points.

Patient Preparation

- Obtain signed informed consent;
- Discuss the desirable lip ratio using practical examples (Fig. 2);
- Obtain photographs/videos;
- Position patient in a comfortable supine or semi-sitting position;
- Administer anesthetic lidocaine/tetracaine cream mixture;
- Disinfect using chlorhexidine solution.

Marking the Lips

A specific phi caliper (9 cm × 2 cm, manufactured by Golden Mean Calipers) that can expand to fit an individual’s lips is required. The injection points are marked with the following order: the caliper is placed at the outer corner of the upper right side of the lip, with the total length of the caliper extending from the outer corner to the right philtrum ridge, and then 3 injection points are marked. If

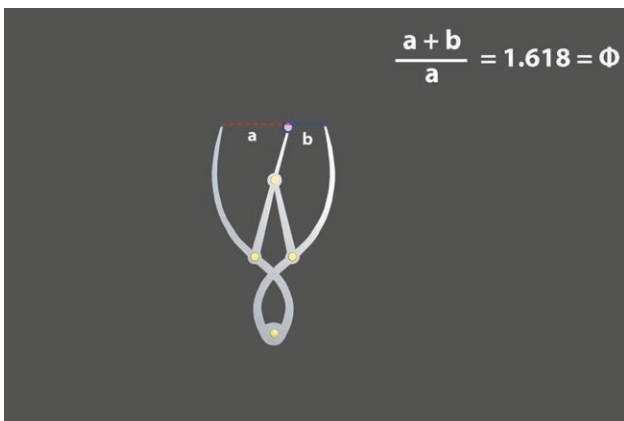


Fig. 1. The Φ caliper.




Fig. 2. Photoshopped images of different lip ratios for patient consultation.

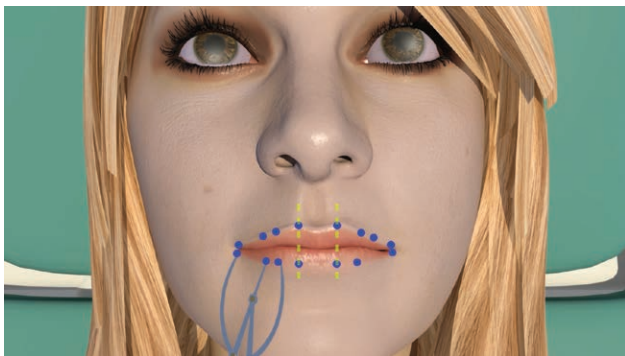


Fig. 3. Marking the injection points.

more volume is needed and depending on the patient's lip length, the caliper is placed at the right side of the upper lip, with its length extending from the outer corner of the lip up to the previously marked middle injection point. Then, a fourth injection point is marked between the 2 initial marked points. The same marking is repeated for the upper left side of the lip. For the lower lip, a line is drawn from the philtrum columns to the lower lip, an area that could be injected at the end to achieve a better projection, and we repeat the same 4 steps, leaving the lips with a total of 12 or 16 needle entry points: 6 or 8 on the upper and 6 or 8 on the lower lip, as shown in [Figure 3](#). Typically, 12 points of injection (6 in the upper and 6 in the lower lip) are needed.

The Injection Technique

- Between various dermal fillers, HA is the most commonly used because it is considered safe and effective.^{24,25} In our patients, we used HA with the following characteristics: cross-linking 3/6, concentration 25 mg/g.

- When aiming to restore the volume, the injection is performed into the vermillion through the vermillion border. Insert a 30-gauge needle at each marked point of the vermillion border at an oblique angle (30 degrees) no more than 2.5-mm deep to avoid lip vessels. To maintain the right needle depth measure, bend the needle at 2.5mm. Proceed slowly. At each needle's point, small boluses of 0.05–0.1 ml of HA are slowly injected with a total amount of 1–1.5 ml in both lips per session. Injection of HA is performed in a retrograde linear threading fashion.
- When aiming to restore the shape, the injection is performed into the vermillion border. At this point, it is important to avoid injections into the white roll because the hydrophilic HA leads to a blunted lip margin possibly due to the different histological characteristics of this area. Insert a 30-gauge needle at each marked point of the vermillion border at a parallel angle. This delicate part of the lip is more prone to unnatural results; thus, we strongly recommend using a modest amount of 0.02–0.4 ml of HA. Injection of HA is performed slowly in a retrograde linear threading fashion.
- Assess the lips for any asymmetry depending on the individual's anatomy and, if needed, inject 0.05 to 0.1 ml in the intended area.

A helpful tool in the injection technique is categorizing the lips according to their needs and tissue properties. Although many validated classifications exist,^{26–28} we proposed a simple categorization method to organize and simplify the lip shaping process:

1. Normal-volume lips

Delightful volume (vermillion) and definition (vermillion border) exist but patients are requesting a more projected view. Injection is performed into the vermillion to enhance volume and correct any asymmetries. Reassessment is

scheduled after 15 days and if needed more volume is added. Do not inject more than 1–1.5 ml of HA in each session.

2. Thin lips

Patients present with hereditary acquired atrophic lips, opting for a luscious pout. Volume is usually insufficient in the upper lip and less frequently in both lips or in the lower lip. The goal is to achieve the desired result while respecting soft tissue's expansion properties. To accomplish that, address the ratio by injecting into the vermillion of the thinner lip 0.5–1 ml of HA in the first session. As soon as the desired ratio is acquired, inject 0.5–1 ml of HA in both lips usually in the second or third session. Sessions interval is 30 days so that the tissues adjust to the placed HA and continue until the desired volume is achieved. If any asymmetries are present, we correct them by injecting more HA on the proper side of the lip. The next goal is defining and shaping the lips with the same step-by-step philosophy, by injecting into the vermillion border a moderate amount (0.02–0.4 ml) of HA. Reassess after 15 days and, if needed, add more HA to establish a better definition.

3. Aged thin lips

Vermillion border disappearance, soft tissue volume loss, lengthening of the upper lip, and vertical lines are only some aging signs. These patients desire a more youthful appearance. Similarly to thin lips shaping procedure, we prefer to first correct the volume by injecting HA into the vermillion and then correct the shape by injecting HA into the vermillion border. Again, the use of 0.5–1 ml in each session, every 30 days is essential because lips have limited expansion properties. In contrast to thin lips, aged lips should be injected with less HA (up to 0.5 ml) in each session; thus, more sessions are needed to achieve the desired natural results. Moreover, even from the first session, HA can be injected into the vertical lines of the upper lip.

- Assess at all times for any signs of intravascular injections: immediate blanching, extreme pain. If present, treat with hyaluronidase, massage, warm compresses, and aspirin administration until the capillary refill is back to normal.^{24,29,30}

Aftercare

- Lightly massage the treated area.
- Cleanse the skin with saline 0.9%.
- Apply ice packs for a few minutes to reduce pain and the risk of edema and bruising.
- Patients were advised to avoid excessive exercise, hot temperatures, and/or hot beverages for the next 24 hours.
- The next session is 15 days after, and the third, if needed, 30 days after the first one.

(See Video 1 [online], which demonstrates the technique in 3D animation.)

RESULTS

An estimated 833 patients underwent the “step-by-step Φ technique” lip augmentation from June 2013 to March

2019. Patients' medical records were reviewed retrospectively. The mean age was 30.2 years, with a range of 18–72 years.

Approximately 3 ml of HA (range: 1–12) was injected into each patient. The majority of patients required 3 sessions to achieve the optimum result spaced in 1-month interval. The time until the desired result was achieved ranged between 1 and 16 months. The results were evaluated immediately after the procedure, 15 days later to assess the results, correct any asymmetries, and schedule the next session, if needed. From a total of 833 patients, the 623 continuously revisited our office every year or two to repeat the treatment in different degrees to maintain their results. All 833 patients revisited our office at least one more time and were asked to fill out a written questionnaire. We evaluated their results using a GAIS 5-point scale evaluation system. In total, 92.4% of patients marked the results as exceptional, 7.56% as very improved or improved, 0% as no result, and 0% as worse. Figures 4–7 show representative participants.

In terms of the adverse effects, minimal pain, mild swelling, and a fair degree of redness were observed. Severe bruising was observed in 8 patients, mild bruising in 15 patients, and all developed bruising in the upper lip. Severe swelling occurred in 10 patients and mild swelling in 50 patients. However, no severe complications such as infection, vascular occlusion, necrosis, discoloration, or granuloma formation occurred.

Regarding the duration of the results, as per our experience, after using 3 syringes of 1 ml, the desired results can be long-lasting, and the mean time for a patient to revisit our office to maintain the initial result was 12–18 months.

Case 1

Lip category: normal lips

Number of sessions: 2

Total amount of HA: 2 ml

Time period to achieve the desired result: 2 months

Figure 4 shows a participant representing normal-volume lips.

Case 2

Lip category: thin lips

Number of sessions: 9

Total amount of HA: 9 ml

Time period to achieve the desired result: 12 months

Figures 5 and 6 show a thin lips category patient's augmentation process. (See Video 2 [online], which displays the patient talking and smiling, demonstrating natural lip movement.)

Case 3

Lip category: aged lips

Number of sessions: 2

Total amount of HA: 2 ml

Time period to achieve the desired result: 2 months

Figure 8 shows an aged-lips category participant.

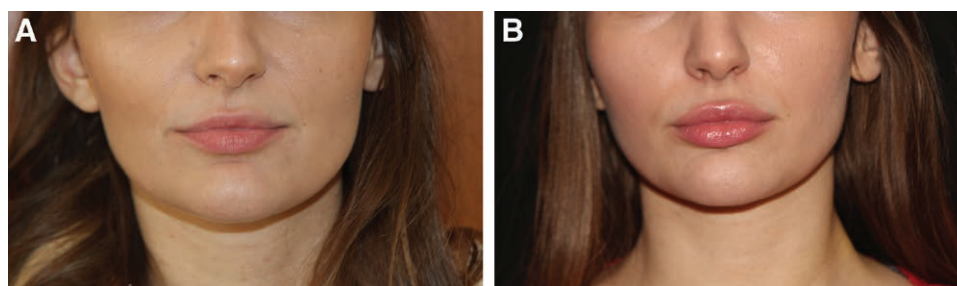


Fig. 4. Participant with normal-volume lips category before (A) and 2 months after applying the technique (B).

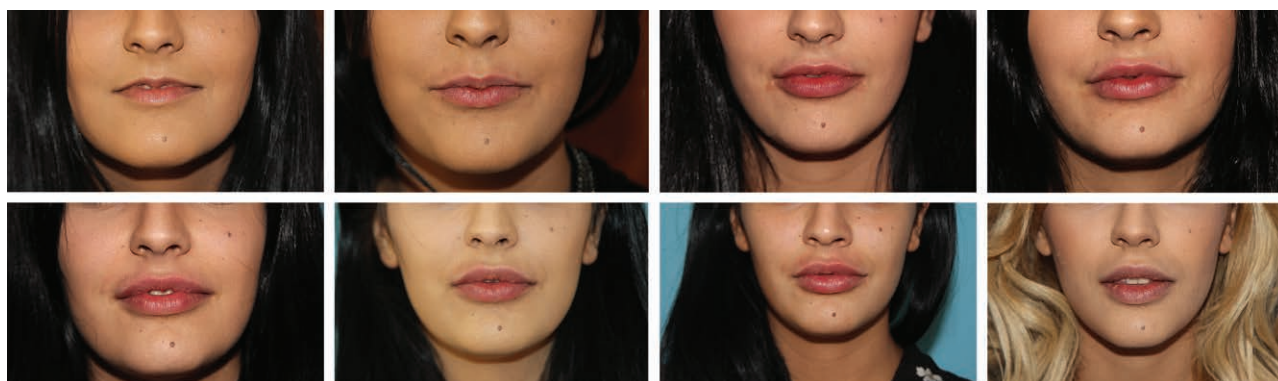

Fig. 5. Monthly spaced lip augmentation stages on a typical thin lips category participant.

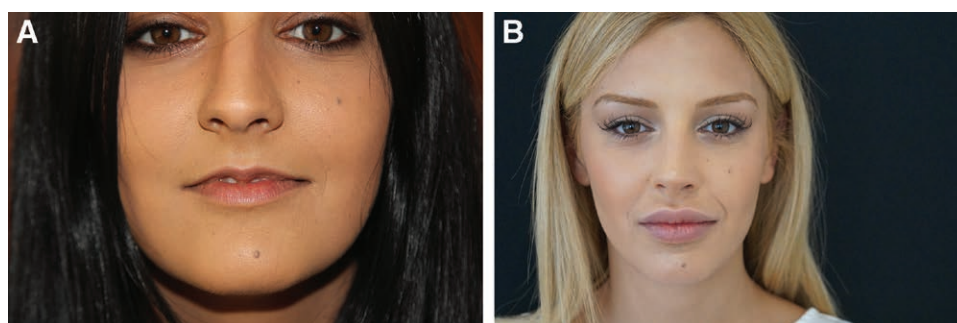


Fig. 6. Image of the patient in [Figure 5](#) just before her first session of HA lips injection (A) using the step-by-step Φ technique and 18 months following her last session (B).

DISCUSSION

There are quite a few remarkable techniques that already exist concerning lip augmentation.^{22,24,31} However we feel that the “step-by-step Φ ” technique is designed to assist junior practitioners to simplify and senior practitioners to optimize their own lip augmentation procedure. This method has a short learning curve and it is easy and safe for even a resident plastic surgeon to master. As per our experience, the most challenging parts of lip augmentation are maintaining safety at all times; finding the proper injection points; choosing the appropriate HA and the amount that should be injected in each marking point and in total in each session; planning the frequency of the sessions until the desirable goal in ratio, volume, and

shape is achieved; and, last but not least, consulting the patient.

Safety is established by: keeping the needle at 2.5-mm depth when injecting through the vermillion border at an oblique angle (30 degrees), by avoiding injecting posterior to the wet line border, and by slowly injecting the HA in a retrograde manner. Slow injection in each marked point helps prevent intravascular injections of a significant amount of HA. If an intra-arterial injection is administered accidentally, immediate acute pain and blanching will warn us to stop the procedure. Also, using a needle (instead of a cannula)—especially for beginners—helps the injector to become familiar with the most precise placement of HA.³²

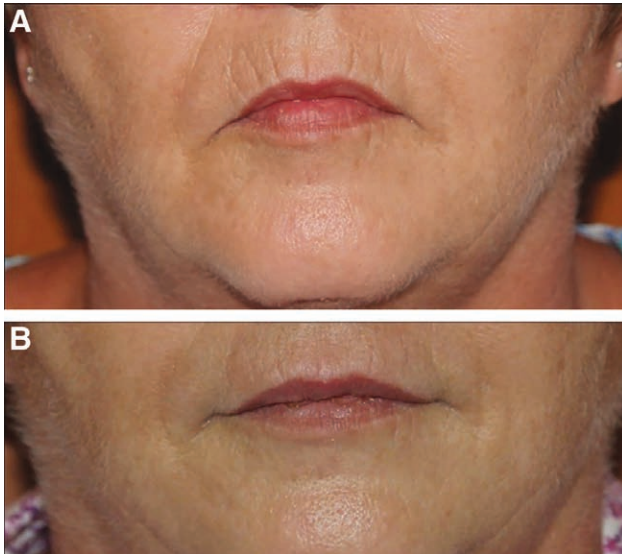

Fig. 7. Participant with thin aged-lips category before (A) and 2 months after application of the technique (B).

The Φ caliper provides a practical and reproducible way of finding and marking the correct injection points. The golden ratio has proved its aesthetic value and has had numerous applications throughout the centuries. By using the Φ caliper in a modern, different way, we identified which points/parts of the lips—if enhanced—would flatter them the most. As per our experience, a standardized lip-marking pattern with fixed injection sites, that can be applied even in quite asymmetric lips, not only allows safe aesthetic outcomes, but also provides confidence to the injector in training. However, if any asymmetries are present, customization, according to the individual's anatomy, can be achieved by injecting only 0.05–0.1 ml in the intended areas.

Classifying patients in normal-volume, thin, and aged lips is a useful tool that helps the physician planning the procedure. In normal-volume lips, we propose enhancing volume by injecting into the vermillion. In thin lips, we prefer to address first the ratio by injecting into the thinner lip, then the volume by injecting into the vermillion, and lastly the shape by injecting into the vermillion border when necessary.³³ In aged lips, we proceed as in thin lips, but we also inject HA into the vertical upper lip lines in a particularly modest manner to avoid distortions. Moreover, each target group has different reasons for undergoing this cosmetic procedure, and the injector should take these into consideration to better educate the patients, manage their expectations^{2,6,21} and set accordingly their aesthetic goals.^{21,34}

Obtaining the desirable volume at the adequate time is essential and it is summarized in the step-by-step part of this technique. The delicate lip tissue should be treated with respect, mildness, and caution. Gentle manipulations are recommended, and overfilling in a single session should be avoided because it increases the risk of complications and creates a counterfeit, “sausage,” or “duck-like”

appearance. In each marking point, it is advised to inject no more than 0.05–0.1 ml of HA, and in each session, the maximum amount of HA should be no more than 1–1.5 ml.⁶ These 2 measures of quantity could allow the tissues, especially in thin and aged lips, to gradually “expand” and provide space for the HA to settle.²¹ The filler proper adjustment provides natural lip movements and an overall natural appearance to the lips, but prevents premature lip philtrum prolongation. Undetectable results are eventually achieved by gradually injecting HA in separate 15- to 30-day sessions, according to our experience, especially in thin and aged-lips categories.

Considering the ratios of the perfect lips, the definition of ideal proportions has been attempted since ancient times, but the perception of beauty depends on aesthetic trends, which are only a snapshot in time and may be subject to change. Moreover, social media preferences of how the lips should look vary in different countries and cultures; thus, golden ratios and ideal proportions are not universally applicable and need to be seen in this context.^{2,35} However, we believe they can serve as a very helpful tool, especially in achieving aesthetically pleasing and natural results. In our technique, we use our survey's photoshopped image as a guide when discussing lip augmentation with our patients. The majority find it pleasing and helpful in managing their expectations regarding the immediate and long-term procedure's aftermath. Tailoring treatment to individual patient's needs is one of the most important steps in every technique; after all, the relative attractiveness of the lips is a matter of just a few millimeters or even less.

It is our hope that this article will help physicians, who are just starting to learn how to perform lip augmentation procedures or want to update their technique, to treat their patients effectively and in an aesthetically pleasing way.

CONCLUSIONS

We present the step-by-step Φ technique as a safe and effective method to create attractive lips. There is no single way to achieve the intended results; however, anatomical knowledge and the use of the appropriate technique are essential for an optimal and safe result.

Evangelos Keramidis, MD, FEBOPRAS

Kosmesis Aesthetic Plastic Surgery Center

Ethnikis Antistaseos 9-11

Chalandri, Athens 15232

Greece

E-mail: plastker@yahoo.com

PATIENT CONSENT

Patients provided written consent for the use of their images.

REFERENCES

1. Sito G, Consolini L, Trévidic P. Proposed guide to lip treatment in Caucasian women using objective and measurable parameters. *Aesthet Surg J*. 2019;39:NP474–NP483.
2. Popenko NA, Tripathi PB, Devic Z, et al. A quantitative approach to determining the ideal female lip aesthetic and its effect on facial attractiveness. *JAMA Facial Plast Surg*. 2017;19:261–267.

3. American Society of Plastic Surgeons. In the age of selfies, America's love affair with lips is leading to a boom in cosmetic procedures. Available at <https://www.plasticsurgery.org/news/press-releases/in-the-age-of-selfies-americas-love-affair-with-lips-is-leading-to-a-boom-in-cosmetic-procedures>. Published 2016. Accessed June 1, 2020.
4. American Society of Plastic Surgeons. 2018 national plastic surgery statistics. Available at <https://www.plasticsurgery.org/documents/News/Statistics/2018/plastic-surgery-statistics-report-2018.pdf>. Published 2019.
5. American Society of Plastic Surgeons. 2017 plastic surgery statistics. Available at <https://www.plasticsurgery.org/documents/News/Statistics/2017/cosmetic-procedure-trends-2017.pdf>. Published 2018.
6. Kim SW, Rousso DE. Determining the 2-dimensional threshold for perception of artificial-appearing lips. *JAMA Facial Plast Surg*. 2017;19:392–398.
7. Mayer JE, Goldberg DJ. Injuries attributable to cosmetic procedures performed by unlicensed individuals in the United States. *J Clin Aesthet Dermatol*. 2015;8:35–37.
8. Martin DS, Han H, Farley KL. Self injection of topical skin preparation by patient seeking facial volume enhancement: a case report. *J Clin Aesthet Dermatol*. 2019;12:51–54. <https://pubmed.ncbi.nlm.nih.gov/31531173>.
9. Ono S, Hyakusoku H. Complications after self-injection of hyaluronic acid and phosphatidylcholine for aesthetic purposes. *Aesthet Surg J*. 2010;30:442–445.
10. Perenack JD, Burke VP. Cosmetic surgery. *Manag Complicat Oral Maxillofac Surg*. 2012;203–232.
11. Haneke E. Managing complications of fillers: rare and not-so-rare. *J Cutan Aesthet Surg*. 2015;8:198–210.
12. Lee SH, Gil YC, Choi YJ, et al. Topographic anatomy of the superior labial artery for dermal filler injection. *Plast Reconstr Surg*. 2015;135:445–450.
13. Cotofana S, Steinke H, Schlattau A, et al. The anatomy of the facial vein: implications for plastic, reconstructive, and aesthetic procedures. *Plast Reconstr Surg*. 2017;139:1346–1353.
14. Lee KL, Lee HJ, Youn KH, et al. Positional relationship of superior and inferior labial artery by ultrasonography image analysis for safe lip augmentation procedures. *Clin Anat*. 2020;33:158–164.
15. Tansatit T, Phumyoo T, MCCabe H, et al. Translucent and ultrasonographic studies of the inferior labial artery for improvement of filler injection techniques. *Plast Reconstr Surg Glob Open*. 2019;7:e2399.
16. Tansatit T, Apinuntrum P, Phetudom T. A typical pattern of the labial arteries with implication for lip augmentation with injectable fillers. *Aesthetic Plast Surg*. 2014;38:1083–1089.
17. Tamargo RJ, Pindrik JA. Mammalian skull dimensions and the golden ratio (Φ). *J Craniofac Surg*. 2019;30:1750–1755.
18. Kar M, Muluk NB, Bafaqeeh SA, et al. Is it possible to define the ideal lips? *Acta Otorhinolaryngol Ital*. 2018;38:67–72.
19. Singh P, Vijayan R, Mosahebi A. The golden ratio and aesthetic surgery. *Aesthet Surg J*. 2019;39:NP4–NP5.
20. Holland E. Marquardt's Phi mask: pitfalls of relying on fashion models and the golden ratio to describe a beautiful face. *Aesthetic Plast Surg*. 2008;32:200–208.
21. Greene RM. Comparing the use of injectable fillers for the youthful lip and the more mature lip. *Facial Plast Surg*. 2019;35:134–139.
22. Sarnoff DS, Gotkin RH. Six steps to the “perfect” lip. *J Drugs Dermatol*. 2012;11:1081–1088.
23. Heidekrueger PI, Juran S, Szpalski C, et al. The current preferred female lip ratio. *J Craniomaxillofac Surg*. 2017;45:655–660.
24. Rohrich RJ, Bartlett EL, Dayan E. Practical approach and safety of hyaluronic acid fillers. *Plast Reconstr Surg Glob Open*. 2019;7:e2172.
25. Stojanovič L, Majdič N. Effectiveness and safety of hyaluronic acid fillers used to enhance overall lip fullness: a systematic review of clinical studies. *J Cosmet Dermatol*. 2019;18:436–443.
26. Werschler WP, Fagien S, Thomas J, et al. Development and validation of a photographic scale for assessment of lip fullness. *Aesthet Surg J*. 2015;35:294–307.
27. Kane MA, Lorenc ZP, Lin X, et al. Validation of a lip fullness scale for assessment of lip augmentation. *Plast Reconstr Surg*. 2012;129:822e–828e.
28. Carruthers A, Carruthers J, Hardas B, et al. A validated lip fullness grading scale. *Dermatol Surg*. 2008;34(Suppl 2):S161–S166.
29. Urdiales-Gálvez F, Delgado NE, Figueiredo V, et al. Treatment of soft tissue filler complications: expert consensus recommendations. *Aesthetic Plast Surg*. 2018;42:498–510.
30. Ablon G. Understanding how to prevent and treat adverse events of fillers and neuromodulators. *Plast Reconstr Surg Glob Open*. 2016;4(12 Suppl):e1154.
31. Surek CC, Guisantes E, Schnarr K, et al. “No-Touch” technique for lip enhancement. *Plast Reconstr Surg*. 2016;138:603e–613e.
32. Kontis TC, Bunin L, Fitzgerald R. Injectable fillers: panel discussion, controversies, and techniques. *Facial Plast Surg Clin North Am*. 2018;26:225–236.
33. Luthra A. Shaping lips with fillers. *J Cutan Aesthet Surg*. 2015;8:139–142.
34. Rayess HM, Svider PF, Hanba C, et al. A Cross-sectional analysis of adverse events and litigation for injectable fillers. *JAMA Facial Plast Surg*. 2018;20:207–214.
35. Harrar H, Myers S, Ghanem AM. Art or science? An evidence-based approach to human facial beauty: a quantitative analysis towards an informed clinical aesthetic practice. *Aesthetic Plast Surg*. 2018;42:137–146.