



Targeted Therapy with Anlotinib for a Patient with an Oncogenic *FGFR3-TACC3* Fusion and Recurrent Glioblastoma

YONG WANG,^{a,†} DANDAN LIANG,^{c,†} JIMIN CHEN,^c HUAN CHEN,^c RUI FAN,^c YE GAO,^d YONGSHENG GAO,^b RONGJIE TAO^{ORCID},^a HENGHUI ZHANG^{ORCID}^{c,e}

Departments of ^aNeurosurgery and ^bPathology, Shandong Cancer Hospital and Institute Affiliated to Shandong University, Shandong First Medical University and Shandong Academy of Medical Sciences, Jinan, People's Republic of China; ^cGenecast Biotechnology Co., Ltd, Wuxi, People's Republic of China; ^dDepartment of Neurosurgery, The People's Hospital of ZhangQiu Area, Jinan, People's Republic of China; ^eInstitute of Infectious Diseases, Beijing Ditan Hospital, Capital Medical University, Beijing, People's Republic of China

[†]Contributed equally.

Disclosures of potential conflicts of interest may be found at the end of this article.

ABSTRACT

We describe a case of recurrent glioblastoma treated with anlotinib in this report. The patient was administered anlotinib 12 mg p.o. once every day (days 1–14, with a 21-day cycle) (anlotinib clinical study NCT04004975) and oral temozolomide chemotherapy 100 mg/m² (days 1–7, days 15–21, 28-day cycle; 12 cycles). After 2 months of therapy, the patient achieved a partial response that has been maintained for >17 months of follow-up. Molecular characterization confirmed the presence of a *TERT* promoter mutation, wild-type *IDH1/2*, an *FGFR3-TACC3*

fusion, and *FGFR3* amplification in the patient. Anlotinib is a multitarget tyrosine kinase inhibitor that was originally designed to inhibit VEGFR2/3, FGFR1–4, PDGFR α/β , and c-Kit. Patients with *TERT* promoter mutations and high-grade *IDH*-wild-type glioma have shorter overall survival than patients with *IDH*-wild-type glioma without *TERT* promoter mutations. However, this patient had a favorable clinic outcome, and *FGFR3-TACC3* fusion may be a new marker for treatment of glioma with anlotinib. *The Oncologist* 2021;26:173–177

KEY POINTS

- This case study is believed to be the first report that *FGFR3-TACC3* fusion could be a novel indication to treat recurrent glioblastoma with the drug anlotinib.
- This case exhibited an exceptional response (maintained partial response >17 months) after 2-month combined therapy of anlotinib and oral temozolomide chemotherapy.
- This case also underscores the importance of molecular diagnosis for clinically complex cases. Tumor tissue-based assessment of molecular biomarkers in brain tumors has been successfully translated into clinical application.

INTRODUCTION

Glioblastoma (GBM) is the most common and fatal primary brain tumor. Despite aggressive treatment, the median overall survival (OS) is less than 15 months [1]. The preferred treatment for GBM is surgery, and subsequent treatment is a combination of radiotherapy and chemotherapy. For patients with recurrent GBM, targeted therapies are limited [2–4]. Molecular markers of GBM are needed to improve personalized diagnosis and treatment and to better understand the biology of the disease to facilitate the development of new therapies [1].

Carcinogenic fusion because of chromosomal translocation is recognized as a molecular driver in gliomas [5]. A fusion involving fibroblast growth factor receptors (*FGFR1/FGFR3*) and *TACC1/TACC3* occurs in approximately 3% of patients with GBM. *FGFR3-TACC3* fusion gliomas exhibit *FGFR3* expression [6]. Gliomas carrying the *FGFR3-TACC3* fusion are also *IDH1/2* wild type and almost always (~75%) have *TERT* promoter mutations or *CDKN2A* loss [7]. *IDH1/2*-wild-type gliomas with *TERT* promoter mutations are

Correspondence: Henghui Zhang, Ph.D., Institute of Infectious Diseases, Beijing Ditan Hospital, Capital Medical University, Beijing, 100000, People's Republic of China, Telephone: +86-10-84322621; e-mail: zhzbao@ccmu.edu.cn; or Rongjie Tao, Ph.D., Departments of Neurosurgery and Departments of Pathology, Shandong Cancer Hospital and Institute Affiliated to Shandong University, No.440. Jiyuan Road, Jinan, Shandong, 250000, People's Republic of China, Telephone: +86-31-67626311; e-mail: rongjietao@163.com Received March 10, 2020; accepted for publication August 26, 2020; published Online First on October 3, 2020. <http://dx.doi.org/10.1002/onco.13530>

No part of this article may be reproduced, stored, or transmitted in any form or for any means without the prior permission in writing from the copyright holder. For information on purchasing reprints contact Commercialreprints@wiley.com. For permission information contact permissions@wiley.com.

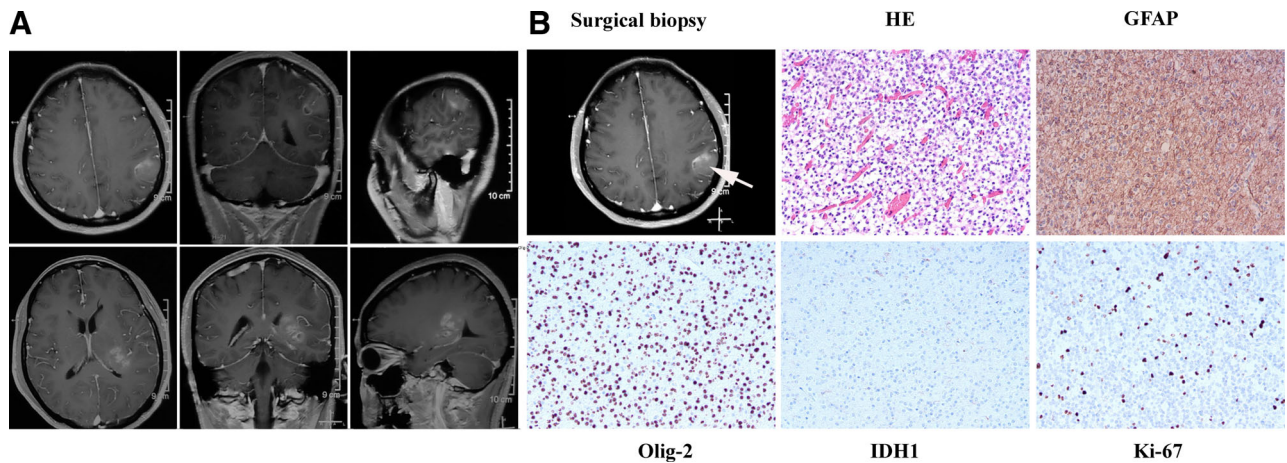


Figure 1. Image of pathological diagnosis. **(A):** Magnetic resonance imaging revealed space-occupying lesion in left thalamus and left parietal lobe. **(B):** Hematoxylin and eosin stain (200 \times) shows that tumor cells are dense and unevenly distributed, with obvious nuclear heterogeneity, and that small blood vessels proliferate in the tumor tissue. The immunohistochemical results showed that GFAP and Olig-2 were expressed, IDH-1 was negative, and the Ki67 proliferation index was \sim 3%. The final diagnosis was anaplastic astrocytoma, *IDH* wild type, World Health Organization grade III. Abbreviations: GFAP, glial fibrillary acidic protein; HE, hematoxylin and eosin.

FGFR3-TACC3 Fusion

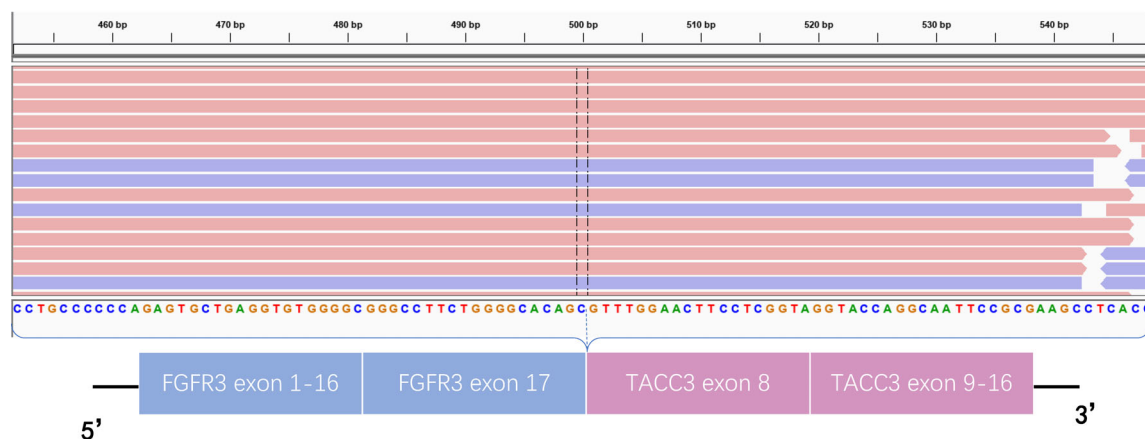


Figure 2. Structure of *FGFR-TACC* gene fusions identified by next-generation sequencing. The *FGFR3-TACC3* fusion (COSF1353) was a classic fusion in the Catalogue of Somatic Mutations in Cancer (COSMIC) and was confirmed by RNA sequencing. Abbreviation: bp, base pairs.

associated with reduced OS compared with gliomas without *TERT* mutations [8–10].

Anlotinib is a multitarget tyrosine kinase inhibitor that was originally designed to inhibit VEGFR2/3, FGFR1–4, PDGFR α/β , c-Kit, and Ret. Anlotinib can inhibit not only tumor angiogenesis but also tumor cell growth. It has been used to treat advanced lung cancer [11]. Anlotinib is approved by the National Medical Products Administration for use in non-small cell lung cancer. Preclinical results showed that anlotinib significantly inhibited FGFR1–4, especially FGFR2 [12].

PATIENT STORY

A 44-year-old woman was admitted to the hospital as a new patient on October 1, 2017; she experienced three episodes

of sudden grand mal epilepsy prior to being admitted to the hospital. Magnetic resonance imaging (MRI) revealed space-occupying lesion in the left thalamus and left parietal lobe (Fig. 1). The patient underwent tumor resection in the left parietal lobe under general anesthesia on October 10, 2017. The immunohistochemical results showed that glial fibrillary acidic protein, Olig-2, and p53 were expressed; epithelial membrane antigen and IDH-1 were negative; and the Ki67 proliferation index was \sim 3% (Fig. 1). The final diagnosis was anaplastic astrocytoma, *IDH* wild type, World Health Organization (WHO) grade III. The patient was treated with intensity modulated radiation therapy to a total dose of 60 Gy in 30 fractions, together with temozolomide (TMZ) chemotherapy 75 mg/m² taken orally on November 29, 2017. Two adjuvant TMZ cycles (200 mg/m² per day, every day, days 1–5,

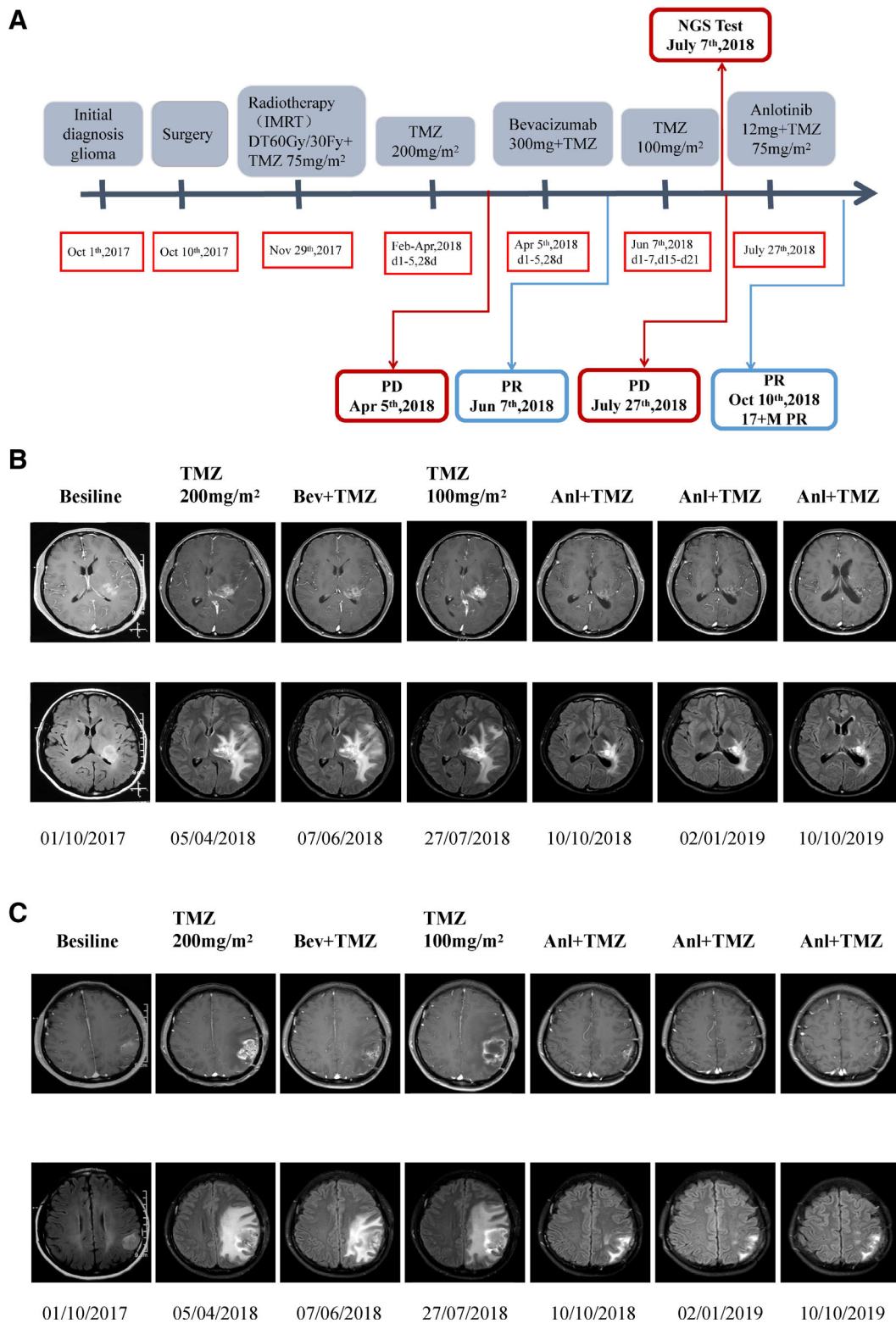


Figure 3. Timeline of treatment and radiographic responses. **(A):** Timeline of treatment. **(B):** Radiographic responses to anlotinib on left thalamus: the image of the previous row at each time is an enhanced image of the lesion; the image of the lower row of each time is the fluid attenuated inversion recovery (FLAIR) image of the lesion. FLAIR image mainly shows that the edema subsided after antivasular treatment. **(C):** Radiographic responses to anlotinib on left parietal: the image of the previous row at each time is an enhanced image of the lesion; the image of the lower row of each time is the FLAIR image of the lesion. FLAIR image mainly shows that the edema subsided after antivasular treatment. Abbreviations: 17 + M, more than 17 months; Anl, anlotinib; Bev, bevacizumab; IMRT, intensity modulated radiation therapy; NGS, next-generation sequencing; PD, progressive disease; PR, partial response; TMZ, temozolomide.

Table 1. Clinical trials of FGFR inhibitors

Tumor type	Drug	Company	Target	Clinical development stage
Glioblastoma	BGJ398	Novartis	FGFR1–3	Phase II (NCT01975701)
	AZD4547	AstraZeneca	FGFR1–3	Phase I/II (NCT02824133)
Solid tumors/ lymphoma	E-7090	Eisai	FGFR1–3	Phase I (NCT02275910)
	LY2874455	Eli Lilly & Co.	Pan-FGFR	Phase I (NCT03125239)
	TAS-120	Taiho Pharm	FGFR1–4	Phase I/II (NCT02052778)
	Erdafitinib (JNJ42756493)	Janssen	FGFR1–4, VEGFR2	Phase II (NCT02421185)
	Rogaratiniib (BAY1163877)	Bayer	FGFR1–4	Phase II (NCT03410693)
	Debio-1347	Debio Pharm	FGFR1–3	Phase I (NCT01948297)

every 28 days for one cycle) were given to this patient. MRI revealed relapse of the tumor on April 5, 2018, and the patient received bevacizumab 300 mg (5 mg/kg) targeted therapy and temozolomide (200 mg/m², days 1–5, every 28 days). Brain MRI monitoring revealed a partial response on June 7, 2018. Then, the patient received oral temozolomide chemotherapy at home (100 mg/m², days 1–7, days 15–21, every 28 days). Subsequent brain MRI monitoring showed progressive disease on July 7, 2018.

Next-generation sequencing analysis (NGS) of DNA was performed for the primary surgical tissue. The results showed the *TERT* p.C228T mutation (mutation allele frequency [MAF] = 40%, formalin-fixed, paraffin-embedded [FFPE] sample), *FGFR3* amplification (copy number [N] = 3.13, FFPE sample), and an *FGFR3-TACC3* fusion (Catalogue of Somatic Mutations in Cancer [COSMIC] mutation identifier, COSF1353; FFPE sample) (Fig. 2). Then, the *FGFR3-TACC3* fusion was verified with an RNA fusion panel. The *FGFR3-TACC3* fusion can result in diffuse FGFR3 expression in most tumor cells. *FGFR-TACC* fusions are potent oncogenic events that, when present in brain tumor cells, confer sensitivity to FGFR inhibitors [11]. Anlotinib is a novel multitarget tyrosine kinase inhibitor that is designed to primarily inhibit VEGFR2/3, FGFR1–4, PDGFR α/β , and c-Kit. The patient was administered anlotinib 12 mg p.o. every day (days 1–14, 21-day cycle) (anlotinib clinical study NCT04004975) and oral TMZ chemotherapy 100 mg/m² (days 1–7, days 15–21, 28-day cycle; 12 cycles). After 2 months of therapy, the patient achieved a partial response that has been maintained for >17 months of follow-up.

No serious adverse reactions occurred during anlotinib treatment in this case. The adverse reactions were grade 1 hypertension (well controlled by antihypertensive drugs), grade 2 hand and foot syndrome, and grade 1 white blood cell decline, with no bleeding and no proteinuria. In an ongoing clinical trial, the most common grade ≥ 3 adverse events during anlotinib treatment in advanced non-small cell lung cancer were hypertension, triglyceride elevation, hand and foot skin reaction, and lipase elevation [13]. The timeline of treatment and radiographic responses is shown in Figure 3.

DISCUSSION

Patients with *TERT* promoter mutations and high-grade *IDH*-wild-type glioma have shorter OS than patients with *IDH*-wild-type glioma without *TERT* promoter mutations [14–16]. The prognosis of patients with recurrent GBM is poor. For recurrent

gliomas, bevacizumab is the preferred drug in the National Comprehensive Cancer Network (NCCN) guidelines. Bevacizumab, a monoclonal antibody primarily inhibiting VEGF, has been used in patients with GBM as a later-line treatment since its approval in the U.S. for recurrent GBM in 2009 and has become the standard treatment for patients with recurrent GBM in the NCCN guidelines [17]. Another recommended regimen is bevacizumab plus chemotherapy (carmustine or lomustine, TMZ, or carboplatin). A meta-analysis showed that the combination of bevacizumab and chemotherapy in the treatment of recurrent GBM significantly improved the progression-free survival and objective response rate but did not extend the OS compared with single-agent bevacizumab [18]. In cases in which standard regimens fail for patients with relapsed GBM, targeted therapies are limited [2]. Molecular markers of GBM are needed to improve personalized diagnosis and treatment and to better understand the biology to facilitate the development of new therapies [1].

The significant difference in efficacy between bevacizumab and anlotinib in our case suggests that anlotinib is a suitable and promising treatment for GBM with *FGFR3-TACC3* fusion. It may provide a new option for patients with recurrent GBM after TMZ or bevacizumab treatment.

Anlotinib is a multitarget tyrosine kinase inhibitor and an oral small molecule inhibitor. The drug was originally designed to inhibit VEGFR2/3, FGFR1–4, PDGFR α/β , and c-Kit; thus, it has broad inhibitory effects on tumor angiogenesis and growth [12]. In our case report, the patient carried an *FGFR3-TACC3* fusion (COSF1353) and *FGFR3* amplification according to the NGS analysis. The *FGFR3-TACC3* fusion (COSF1353) is a classic fusion (an oncogenic driver mutually exclusive with *IDH* mutation and *EGFR* amplification that mainly occurs in GBM) [6] and was once reported in the recurrent tumor of two patients who were diagnosed with glioblastoma, WHO grade IV [7]. The *FGFR3-TACC3* fusion (COSF1353) was also reported in a 64-year-old woman who was affected by left parietal GBM, whose tumor showed diffuse FGFR3 expression in most tumor cells [11]. *FGFR-TACC* fusions are clear oncogenic events in vitro, and brain tumor cells carrying these fusions have sensitivity to FGFR inhibitors [5, 18]. In glioblastoma, a relationship between *FGFR3* amplification and FGFR3 protein expression has not been reported. However, the two are correlated up to approximately 90% of the time in bladder cancer [19]. Therefore, the reason for the significant effect of anlotinib treatment in this patient may be that the patient carried two alterations at the same time and was thus particularly sensitive to FGFR3 inhibitors. Patients with *FGFR3-TACC3* rearrangements and/or

FGFR3 amplification should be considered for clinical trials featuring FGFR inhibitors.

Gliomas carrying *FGFR3-TACC3* fusions are also *IDH1/2* wild type and almost always (~75%) have *TERT* promoter mutations or *CDKN2A* loss, which can provide an important clue for the molecular characterization of this glioma subtype [7].

Currently, it is very difficult to treat recurrent glioblastoma. There is no effective targeted drug that can prolong the overall survival of patients with recurrent glioblastoma. Our case is the first report in the world in which a patient with recurrent GBM with an *FGFR3-TACC3* fusion was treated with anlotinib, and the patient achieved a partial response that has been maintained for >17 months. In recent years, a variety of FGFR inhibitors are also undergoing clinical trials (Table 1). In view of the particularly effective treatment of a patient with recurrent GBM with *FGFR3-TACC3* fusion with anlotinib, it is worth conducting further clinical trials. Perhaps anlotinib can change the current treatment status of patients with GBM with *FGFR3-TACC3* fusion. Such a finding will have important clinical significance.

LIMITATION

There are some interesting points to be addressed. First, the patient has multiple tumors located in important functional areas (left thalamus and left parietal lobe). Therefore, the first surgery only removed the tumor node from left parietal lobe. Second, because the surgical biopsy tissue did not penetrate the central area of the tumor, we inferred that the pathological result may not comprehensively represent the true clinical situation of the patient. We invited a pathologist to perform another

pathological assessment. The final pathological diagnosis was anaplastic astrocytoma, *IDH* wild type, WHO grade III. Third, the patient did not take a molecular diagnosis after the first surgery, and she only took the traditional treatment (because of economic reasons). Then the patient had a short clinical relapse, and the disease could not be controlled after traditional treatment. In order to find a better treatment, NGS of DNA was performed for the primary surgical tissue. The results showed *IDH* wild type, codeletion of 1q/19p absent, *TERT* p.C228T mutation. Based on the above data and the initial pathological results, we concluded that this patient had a glioblastoma [20, 21].

After relapse, MRI of tumor lesions showed a cystic change and enhanced aggravation, accompanied by tumor cell necrosis. The characteristics of MRI were also consistent with the recurrent glioblastoma.

Combining the pathological result, molecular features, and postrelapse MRI characteristics, the patient had a recurrent glioblastoma. This also reflects the importance of molecular diagnosis for clinically complex cases.

AUTHOR CONTRIBUTIONS

Conception/design: Yong Wang, Dandan Liang

Provision of study material or patients: Yong Wang, Jimin Chen

Collection and/or assembly of data: Jimin Chen, Huan Chen

Data analysis and interpretation: Yong Wang, Rui Fan

Manuscript writing: Rui Fan, Rongjie Tao

Final approval of manuscript: Yong Wang, Dandan Liang, Jimin Chen, Huan Chen, Rui Fan, Ye Gao, Yongsheng Gao, Rongjie Tao, Henghui Zhang

DISCLOSURES

The authors indicated no financial relationships.

REFERENCES

- Diplas BH, He X, Brosnan-Cashman JA et al. The genomic landscape of *TERT* promoter wildtype-*IDH* wildtype glioblastoma. *Nat Commun* 2018;9:2087.
- Lv Y, Zhang J, Liu F et al. Targeted therapy with anlotinib for patient with recurrent glioblastoma: A case report and literature review. *Medicine (Baltimore)* 2019;98:e15749.
- Lau D, Magill ST, Aghi MK. Molecularly targeted therapies for recurrent glioblastoma: Current and future targets. *Neurosurg Focus* 2014;37:E15.
- Touat M, Idbaih A, Sanson M et al. Glioblastoma targeted therapy: Updated approaches from recent biological insights. *Ann Oncol* 2017;28:1457–1472.
- Singh D, Chan JM, Zoppoli P et al. Transforming fusions of FGFR and TACC genes in human glioblastoma. *Science* 2012;337:1231–1235.
- Bielle F, Di Stefano AL, Meyronet D et al. Diffuse gliomas with *FGFR3-TACC3* fusion have characteristic histopathological and molecular features. *Brain Pathol* 2018;28:674–683.
- Ballester LY, Moghadamtousi SZ, Leeds NE et al. Coexisting *FGFR3* p.K650T mutation in two *FGFR3-TACC3* fusion glioma cases. *Acta Neuropathol Commun* 2019;7:63.
- Camille P, Anne G, Emilie B et al. Increasing incidence of central nervous system (CNS) tumors (2000–2012): Findings from a population based registry in Gironde (France). *BMC Cancer* 2018;18:653.
- Horbinski C. What do we know about *IDH1/2* mutations so far, and how do we use it? *Acta Neuropathol* 2013;125:621–636.
- Jiao Y, Killela PJ, Reitman ZJ et al. Frequent *ATRX*, *CIC*, *FUBP1* and *IDH1* mutations refine the classification of malignant gliomas. *Oncotarget* 2012;3:709–722.
- Di Stefano AL, Fucci A, Frattini V et al. Detection, characterization, and inhibition of *FGFR-TACC* fusions in *IDH* wild-type glioma. *Clin Cancer Res* 2015;21:3307–3317.
- Sun Y, Niu W, Du F et al. Safety, pharmacokinetics, and antitumor properties of anlotinib, an oral multi-target tyrosine kinase inhibitor, in patients with advanced refractory solid tumors. *J Hematol Oncol* 2016;9:105.
- Syed YY. Anlotinib: First global approval. *Drugs* 2018;78:1057–1062.
- Eckel-Passow JE, Lachance DH, Molinaro AM et al. Glioma groups based on 1p/19q, *IDH*, and *TERT* promoter mutations in tumors. *N Engl J Med* 2015;372:2499–2508.
- Killela PJ, Reitman ZJ, Jiao Y et al. *TERT* promoter mutations occur frequently in gliomas and a subset of tumors derived from cells with low rates of self-renewal. *Proc Natl Acad Sci USA* 2013;110:6021–6026.
- Arita H, Yamasaki K, Matsushita Y et al. A combination of *TERT* promoter mutation and *MGMT* methylation status predicts clinically relevant subgroups of newly diagnosed glioblastomas. *Acta Neuropathol Commun* 2016;4:79.
- Capelletti M, Dodge ME, Ercan D et al. Identification of recurrent *FGFR3-TACC3* fusion oncogenes from lung adenocarcinoma. *Clin Cancer Res* 2014;20:6551–6558.
- Chen Z, Xu N, Zhao C et al. Bevacizumab combined with chemotherapy vs single-agent therapy in recurrent glioblastoma: Evidence from randomized controlled trials. *Cancer Manag Res* 2018;10:2193–2205.
- Tomlinson DC, Baldo O, Harnden P et al. *FGFR3* protein expression and its relationship to mutation status and prognostic variables in bladder cancer. *J Pathol* 2007;213:91–98.
- Foot MB, Papadopoulos N, Diaz Jr LA. Genetic classification of gliomas: Refining histopathology. *Cancer Cell* 2015;28:9–11.
- Masui K, Mischel PS, Reifenberger G. Molecular classification of gliomas. *Handb Clin Neurol* 2016;134:97–120.