



Since January 2020 Elsevier has created a COVID-19 resource centre with free information in English and Mandarin on the novel coronavirus COVID-19. The COVID-19 resource centre is hosted on Elsevier Connect, the company's public news and information website.

Elsevier hereby grants permission to make all its COVID-19-related research that is available on the COVID-19 resource centre - including this research content - immediately available in PubMed Central and other publicly funded repositories, such as the WHO COVID database with rights for unrestricted research re-use and analyses in any form or by any means with acknowledgement of the original source. These permissions are granted for free by Elsevier for as long as the COVID-19 resource centre remains active.

Cerebral Venous Sinus Thrombosis in COVID-19 Patients: A Multicenter Study and Review of Literature

Mohamad Abdalkader,^{*#} Shamsh P. Shaikh,[†] James E. Siegler,[‡]
Anna M. Cervantes-Arslanian,^{†§} Cristina Tiu,^e Razvan Alexandru Radu,[¶]
Vlad Eugen Tiu,[¶] Dinesh V. Jillella,[|] Ossama Yassin Mansour,^{\$}
V́ctor Vera,^{**} Ángel Chamorro,^{**} Jordi Blasco,^{**} Antonio López,^{**}
Mudassir Farooqui,^{††} Lauren Thau,[‡] Ainsley Smith,[‡]
Santiago Ortega Gutierrez,^{‡‡} Thanh N. Nguyen,^{*†§} and Tudor G. Jovin,[‡]

Background: COVID-19 infection has been known to predispose patients to both arterial and venous thromboembolic events such as deep venous thrombosis, pulmonary embolism, myocardial infarction, and stroke. A few reports from the literature suggest that Cerebral Venous Sinus Thrombosis (CVSTs) may be a direct complication of COVID-19. *Objective:* To review the clinical and radiological presentation of COVID-19 positive patients diagnosed with CVST. *Methods:* This was a multicenter, cross-sectional, retrospective study of patients diagnosed with CVST and COVID-19 reviewed from March 1, 2020 to November 8, 2020. We evaluated their clinical presentations, risk factors, clinical management, and outcome. We reviewed all published cases of CVST in patients with COVID-19 infection from January 1, 2020 to November 13, 2020. *Results:* There were 8 patients diagnosed with CVST and COVID-19 during the study period at 7 out of 31 participating centers. Patients in our case series were mostly female (7/8, 87.5%). Most patients presented with non-specific symptoms such as headache (50%), fever (50%), and gastrointestinal symptoms (75%). Several patients presented with focal neurologic deficits (2/8, 25%) or decreased consciousness (2/8, 25%). D-dimer and inflammatory biomarkers were significantly elevated relative to reference ranges in patients with available laboratory data. The superior sagittal and transverse sinuses were the most common sites for acute CVST formation (6/8, 75%). Median time to onset of focal neurologic deficit from initial COVID-19 diagnosis was 3 days (interquartile range 0.75–3 days). Median time from onset of COVID-19 symptoms to CVST radiologic diagnosis was 11 days (interquartile range 6–16.75 days). Mortality was low in this cohort (1/8 or 12.5%). *Conclusions:* Clinicians should consider the risk of acute CVST in patients positive for COVID-19, especially if neurological symptoms develop.

From the *Department of Radiology, Boston Medical Center, Boston, Massachusetts, USA; †Department of Neurology, Boston Medical Center, Boston, Massachusetts, USA; ‡Department of Neurosurgery, Boston Medical Center, Boston, Massachusetts, USA; §Department of Neurology, Cooper University Hospital, Camden, New Jersey, USA; ¶Department of Neurology, Elias University Emergency Hospital, Bucharest, Romania; | Department of Neurology, Emory University Hospital, Atlanta, Georgia, USA; \$Department of Neurology, Alexandria University School of Medicine, Alexandria, Egypt; **Department of Radiology, Hospital Cĺnic de Barcelona, Barcelona, Spain; ††Department of Neurology, University of Iowa, Iowa City, Iowa, USA; and ‡‡Department of Neurosurgery, University of Iowa, Iowa City, Iowa, USA.

Received January 25, 2021; revision received February 23, 2021; accepted February 28, 2021.

Corresponding authors. E-mail: mohamad.abdalkader@bmc.org.

[#]Both authors contributed equally to this manuscript

1052-3057/\$ - see front matter

© 2021 Elsevier Inc. All rights reserved.

<https://doi.org/10.1016/j.jstrokecerebrovasdis.2021.105733>

Key Words: COVID-19—SARS-CoV-2—Cerebral venous sinus thrombosis—CVST—Stroke
© 2021 Elsevier Inc. All rights reserved.

Introduction

The COVID-19 pandemic originated in December 2019 in Wuhan, China and quickly spread across the world with over 110 million reported global cases and 2.4 million global deaths as of February 20th, 2021.¹ Though COVID-19 was initially feared due to its respiratory sequelae, a spectrum of thromboembolic and neurologic complications have been reported^{2–6}. Several reports suggest that COVID-19 may be associated with an increased risk of stroke in young patients or patients with cryptogenic stroke.^{7–9} Proposed mechanisms for ischemic events include systemic inflammation (as evidenced by biomarkers), hypercoagulable state (due to renin-angiotensin-aldosterone disruption and cytokine storm), and endothelial injury leading to alterations in the normal coagulation cascade.¹⁰

Both cerebral venous thrombosis and COVID-19 infection are known to occur independently in young populations, the former often with concomitant risk factors such as oral contraceptives, malignancy, dehydration, hypercoagulable state, or trauma.¹¹ The clinical presentation may be compounded by recent reports suggesting that CVST may be a direct consequence of COVID-19.^{12–30} Age, abnormal level of consciousness, and focal motor deficits on admission may be harbingers of poorer outcome in CVST patients.³¹

Here, we present a case series of 8 patients and review the literature to characterize the presentation, management, and outcomes related to CVST events in COVID-19 patients.

Methods

A retrospective observational registry (The SVIN COVID-19 Multinational Registry involving prospectively gathered data from 17 healthcare networks (31 unique hospitals) across four countries (USA, Spain, Egypt, and Romania) was queried.³² Of the 31 participating centers, 7 hospitals reported patients diagnosed with CVST and COVID-19 between March 1, 2020 to November 8, 2020. The clinical presentations, risk factors, management, and outcomes of these patients were subsequently reviewed. Patient demographic information, pertinent medical history, National Institutes of Health Stroke Scale (NIHSS) score, neuroimaging, treatment, laboratory testing (inflammatory and hematologic parameters, D-dimer), discharge modified Rankin Scale (mRS), and discharge disposition were recorded. De-identified data elements (including age, which was binned by decade for de-identification purposes) were documented by local investigators on a HIPAA-compliant, previously described online platform. Cooper University Hospital served as the central coordinating site of data.

We reviewed the literature and extracted published cases of CVST in patients with COVID-19 infection from January 1, 2020 to November 13, 2020 using the keywords “cerebral venous sinus thrombosis AND COVID-19;” “cerebral venous sinus thrombosis AND SARS-CoV-2;” or “cerebral venous sinus thrombosis AND coronavirus;” “Stroke AND COVID-19;” or “venous thromboembolism AND COVID-19” searched on PubMed and Google Scholar.

Abstracts and published articles were reviewed for the following parameters: patient demographics, clinical presentation, comorbidities, relevant laboratory studies, imaging data, hospitalization events, and outcomes. Studies that did not utilize PCR testing for COVID-19 diagnosis or studies without a confirmed radiologic diagnosis of CVST were excluded. One study was excluded in its entirety, whereas several individual patients from other studies were also excluded if they did not have confirmed RT-PCR nasopharyngeal swab results (two patients were excluded).

This study was approved under a waiver of informed consent by the local institutional review board at each participating center. Anonymized data are available upon reasonable request to the corresponding author.

Results

There were 8 patients with COVID-19 infection confirmed by RT-PCR testing who developed CVST (Table 1). Patients were mostly female (N = 7, 87.5%), with an average age of 63.3 ± 20 years old. Essential hypertension (N = 4, 50%) and diabetes mellitus (N = 3, 37.5%) were the most common medical comorbidities. Two patients (25%) had identifiable risk factors for CVST including an underlying hypercoagulable state likely due to antiphospholipid syndrome as well as morbid obesity. Most patients presented with non-specific symptoms such as headache (50%), fever (50%), and gastrointestinal symptoms (75%). Other neurological symptoms such as decreased consciousness (12.5%) and focal neurologic deficit (25%) were also seen. The median time to onset of focal neurologic deficit from initial COVID-19 diagnosis (as defined by numbness, hemiparesis, weakness, facial palsy, vision changes, or aphasia) was 3 days (interquartile range 0.75–3 days). The median time from onset of COVID-19 symptoms to CVST radiologic diagnosis was 11 days (interquartile range 6–16.75 days).

The radiologic diagnosis of acute CVST was confirmed via observing cord-like hyperintensities or cord-like filling defects on Computerized Tomography Venogram (CTV) studies in five (62.5%) patients. CVST in the remaining three patients was confirmed by the absence of flow-related signal loss on Magnetic Resonance Imaging (MRI)

Table 1. Patient demographics, CVST risk factors, presenting symptoms, diagnostic imaging, vessels affected, hospital-stay associated complications, treatment modalities, and endpoints

Variable	Current series n = 8	Literature series n = 33	Combined series n = 41
Age in years, mean ± SD	63.3 ± 20.0	51.7 ± 21.9	50.1 ± 16.5
Sex — N (%)			
Male	1 (12.5%)	18 (54.5%)	19 (46.3%)
Female	7 (87.5%)	15 (45.5%)	22 (53.7%)
Past medical history — N (%)			
Hypertension	4 (50%)	2 (6.06%)	6 (14.6%)
Heart failure	1 (12.5%)	-	1 (2.44%)
Diabetes mellitus	3 (37.5%)	2 (6.06%)	5 (12.2%)
Hyperlipidemia	1 (12.5%)	-	1 (2.44%)
Prior solid malignancy	-	1 (3.03%)	1 (2.44%)
Miliary tuberculosis	-	1 (3.03%)	1 (2.44%)
Known CVST risk factor			
Oral contraceptive usage	-	5 (15.2%)	5 (12.2%)
Hormone replacement therapy	-	1 (3.03%)	1 (2.44%)
Iron-deficiency anemia	-	1 (3.03%)	1 (2.44%)
Antiphospholipid syndrome ¹	1 (12.5%)	1 (3.03%)	2 (4.88%)
Morbid obesity	1 (12.5%)	1 (3.03%)	2 (4.88%)
Presenting symptoms			
Headache	4 (50%)	16 (48.5%)	20 (48.8%)
Fever	4 (50%)	8 (24.2%)	12 (29.3%)
Gastrointestinal	6 (75%)	3 (9.1%)	9 (21.9%)
Cough	3 (37.5%)	5 (15.2%)	8 (19.5%)
Dyspnea	2 (25%)	3 (9.1%)	5 (12.2%)
Decreased consciousness	2 (25%)	8 (24.2%)	10 (24.4%)
Seizure	-	8 (24.2%)	8 (19.5%)
Focal neurologic deficit ²	2 (12.5%)	11 (33.3%)	13 (31.7%)
Diagnostic imaging for CVST			
Non-contrast head CT	5 (62.5%)	28 (84.8%)	33 (80.4%)
CT angiogram	2 (25%)	4 (12.1%)	6 (14.6%)
CT venogram	3 (37.5%)	10 (30.3%)	13 (31.7%)
MRI	3 (37.5%)	24 (72.7%)	27 (65.9%)
MR venogram	2 (25%)	17 (51.5%)	19 (46.3%)
Location of CVST			
Superior sagittal sinus	6 (75%)	13 (39.4%)	19 (46.3%)
Inferior sagittal sinus	2 (25%)	-	2 (4.88%)
Transverse sinus	6 (75%)	20 (60.6%)	26 (63.4%)
Sigmoid sinus	2 (25%)	6 (18.2%)	8 (19.5%)
Straight sinus	-	8 (24.2%)	8 (19.5%)
Vein of Galen	2 (25%)	5 (15.2%)	7 (17.1%)
Internal cerebral veins	2 (25%)	6 (18.2%)	8 (19.5%)
Deep medullary veins	-	1 (3.03%)	1 (2.44%)
Vein of Labbe	-	1 (3.03%)	1 (2.44%)
Basal veins of Rosenthal	-	2 (6.06%)	2 (4.88%)
Confluence of sinuses	1 (12.5%)	2 (6.06%)	3 (7.32%)
Cavernous sinus	-	1 (3.03%)	1 (2.44%)
In-hospital events — N (%)			
Intubation	1 (12.5%)	6 (18.2%)	7 (17.1%)
Seizure	3 (37.5%)	3 (9.1%)	6 (14.6%)
Hypovolemic shock	1 (12.5%)	2 (6.06%)	3 (7.32%)
Myositis	1 (12.5%)	-	1 (2.44%)
Intracranial hemorrhage	2 (25%)	6 (18.2%)	8 (19.5%)
Elevated intracranial pressure	1 (12.5%)	4 (12.1%)	5 (12.2%)
Coagulation dysregulation	1 (12.5%) ³	2 (6.06%) ⁴	3 (7.32%)

(Continued)

Table 1 (Continued)

Variable	Current series <i>n</i> = 8	Literature series <i>n</i> = 33	Combined series <i>n</i> = 41
Cardiac arrest	-	1 (3.03%)	1 (2.44%)
Acute Respiratory Distress Syndrome	-	1 (3.03%)	1 (2.44%)
Treatment — N (%)			
Pharmacological treatment for COVID-19 ⁵	1 (12.5%)	5 (15.2%)	6 (12.2%)
Therapeutic anticoagulation	7 (87.5%)	16 (48.5%)	23 (56.1%)
Intravenous rTPA	-	1 (3.03%)	1 (2.44%)
Endovascular therapy	-	1 (3.03%)	1 (2.44%)
Decompressive hemicraniectomy	-	1 (3.03%)	1 (2.44%)
External ventricular drain / Ventriculoperitoneal shunt	-	2 (6.06%)	2 (4.88%)
Antiplatelet agent (aspirin)	1 (12.5%)	1 (3.03%)	1 (2.44%)
Intravenous antibiotics	-	2 (6.06%)	2 (4.88%)
Anti-epileptic agents	3 (37.5%)	6 (18.2%)	9 (21.9%)
Steroids	-	2 (6.06%)	2 (4.88%)
Outcomes			
Death — N (%)	1 (12.5%)	8 (24.2%)	9 (21.9%)
Readmission — N (%) ⁶	2 (25%)	3 (9.1%)	5 (12.2%)
GCS at time of CVST diagnosis — median (IQR)	15 (14.75-15)	15 (14-15)	15 (12-15)
NIHSS at time of CVST diagnosis — median (IQR)	1 (0.75-1.25)	15 (7-15.5)	4 (1-13)
Days to neurological symptoms — median (IQR)	3 (0.75-3)	1 (0-13)	1 (0-12.5)
modified Rankin Scale (mRS) \leq 2	5 (62.5%)	15 (45.5%)	20 (48.8%)

SD = standard deviation; GCS = Glasgow Coma Scale; NIHSS = National Institutes of Health Stroke Scale; IQR = interquartile range

¹As evidenced by elevated titers of antiphospholipid antibodies (lupus anticoagulant, anti-cardiolipin IgG or IgM, anti-beta-2-glycoprotein IgG or IgM) in the setting of CVST

²Defined as weakness, hemiparesis, numbness, facial asymmetry, vision disturbances, or aphasia

³This patient's aPTT rose to 164 seconds at the time of CVST diagnosis. Of note, she had an extensive past medical history of bleeding disorders such as Immune Thrombocytopenic Purpura, von Willebrand disease, and Evans syndrome.

⁴One patient suffered from Disseminated Intravascular Coagulation while another was found to have a pulmonary embolism

⁵Including but not limited to hydroxychloroquine and azithromycin

⁶Defined as subsequent hospitalization for COVID-19 related symptoms less than 1 month after CVST

or by visualizing cord-like filling defects on Magnetic Resonance Venogram (MRV) studies. The superior sagittal and transverse sinuses were the most common sites for CVST formation (N = 6 or 75% for both). However, CVST was also observed in the torcular herophili in 1 patient and in smaller caliber "deep" venous structures such as the vein of Galen and internal cerebral veins (N = 2 or 25% for both). Half of our patients (N = 4, 50%) had CVST spanning multiple cerebral venous sinuses. If bilateral CVST was present — as seen in two patients (25%) — the transverse sinuses were most likely to be affected (Fig. 1).

Inflammatory biomarkers such as CRP (45.1 ± 50.6 mg/L), ESR (49 ± 17.5 mm/hr), ferritin (548.3 ± 202.2 ng/mL), and LDH (373.5 ± 171.6 units/L) were universally elevated compared to their respective reference ranges. Reported white blood cell counts on presentation were sub-clinical at 8.8 ± 4.8 (thousand per uL). D-dimer ($5,919 \pm 3,548$ ng/mL) was significantly elevated above reference ranges. On the other hand, aPTT (35.7 ± 15.4 s), PT (12.9 ± 0.5 s), INR (1.05 ± 0.06), and platelets (227.5 ± 120.2 thousand per uL) were within normal limits. Coagulation studies were obtained prior to the initiation of anticoagulation. Lastly, serum glucose levels were found to be elevated (342 ± 279.6 mg/dL).

The severity of COVID-19 infection at the time of hospital admission was classified according to the World Health Organization (WHO) guidelines into the following categories: asymptomatic, mild, moderate, severe, and critical.³³ Three patients presented with severe disease as characterized by their need for supplemental oxygen upon arrival, elevated systolic blood pressure >160 mmHg, and CT chest imaging data. The remaining five patients had mild to moderate disease as evidenced by oxygen saturation \geq 90% on room air, normotensive blood pressure, or absence of pulmonary findings on chest radiographs.

Several of our patients experienced in-hospital complications including intracranial hemorrhage (2/8, 25%), seizure (3/8, 37.5%), hypovolemic shock (1/8, 12.5%), or intubation (1/8, 12.5%). Intraparenchymal hemorrhage (1/8) and subarachnoid hemorrhage (1/8) were observed on repeat CT brain studies. Most patients (87.5%) received therapeutic anticoagulation in the form of subcutaneous enoxaparin (N = 3) or an intravenous heparin drip (N = 4) immediately after radiographic diagnosis of CVST was confirmed. No patients received prophylactic anticoagulation, and no patients underwent transition from heparin to enoxaparin during their hospital stay (or vice versa). None of the patients received endovascular therapy. One

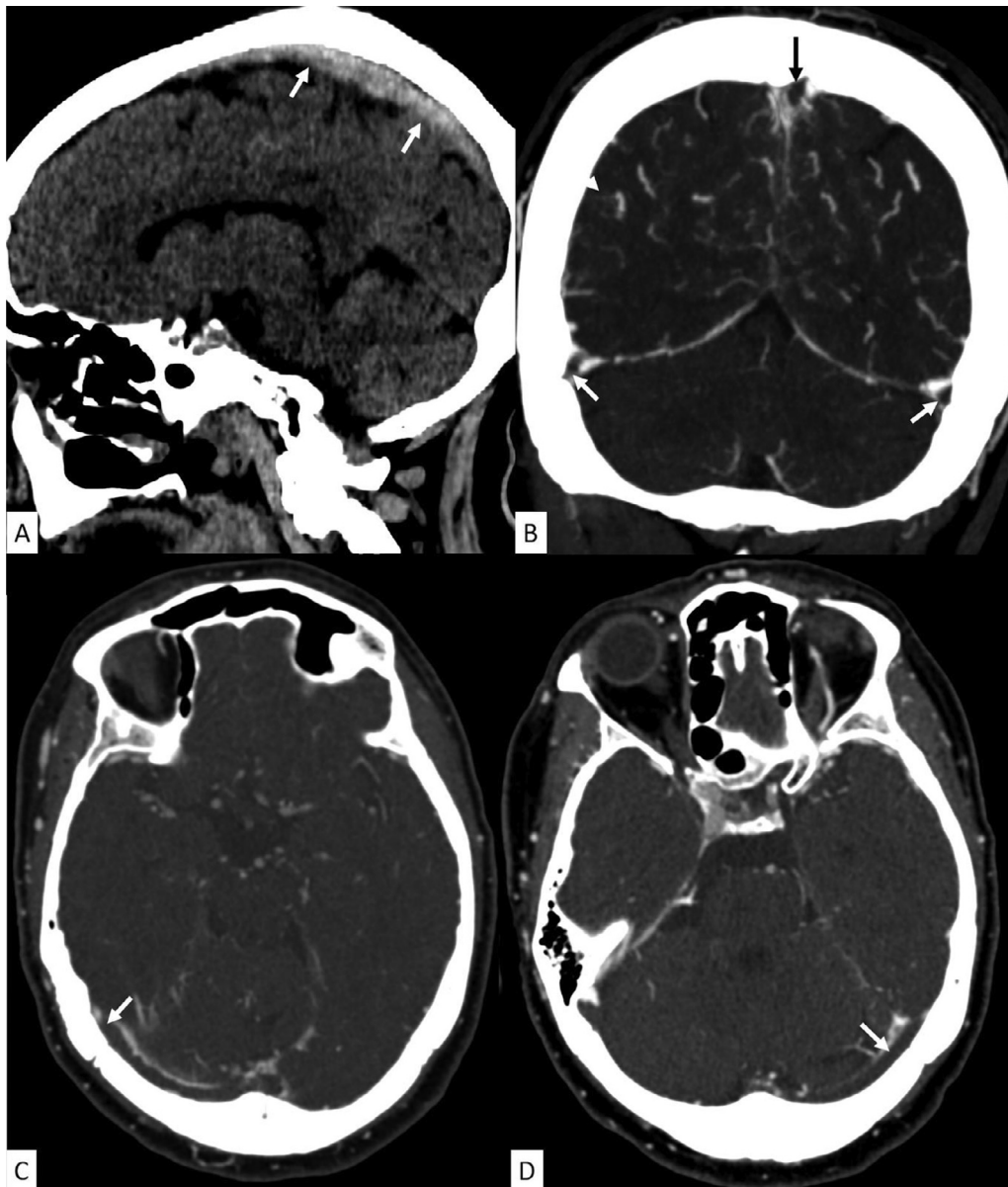


Figure 1. A 68-year-old woman presented with fever, cough, and shortness of breath. A nasopharyngeal swab RT-PCR test resulted positive for SARS-CoV-2. Three weeks later, she returned with generalized weakness, headache, nausea and vomiting. Sagittal CT brain without contrast (A) showing abnormally dense superior sagittal sinus (white arrows). Coronal (B) and axial (C, D) CT venogram showing filling defects within the superior sagittal sinus (black arrow, B) and the bilateral transverse sinuses (white arrows, A, B and C) consistent with venous thrombosis.

patient was simultaneously started on aspirin. All patients who developed seizure-like activity underwent EEG monitoring and received antiepileptic agents such as lorazepam, levetiracetam, and lacosamide. Median GCS and NIHSS at the time of CVST diagnosis were 15 (interquartile range of 14–15) and 1 (interquartile range 0–3) respectively. Additional endpoints included $N = 2$ (25%) readmissions due to COVID-19 induced respiratory complications and $N = 1$ (12.5%) recorded death related. Five patients (62.5%) were discharged home with minimal to no symptoms ($mRS \leq 2$).

Our literature review (Tables 1 and 2) consists of seventeen eligible studies from twelve countries describing 33 total

COVID-19 patients who also developed CVST. On average, patients in the literature series were younger with a mean age of 43.6 ± 17.6 years old. There was a male preponderance, with females making up 42.9% of the population. Known CVST risk factors reported included estrogen-modulating medications (6/35, 17.1%), antiphospholipid syndrome (1/35, 2.9%), and morbid obesity (1/35, 2.9%). Although headache continued to be the predominant presenting symptom in (48.6%) of patients, seizure (25.7%), decreased consciousness (25.7%), and focal neurologic deficits (31.4%) were also common. Median GCS and NIHSS at the time of CVST diagnosis were 14 (interquartile range 12–15) and 12 (interquartile range 7–15) respectively. Median time to onset of

Table 2. Summary of literature review separated by author (total of $n = 33$ patients)

Authors	Patients (n)
<i>Klein et al.</i> (East Garden City, New York, USA)	1
<i>Cavalcanti et al.</i> (New York City, New York, USA)	3
<i>Poillon et al.</i> (Paris, France)	2
<i>Sugiyama et al.</i> (Kobe City, Japan)	1
<i>Hoelscher et al.</i> (Philadelphia, Pennsylvania, USA)	1
<i>Hughes et al.</i> (Bangor, Wales, United Kingdom)	1
<i>Dahl-Cruz et al.</i> (Alicante, Spain)	1
<i>Bolaji et al.</i> (Wolverhampton, United Kingdom)	1
<i>HemAsian et al.</i> (Isfahan, Iran)	1
<i>Chougar et al.</i> (Paris, France)	1
<i>Garaci et al.</i> (Rome, Italy)	1
<i>Essajee et al.</i> (Cape Town, South Africa)	1
<i>Aghayari et al.</i> (Rasht, Iran)	1
<i>Dakay et al.</i> (Valhalla, New York, USA)	2
<i>Hussain et al.</i> (Doha, Qatar)	1
<i>Khacha et al.</i> (Fez, Morocco)	1
<i>Mowla et al.</i> (Danville, Pennsylvania, USA)	13

neurological symptoms was 1 day with an interquartile range of 0.25–4.25 days. CVST diagnosis was confirmed via CT venogram (48.6%) or MR venogram (51.4%). The transverse sinus was the most common site for CVST formation (62.9%), followed by the superior sagittal sinus (37.1%). Several less common locations for CVST were observed in this literature series such as the straight sinus (22.9%), vein of Galen (14.3%), basal veins of Rosenthal (5.7%), and the cavernous sinus (3.03%). Inflammatory biomarkers were elevated as characterized by CRP (34.8–39.2 mg/L), ESR (56.1 ± 28.8 mm/hr), ferritin (580 ± 553 ng/mL), and LDH (737 ± 800 units/L). Coagulation studies such as D-dimer ($9,571 \pm 14,439$ ng/mL) were significantly elevated.

Our literature series of patients also experienced a similar spectrum of in-hospital events, such as intubation (6/35, 17.1%), seizure (3/35, 8.6%), and intracranial hemorrhage (7/35, 20.0%). Other events such as elevated intracranial pressure (4/35, 11.4%), Acute Respiratory Distress Syndrome (1/35, 2.9%), cardiac arrest (1/35, 2.9%), pulmonary embolism (1/35, 2.9%), and Disseminated Intravascular Coagulation (1/35, 2.9%) were also documented. Treatment modalities varied from therapeutic anticoagulation (18/35, 51.4%) to endovascular therapy (1/35, 2.9%) and intravenous rtPA administration (1/35, 2.9%). Additional endpoints included (3/35, 8.6%) readmissions due to COVID-19 induced respiratory complications and (9/35, 25.7%) recorded mortalities. Sixteen patients (45.7%) were discharged with mRS ≤ 2 in this cohort.

Discussion

Our series of 8 cases, as well as the published data of patients with CVST and COVID-19, suggest that acute

CVST is a rare event associated with COVID-19 infection. Most patients in our series (75%) as well as 74% of the published cases of CVST and COVID-19 did not have identifiable risk factors for CVST.

In our current series, the majority of patients with CSVT and COVID-19 were women (87.5%), similar to incidence rates reported in non-COVID-19 patient populations.³⁴ Although CVST is usually more commonly reported in young individuals,³⁵ the mean age of patients with CVST and COVID-19 in our series was older (~63 years old). Our findings indicate that age may not play as significant of a role in assessing risk for CVST in COVID-19 patients as previously suggested. In-hospital mortality was also relatively low in our current series (1/8 patients or 12.5%). This is in contrast to data aggregated from our literature review, wherein 9/35 or 25.7% of patients succumbed to their illness.^{15,18,23,27} This mortality rate is significantly higher than previous reports in non-COVID-19 CVST populations (2–8%), suggesting that concomitant COVID-19 infection in CVST patients may portend worse prognosis.^{36–38}

Our data corroborate previous findings that COVID-19 may be a trigger for a systemic inflammatory state as evidenced by noticeable elevations in peripheral biomarkers.^{39–40} Notably, ESR, CRP, ferritin, and LDH were elevated in the majority of our patients with available laboratory data when compared to reference ranges. Moreover, our case series revealed extreme elevations in standard coagulation studies such as D-dimer, which was noted to exceed 3,000 ng/mL and approach 10,000 ng/mL in five out of six of our patients with laboratory data. These findings support the notion that COVID-19 infection may be associated with widespread, systemic prothrombotic consequences.^{41–42}

Although the presentation of CVST is subtle, the most common initial symptoms seen in our series included headache, low-grade fever, and gastrointestinal symptoms. However, clinicians should be prepared for a wide variety of symptoms as COVID-19 patients with acute CVST can present with seizures, signs of intracranial hypertension, decreased consciousness, altered sensorium, and classic stroke symptoms such as numbness/weakness of the extremities. Such neurologic symptoms may appear within hours, days, or weeks of initial presentation with no definite time frame, thereby further complicating the already elusive diagnosis of CVST. Our data supports prior conclusions that CVST may be an underlying etiology causing seizure-like activity, headache, or altered level of consciousness in patients with concomitant COVID-19 infection.⁴³

It is important to highlight that most of our patients ($N = 5$, 62.5%) presented with mild to moderate COVID-19 symptoms prior to and at the time of CVST diagnosis. Similar to the conclusions outlined by *Mowla et al.*, our data suggests that the severity of COVID-19 disease presentation may not necessarily be associated with

subsequent CVST events.²⁷ That is, CVST may occur even in patients with relatively indolent or mild COVID-19 infection as determined by the WHO guidelines. Therefore, we recommend that clinicians maintain a high degree of suspicion for CVST development in patients with confirmed COVID-19 infection and otherwise unexplained neurological symptoms.

Although the superior sagittal sinus is the most frequently reported location for CVST, our combined series data suggests that multi-location thrombosis with a transverse sinus predominance is the more typical finding. Furthermore, data from our literature review on CVST-associated prognosis supports observations outlined in the International Study on Cerebral Vein and Dural Sinus Thrombosis (ISCVT).^{44–45} That is, CVSTs in the “deep” venous system (including the vein of Galen, internal cerebral veins, and deep medullary veins) were associated with worse overall prognosis as well as a high degree of mortality.⁴⁶

Of note, intracranial hemorrhage was detected in two of our patients (25%) upon repeat CT brain imaging. This is similar to data reported by *Shakibajrohmi et al.*, who found that 35.1% of patients with CVST developed hemorrhagic lesions.⁴⁷ Thus, CVST should be considered a potential etiology of intracranial and intracerebral hemorrhage in COVID-19 patients. Our patient who developed a subarachnoid hemorrhage after CVST was initially treated with intravenous heparin (5000 U loading dose followed by 800 U/hour continuous infusion) and was then transitioned to dabigatran 150 mg twice daily. The patient who developed parenchymal hemorrhage received Enoxaparin 80 mg every twelve hours.

With regards to management, therapeutic anticoagulation coupled with hydration is the mainstay treatment for CVST in COVID-19 patients, even in the presence of intracranial hemorrhage. As with patients with arterial ischemic stroke, intermittent pneumatic compression devices should also be utilized in patients with CVST for additive thromboprophylaxis if there are no contraindications.⁴⁸ Use of intravenous rtPA and endovascular therapy should be reserved as a last resort for thrombus refractory to therapeutic anticoagulation and in cases of clinical deterioration despite anticoagulation.⁴⁹

Previously reported data by *Siegler et al.* revealed that the incidence of arterial ischemic stroke in COVID-19 patients was 1% (156 / 14,483) but may range up to 1.5%.^{32,50} The incidence of CVST in this same population, however, was observed to be a much lower 0.02% (3 / 14,483). Though this value may seem low, it is 30 to 60 times greater than rates of CVST reported in non-COVID 19 populations — 3 to 4 cases per 1 million adults (0.0003–0.0004%) and 7 cases per 1 million children (0.0007%).⁵¹

Laboratory data such as abnormal coagulation studies as well as elevated inflammatory biomarkers in COVID-19 patients suggest that systemic inflammation and underlying hypercoagulable state may be responsible for acute arterial and/or venous thromboembolic events.

However, these findings alone do not sufficiently explain the discrepancy seen between the aforementioned rates of arterial ischemic stroke versus purely venous infarcts (i.e. CVSTs). We speculate that additional confounding factors such as endothelial dysfunction may be responsible for the overrepresentation of arterial consequences. In fact, while the endothelial dysfunction is pathognomonic for arterial ischemic stroke — that is, an atherosclerotic plaque matures, ruptures, then subsequently undergoes thrombosis — its role in venous thrombogenesis is less clear.⁵² Autopsy studies of patients who succumbed to COVID-19 revealed severe endothelial injury, endotheliitis, and widespread microvascular trauma that likely preceded organ failure.⁵³ Though animal models outlining the pathophysiology of CVST continue to improve, further studies analyzing the relationship between endothelial inflammation and CVST are necessary before drawing any conclusions.⁵⁴

There is a plethora of data regarding the occurrence of deep venous thrombosis (DVT) and pulmonary embolism (PE) among COVID-19 patients; a recent meta-analysis of 66 studies (28,173 patients) revealed that the pooled prevalence of VTE events was 14.1% in non-ICU patients and a staggering 22.7% in ICU patients.⁵⁵ Not only do these rates exceed those of VTE in non-COVID populations (affecting approximately 1 per 1000 annually), but they also dwarf the rates of CVST in similar COVID-19 cohort.^{56,32} CVST may be underreported as its presentation may be manifest as non-specific clinical syndromes: isolated intracranial hypertension (headache, papilledema, visual deficits), encephalopathy (altered mental status, reduced consciousness, coma), and focal neurologic deficits (seizures, paresis, aphasia). Furthermore, whereas bedside ultrasonographic techniques exhibit 77.8% and 90% sensitivity for lower extremity DVT and PE respectively, the diagnosis of CVST requires more radiological investigations such as CTA/CTV or MRI with contrast/MRV.⁵⁷

Limitations of this review stem from the small number of patients analyzed with CVST, a reflection of its rare association with COVID-19. Furthermore, there were missing laboratory data values as consensus on laboratory data was not unified among centers. Nevertheless, we believe that our case series provides valuable information, adding to the literature on a diverse, multinational cohort of patients with COVID-19 infection who also developed CVST.

In summary, clinicians should consider the risk of developing acute CVST in patients with co-existing COVID-19 infection, especially if neurological symptoms develop that are not otherwise explained by other conditions.

Statements

Statement of Ethics: This manuscript is exempt from ethical committee approval due to its retrospective nature and use of de-identified data.

Conflicts of Interest: The authors have no conflicts of interest to declare.

Funding Sources: None

Author Contributions

Shamsh P. Shaikh BS, Mohamad Abdalkader MD, Thanh N. Nguyen MD, James E. Siegler MD, Tudor G. Jovin MD all contributed substantially to the conception or design of the manuscript as well as the acquisition, analysis, and interpretation of data.

Shamsh P. Shaikh BS, Mohamad Abdalkader MD, Thanh N. Nguyen MD drafted the manuscript and revised it critically for important intellectual content.

All additional co-authors were consulted regarding their final approval of the version to be published.

All authors: Agreement to be accountable for all aspects of the work in ensuring that questions related to the accuracy or integrity of any part of the work are appropriately investigated and resolved.

References

1. "COVID-19 Map." Johns Hopkins Coronavirus Resource Center. Johns Hopkins Centers for Civic Impact; 2020 coronavirus.jhu.edu/map.html.
2. Mao L, Jin H, Wang M, Hu Y, Chen S, He Q, Chang J, Hong C, Zhou Y, Wang D, et al. Neurologic manifestations of hospitalized patients with Coronavirus Disease 2019 in Wuhan, China. *JAMA Neurol* 2020.
3. Pleasure SJ, Green AJ, Josephson SA. The spectrum of neurologic disease in the severe acute respiratory syndrome coronavirus 2 pandemic infection. *JAMA Neurol* 2020. <https://doi.org/10.1001/jamaneurol.2020.1065>. Published online April 10, 2020.
4. Bikdeli B, Madhavan MV, Jimenez D, Chuich T, Dreyfus I, Driggin E, et al. COVID-19 and thrombotic or thromboembolic disease: implications for prevention, antithrombotic therapy, and follow-up. *J Am Coll Cardiol* 2020. <https://doi.org/10.1016/j.jacc.2020.04.031>. pii: S0735-1097(20)35008-7. [Epub ahead of print].
5. Song JC, Wang G, Zhang W, Zhang Y, Li WQ, Zhou Z, et al. Chinese expert consensus on diagnosis and treatment of coagulation dysfunction in COVID-19. *Mil Med Res* 2020;7(1):19.
6. Zhai Z, Li C, Chen Y, Gerotziafas G, Zhang Z, Wan J, et al. Prevention and treatment of venous thromboembolism associated with coronavirus disease 2019 infection: a consensus statement before guidelines. *Thromb Haemostasis* 2020. <https://doi.org/10.1055/s-0040-1710019>. [Epub ahead of print].
7. Elkind MSV, Boehme AK, Smith CJ, Meisel A, Buckwalter MS. Infection as a Stroke Risk Factor and Determinant of Outcome After Stroke. *Stroke* 2020;51(10):3156-3168. <https://doi.org/10.1161/STROKEAHA.120.030429>. Epub 2020 Sep 8. PMID: 32897811; PMCID: PMC7530056.
8. Oxley TJ, Mocco J, Majidi S, Kellner CP, Shoirah H, Singh IP, De Leacy RA, Shigematsu T, Ladner TR, Yaeger KA, Skliut M, Weinberger J, Dangayach NS, Bederson JB, Tuhim S, Fifi JT. Large-vessel stroke as a presenting feature of Covid-19 in the young. *N Engl J Med* 2020;382(20):e60.
9. Yaghi S, Ishida K, Torres J, Mac Grory B, Raz E, Humbert K, Henninger N, Trivedi T, Lillemoe K, Alam S, Sanger M, Kim S, Scher E, Dehkharghani S, Wachs M, Tanweer O, Volpicelli F, Bosworth B, Lord A, Frontera J. SARS-CoV-2 and Stroke in a New York Healthcare System. *Stroke* 2020;51(7). <https://doi.org/10.1161/STROKEAHA.120.030335>. Epub 2020 May 20. Erratum in: *Stroke*. 2020 Aug;51(8):e179. PMID: 32432996; PMCID: PMC7258764.
10. Connors JM, Levy JH. COVID-19 and its implications for thrombosis and anticoagulation. *Blood* 2020;135(23):2033-2040.
11. Silvis S, de Sousa D, Ferro J, et al. Cerebral venous thrombosis. *Nat Rev Neurol* 2017;13:555-565. <https://doi.org/10.1038/nrneurol.2017.104>.
12. Klein DE, Libman R, Kirsch C, Arora R. Cerebral venous thrombosis: a typical presentation of COVID-19 in the young. *J Stroke Cerebrovasc Dis* 2020;29(8):104989. <https://doi.org/10.1016/j.jstrokecerebrovasdis.2020.104989>.
13. Nwajei F, Anand P, Abdalkader M, et al. Cerebral Venous Sinus Thromboses in patients with SARS-CoV-2 infection: three cases and a review of the literature. *J Stroke Cerebrovasc Dis* 2020;29(12):105412. <https://doi.org/10.1016/j.jstrokecerebrovasdis.2020.105412>.
14. Cavalcanti DD, Raz E, Shapiro M, et al. Cerebral venous thrombosis associated with COVID-19 [published online ahead of print, 2020 Jun 18]. *AJNR Am J Neuroradiol* 2020. <https://doi.org/10.3174/ajnr.A6644>. 10.3174/ajnr.A6644.
15. Poillon G, Obadia M, Perrin M, Savatovsky J, Leder A. Cerebral venous thrombosis associated with COVID-19 infection: Causality or coincidence? [published online ahead of print, 2020 May 11]. *J Neuroradiol* 2020. <https://doi.org/10.1016/j.neurad.2020.05.003>. S0150-9861(20)30167-X.
16. Sugiyama Y, Tsuchiya T, Tanaka R, et al. Cerebral venous thrombosis in COVID-19-associated coagulopathy: A case report. *J Clin Neurosci* 2020;79:30-32. <https://doi.org/10.1016/j.jocn.2020.07.038>.
17. Hoelscher C, Sweid A, Ghosh R, Al Saiagh F, Keppetipola KM, Farrell CJ, Jallo J, Jabbour P, Tjoumakaris S, Gooch MR, Rosenwasser RH, Shah SO. Cerebral deep venous thrombosis and COVID-19: case report. *J Neurosurg* 2020:1-4. <https://doi.org/10.3171/2020.5.JNS201542>. Epub ahead of print. PMID: 32886922.
18. Hughes C, Nichols T, Pike M, Subbe C, Elghenzai S. Cerebral venous sinus thrombosis as a presentation of COVID-19. *Eur J Case Rep Intern Med* 2020;7(5):001691. https://doi.org/10.12890/2020_001691. Published 2020 Apr 29.
19. Dahl-Cruz F, Guevara-Dalrymple N, López-Hernández N. Trombosis venosa cerebral e infección por SARS-CoV-2 [Cerebral venous thrombosis and SARS-CoV-2 infection]. *Rev Neurol* 2020;70(10):391-392. <https://doi.org/10.33588/rn.7010.2020204>.
20. Bolaji P, Kukoyi B, Ahmad N, Wharton C. Extensive cerebral venous sinus thrombosis: a potential complication in a patient with COVID-19 disease. *BMJ Case Rep* 2020;13(8):e236820. <https://doi.org/10.1136/bcr-2020-236820>. Published 2020 Aug 11.
21. Hemsian H, Ansari B. First case of Covid-19 presented with cerebral venous thrombosis: a rare and dreaded case. *Rev Neurol (Paris)* 2020;176(6):521-523. <https://doi.org/10.1016/j.neurol.2020.04.013>.
22. Chougar L, Mathon B, Weiss N, Degos V, Shor N. Atypical deep cerebral vein thrombosis with hemorrhagic venous infarction in a patient positive for COVID-19. *AJNR Am J Neuroradiol* 2020;41(8):1377-1379. <https://doi.org/10.3174/ajnr.A6642>. Epub 2020 Jun 18. PMID: 32554423.

23. Garaci F, Di Giuliano F, Picchi E, Da Ros V, Floris R. Venous cerebral thrombosis in COVID-19 patient. *J Neurol Sci* 2020;414:116871. <https://doi.org/10.1016/j.jns.2020.116871>.
24. Essajee F, Solomons R, Goussard P, Van Toorn R. Child with tuberculous meningitis and COVID-19 coinfection complicated by extensive cerebral sinus venous thrombosis. *BMJ Case Rep* 2020;13(9):e238597. <https://doi.org/10.1136/bcr-2020-238597>. Published 2020 Sep 14.
25. Aghayari Sheikh Neshin S, Basirjafari S, Saberi A, Shahhosseini B, Zarei M. Liver abnormality may develop cerebral vein thrombosis in COVID-19. *J Neurol Sci* 2020;417:117076. <https://doi.org/10.1016/j.jns.2020.117076>.
26. Mowla A, Shakibajahromi B, Shahjouei S, Borhani-Haghighi A, Rahimian N, Baharvahdat H, Naderi S, Khorvash F, Altafi D, Ebrahimzadeh SA, Farahmand G, Vaghefi Far A, Sharma VK, Neshin S, Tsvigoulis G, Zand R. Cerebral venous sinus thrombosis associated with SARS-CoV-2; a multinational case series. *J Neurol Sci* 2020;419:117183. <https://doi.org/10.1016/j.jns.2020.117183>. Advance online publication.
27. Dakay K, Cooper J, Bloomfield J, Overby P, Mayer SA, Nuoman R, Sahni R, Gulko E, Kaur G, Santarelli J, Gandhi CD, Al-Mufti F. Cerebral Venous Sinus Thrombosis in COVID-19 infection: a case series and review of the literature. *J Stroke Cerebrovasc Dis* 2021;30(1):105434. <https://doi.org/10.1016/j.jstrokecerebrovasdis.2020.105434>. ISSN 1052-3057.
28. Hussain S, Vattoth S, Haroon KH, Muhammad A. A Case of Coronavirus Disease 2019 presenting with seizures secondary to cerebral venous sinus thrombosis. *Case Rep Neurol* 2020;12:260-265. <https://doi.org/10.1159/000509505>.
29. Khacha A, Bouchal S, Ettabyaoui A, Haloua M, Lamrani YA, Boubbou M, Belahsen F, Maâroufi M, Alami B. Cavernous sinus thrombosis in a COVID-19 patient: a case report. *Radiol Case Rep* 2021;16(3):480-482. <https://doi.org/10.1016/j.radcr.2020.12.013>. Epub 2020 Dec 9. PMID: 33318774; PMCID: PMC7723769.
30. Tu TM, Goh C, Tan YK, Leow AS, Pang YZ, Chien J, Shafi H, Chan BP, Hui A, Koh J, Tan BY, Umapathi NT, Yeo LL. Cerebral venous thrombosis in patients with COVID-19 infection: a case series and systematic review. *J Stroke Cerebrovasc Dis* 2020;29(12):105379. <https://doi.org/10.1016/j.jstrokecerebrovasdis.2020.105379>. Epub 2020 Oct 6. PMID: 33254369; PMCID: PMC7538072.
31. Ortega-Gutierrez S, Holcombe A, Aksan N, Dai B, Shaban A, Lazarre L, Zheng-Lin B, Sager L, Dandapat S, Siddiqui FM, Mohr NM. Association of admission clinical predictors and functional outcome in patients with Cerebral Venous and Dural Sinus Thrombosis. *Clin Neurol Neurosurg* 2020;188:105563.
32. Siegler JE, Cardona P, Arenillas JF, Talavera B, Guillen AN, Chavarría-Miranda A, de Lera M, Khandelwal P, Bach I, Patel P, et al. Cerebrovascular events and outcomes in hospitalized patients with COVID-19: the SVIN COVID-19 multinational registry. *Int J Stroke* 2020. 1747493020959216. PMID: 32852257.
33. Organization WH. World Health Organization; 2020. Clinical Management of COVID-19: Interim Guidance. 2020.
34. Coutinho JM, Ferro JM, Canhao P, Barinagarrementeria F, Cantu C, Bousser MG, et al. Cerebral venous and sinus thrombosis in women. *Stroke* 2009;40(7):2356-2361.
35. Saposnik G, Barinagarrementeria F, Brown Jr. RD, Bushnell CD, Cucchiara B, Cushman M. Diagnosis and management of cerebral venous thrombosis: a statement for healthcare professionals from the American Heart Association/American Stroke Association. *Stroke* 2011;42(4):1158-1192.
36. Nasr DM, Brinjikji W, Cloft HJ, Saposnik G, Rabinstein AA. Mortality in cerebral venous thrombosis: results from the national inpatient sample database. *Cerebrovasc. Dis.* 2013;35:40-44. <https://doi.org/10.1159/000343653>.
37. Borhani Haghighi A, Edgell RC, Cruz-Flores S, Feen E, Piriyaawat P, Vora N, Callison RC, Alsheklee A. Mortality of cerebral venous-sinus thrombosis in a large national sample. *Stroke* 2012;43(1):262-264. <https://doi.org/10.1161/STROKEAHA.111.635664>. Epub 2011 Oct 13. PMID: 21998058.
38. Dentali F, Crowther M, Ageno W. Thrombophilic abnormalities, oral contraceptives, and risk of cerebral vein thrombosis: a meta-analysis. *Blood* 2006;107(7):2766-2773. <https://doi.org/10.1182/blood-2005-09-3578>.
39. Zhang ZL, Hou YL, Li DT, Li FZ. Laboratory findings of COVID-19: a systematic review and meta-analysis. *Scand J Clin Lab Invest* 2020;80(6):441-447. <https://doi.org/10.1080/00365513.2020.1768587>. Epub 2020 May 23. PMID: 32449374; PMCID: PMC7256350.
40. Huang I, Pranata R, Lim MA, Oehadian A, Alisjahbana B. C-reactive protein, procalcitonin, D-dimer, and ferritin in severe coronavirus disease-2019: a meta-analysis. *Ther Adv Respir Dis* 2020;14:1753466620937175. <https://doi.org/10.1177/1753466620937175>. PMID: 32615866; PMCID: PMC7336828.
41. Spiezia L, Boscolo A, Poletto F, Cerruti L, Tiberio I, Campello E. COVID-19-related severe hypercoagulability in patients admitted to intensive care unit for acute respiratory failure. *Thromb Haemost* 2020.
42. Lodigiani C, Iapichino G, Carenzo L, Cecconi M, Ferrazzi P, Sebastian T. Venous and arterial thromboembolic complications in COVID-19 patients admitted to an academic hospital in Milan, Italy. *Thromb Res* 2020;191:9-14.
43. Divani AA, Andalib S, Di Napoli M, et al. Coronavirus Disease 2019 and stroke: clinical manifestations and pathophysiological insights. *J Stroke Cerebrovasc Dis* 2020;29(8):104941. <https://doi.org/10.1016/j.jstrokecerebrovasdis.2020.104941>.
44. Canhão P, Ferro JM, Lindgren AG, et al. Causes and predictors of death in cerebral venous thrombosis. *Stroke* 2005;36(8):1720-1725. <https://doi.org/10.1161/01.STR.0000173152.84438.1c>.
45. Girot M, Ferro JM, Canhão P, et al. Predictors of outcome in patients with cerebral venous thrombosis and intracerebral hemorrhage. *Stroke* 2007;38(2):337-342. <https://doi.org/10.1161/01.STR.0000254579.16319.35>.
46. Ferro JM, Canhão P, Stam J, Bousser MG, Barinagarrementeria F, ISCVT Investigators. Prognosis of cerebral vein and dural sinus thrombosis: results of the International Study on Cerebral Vein and Dural Sinus Thrombosis (ISCVT). *Stroke* 2004;35(3):664-670. <https://doi.org/10.1161/01.STR.0000117571.76197.26>. Epub 2004 Feb 19. PMID: 14976332.
47. Shakibajahromi B, Borhani-Haghighi A, Ghaedian M, Feiz F, Molavi Vardanjani H, Safari A, et al. Early, delayed, and expanded intracranial hemorrhage in cerebral venous thrombosis. *Acta Neurol Scand.* 2019;140:435-442.
48. Ma A, Kase CS, Shoemanesh A, Abdalkader M, Pikula A, Sathya A, Catanese L, Ellis AT, Nguyen TN. Stroke and Thromboprophylaxis in the Era of COVID-19. *J Stroke Cerebrovasc Dis* 2020;30(1):105392. PMID: 33130478.
49. Eskey CJ, Meyers PM, Nguyen TN, Ansari SA, Jayaraman M, McDougall CG, DeMarco JK, Gray WA, Hess

- DC, Higashida RT, et al. Indications for the performance of intracranial endovascular neurointerventional procedures: a scientific statement from the American Heart Association. *Circulation* 2018;137(21):e661-e689. 05 22PMID: 29674324.
50. Nogueira R, Abdalkader M, Qureshi MM, Frankel MR, Mansour OY, Yamagami H, Qiu Z, Farhoudi M, Siegler JE, Yaghi S, et al. Global impact of the COVID-19 pandemic on stroke hospitalizations and mechanical thrombectomy volumes. *Int J Stroke* 2021;1747493021991652. <https://doi.org/10.1177/1747493021991652>. Epub ahead of print. PMID: 33459583.
51. Stam J. Thrombosis of the cerebral veins and sinuses. *N Engl J Med* 2005;352(17):1791-1798. <https://doi.org/10.1056/NEJMr042354>. PMID: 15858188.
52. Rumbaut RE, Thiagarajan P. Platelet-Vessel Wall Interactions in Hemostasis and Thrombosis. San Rafael (CA): Morgan & Claypool Life Sciences; 2010. Chapter 6, Arterial, Venous, and Microvascular Hemostasis/Thrombosis Available from: <https://www.ncbi.nlm.nih.gov/books/NBK53453/>.
53. Varga Z, Flammer AJ, Steiger P, et al. Endothelial cell infection and endotheliitis in COVID-19. *Lancet* 2020;395 (10234):1417-1418. [https://doi.org/10.1016/S0140-6736\(20\)30937-5](https://doi.org/10.1016/S0140-6736(20)30937-5).
54. Yenigün M, Jünemann M, Gerriets T, Stolz E. Sinus thrombosis-do animal models really cover the clinical syndrome? *Ann Transl Med* 2015;3(10):138. <https://doi.org/10.3978/j.issn.2305-5839.2015.05.14>.
55. Nopp S, Moik F, Jilma B, Pabinger I, Ay C. Risk of venous thromboembolism in patients with COVID-19: A systematic review and meta-analysis. *Res Pract Thromb Haemost* 2020;4(7):1178-1191. <https://doi.org/10.1002/rth2.12439>. Epub ahead of print. PMID: 33043231; PMCID: PMC7537137.
56. Cushman M. Epidemiology and risk factors for venous thrombosis. *Semin Hematol* 2007;44(2):62-69. <https://doi.org/10.1053/j.seminhematol.2007.02.004>.
57. Needleman L, Cronan JJ, Lilly MP, Merli GJ, Adhikari S, Hertzberg BS, DeJong MR, Streiff MB, Meissner MH. Ultrasound for lower extremity deep venous thrombosis: multi-disciplinary recommendations from the society of radiologists in ultrasound consensus conference. *Circulation* 2018;137(14):1505-1515. <https://doi.org/10.1161/CIRCULATIONAHA.117.030687>. PMID: 29610129.