

Bestrophinopathies: perspectives on clinical disease, Bestrophin-1 function and developing therapies

Simranjeet Singh Grewal , Joseph J. Smith and Amanda-Jayne F. Carr 

Ther Adv Ophthalmol

2021, Vol. 13: 1–16

DOI: 10.1177/
2515841421997191

© The Author(s), 2021.
Article reuse guidelines:
[sagepub.com/journals-](https://sagepub.com/journals-permissions)
permissions

Abstract: Bestrophinopathies are a group of clinically distinct inherited retinal dystrophies that typically affect the macular region, an area synonymous with central high acuity vision. This spectrum of disorders is caused by mutations in bestrophin1 (*BEST1*), a protein thought to act as a Ca²⁺-activated Cl⁻ channel in the retinal pigment epithelium (RPE) of the eye. Although bestrophinopathies are rare, over 250 individual pathological mutations have been identified in the *BEST1* gene, with many reported to have various clinical expressivity and incomplete penetrance. With no current clinical treatments available for patients with bestrophinopathies, understanding the role of *BEST1* in cells and the pathological pathways underlying disease has become a priority. Induced pluripotent stem cell (iPSC) technology is helping to uncover disease mechanisms and develop treatments for RPE diseases, like bestrophinopathies. Here, we provide a comprehensive review of the pathophysiology of bestrophinopathies and highlight how patient-derived iPSC-RPE are being used to test new genomic therapies in vitro.

Keywords: *BEST1*, bestrophinopathies, CRISPR, gene editing, gene therapy, induced pluripotent stem cells

Received: 18 January 2021; revised manuscript accepted: 27 January 2021.

Introduction

Pathogenic mutations in *BEST1* are known to cause a number of distinct autosomal dominant dystrophies including Best disease, Adult vitelliform macular degeneration (AVMD), autosomal dominant vitreoretinopathy (ADVIRC) and the recessive disease, autosomal recessive bestrophinopathy (ARB).^{1,2} This spectrum of diseases, collectively known as bestrophinopathies, affect the macular region, with patients typically presenting in clinic within the first two decades of life. The prevalence of individual bestrophinopathies is rare and varied, however, in a recent study of 3000 patient families with inherited disease, *BEST1* was the 5th most mutated gene, accounting for 3.9% of affected families, and one of the highest causes of autosomal dominant macular dystrophy.³ Bestrophinopathies primarily affect the retinal pigment epithelium (RPE), a monolayer of cells that interacts with and sustains the light responsive retina. In the RPE, *BEST1* is

normally expressed on the basolateral membrane, where it acts as an ion channel.^{4–6} Dysfunction of RPE with age or as a result of inherited mutations, can lead to degeneration of the retina. Over the last 30 years, research has focused on investigating the biological function of *BEST1* in the RPE and the mechanisms by which *BEST1* mutations contribute to retinal disease. These advances have led to a better understanding of disease mechanisms and development of potential therapies to treat the unmet clinical needs for bestrophinopathies.

Clinical spectrum of bestrophinopathies

Best disease

Best disease is the most common bestrophinopathy, with an estimated prevalence ranging from 1:5,000 to 1:67,000 and an onset that usually occurs during childhood or early adulthood.^{7,8}

Correspondence to:
Amanda-Jayne F. Carr
UCL Institute of
Ophthalmology, University
College London, 11-43
Bath Street, London EC1V
9EL, UK.
a.carr@ucl.ac.uk
Simranjeet Singh Grewal
Joseph J. Smith
UCL Institute of
Ophthalmology, University
College London, London,
UK

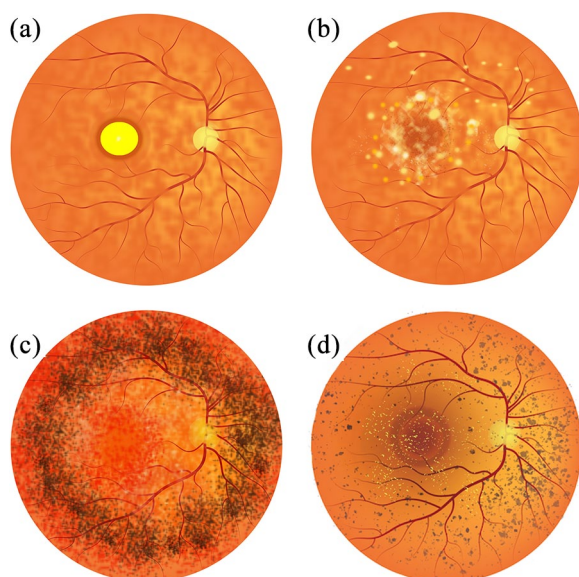


Figure 1. Representative illustrations of Bestrophinopathy fundus appearance. (a) Best disease, with the egg yolk-like vitelliform lesion observed at the macula. (b) Autosomal recessive bestrophinopathy, characterised by multifocal deposits and lesions around and beyond the macula. (c) Autosomal dominant vitreoretinchoroidopathy typified by presence of a hyperpigmented circumferential band of pigmentation in the peripheral retina. (d) Best-related retinitis pigmentosa characterised by the presence of peripheral pigment changes, bone spicules and foveal deposits.

The disease was first described in 1883 as a peculiar change in the macula⁹ and later identified in a large German family, by Dr Friedrich Best, who noted its dominant inheritance pattern.¹⁰ Best disease is characterised by the presence of vitelliform lesions that evolve over time, and progress through a number of stages, which may or may not follow chronologically for each patient. During the initial previtelliform stage, the fundus appearance and visual acuity (VA) are normal; however, there may be subtle changes of the RPE, appearing on the central retina as yellowish pigment changes, with some granularity defects.^{2,11} Best disease is most easily identified during the vitelliform stage, where a yellow demarcated ‘egg-yolk’ vitelliform lesion, 2–3 mm in diameter, is observed on the macula (Figure 1(a)). At the vitelliform stage there may be mild vision loss and a decrease in VA, although VA has been reported to be normal in some patients.^{2,11} Patients may also report photophobia, metamorphosis and night blindness at this stage.^{7,12}

Over time, the demarcated borders and yellow appearance of the vitelliform lesion can become more irregular and a partial resorption of fluid may lead to the appearance of a pseudohypopyon, where various inflammatory cells infiltrate the anterior chamber. Despite the dramatic appearance of a pseudohypopyon, VA may only be mildly affected.^{2,11} The disease can then progress to a vitelliruptive stage, where breakdown of the vitelliform lesion leads to a ‘scrambled-egg’ fundus appearance, with irregular yellow deposits present. At this stage, VA may be steady or may begin to decline as the disease progresses.^{2,13} Best disease can then progress to an atrophic stage, resulting in death of the RPE and loss of photoreceptor cells. Hyperpigmented fibrous scar tissue can be present in the macula, leading to widespread geographic atrophy, synonymous with progressive and irreversible retinal cell loss.¹¹

During the atrophic stage VA can decline dramatically (from 6/12 to 6/60 or less) and loss is irreversible. The breakdown of the RPE barrier can also lead to choroid neovascularisation (CNV). The presence of newly created, weak blood vessels, prone to rupturing, can lead to subretinal bleeds, fluid accumulation and a sudden decrease in VA.¹⁴ Complications due to CNV have been reported to occur in 2%–9% of Best disease patients.⁷ Best disease is generally bilateral, with lesions displaying some relative symmetry, but cases of unilateral Best disease have also been described.¹⁵

For the most part, vision loss is gradual with 75% of affected individuals retaining a VA of 6/12 or better into their fifties in at least one eye;¹³ however, the presence of CNV can lead to a steep decline in VA. Patients can also present with hyperopia, astigmatism¹⁶ and anterior segment abnormalities, such as shallow anterior chambers, putting them in the risk group for having a narrow anterior angle and suffering from acute angle closure glaucoma (AACG). Best disease can also be multifocal, with numerous vitelliform lesions varying in size clustered around the macula.¹⁷ Patients can also be prone to subretinal haemorrhages, the formation of macular holes, and retinal detachment in response to modest trauma.^{7,18}

Adult vitelliform macular degeneration

Adult vitelliform macular degeneration is a dominantly inherited bestrophinopathy. AVMD typically has an onset of between 30 and 50 years of

age, with more females seeming to be affected.¹² AVMD patients present with vitelliform lesions (similar to Figure 1(a)) that can be smaller than those observed in Best disease patients. Generally, AVMD has a less dramatic effect on vision and patients may not progress through all the stages described for Best disease, however, although CNV is rare, atrophy can occur⁷ with complications, such as CNV or pigment epithelial detachment.^{19,20} In general, AVMD is clinically indistinguishable from Best disease and has been described as a milder form of Best disease, owing to its later onset and slower progression. The resemblance between the two conditions has led to the suggestion that AVMD should be reclassified as Best disease.^{2,7}

Autosomal recessive bestrophinopathy

ARB is an autosomal recessive disease resulting from bi-allelic homozygous or compound heterozygous mutations within the *BEST1* locus. Parents of ARB patients generally have normal vision, suggesting a tolerance of *BEST1* haploinsufficiency.^{7,21} ARB is estimated to have a prevalence of 1:1,000,000, with an onset range between 4 and 40 years of age, although a juvenile onset is typical.^{7,22} ARB presents distinctively, with an alteration in the RPE leading to the formation of multiple subretinal deposit at the macula and midperipheral retina²¹ (Figure 1(b)). The distinctive vitelliform macular lesions seen in Best disease are rare but may be present in some ARB patients at late stage.²³ The fundus of patients with ARB has a speckled appearance with multiple yellow/white, round, demarcated, and partially confluent lesions located towards the fovea and the vascular arcades, at the posterior pole and around the optic nerve.^{21,24} ARB also appears to affect the periphery, indicated by presence of peripheral drusen and RPE atrophy.²³

Patients also typically present with accumulation of subretinal fluid, culminating in some patients having cystoid macular edema with retinal fibrosis.^{7,22,25,26} Some developmental anomalies may also be present in ARB, and patients may be hyperopic and have shallow anterior chambers, increasing their risk of AACG.^{7,21} Vision loss is slow and progressive,²³ but in some cases central vision may eventually stabilise; however, complications such as CNV and AACG can lead to a rapid deterioration of vision.^{7,21,24,27}

Autosomal dominant vitreoretinopathy

ADVIRC follows a dominant mode of inheritance and seems to differ from the other bestrophinopathies as it does not present with distinctive lesions of the macula. Instead, ADVIRC patients present with a strongly demarcated 360-degree circumferential hyperpigmented band in the peripheral retina, from the equator to the ora serrata^{28,29} (Figure 1(c)). ADVIRC is a very rare condition with a prevalence of 1;1,000,000, with only five *BEST1* mutations currently known to cause the disease.^{28,30} The typical age of onset is during early childhood, with the hyperpigmented band generally seen in early stage patients. For older patients, the hyperpigmented band is considered a hallmark for ADVIRC; however, a recent reports have described its absence in some patients, indicating a high phenotypic variability.^{2,31,32}

During early stage disease, ADVIRC affects the peripheral retina, with very little change in the appearance of the central retina. As ADVIRC progresses, it can encroach onto the macular region, causing central vision loss.³³ VA can range from 6/6, to absence of light perception in some cases; however, the majority of patients are able to maintain good vision of at least 6/12 throughout life.^{31,33,34} Patients can also present with punctate white retinal opacities, a pale optic disc and attenuated and narrow blood vessels.^{33,34} Further complications include retinal neovascularisation (leading to retinal bleeding and macula edema), retinal fibrosis, atrophy of the underlying choroid, retinal detachment and vitreous haemorrhage.^{7,28,33,35} Interestingly, ADVIRC patients may also have a wide range of eye development issues, including: microcornea, nanophthalmos, discrete rotatory nystagmus, hyperopia, presenile cataracts, iris dysgenesis, optic nerve dysplasia and a shallow anterior chamber leading to risk of AACG.^{7,28,33–35} These findings suggest that bestrophinopathy mutations may also contribute to broader ocular defects. Microcornea, rod-cone dystrophy and staphyloma (MRCS), a disease linked to *BEST1* mutations, shares many ADVIRC-associated clinical features and the phenotype could be on the spectrum of ADVIRC disease expressivity.^{28,36}

Retinitis pigmentosa

A number of patients have also been diagnosed with a bestrophinopathy-related form of retinitis pigmentosa,³⁷ classified by dense pigmentary

changes in the peripheral retina. This can be accompanied by retinal gliosis, vascular attenuation, peripheral bone spicules, pale optic discs, yellow and foveal deposits and macular edema (Figure 1(d)), leading to patients typically having vision loss and night blindness. However, these may represent misdiagnosed cases of ADVIRC or ARB.^{1,2,38} Targeted next-generation sequencing has retrospectively diagnosed cases of bestrophinopathy-related RP as ADVIRC, despite patients lacking the hallmark ADVIRC hyperpigmented circumferential band on clinical presentation.³² Alternatively, *BEST1*-related RP may be the result of multigenic mutations.^{39,40}

Diagnosis of bestrophinopathies

Although the clinically distinct features of the bestrophinopathies may be sufficient for diagnosis, a number of additional tests can be used for confirmation. The electrooculogram (EOG) measures the standing potential, the electrical difference between the front and the back of the eye, and is used to assess the potential across the RPE, an indicator of its health.⁴¹ The EOG measures the potential during exposure to the dark and following exposure to light, to calculate a light peak (LP): dark trough ratio, termed the Arden ratio.⁴¹ According to the International Society for Clinical Electrophysiology of Vision (<https://iscev.wildapricot.org/standards>), a standard Arden ratio is between 1.7 and 4.3; this typically decreases below 1.5 in patients with bestrophinopathies.^{21,23,28,33,35,41} However, in some patients, the Arden ratio may be normal or only slightly reduced,^{11,12,33,42} this has been observed in 8% of Best disease cases,³¹ highlighting the need for genetic testing to correctly distinguish and diagnose a bestrophinopathy. The electroretinogram (ERG) is typically found to be normal in patients, although delayed cone and rod response may be observed in ADVIRC patients^{28,31,34} and full-field, pattern and multifocal ERG's can be affected in ARB patients.^{2,24,27,43}

Disease progression can be monitored using optical coherence tomography (OCT), measuring foveal thickness, retinal degeneration and RPE atrophy, and the presence of retinal edema or subretinal fluid.^{7,16,23,35} Fluorescein angiography and fundus autofluorescence, can also be used to examine blood vessel structure and accumulation of lipofuscin respectively in patients.⁷ Hyperfluorescence is observed during early stage Best disease, but can decline as the disease progresses. In ADVIRC

patients, autofluorescence appears normal in the central retina, but is often blocked in the periphery by the characteristic peripheral hyperpigmented ring.³⁴ Patchy areas of hyperautofluorescence, corresponding to fluid accumulation and small confluent lesions, are typically observed in ARB patients.²¹ CNV, a serious complication in bestrophinopathy, can be confirmed using OCT and fluorescein angiography. Despite these modern imaging techniques, genetic testing is generally used to confirm clinically suspected bestrophinopathy and identify novel *BEST1* mutations.^{1,21,28,35,44}

Clinical management of bestrophinopathies

There are currently no treatments for the bestrophinopathies; however, complications experienced as a result of disease, can be managed. One common complication is neovascularisation, which, although problematic, has been treated using photodynamic therapy (with the use of verteporfin),⁴⁵ photocoagulation or through anti-vascular endothelial growth factor (VEGF) injections, such as Avastin or Bevacizumab.^{7,46} Interestingly, sufficient VA can be retained in some Best disease patients displaying CNV without any treatment.¹⁴ Complications such as macula edema have been treated using oral acetazolamide with a nepafenac suspension³⁹ (p. 129), while vitrectomy surgery has been used to repair macular holes.¹⁸ In patients at risk of AACG, monitoring intra-ocular pressure and irido-corneal angle with gonioscopy is recommended. Intraocular pressure can be used to assess the development of glaucoma, which can be controlled with topical drops or treated with prophylactic yttrium aluminium garnet (YAG)-laser iridotomy.³⁵ Bestrophinopathy patients are at risk of subretinal haemorrhages, they may therefore be advised to avoid contact sport and wear safety glasses at times to circumvent this complication.⁴⁷

Bestrophin-1

Bestrophinopathies are caused by mutations in the Bestrophin-1 (*BEST1*) gene, which maps to a 16 kB region of chromosome 11 (11q13), where it spans 11 exons, producing a 1758 bp transcript expressed exclusively in the RPE, of the adult eye.^{7,48–50} *BEST1* is also expressed in extra-ocular tissues including the trachea, lung, kidney, sperm, colon, and testes, and within astrocytes, neurons, and epithelia of the central nervous system.^{7,51–53} In addition *BEST1* is also expressed in the retina

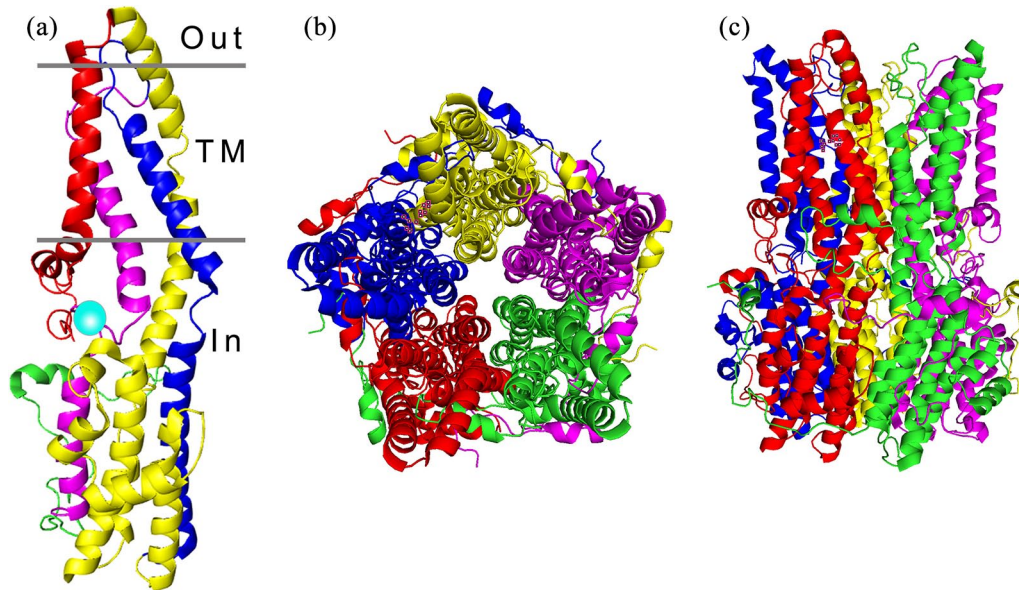


Figure 2. Architecture of the *BEST1* channel. (a) The structure of a *BEST1* protein unit is divided into four segments, composed of alpha helices represented as S1a-c (red), S2a-h (yellow), S3a-b (blue) and S4a-b (magenta), the transmembrane regions (TM) are indicated. The calcium clasp is represented by a turquoise sphere and the start of the C-terminal tail is coloured green. (b) The *BEST1* channel, viewed from the extracellular side, is formed from five *BEST1* proteins arranged in a pentameric structure, forming a barrel shaped ion pore (c).

during foetal development.⁵⁴ *BEST1* is a member of the Bestrophin family, an ancient group of membrane proteins, and has been identified in most metazoan organisms.⁵⁵ The coding region, which starts in the second exon, encodes a 68 kD protein, consisting of 585 amino acids⁴ with a highly conserved intracellular N-terminal domain containing 4 transmembrane spanning domains and a long diverse cytosolic C-terminal domain tail.^{56–59} Chicken and bacterial proteins have been used to analyse the crystal structure of *BEST1*, revealing a homo-pentameric organisation comprised of five *BEST1* protomers^{58,59} arranged around a central axis to produce a barrel-shaped pore (Figure 2). The channel protrudes just outside the cell membrane, with the majority of the protein located in the cytosol. In the pentameric structure, Ca^{2+} clasp within each protomer come together as a belt around the central section of the channel, forming a hydrophobic neck, which is dilated by the binding of cytosolic calcium, allowing the flux of Cl^- ions.^{58,59} Over 250 distinct pathogenic *BEST1* mutations have been discovered thus far,^{48,60} these are thought to affect channel formation, channel function, or protein/channel localisation (Figure 3).

The retinal pigment epithelium

Bestrophinopathies primarily affect the RPE, a monolayer of pigmented cells that lies between the neural retina and the choriocapillaris, directly below the cone and rod photoreceptors. RPE cells form tight connections with each other acting as a physical barrier between the retina and the underlying choroid and forming an essential component of the blood-retinal barrier.⁶¹ The RPE apical membrane is scattered with microvilli, which project between the outer segments of the photoreceptors. Despite its simple structure, the RPE performs a number of crucial roles that are needed for photoreceptors to detect light and keep the retina healthy (Figure 4). Disruption in these functions can lead to retinal degeneration and loss of vision.

The RPE is involved in the phagocytosis and degradation of photoreceptor outer segments (POS). The removal and processing of POS waste prevents the build-up of photo-oxidative by-products, and is crucial for RPE and photoreceptor cell health.⁶² Furthermore, essential substances contained within the POS, such as retinal, can be recycled by the RPE, as part of the visual cycle,

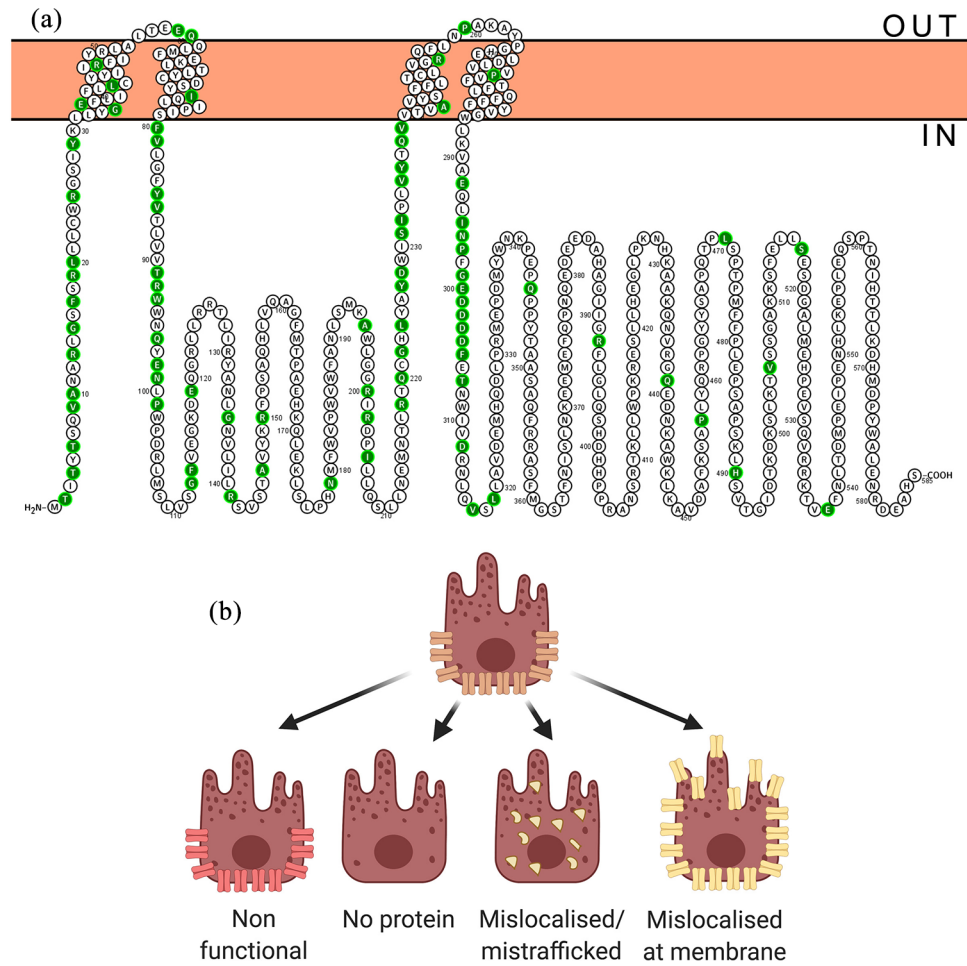


Figure 3. *BEST1* disease causing mutations. (a) Annotated *BEST1* protein sequence with ClinVar benign/likely benign mutations indicated in green. (b) Potential effects of mutation on *BEST1* channel.

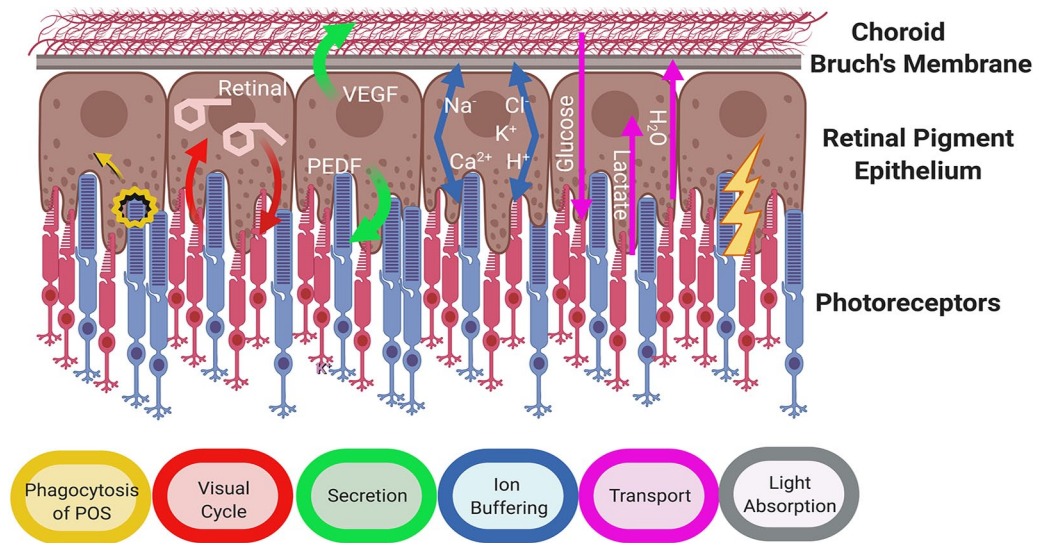


Figure 4. Crucial roles of retinal pigment epithelium (Adapted from Strauss, 2005⁶¹).

and returned to photoreceptor cells to enable phototransduction.⁶¹ The RPE is a highly active phagocytic monolayer, engulfing and ingesting around 25,000 outer segment discs per day, with each RPE cell in the macular fovea phagocytosing around 20 POS daily.⁶³ Changes in cell pH, Ca²⁺ and ion balance can impact on RPE phagocytosis of POS and affect lysosomal function,^{61,64} therefore disruption of cell homeostasis can affect the removal of waste, resulting in the build-up of toxic debris within and around cells, ultimately leading to cell atrophy.⁶⁵

The RPE maintains a healthy retinal environment and structural integrity by secreting signalling molecules, growth factors, neuroprotective factors and immunosuppressive factors, for example, pigment epithelium-derived factor (PEDF) and VEGF, allowing the RPE to communicate with other tissues.⁶¹ As a crucial component of the blood: retina barrier the RPE is involved in the transepithelial transport of molecules between the retina and the choroid⁶¹ and maintaining the ionic homeostasis of the subretinal environment, transporting water and metabolites (e.g. glucose and lactate), controlling pH and removing waste products. The RPE regulates the buffering of ions in the subretinal space in response to the fast paced, light responsive activity of photoreceptors, maintaining ionic balance and pH. To do this, cells express a number of key pumps, transporter and ion channels at the apical and basal surfaces, including ligand-gated/voltage-gated/Ca²⁺-activated potassium channels, Na⁺/K⁺-ATPase, voltage-dependent/ligand-gated Ca²⁺ channels, volume-regulated anion channels and Ca²⁺-activated chloride channels.⁶⁶

Role of BEST1

Bestrophinopathies are classed as channelopathies, due to the effects of mutations on the conductance of currents through the cell membrane. *BEST1* was first identified as a chloride channel in 2002 after overexpression of exogenous *BEST1* in HEK293 cells induced chloride currents that were calcium sensitive.⁶⁷ Similarly, studies in human foetal RPE suggest it is an Ca²⁺ responsive channel, which is required to maintain the RPE transepithelial potential.⁶⁸ In addition, structural studies support the hypothesis that *BEST1* is a Ca²⁺-dependent Cl⁻ channel, controlling the flux of Cl⁻ ions in cells.^{58,59} However, *BEST1* may be involved in a number of processes within epithelial cells. *BEST1* interacts with the CaV1.3 α 1D and CaV β subunits of L-type voltage-dependent

calcium channels,^{69,70} participating in intracellular Ca²⁺ signalling and potentially contributing to the generation of the LP.⁷⁰⁻⁷² *BEST1* may also regulate intracellular Ca²⁺, by modulating the release of Ca²⁺ from endoplasmic reticulum stores, this hypothesis is aided by the finding that some protein can localise away from the membrane.^{71,73,74} There is also evidence to suggest that *BEST1* can act directly as a volume-regulated anion channel, regulating cell volume and homeostasis in RPE cells,⁷⁵ a role which would be essential for maintaining cell homeostasis.

Although *BEST1* is primarily thought to be a Cl⁻ channel, it is highly permeable to other molecules, such as HCO₃⁻,⁷⁶ glutamate⁷⁷ and gamma aminobutyric acid (GABA),⁷⁸ implying that the channel could potentially serve as a pH sensor/regulator and be involved in neurotransmitter release. In addition, the presence of developmental ocular defects, for example, microcornea and nanophthalmos, in some bestrophinopathy patients, suggests that *BEST1* may play a role in normal eye development.^{16,35} Although protein is only observed in the adult RPE, *BEST1* is expressed in human retinal cells during early development.⁵⁴ Given that eye development is reliant on correct spatial signalling from neighbouring cells, the expression of mutant *BEST1* outside the RPE may affect cell: cell interactions, interfering with normal ocular developmental pathways.^{79,80}

It is widely accepted that the *BEST1* channel is activated by the binding of Ca²⁺, however the protein also contains an ATP binding motif, which may be important in modulating channel function. The binding of ATP can modulate channel activity, resulting in increased currents in the presence of Ca²⁺. This response is disrupted in iPSC-RPE cells from patients with a mutation in the binding motif, suggesting a relevance to physiological *BEST1* function in human cells.⁷² ATP is the primary candidate for the substance released during the light peak in electrophysiological recordings, such as the EOG test. The EOG is the defining diagnostic test for bestrophinopathies, with patients generally recording a decrease in the recorded light peak: dark trough ratio. The light peak reflects the increased conductance of Cl⁻ across the RPE basolateral membrane. This is thought to occur in response to an unknown 'light peak substance' (LPS), released by photoreceptors after exposure to light, which binds to a receptor on the RPE cells, initiating a cascade that results in depolarisation of the RPE

basolateral membrane. Previously, ATP was thought to increase intracellular calcium through purinergic receptors, driving the conductance of chloride Cl^- across the basal membrane.⁸¹ However, the direct interaction of ATP with *BEST1* within the RPE provides another means to drive depolarisation in response to light.

Model systems for bestrophinopathies

A number of animal models have been used to investigate *BEST1* in RPE cells, including rats, mice, and dogs. The rat model of Best disease, created by overexpressing mutated forms of *BEST1*, localises the protein in the RPE basolateral membrane and displays electrophysiological findings typical of human disease, yet no ocular disease phenotype was observed.⁸² Similarly in a *BEST1*^{-/-} knock out mouse model,^{5,83} although a reduced light peak, reminiscent of Best disease, was observed, no ocular phenotypes were reported. Knock-in mice expressing mutant forms of *BEST1* may represent better rodent models as the reduced electrophysiological responses are also accompanied by lipid accumulation, and retinal detachments.^{11,84} There may be a limit to how much rodent models can contribute to our knowledge of bestrophinopathies as these animals do not possess a macula and therefore might not develop the equivalent retinal lesions seen in human macular diseases.⁸⁵

Although dogs do not have a macula, there is a region in the retina called the area centralis, populated with a higher density of cones and free from large blood vessels. Within this region is a foveal-like region, susceptible to a canine form of recessive bestrophinopathy,⁸⁶ termed canine multifocal retinopathy (CMR). CMR affects a number of canine breeds and is caused by mutations in *cBEST1*, making the dog a naturally occurring animal model of bestrophinopathy.^{87,88} In these animals, the area centralis is affected by vitelliform lesions typical of Best disease, with focal detachment between the RPE and the neural retina also noted⁸⁹ or, more typically, multiple retinal lesions, reminiscent of ARB.^{21,90} The CMR model is aiding current knowledge of disease progression through lesions, pseudohypopyon and atrophy stages. Loss of RPE apical microvilli leading to microdetachment of the retina is thought to be the earliest features of CMR, indicating an RPE-photoreceptor disease interface for bestrophinopathy.^{91,92}

Much of the early work examining *BEST1* in human cells involved overexpression of the protein in the kidney epithelial cell lines, HEK-293 or MDCKII.^{67,93} Yet, RPE cells have a unique polarisation signature, independent of E-Cadherin, where sorting of proteins to the apical and basolateral membrane for example, Na^+/K^+ ATPase and monocarboxylate transporter 1, is reversed compared to other epithelial cells.⁹⁴ Wild type (WT) *BEST1* does not localise to the membrane of HEK-293³⁷ and MDCKII already express endogenous ion channels that could impact on electrophysiological recordings. In addition, overexpression studies in foetal RPE have provided valuable insights into the oligomerisation of *BEST1*, its role as an anion channel and its involvement in regulation of transepithelial resistance.^{68,95} However, the availability of foetal RPE tissue limits its use as a common model system.

The advent of induced pluripotent stem cell (iPSC) technology has transformed the modelling of bestrophinopathies in vitro (Figure 5). Reprogramming of human somatic cells to a state of pluripotency using embryonic transcription factors has enabled researchers to derive RPE from patients skin or blood sample, providing a cell model which contains an individual patients unique genetic makeup.⁹⁶⁻⁹⁸ iPSC-derived RPE have a pigmented, cobblestone-like epithelial morphology, replicate many of the functions of RPE and express *BEST1* in the basolateral membrane, allowing the investigation of inherited ophthalmic disorders within a disease-in-a-cell system.

Disease modelling using iPSC-RPE has replicated many of the features of bestrophinopathies, including reduced channel activity, defects in POS phagocytosis lysosome defects, accumulation of lipofuscin and reduced net fluid transport.^{40,54,99-102} iPSC-RPE studies have also provided more evidence suggesting *BEST1* can function as a voltage gated anion channel,⁵ regulate calcium signalling⁶ and be regulated by ATP.⁷² Cellular studies have identified distinct pathological features that can be used to distinguish between the effects of different mutations¹⁰² and different bestrophinopathies for example, anion transport is increased in ADVIRC cells and decreased in Best disease cells compared to controls.¹⁰⁰ Disease-in-a-dish modelling using iPSC-RPE may yet reveal more about the nature of *BEST1* mutations. However, the power of these

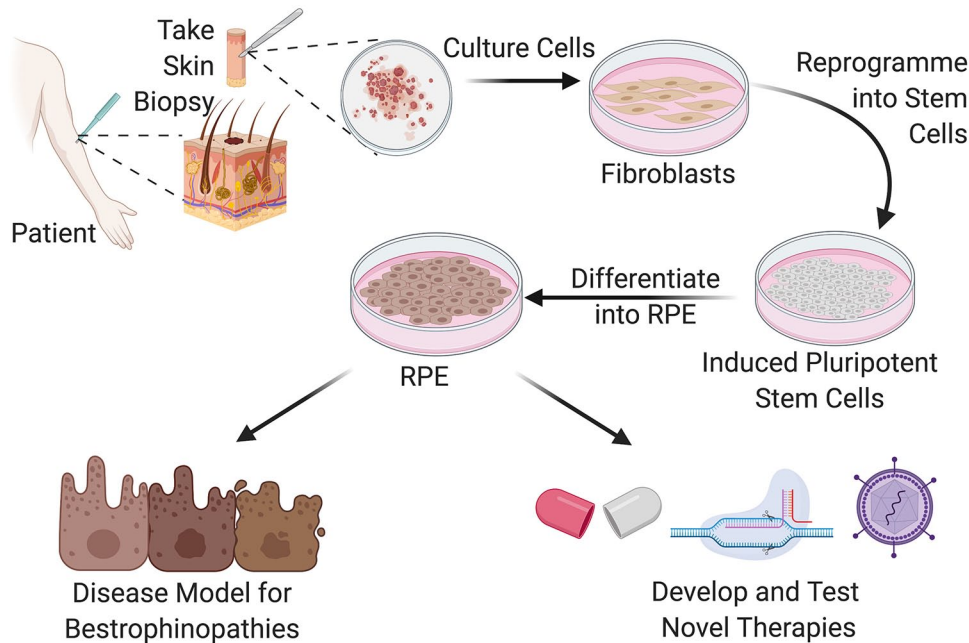


Figure 5. Generation of patient derived iPSC-RPE as a human disease model system for the study of bestrophinopathies and development novel forms of treatments for patients.

cells is the ability to investigate new therapeutics by performing drug/compound screens and developing the next generation of personalised genomic medicines.

Therapies for bestrophinopathies

Ophthalmology has been at the forefront of developing the new era of genomic and regenerative medicine approaches, including gene therapy, CRISPR genome editing, antisense oligonucleotide and stem cell therapies. Rapid clinical advances for retinal degeneration have been enabled by the accessibility and small size (6 mm) of the macula, ocular immune privilege, real-time ocular imaging, visual function testing, and the availability of two eyes in a patient—allowing one to serve as an untreated. Currently there are no curative therapies for bestrophinopathies, therefore research is focusing on developing a number of clinical treatments.

Gene therapy

Gene therapy involves introducing exogenous genetic material, that is, a working copy of the *BEST1* gene, into the cells of a host in an attempt to treat the underlying cause of a disease. This approach is predicted to be optimal in loss of function mutations, where levels of functional

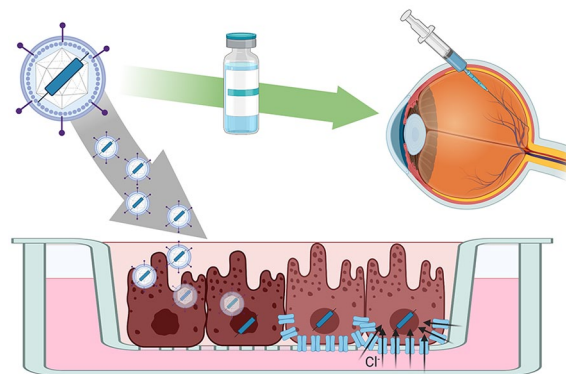


Figure 6. Gene therapy approaches for bestrophinopathies can be tested in patient iPSC-RPE cells in a trial in a dish scenario. This approach could be used as a screen to identify mutations responsive to the treatment prior to clinical application in the patient.

protein are low or absent (Figure 6). A number of research groups have provided proof-of-concept approaches treating bestrophinopathy with a gene augmentation approach. Guziewicz and colleagues, have used subretinal injections of *BEST1* adeno-associated virus (AAV)-mediated augmentation gene therapy to reverse the early retinal microdetachments and lesions seen in canine models of ARB (CMR). Improvements were maintained for at least 23 months and no reports

of retinal toxicity noted up to 6 weeks post-injection. This approach also preserved the cytoarchitecture of the RPE–Photoreceptor interface and normalised the otherwise diseased hyperthick outer nuclear layer, providing proof of principle that gene therapy may be a viable treatment for patients with CMR-like ARB.⁸⁸

iPSC-RPE are also being used to assess the feasibility of *BEST1* gene therapy in human cells (Figure 6). Initial studies, using iPSC-RPE from patients with ARB show that gene therapy delivered using baculovirus rescues the Ca^{2+} -dependent Cl^- channel deficiencies observed in cells from patients with recessive disease.¹⁰³ Surprisingly, supplemental gene therapy may also be a potential treatment for dominant bestrophinopathies. Ji and colleagues examined iPSC-RPE cells derived from six patients with Best disease, where dominant *BEST1* mutations affected the subcellular localisation or function of *BEST1*. Here they found that treatment of patient iPSC-RPE with *BEST1*-AAV restored deficiencies in Ca^{2+} -dependent chloride channel activity, with the viral *BEST1* protein localising to the plasma membrane.¹⁰² Despite these successes and exciting proof-of-concepts for recessive and dominant disease, gene therapy may not be a suitable treatment for all *BEST1* mutations. Gene augmentation using lentiviral *BEST1* was able to restore Ca^{2+} -activated Cl^- channel in activity and phagocytosis of outer segments in 3 of 4 patient lines tested, but one cell line, with the Ala146Lys mutation, did not respond to the treatment. This may be due to dominant effect of the mutated protein on the supplemental WT *BEST1* protein.¹⁰⁴ Although gene therapy for *BEST1* is still in its infancy, early indications in these pre-clinical models suggest it may be a viable option for recessive disease and, in some cases, dominant disease with responsive mutations, highlighting the need for careful screening of potential gene therapy candidates.

Genome editing

Individual mutations within the *BEST1* gene can have different consequences on the protein, affecting its localisation, the formation of the *BEST1* pentameric channel formation or channel function. The interaction of the dominant protein with the supplemental protein may still affect individual patients' responses to gene therapy. In these cases, alternative options need to be investigated. Genome editing provides a therapeutic means to get to the heart of the problem,

changing the mutated DNA sequence or switching off a faulty gene. The CRISPR-Cas9 (Clustered Regularly Interspaced short palindromic repeats with CRISPR associated protein 9) system is currently the most popular, efficient and adaptable method to induce permanent changes in cellular DNA.¹⁰⁵

Initially described as a bacterial defence mechanism to identify and inactivate invading viral DNA, CRISPR-Cas9 is now one of the most promising means to treat inherited diseases (31). CRISPR-Cas9 is an RNA guided endonuclease that can be directed to cut double stranded DNA at a specific site upstream of a short protospacer adjacent motif (PAM). The cut site can be determined by providing a complementary single guide RNA (sgRNA), which directs Cas9 to produce a double-strand break at a precise sequence (Figure 7(a)). At this point the cell activates mechanisms to repair the DNA using either homology directed repair (HDR) or non-homologous end joining (NHEJ), which provides opportunities to edit the gene.¹⁰⁶

Homology-directed repair (HDR) is a critical DNA repair mechanism, commonly active during meiosis, requiring the presence of a homologous DNA for example, a sister chromatid. For genome editing, an sgRNA targeting a mutation site can be introduced into the cell alongside a homologous WT DNA template, which is then incorporated into the gene during the repair, replacing and correcting the mutated DNA region (Figure 7(b)). However due to the practical limitations of HDR, the probability of donor DNA being used as a template in non-dividing somatic cells, like the RPE, is low, therefore HDR repair editing may not be efficient in an RPE cell in situ. An alternative and simpler method of editing uses NHEJ, a common cellular mechanism that joins the two ends of double-stranded DNA breaks back together. This method is highly prone to errors, resulting in indel creation and subsequent transcriptional frameshifts, which lead to degradation of the transcript (Figure 7(c)). NHEJ can therefore be a useful way of switching off a gene in somatic cells, and could be used to target autosomal dominant diseases by directing Cas9 to target specific gene mutation sites on the dominant mutated allele.

Recently, Sinha and colleagues¹⁰⁴ demonstrated the first proof-of-concept approach for gene editing in Best disease using NHEJ, with an average frame shift efficiency of 96%. CRISPR/Cas9

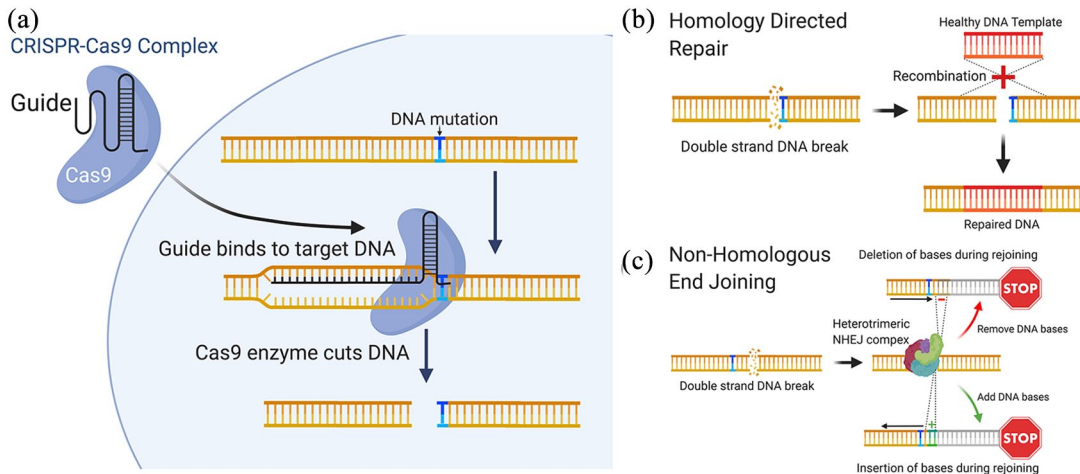


Figure 7. CRISPR genome editing can be used to treat patient mutations at the molecular level. (a) The CRISPR-Cas9 complex is used to create a double strand DNA break in close proximity to the patient. (b) A corrected DNA template can be incorporated into the sequence using homology directed repair, alternatively and (c) non-homologous end joining can be used to create insertions/deletions, resulting in frame-shifts that disrupt the target gene.

treatment of patient derived iPSC-RPE improved *BEST1* channel activity and rhodopsin degradation. However, a major concern was the presence of off-target editing effects, which could affect the expression of other key genes in edited cells. A number of challenges remain before gene editing can be widely used in clinic, including the delivery of the gene editing system to target cells, efficiency of the therapy, utilisation of repair mechanisms in RPE and retinal cells, and prevention of off-target effects.^{107,108}

Pharmacological approaches

Although a great deal of attention is being placed on using genomic medicine to treat inherited diseases, pharmacological approaches may be valid for bestrophinopathies.^{109,110} Singh and colleagues,¹¹¹ investigated whether modulating proteolytic machinery using valproic acid, a histone deacetylase inhibitor, in combination with rapamycin, an inducer of autophagy, could rescue POS processing defects observed in bestrophinopathies. This combinatory treatment increased the rate of POS degradation and reduced the build-up of autofluorescence in patient derived iPSC-RPE, suggesting a link between POS handling and proteolysis in RPE. Furthermore, this treatment also delayed disease progression in a canine model of ARB.

Recent interest has also turned to the use of molecular chaperones and proteasome inhibitors

as therapeutics for bestrophinopathies. The proteasome inhibitor, bortezomib and chemical chaperone, 4-phenylbutyrate (4PBA) have been used in combination to guide correct trafficking of exogenous mutant *BEST1* to the plasma membrane in MDCKII cells. This combination can also rescue channel activity defects in HEK293 cells expressing inducible forms of mutant *BEST1*. Similarly, 4PBA and its analogue, 2-naphthoxyacetic acid, were able to increase *BEST1* protein expression in iPSC-RPE from Best disease and ARB patients and restore channel function in HEK293 cells expressing mutated forms of *BEST1*.¹¹²

Conclusion

Bestrophinopathies are distinct retinal dystrophies with varying clinical heterogeneity and penetrance that typically lead to central vision loss at an early age and have a huge impact on the daily lives of patients. The gene responsible for these diseases, *BEST1*, is a highly conserved anion channel, yet there are few animal models available to fully understand its role in the development of disease, and although *BEST1* expression is widespread throughout the body, it is still unclear why *BEST1* mutations manifest in vision loss only. Patient derived iPSC-RPE are a crucial disease-in-a-dish model system that have enabled a greater understanding of *BEST1* function and its role in human disease. These cells will be important in revealing the role of individual mutations in the development of distinct bestrophinopathies

and could help to interrogate the heterogeneity of disease, by identifying potential genetic modifiers of disease in families. In the future, iPSC may also help gain valuable insight into the importance of the RPE: retinal interface in bestrophinopathies, through the culture of retinal organoids. The importance of iPSC-RPE can be fully appreciated in their use to develop and test potential genomic therapies for bestrophinopathies. Current research suggests that, although there may not be a common approach to treat all bestrophinopathies, a range of options could be available for patients in the future, providing permanent treatments for these inherited diseases.

Conflict of interest statement

The authors declared no potential conflicts of interest with respect to the research, authorship, and/or publication of this article.

Funding

The author(s) disclosed receipt of the following financial support for the research, authorship, and/or publication of this article: The authors gratefully acknowledge funding the Macular Society, the Uren Foundation and the London Project to Cure Blindness.

ORCID iDs

Simranjeet Singh Grewal  <https://orcid.org/0000-0002-5461-0790>

Amanda-Jayne F. Carr  <https://orcid.org/0000-0002-5469-0030>

References

- Shah M, Shah M, Broadgate S, *et al.* Association of clinical and genetic heterogeneity with BEST1 sequence variations. *JAMA Ophthalmol* 2020; 138: 544–551.
- Leroy BP. Bestrophinopathies. In: Traboulsi EI (ed.) *Genetic diseases of the eye*. 2nd ed. Oxford: Oxford University Press, 2012, pp. 426–436.
- Pontikos N, Arno G, Jurkute N, *et al.* Genetic basis of inherited retinal disease in a molecularly characterized cohort of more than 3000 families from the United Kingdom. *Ophthalmology* 2020; 127: 1384–1394.
- Marmorstein AD, Marmorstein LY, Rayborn M, *et al.* Bestrophin, the product of the Best vitelliform macular dystrophy gene (VMD2), localizes to the basolateral plasma membrane of the retinal pigment epithelium. *Proc Natl Acad Sci USA* 2000; 97: 12758–12763.
- Milenkovic A, Brandl C, Milenkovic VM, *et al.* Bestrophin 1 is indispensable for volume regulation in human retinal pigment epithelium cells. *Proc Natl Acad Sci USA* 2015; 112: E2630–E2639.
- Singh R, Shen W, Kuai D, *et al.* IPS cell modeling of best disease: insights into the pathophysiology of an inherited macular degeneration. *Hum Mol Genet* 2013; 22: 593–607.
- Boon CJF, Klevering BJ, Leroy BP, *et al.* The spectrum of ocular phenotypes caused by mutations in the BEST1 gene. *Prog Retin Eye Res* 2009; 28: 187–205.
- Mullins RF, Oh KT, Heffron E, *et al.* Late development of vitelliform lesions and flecks in a patient with best disease: clinicopathologic correlation. *Arch Ophthalmol* 2005; 123: 1588–1594.
- Adams JE. Case showing peculiar changes in the macula. *Trans Ophthalmol Soc UK* 1883; 3: 113–114.
- Best F. Ueber eine hereditäre Maculaaffektion: Beiträge zur Vererbungslehre. *Z Augenheilkd* 1905; 13: 199–212.
- Marmorstein AD, Cross HE and Peachey NS. Functional roles of bestrophins in ocular epithelia. *Prog Retin Eye Res* 2009; 28: 206–226.
- Renner AB, Tillack H, Kraus H, *et al.* Morphology and functional characteristics in adult vitelliform macular dystrophy. *Retina* 2004; 24: 929–939.
- Fishman GA, Baca W, Alexander KR, *et al.* Visual acuity in patients with best vitelliform macular dystrophy. *Ophthalmology* 1993; 100: 1665–1670.
- Chung MM, Oh KT, Streb LM, *et al.* Visual outcome following subretinal hemorrhage in best disease. *Retina* 2001; 21: 575–580.
- Arora R, Khan K, Kasilian ML, *et al.* Unilateral BEST1-associated retinopathy. *Am J Ophthalmol* 2016; 169: 24–32.
- Wittstrom E, Ekvall S, Schatz P, *et al.* Morphological and functional changes in multifocal vitelliform retinopathy and biallelic mutations in BEST1. *Ophthalmic Genet* 2011; 32: 83–96.
- Lacassagne E, Dhuez A, Rigaudière F, *et al.* Phenotypic variability in a French family with a novel mutation in the BEST1 gene causing multifocal best vitelliform macular dystrophy. *Mol Vis* 2011; 17: 309–322.
- Liu J, Xuan Y, Zhang Y, *et al.* Bilateral macular holes and a new onset vitelliform lesion in Best disease. *Ophthalmic Genet* 2017; 38: 79–82.

19. Krämer F, White K, Pauleikhoff D, *et al.* Mutations in the VMD2 gene are associated with juvenile-onset vitelliform macular dystrophy (Best disease) and adult vitelliform macular dystrophy but not age-related macular degeneration. *Eur J Hum Genet* 2000; 8: 286–292.
20. Battaglia Parodi M, Di Crecchio L and Ravalico G. Vascularized pigment epithelial detachment in adult-onset foveomacular vitelliform dystrophy. *Eur J Ophthalmol* 2000; 10: 266–269.
21. Burgess R, Millar ID, Leroy BP, *et al.* Biallelic mutation of BEST1 causes a distinct retinopathy in humans. *Am J Hum Genet* 2008; 82: 19–31.
22. Sheng X, Chen X, Zhao K, *et al.* A novel homozygous BEST1 mutation correlates with complex ocular phenotypes. *Ophthalmology* 2013; 120: 1511–1512.
23. Casalino G, Khan KN, Armengol M, *et al.* Autosomal recessive bestrophinopathy: clinical features, natural history, and genetic findings in preparation for clinical trials. *Ophthalmology*. Epub ahead of print 8 October 2020. DOI: 10.1016/j.ophtha.2020.10.006.
24. Gerth C, Zawadzki RJ, Werner JS, *et al.* Detailed analysis of retinal function and morphology in a patient with autosomal recessive bestrophinopathy (ARB). *Doc Ophthalmol* 2009; 118: 239–246.
25. MacDonald IM, Gudiseva HV, Villanueva A, *et al.* Phenotype and genotype of patients with autosomal recessive bestrophinopathy. *Ophthalmic Genet* 2012; 33: 123–129.
26. Sharon D, Al-Hamdani S, Engelsberg K, *et al.* Ocular phenotype analysis of a family with biallelic mutations in the BEST1 gene. *Am J Ophthalmol* 2014; 157: 697–709.
27. McMurray RJ, Gadegaard N, Tsimbouri PM, *et al.* Nanoscale surfaces for the long-term maintenance of mesenchymal stem cell phenotype and multipotency. *Nat Mater* 2011; 10: 637–644.
28. Yardley J, Leroy BP, Hart-Holden N, *et al.* Mutations of VMD2 splicing regulators cause nanophthalmos and autosomal dominant vitreoretinopathopathy (ADVIRC). *Invest Ophthalmol Vis Sci* 2004; 45: 3683–3689.
29. Kellner U, Jandek C, Kraus H, *et al.* Autosomal dominant vitreoretinopathopathy with normal electrooculogram in a German family. *Graefes Arch Clin Exp Ophthalmol* 1998; 236: 109–114.
30. Chen CJ, Kaufman S, Packo K, *et al.* Long-term macular changes in the first proband of autosomal dominant vitreoretinopathopathy (ADVIRC) due to a newly identified mutation in BEST1. *Ophthalmic Genet* 2016; 37: 102–108.
31. Pasquay C, Wang LF, Lorenz B, *et al.* Bestrophin 1 – phenotypes and functional aspects in bestrophinopathies. *Ophthalmic Genet* 2015; 36: 193–212.
32. Boulanger-Scemama E, Sahel JA, Mohand-Said S, *et al.* AUTOSOMAL DOMINANT VITREORETINOPATHY: when molecular genetic testing helps clinical diagnosis. *Retina* 2019; 39: 867–878.
33. Lafaut BA, Loeys B, Leroy BP, *et al.* Clinical and electrophysiological findings in autosomal dominant vitreoretinopathopathy: report of a new pedigree. *Graefes Arch Clin Exp Ophthalmol* 2001; 239: 575–582.
34. Vincent A, McAlister C, Vandenhoven C, *et al.* BEST1-related autosomal dominant vitreoretinopathopathy: a degenerative disease with a range of developmental ocular anomalies. *Eye* 2011; 25: 113–118.
35. Burgess R, MacLaren RE, Davidson AE, *et al.* ADVIRC is caused by distinct mutations in BEST1 that alter pre-mRNA splicing. *J Med Genet* 2009; 46: 620–625.
36. Reddy MA, Francis PJ, Berry V, *et al.* A clinical and molecular genetic study of a rare dominantly inherited syndrome (MRC5) comprising of microcornea, rod-cone dystrophy, cataract, and posterior staphyloma. *Br J Ophthalmol* 2003; 87: 197–202.
37. Davidson AE, Millar ID, Urquhart JE, *et al.* Missense mutations in a retinal pigment epithelium protein, Bestrophin-1, cause retinitis pigmentosa. *Am J Hum Genet* 2009; 85: 581–592.
38. Brodsky MC, Schimmenti L and Iezzi R. The Best retinitis pigmentosa masquerade. *Ophthalmology* 2019; 126: 1694.
39. Dalvin LA, Abou Chehade JE, Chiang J, *et al.* Retinitis pigmentosa associated with a mutation in BEST1. *Am J Ophthalmol Case Rep* 2016; 2: 11–17.
40. Johnson AA, Guziewicz KE, Lee CJ, *et al.* Bestrophin 1 and retinal disease. *Prog Retin Eye Res* 2017; 58: 45–69.
41. Constable PA, Bach M, Frishman LJ, *et al.* ISCEV standard for clinical electro-oculography (2017 update). *Doc Ophthalmol* 2017; 134: 1–9.
42. Testa F, Rossi S, Passerini I, *et al.* A normal electro-oculography in a family affected by best disease with a novel spontaneous mutation of the BEST1 gene. *Br J Ophthalmol* 2008; 92: 1467–1470.
43. Pomares E, Burés-Jelstrup A, Ruiz-Nogales S, *et al.* Nonsense-mediated decay as the molecular

- cause for autosomal recessive bestrophinopathy in two unrelated families. *Invest Ophthalmol Vis Sci* 2012; 53: 532–537.
44. Nguyen TT, Poornachandra B, Verma A, *et al.* Next generation sequencing identifies novel disease-associated BEST1 mutations in bestrophinopathy patients. *Sci Rep* 2018; 8: 10176.
 45. Andrade RE, Farah ME and Costa RA. Photodynamic therapy with verteporfin for subfoveal choroidal neovascularization in best disease. *Am J Ophthalmol* 2003; 136: 1179–1181.
 46. Hussain RN, Shahid FL, Empeslidis T, *et al.* Use of intravitreal bevacizumab in a 9-year-old child with choroidal neovascularization associated with autosomal recessive bestrophinopathy. *Ophthalmic Genet* 2015; 36: 265–269.
 47. Chowers I, Zamir E, Banin E, *et al.* Blunt trauma in Best's vitelliform macular dystrophy. *Br J Ophthalmol* 2000; 84: 1330–1331.
 48. Petrukhin K, Koisti MJ, Bakall B, *et al.* Identification of the gene responsible for Best macular dystrophy. *Nat Genet* 1998; 19: 241–247.
 49. Stone EM, Nichols BE, Streb LM, *et al.* Genetic linkage of vitelliform macular degeneration (Best's disease) to chromosome 11q13. *Nat Genet* 1992; 1: 246–250.
 50. Marquardt A, Stöhr H, Passmore LA, *et al.* Mutations in a novel gene, VMD2, encoding a protein of unknown properties cause juvenile-onset vitelliform macular dystrophy (Best's disease). *Hum Mol Genet* 1998; 7: 1517–1525.
 51. Oh SJ, Woo J, Lee YS, *et al.* Direct interaction with 14-3-3 γ promotes surface expression of Best1 channel in astrocyte. *Mol Brain* 2017; 10: 1–12.
 52. Soria RB, Spitzner M, Schreiber R, *et al.* Bestrophin-1 enables Ca²⁺-activated Cl⁻ conductance in epithelia. *J Biol Chem* 2009; 284: 29405–29412.
 53. Milenkovic A, Schmied D, Tanimoto N, *et al.* The Y227N mutation affects bestrophin-1 protein stability and impairs sperm function in a mouse model of Best vitelliform macular dystrophy. *Biol Open* 2019; 8: bio041335.
 54. Carter DA, Smart MJK, Letton WVG, *et al.* Mislocalisation of BEST1 in iPSC-derived retinal pigment epithelial cells from a family with autosomal dominant vitreoretinopathopathy (ADVIRC). *Sci Rep* 2016; 6: 33792.
 55. Milenkovic VM, Langmann T, Schreiber R, *et al.* Molecular evolution and functional divergence of the bestrophin protein family. *BMC Evol Biol* 2008; 8: 1–10.
 56. Milenkovic VM, Rivera A, Horling F, *et al.* Insertion and topology of normal and mutant bestrophin-1 in the endoplasmic reticulum membrane. *J Biol Chem* 2007; 282: 1313–1321.
 57. Tsunenari T, Sun H, Williams J, *et al.* Structure-function analysis of the bestrophin family of anion channels. *J Biol Chem* 2003; 278: 41114–41125.
 58. Kane Dickson V, Pedi L and Long SB. Structure and insights into the function of a Ca²⁺-activated Cl⁻ channel. *Nature* 2014; 516: 213–218.
 59. Yang T, Liu Q, Kloss B, *et al.* Structure and selectivity in bestrophin ion channels. *Science* 2014; 346: 355–359.
 60. Smith JJ, Nommiste B and Carr AJF. Bestrophin1: a gene that causes many diseases. *Adv Exp Med Biol* 2019; 1185: 419–423.
 61. Strauss O. The retinal pigment epithelium in visual function. *Physiol Rev* 2005; 85: 845–881.
 62. Kevany BM and Palczewski K. Phagocytosis of retinal rod and cone photoreceptors. *Physiology* 2010; 25: 8–15.
 63. Hartzell C. Looking chloride channels straight in the eye: bestrophins, lipofuscinosis, and retinal degeneration. *Physiology* 2005; 20: 292–302.
 64. Reichhart N and Strauß O. Ion channels and transporters of the retinal pigment epithelium. *Exp Eye Res* 2014; 126: 27–37.
 65. Strick DJ and Vollrath D. Focus on molecules: MERTK. *Exp Eye Res* 2010; 91: 786–787.
 66. Wimmers S, Karl MO and Strauss O. Ion channels in the RPE. *Prog Retin Eye Res* 2007; 26: 263–301.
 67. Sun H, Tsunenari T, Yau K-W, *et al.* The vitelliform macular dystrophy protein defines a new family of chloride channels. *Proc Natl Acad Sci USA* 2002; 99: 4008–4013.
 68. Marmorstein AD, Kinnick TR, Stanton JB, *et al.* Bestrophin-1 influences transepithelial electrical properties and Ca²⁺ signaling in human retinal pigment epithelium. *Mol Vis* 2015; 21: 347–359.
 69. Strauss O, Milenkovic V, Striessnig J, *et al.* Direct interaction of Bestrophin-1 and beta-subunits of voltage-dependent calcium channels. *Investig Ophthalmol Vis Sci* 2008; 49: 5182.
 70. Wu J, Marmorstein AD, Striessnig J, *et al.* Voltage-dependent calcium channel CaV1.3 subunits regulate the light peak of the

- electroretinogram. *J Neurophysiol* 2007; 97: 3731–3735.
71. Rosenthal R, Bakall B, Kinnick T, *et al.* Expression of bestrophin-1, the product of the VMD2 gene, modulates voltage-dependent Ca^{2+} channels in retinal pigment epithelial cells. *FASEB J* 2006; 20: 178–180.
 72. Zhang Y, Kittredge A, Ward N, *et al.* ATP activates bestrophin ion channels through direct interaction. *Nat Commun* 2018; 9: 3126.
 73. Strauß O, Müller C, Reichhart N, *et al.* The role of bestrophin-1 in intracellular Ca^{2+} signaling. *Adv Exp Med Biol* 2014; 801: 113–119.
 74. Gómez NM, Tamm ER and Strauß O. Role of bestrophin-1 in store-operated calcium entry in retinal pigment epithelium. *Pflugers Arch* 2013; 465: 481–495.
 75. Fischmeister R and Hartzell HC. Volume sensitivity of the bestrophin family of chloride channels. *J Physiol* 2005; 562: 477–491.
 76. Qu Z and Hartzell HC. Bestrophin Cl^- channels are highly permeable to HCO_3^- . *Am J Physiol Cell Physiol* 2008; 294: C1371–C1377.
 77. Woo DH, Han K-SS, Shim JW, *et al.* TREK-1 and Best1 channels mediate fast and slow glutamate release in astrocytes upon GPCR activation. *Cell* 2012; 151: 25–40.
 78. Lee S, Yoon BE, Berglund K, *et al.* Channel-mediated tonic GABA release from glia. *Science* 2010; 330: 790–796.
 79. Nguyen M and Arnheiter H. Signaling and transcriptional regulation in early mammalian eye development: a link between FGF and MITF. *Development* 2000; 127: 3581–3591.
 80. Carricondo PC, Andrade T, Prasov L, *et al.* Nanophthalmos: a review of the clinical spectrum and genetics. *J Ophthalmol* 2018; 2018: 2735465.
 81. Peterson WM, Meggyesy C, Yu K, *et al.* Extracellular ATP activates calcium signaling, ion, and fluid transport in retinal pigment epithelium. *J Neurosci* 1997; 17: 2324–2337.
 82. Marmorstein AD, Stanton JB, Yocom J, *et al.* A model of best vitelliform macular dystrophy in rats. *Invest Ophthalmol Vis Sci* 2004; 45: 3733–3739.
 83. Marmorstein LY, Wu J, McLaughlin P, *et al.* The light peak of the electroretinogram is dependent on voltage-gated calcium channels and antagonized by Bestrophin (Best-1). *J Gen Physiol* 2006; 127: 577–589.
 84. Zhang Y, Stanton JB, Wu J, *et al.* Suppression of Ca^{2+} signaling in a mouse model of Best disease. *Hum Mol Genet* 2010; 19: 1108–1118.
 85. Huber G, Heynen S, Imsand C, *et al.* Novel rodent models for macular research. *PLoS ONE* 2010; 5: e13403.
 86. Beltran WA, Cideciyan AV, Guziewicz KE, *et al.* Canine retina has a primate fovea-like bouquet of cone photoreceptors which is affected by inherited macular degenerations. *PLoS ONE* 2014; 9: e90390.
 87. Zangerl B, Wickström K, Slavik J, *et al.* Assessment of canine BEST1 variations identifies new mutations and establishes an independent bestrophinopathy model (cmr3). *Mol Vis* 2010; 16: 2791–2804.
 88. Guziewicz KE, Cideciyan AV, Beltran WA, *et al.* BEST1 gene therapy corrects a diffuse retina-wide microdetachment modulated by light exposure. *Proc Natl Acad Sci USA* 2018; 115: E2839–E2848.
 89. Guziewicz KE, Zangerl B, Lindauer SJ, *et al.* Bestrophin gene mutations cause canine multifocal retinopathy: a novel animal model for best disease. *Invest Ophthalmol Vis Sci* 2007; 48: 1959–1967.
 90. Guziewicz KE, Slavik J, Lindauer SJP, *et al.* Molecular consequences of BEST1 gene mutations in canine multifocal retinopathy predict functional implications for human bestrophinopathies. *Investig Ophthalmol Vis Sci* 2011; 52: 4497–4505.
 91. Guziewicz KE, Sinha D, Gómez NM, *et al.* Bestrophinopathy: an RPE-photoreceptor interface disease. *Prog Retin Eye Res* 2017; 58: 70–88.
 92. Guziewicz KE, McTish E, Dufour VL, *et al.* Underdeveloped RPE apical domain underlies lesion formation in canine bestrophinopathies. *Adv Exp Med Biol* 2018; 1074: 309–315.
 93. Johnson AA, Lee Y-S, Chadburn AJ, *et al.* Disease-causing mutations associated with four bestrophinopathies exhibit disparate effects on the localization, but not the oligomerization, of Bestrophin-1. *Exp Eye Res* 2014; 121: 74–85.
 94. Marmorstein AD. The polarity of the retinal pigment epithelium. *Traffic* 2001; 2: 867–872.
 95. Johnson AA, Lee YS, Brett Stanton J, *et al.* Differential effects of best disease causing missense mutations on bestrophin-1 trafficking. *Hum Mol Genet* 2013; 22: 4688–4697.
 96. Carr A-JF, Vugler AA, Hikita S, *et al.* Protective effects of human iPS-derived retinal pigment epithelium cell transplantation in the retinal dystrophic rat. *PLoS ONE* 2009; 4: e8152.

97. Brandl C, Zimmermann SJ, Milenkovic VM, *et al.* In-depth characterisation of retinal pigment epithelium (RPE) cells derived from human induced pluripotent stem cells (hiPSC). *NeuroMol Med* 2014; 16: 551–564.
98. Carter DA, Nommiste B, Coffey PJ, *et al.* Spontaneous generation of patient-specific retinal pigment epithelial cells using induced pluripotent stem cell technology. In: Davidson Negraes P and Ulrich H (eds) *Working with stem cells*. Cham: Springer, 2016, pp. 143–162.
99. Marmorstein AD, Johnson AA, Bachman LA, *et al.* Mutant Best1 expression and impaired phagocytosis in an iPSC model of autosomal recessive bestrophinopathy. *Sci Rep* 2018; 8: 4487.
100. Nachtigal AL, Milenkovic A, Brandl C, *et al.* Mutation-dependent pathomechanisms determine the phenotype in the bestrophinopathies. *Int J Mol Sci* 2020; 21: 1597.
101. Moshfegh Y, Velez G, Li Y, *et al.* BESTROPHIN1 mutations cause defective chloride conductance in patient stem cell-derived RPE. *Hum Mol Genet* 2016; 25: 2672–2680.
102. Ji C, Li Y, Kittredge A, *et al.* Investigation and restoration of BEST1 activity in patient-derived RPEs with dominant mutations. *Sci Rep* 2019; 9: 19026.
103. Li Y, Zhang Y, Xu Y, *et al.* Patient-specific mutations impair BESTROPHIN1's essential role in mediating Ca²⁺-dependent Cl⁻ currents in human RPE. *Elife* 2017; 6: 1–23.
104. Sinha D, Steyer B, Shahi PK, *et al.* Human iPSC modeling reveals mutation-specific responses to gene therapy in a genotypically diverse dominant maculopathy. *Am J Hum Genet* 2020; 107: 278–292.
105. Jinek M, Chylinski K, Fonfara I, *et al.* A programmable dual-RNA-guided DNA endonuclease in adaptive bacterial immunity. *Science* 2012; 337: 816–821.
106. Ryu SM, Hur JW and Kim K. Evolution of CRISPR towards accurate and efficient mammal genome engineering. *BMB Rep* 2019; 52: 475–481.
107. Lino CA, Harper JC, Carney JP, *et al.* Delivering CRISPR: a review of the challenges and approaches. *Drug Deliv* 2018; 25: 1234–1257.
108. Zhang XH, Tee LY, Wang XG, *et al.* Off-target effects in CRISPR/Cas9-mediated genome engineering. *Mol Ther Nucleic Acids* 2015; 4: e264.
109. Yang T, Justus S, Li Y, *et al.* BEST1: the best target for gene and cell therapies. *Mol Ther* 2015; 23: 1805–1809.
110. Uggenti C, Briant K, Streit AK, *et al.* Restoration of mutant bestrophin-1 expression, localisation and function in a polarised epithelial cell model. *Dis Model Mech* 2016; 9: 1317–1328.
111. Singh R, Kuai D, Guziewicz KE, *et al.* Pharmacological modulation of photoreceptor outer segment degradation in a human iPSC cell model of inherited macular degeneration. *Mol Ther* 2015; 23: 1700–1711.
112. Liu J, Taylor RL, Baines RA, *et al.* Small molecules restore Bestrophin 1 expression and function of both dominant and recessive bestrophinopathies in patient-derived retinal pigment epithelium. *Investig Ophthalmol Vis Sci* 2020; 61: 28.