

## Extracorporeal membrane oxygenation for coronavirus disease 2019-associated acute respiratory distress syndrome: Report of two cases and review of the literature

Jun-Lin Wen, Qi-Zhe Sun, Zhou Cheng, Xiao-Zu Liao, Li-Qiang Wang, Yong Yuan, Jian-Wei Li, Liu-Sheng Hou, Wen-Jun Gao, Wei-Jia Wang, Wei-Yan Soh, Bin-Fei Li, Da-Qing Ma

**ORCID number:** Jun-Lin Wen 0000-0001-5013-0901; Qi-Zhe Sun 0000-0002-3023-7127; Zhou Cheng 0000-0003-4441-2544; Xiao-Zu Liao 0000-0002-5727-901X; Li-Qiang Wang 0000-0003-4974-0571; Yong Yuan 0000-0002-1845-7506; Jian-Wei Li 0000-0003-4756-6848; Liu-Sheng Hou 0000-0002-5899-3645; Wen-Jun Gao 0000-0002-7920-393X; Wei-Jia Wang 0000-0003-0173-6733; Wei-Yan Soh 0000-0002-1206-9174; Bin-Fei Li 0000-0003-4755-314X; Da-Qing Ma 0000-0003-1235-0537.

**Author contributions:** Wen JL collected and interpreted the data; Sun QZ drafted the manuscript; Li BF and Yuan Y supervised and coordinated management of the patients; Cheng Z, Liao XZ, and Wang LQ were in charge of the ECMO application and management; Li JW, Gao WJ, Hou LS, and Wang WJ directed the administration of drugs; Li BF, Cheng Z, Liao XZ, Wang LQ, and Yuan Y contributed to design of the study; Ma DQ and Soh WY edited the report for important intellectual content; Li BF is the guarantor of this report; all authors read and approved the final manuscript.

**Supported by** Zhongshan City Social Welfare Project, No.

**Jun-Lin Wen, Zhou Cheng, Xiao-Zu Liao, Li-Qiang Wang, Bin-Fei Li**, Department of Anaesthesiology, Zhongshan People's Hospital, Zhongshan 528403, Guangdong Province, China

**Qi-Zhe Sun, Da-Qing Ma**, Department of Surgery and Cancer, Imperial College London, London SW10 9NH, United Kingdom

**Yong Yuan, Liu-Sheng Hou**, Cardiovascular Centre, Zhongshan People's Hospital, Zhongshan 528403, Guangdong Province, China

**Jian-Wei Li**, Department of Intensive Medicine, Zhongshan People's Hospital, Zhongshan 528403, Guangdong Province, China

**Wen-Jun Gao**, Department of Hepatology, The Second People's Hospital of Zhongshan, Zhongshan 528447, Guangdong Province, China

**Wei-Jia Wang**, Laboratory Diagnosis Centre, Zhongshan People's Hospital, Zhongshan 528403, Guangdong Province, China

**Wei-Yan Soh**, Faculty of Medicine, Ewcastle University Medicine Malaysia, Johor 79200, Malaysia

**Corresponding author:** Bin-Fei Li, MD, PhD, Chief Doctor, Department of Anaesthesiology, Zhongshan People's Hospital, No. 2 Sunwen East Road, Zhongshan 528403, Guangdong Province, China. [libf@zsph.com](mailto:libf@zsph.com)

### Abstract

#### BACKGROUND

Coronavirus disease 2019 (COVID-19), caused by severe acute respiratory syndrome coronavirus-2, is a worldwide pandemic. Some COVID-19 patients develop severe acute respiratory distress syndrome and progress to respiratory failure. In such cases, extracorporeal membrane oxygenation (ECMO) treatment is a necessary life-saving procedure.

#### CASE SUMMARY

Two special COVID-19 cases – one full-term pregnant woman and one elderly (72-

2020B1002.

**Informed consent statement:**

Written informed consent was obtained from the patients for publication of this case report and any accompanying images. A copy of the written consent is available on request.

**Conflict-of-interest statement:** The authors declare no conflict of interests.

**CARE Checklist (2016) statement:**

The authors have read the CARE Checklist (2016), and the manuscript was prepared and revised according to the CARE Checklist (2016).

**Open-Access:** This article is an open-access article that was selected by an in-house editor and fully peer-reviewed by external reviewers. It is distributed in accordance with the Creative Commons Attribution NonCommercial (CC BY-NC 4.0) license, which permits others to distribute, remix, adapt, build upon this work non-commercially, and license their derivative works on different terms, provided the original work is properly cited and the use is non-commercial. See: <http://creativecommons.org/licenses/by-nc/4.0/>

**Manuscript source:** Unsolicited manuscript

**Specialty type:** Medicine, research and experimental

**Country/Territory of origin:** China

**Peer-review report's scientific quality classification**

Grade A (Excellent): 0  
Grade B (Very good): B  
Grade C (Good): C  
Grade D (Fair): D  
Grade E (Poor): 0

**Received:** November 4, 2020

**Peer-review started:** November 4, 2020

**First decision:** November 23, 2020

**Revised:** December 23, 2020

**Accepted:** January 20, 2021

**Article in press:** January 20, 2021

year-old) man – were treated by veno-venous (VV)-ECMO in the Second People's Hospital of Zhongshan, Zhongshan City, Guangdong Province, China. Both patients had developed refractory hypoxemia shortly after hospital admission, despite conventional support, and were therefore managed by VV-ECMO. Although both experienced multiple ECMO-related complications on top of the COVID-19 disease, their conditions improved gradually. Both patients were weaned successfully from the ECMO therapy. At the time of writing of this report, the woman has recovered completely and been discharged from hospital to home; the man remains on mechanical ventilation, due to respiratory muscle weakness and suspected lung fibrosis. As ECMO itself is associated with various complications, it is very important to understand and treat these complications to achieve optimal outcome.

**CONCLUSION**

VV-ECMO can provide sufficient gas exchange for COVID-19 patients with acute respiratory distress syndrome. However, it is crucial to understand and treat ECMO-related complications.

**Key Words:** SARS-CoV-2; COVID-19; Coronavirus; Acute respiratory distress syndrome; Extracorporeal membrane oxygenation; Complications; Case report

©The Author(s) 2021. Published by Baishideng Publishing Group Inc. All rights reserved.

**Core Tip:** We present two cases of severe coronavirus disease 2019 (COVID-19) treated by extracorporeal membrane oxygenation (ECMO). The first, a full-term pregnant woman, was discharged with child loss but in good health, and the second, an elderly man, remains on ventilation support and may require lung transplantation. ECMO provided sufficient support for these COVID-19 patients with severe respiratory failure; however, both experienced several complications during the ECMO therapy, including right ventricular dysfunction, bleeding, thrombosis, acute renal failure, respiratory muscle weakness, and suspected pulmonary fibrosis. More case studies are needed to determine the optimal ECMO management strategy for COVID-19 patients.

**Citation:** Wen JL, Sun QZ, Cheng Z, Liao XZ, Wang LQ, Yuan Y, Li JW, Hou LS, Gao WJ, Wang WJ, Soh WY, Li BF, Ma DQ. Extracorporeal membrane oxygenation for coronavirus disease 2019-associated acute respiratory distress syndrome: Report of two cases and review of the literature. *World J Clin Cases* 2021; 9(8): 1953-1967

**URL:** <https://www.wjgnet.com/2307-8960/full/v9/i8/1953.htm>

**DOI:** <https://dx.doi.org/10.12998/wjcc.v9.i8.1953>

**INTRODUCTION**

Coronavirus disease 2019 (COVID-19), caused by severe acute respiratory syndrome coronavirus-2 (SARS-CoV-2), has rapidly evolved into a worldwide pandemic. To date, there are more than 33 million confirmed cases and 1 million deaths globally<sup>[1]</sup>. It has been shown that the lungs are the most affected organ, and many COVID-19 patients developed acute respiratory distress syndrome (ARDS) during their illness<sup>[2,3]</sup>.

Extracorporeal membrane oxygenation (ECMO) is a mechanical pump-assisted device that provides circulatory and respiratory support for patients experiencing cardiopulmonary failure. As a life-supporting intervention, ECMO is recommended by the World Health Organisation's interim guidance as a treatment for patients with refractory hypoxemia despite conventional ventilation support<sup>[4]</sup>.

Here, we report two special COVID-19 patients – one full-term pregnant woman and one elderly (72-year-old) man – whose lives were saved by veno-venous (VV-)ECMO support in the Second People's Hospital of Zhongshan, Guangdong Province, China.

Published online: March 16, 2021

P-Reviewer: He YF, Merkely B

S-Editor: Fan JR

L-Editor: Wang TQ

P-Editor: Liu JH



## CASE PRESENTATION

### Chief complaints

**Case 1:** A timeline of the main events is provided in [Figure 1](#). On February 1, 2020, a 31-year-old pregnant woman (week 35 of gestation) presented to Xiaolan People's Hospital in Zhongshan, China with complaints of fever and throat pain.

**Case 2:** A timeline of the main events is provided in [Figure 2](#). On February 9, 2020, a 72-year-old male patient presented to Zhongshan Traditional Chinese Medicine Hospital, with complaints of cough, subjective fever, and fatigue lasting since February 2, 2020.

### History of present illness

**Case 1:** The patient reported symptoms having started 4 d prior, coinciding with a travel back to Zhongshan from Wuhan on January 25, 2020. She reported having attended regular antenatal checks throughout her pregnancy, with all examination results having been normal. Within 6 h of admission to the Xiaolan People's Hospital, she developed severe hypoxia and septic shock. She was intubated and sedated for administration of mechanical ventilation (MV). An emergency caesarean delivery was carried out at bedside, and a live male was delivered. The infant weighed 2700 g and had an Apgar score of 1 at 1 min immediately after delivery. Cord blood tests indicated severe acidosis, hypoxemia, and potential cardiac damage. The infant died on the same day, despite receipt of active care. The patient's family refused a post-mortem examination, precluding determination of a definitive cause of death (*i.e.*, viral infection and/or hypoxia before birth).

As the mother's condition was extremely unstable, she was transferred to the Second People's Hospital of Zhongshan the day after delivery, in the early morning.

**Case 2:** The patient's symptoms started 1 wk before presenting to hospital.

### History of past illness

**Case 1:** The patient had previous good health.

**Case 2:** The patient had a long-term history of hypertension (20 years) and had undergone percutaneous coronary intervention (PCI) for left main and three-vessel coronary artery disease 5 years prior.

### Personal and family history

**Case 1:** The patient declared no remarkable family medical history.

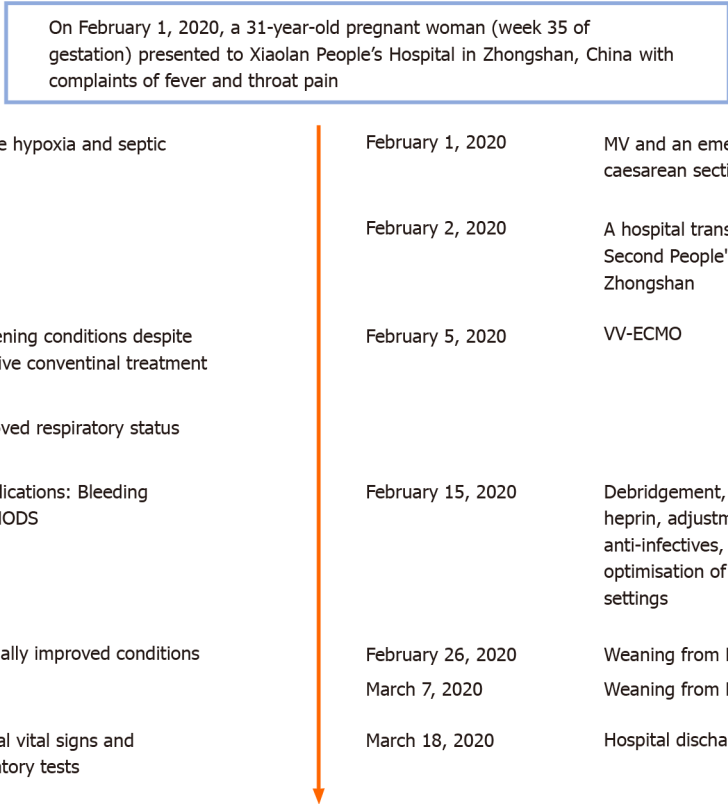
### Physical examination

**Case 1:** Upon admission to the Second People's Hospital of Zhongshan, the patient was placed on assisted MV [positive end-expiratory pressure (PEEP) of 15 cmH<sub>2</sub>O] under mild sedation. Intravenous norepinephrine was administered at 0.8 µg/kg/min. The patient's vital signs at admission were: Body temperature, 36.3 °C; pulse, 150 beats/min; and respiratory rate, 25 breaths/min. Her blood pressure was 122/79 mmHg and peripheral capillary oxygen saturation was 96.4%. Chest auscultation revealed coarse crackles in the left inferior lobe. No pathologic heart sound was detected by cardiac auscultation.

**Case 2:** The patient's vital signs at admission were body temperature of 37.5 °C, pulse of 98 beats/min, and respiratory rate of 20 breaths/min. His blood pressure was 129/71 mmHg. Chest auscultation detected crackles in both lungs. There was no pathologic sound detected from cardiac auscultation.

### Laboratory examinations

**Case 1:** Routine blood tests administered at admission gave the following results: White blood cell count,  $6.8 \times 10^9/L$  (normal range:  $4-10 \times 10^9/L$ ); lymphocytes, 14% (normal range: 17%-48%); neutrophils, 83.2% (normal range: 43%-76%); haemoglobin, 110 g/L (normal range: 110-150 g/L); red blood cell count,  $3.48 \times 10^{12}/L$  (normal range:  $3.5-5.5 \times 10^{12}/L$ ); and platelet count (PLT),  $160 \times 10^9/L$  (normal range:  $100-300 \times 10^9/L$ ). Biochemical tests showed high-level aspartate aminotransferase (AST) (190.6 U/L; normal range: 10-40 U/L), alanine aminotransferase (ALT) (137 U/L; normal range: 7-56 U/L), lactate dehydrogenase (LDH) (528.76 U/L; normal range: 140-280 U/L), C-reactive protein (CRP) (44.3 mg/L; normal range: < 8 mg/L), and creatine kinase (CK)-MB (33.4 U/L; normal range: < 24 U/L). Her blood electrolyte levels were normal.



**Figure 1 Case 1 timeline.** ECMO: Extracorporeal membrane oxygenation; MODS: Multiple organ dysfunction syndrome; MV: Mechanical ventilation; VV: Venovenous.

SARS-CoV-2 test, from nasopharyngeal swab specimen, was positive.

**Case 2:** Blood measures yielded the following results: White blood cell count,  $6.8 \times 10^9$  /L (normal range:  $4-10 \times 10^9$  /L); lymphocyte count,  $0.93 \times 10^9$  /L (normal range:  $0.8-4.0 \times 10^9$  /L); haemoglobin, 121 g/L (normal range: 120-160 g/L); and PLT,  $102 \times 10^9$  /L (normal range:  $100-300 \times 10^9$  /L). Biochemical tests yielded the following results: AST, 59.3 U/L (normal range: 10-40 U/L); CK, 478 U/L (normal range: 22-198 U/L); LDH, 366.98 U/L (normal range: 140-280 U/L); CRP, 44.3 mg/L (normal range: < 8 mg/L); creatinine, 189.00  $\mu$ mol/L (normal range: 74-107  $\mu$ mol/L); blood urea nitrogen, 15.40 mmol/L (normal range: 2.9-7.5 mmol/L); and potassium, 5.60 mmol/L (normal range: 3.5-5.0 mmol/L). His SARS-CoV-2 nucleic acid test was positive.

**Imaging examinations**

**Case 1:** Chest X-ray showed large patchy shadows in bilateral lungs (Figure 3A). Fibreoptic bronchoscopy detected massive frothy sputum.

**Case 2:** Chest X-ray showed infiltrates in bilateral lungs (Figure 4A). A chest computed tomography (CT) scan demonstrated ground-glass opacities and consolidation in bilateral lungs. The representative upper, middle, and lower transverse chest CT images showed multiple ground glass shadows in both lungs (day 3; Figure 5).

**FINAL DIAGNOSIS**

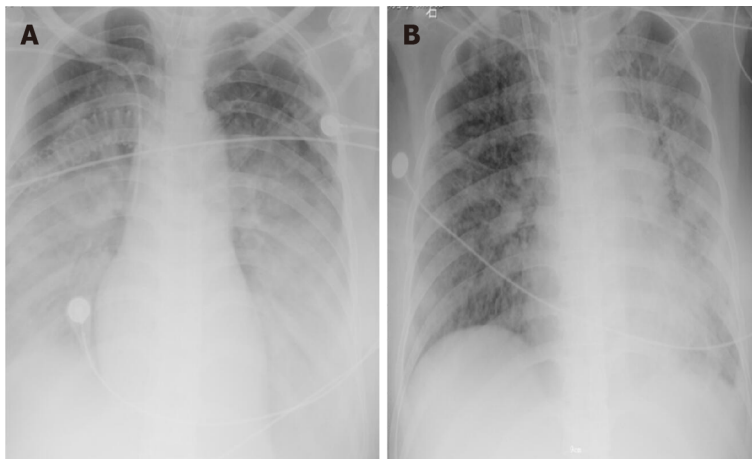
**Case 1:** COVID-19 pneumonia, ARDS, septic shock, septic cardiomyopathy, multiple organ dysfunction syndrome, and post-caesarean condition.

**Case 2:** COVID-19 pneumonia, post-PCI condition, and hypertension.

On February 9, 2020, a 72-year-old male patient presented to Zhongshan Traditional Chinese Medicine Hospital, with complaints of cough, subjective fever, and fatigue lasting since February 2, 2020. He has hypertension for 20 years and had a PCI in 2015.

Hyposensitive, hypoxemia and respiratory alkalosis	February 20, 2020	MV
Worsening conditions despite of active conventional treatment	February 22, 2020	VV-ECMO
Improved respiratory status		
Complications: Bleeding and circuit thrombosis	February 24, 2020	Reduction of heprin, cryoprecipitate and replacement of ECMO circuit
Gradually improved conditions	March 23, 2020	Weaning from ECMO
Deteriorated conditions: Unstable circulatory status, myelosuppression, <i>etc</i>	March 26, 2020	Recombinant human granulocyte colony-stimulating factor, $\gamma$ -globulin, and plasmapheresis
Suspected pulmonary fibrosis, wide area of mucoid impaction in small airways along with inspiratory muscle weakness	April 8, 2020	Remaining on MV

**Figure 2 Case 2 timeline.** ECMO: Extracorporeal membrane oxygenation; MODS: Multiple organ dysfunction syndrome; MV: Mechanical ventilation; PCI: Percutaneous coronary intervention; VV: Veno-venous.

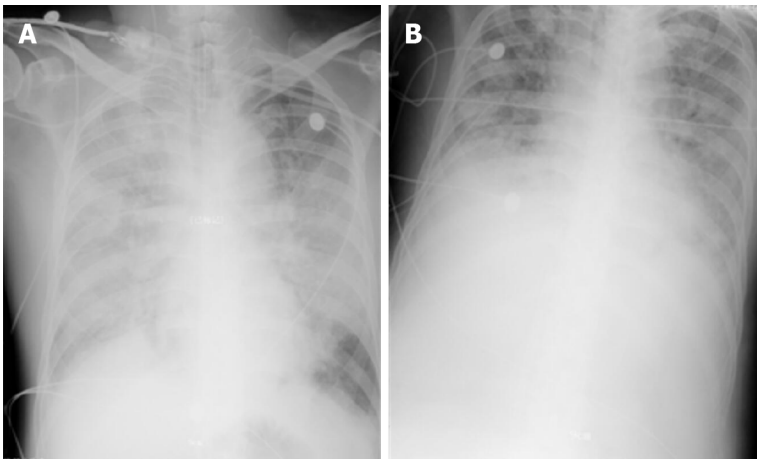


**Figure 3 Chest X-rays before and after extracorporeal membrane oxygenation in case 1.** A: Day of extracorporeal membrane oxygenation (ECMO); B: Day of weaning-off ECMO.

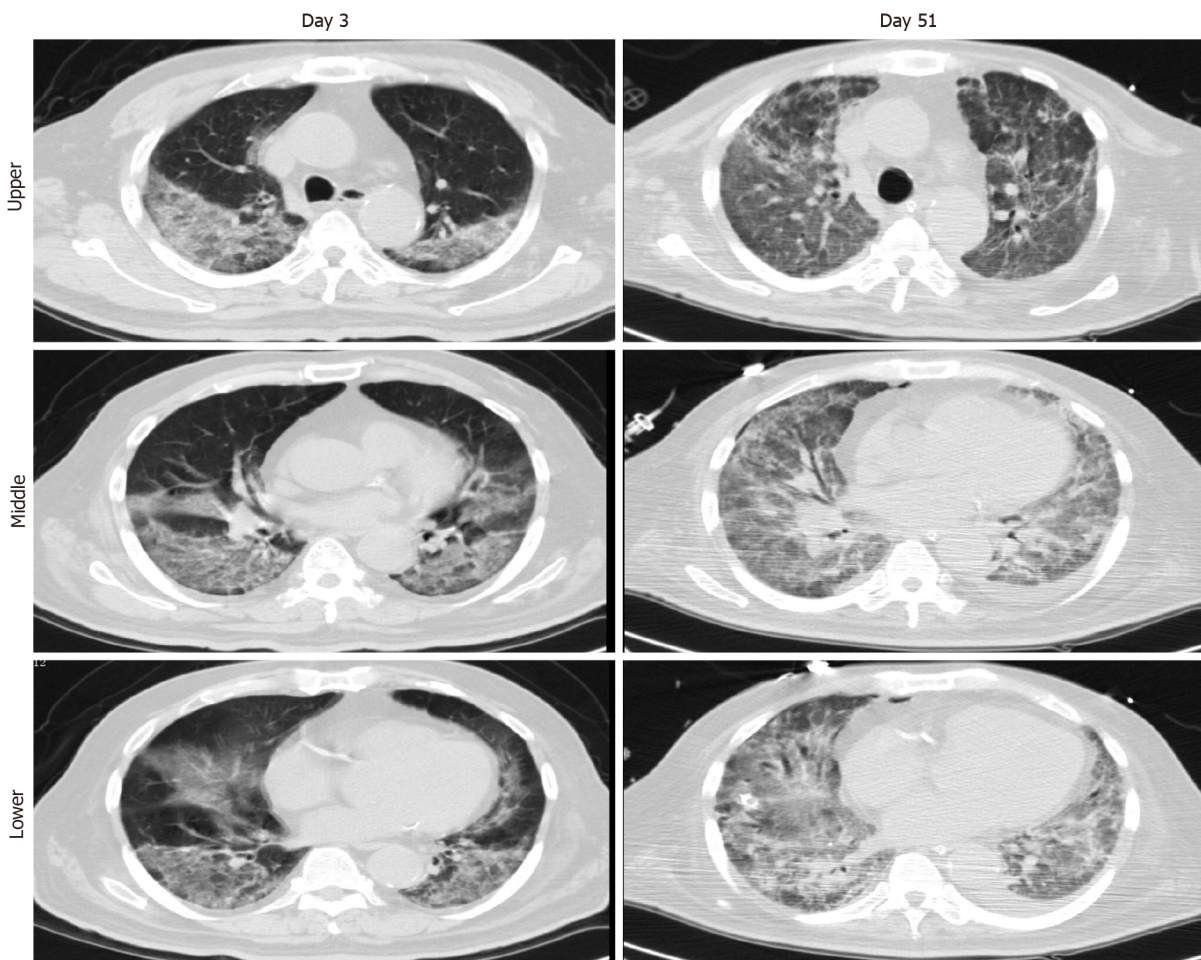
## TREATMENT

**Case 1:** To improve oxygenation, achieve better fluid balance, and remove excessive inflammatory factors, continuous renal replacement therapy (CRRT) was applied. Simultaneously, the patient received antiviral therapy, antibiotic therapy, steroid therapy, and other standard therapies (Figure 6). However, her condition deteriorated rapidly, over the next few hours. Arterial blood gas analysis demonstrated respiratory acidosis [pH, 7.34; partial pressure of carbon dioxide (PaCO<sub>2</sub>), 52.3 mmHg; partial pressure of oxygen (PaO<sub>2</sub>), 91.4 mmHg; HCO<sub>3</sub><sup>-</sup>, 27.9 mmol/L; fraction of inspired oxygen (FiO<sub>2</sub>), 1 L/L]. Consequently, she was placed on controlled MV, at a rate of 18 [bilevel positive airway pressure (BIPAP), FiO<sub>2</sub>, 1 L/L; inspiratory pressure, 35 cmH<sub>2</sub>O; PEEP, 15 cmH<sub>2</sub>O], with deep sedation (*via* morphine, midazolam and propofol





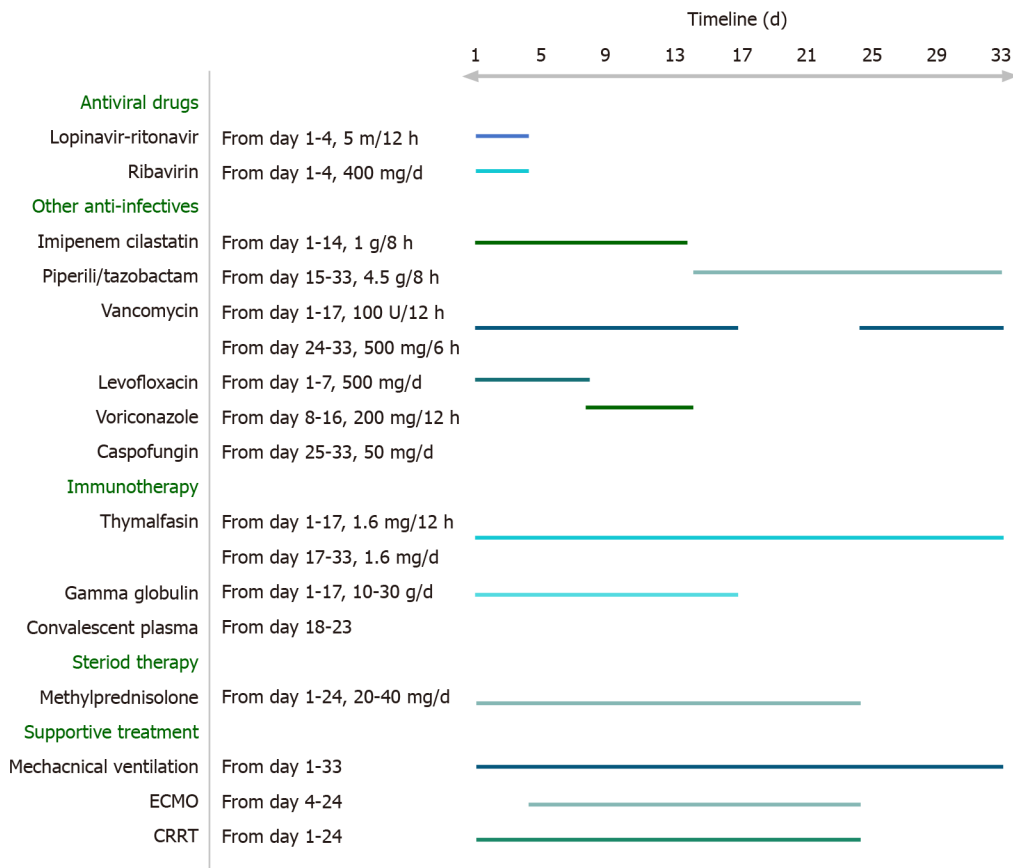
**Figure 4** Chest X-rays before and after extracorporeal membrane oxygenation in case 2. A: Day of extracorporeal membrane oxygenation (ECMO); B: Day of weaning-off ECMO.



**Figure 5** Chest computed tomography images of case 2.

combination).

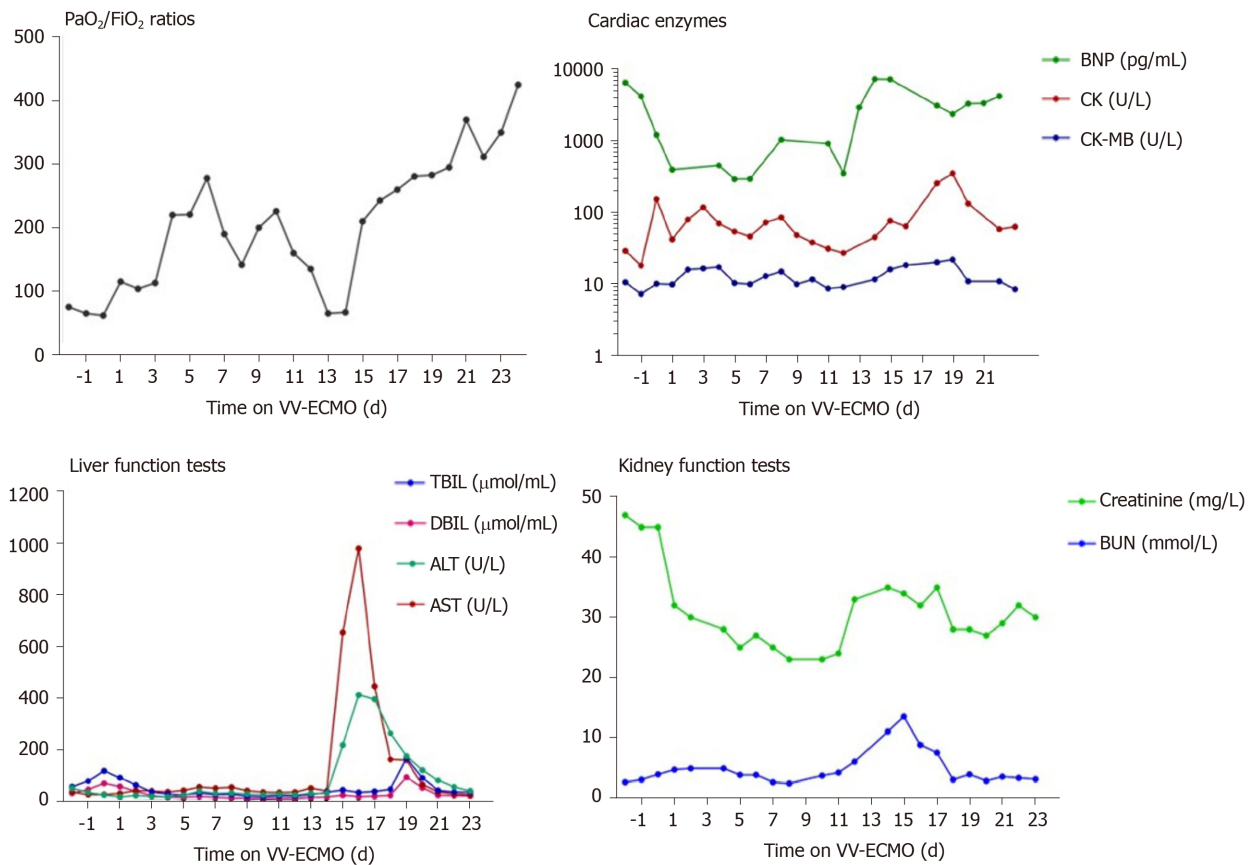
Despite the use of various anti-infective and supportive treatments, the patient's condition continued to deteriorate. She developed mild jaundice. Her blood test revealed leucocytosis (white blood cell count of  $23.86 \times 10^9/L$ ; normal range:  $4-10 \times 10^9/L$ ), neutrophilia (neutrophil percentage of 89.10%; normal range: 43%-76%), thrombocytopenia (PLT of  $68.00 \times 10^9/L$ ), high-level LDH (326.53 U/L; normal range: 140-280 U/L), hyperbilirubinemia [total bilirubin (TBIL) of 117.80  $\mu\text{mol/L}$ ; normal range: 1.71-20.5  $\mu\text{mol/L}$ , with direct bilirubin (DBIL) of 68.30  $\mu\text{mol/L}$ ; normal range:



**Figure 6** Treatments and medications after admission in case 1. ECMO: Extracorporeal membrane oxygenation; CRRT: Continuous renal replacement therapy.

0-5.1  $\mu\text{mol/L}$  and indirect bilirubin (IBIL) of 49.50  $\mu\text{mol/L}$ ; normal range: 0-13.7  $\mu\text{mol/L}$ ], high total bile acid [(TBA) of 14.2  $\text{mmol/L}$ ; normal range: 0.1-10.0  $\mu\text{mol/L}$ ], low prealbumin (45  $\text{mg/L}$ ; normal range: 280-360  $\text{mg/L}$ ), and high inflammatory biomarkers [high-sensitivity (hs-) CRP of 181.92  $\text{mg/L}$ ; normal range: < 1  $\text{mg/L}$ ; procalcitonin of 3.29  $\text{ng/mL}$ ; normal range: < 0.05  $\text{ng/mL}$ ]. Her arterial blood gas analysis showed severe hypoxemia and respiratory acidosis (pH, 7.27;  $\text{PaCO}_2$ , 61.9  $\text{mmHg}$ ;  $\text{PaO}_2$ , 62.3  $\text{mmHg}$ ;  $\text{HCO}_3^-$ , 28.2  $\text{mmol/L}$ ;  $\text{FiO}_2$ , 1  $\text{L/L}$ ). In consideration of her worsening hypoxemia despite maximum conventional support, VV-ECMO support was applied by the Zhongshan People's Hospital ECMO team.

The ECMO circuit was established through the internal jugular vein and femoral vein percutaneously. The blood flow setting ranged from 2.5-3.5  $\text{L/min}$  during the period of ECMO support. The patient's respiratory status improved in the first 10 d, with  $\text{PaO}_2/\text{FiO}_2$  ratios raising from 62 to 226. Considering her needs of prolonged MV after ECMO, a tracheostomy was performed on the day 10 of ECMO support. Surgical bleeding occurred during the operation, and the use of heparin was temporarily halted while a debridement was performed, which successfully controlled the bleeding. Between days 10 and 16 of the ECMO support, her condition worsened again, with  $\text{PaO}_2/\text{FiO}_2$  falling to 65. Blood measurements showed a marked increase of NT-proB-type natriuretic peptide (NT-proBNP) (reaching a maximum of 7267  $\text{pg/mL}$  on day 14; normal range: < 125  $\text{pg/mL}$ ), CK (reaching a maximum of 350  $\text{U/L}$  on day 19; normal range: 22-198  $\text{U/L}$ ), LDH (reaching a maximum of 1943  $\text{U/L}$  on day 16; normal range: 140-280  $\text{U/L}$ ), TBIL (reaching a maximum of 167  $\mu\text{mol/L}$  on day 19; normal range: 1.71-20.5  $\mu\text{mol/L}$ ), DBIL (reaching a maximum of 92.5  $\mu\text{mol/L}$  on day 19; normal range: 0-5.1  $\mu\text{mol/L}$ ), ALT (reaching a maximum of 411  $\text{U/L}$  on day 16; normal range: 10-40  $\text{U/L}$ ), AST (reaching a maximum of 980.7  $\text{U/L}$  on day 16; normal range: 7-56  $\text{U/L}$ ), creatinine (reaching a maximum of 35  $\text{mg/L}$  on day 14; normal range: 5-11  $\text{mg/L}$ ), and blood urea nitrogen (reaching a maximum of 13.5  $\text{mmol/L}$  on day 15; normal range: 2.9-7.5  $\text{mmol/L}$ ), indicating damage of the heart, kidney, and liver (Figure 7). Echocardiography revealed enlargement of the right ventricle (right ventricular diameter of 28 mm), indicating development of right ventricular dysfunction (RVD).



**Figure 7** Laboratory test results during extracorporeal membrane oxygenation in case 1. ALT: Alanine aminotransferase; AST: Aspartate aminotransferase; BNP: B-type natriuretic peptide; BUN: Blood urea nitrogen; CK: Creatine kinase; DBIL: Direct bilirubin; ECMO: Extracorporeal membrane oxygenation;  $FiO_2$ : Fraction of inspired oxygen;  $PaO_2$ : Partial pressure of oxygen; TBL: Total bilirubin; VV: Veno-venous.

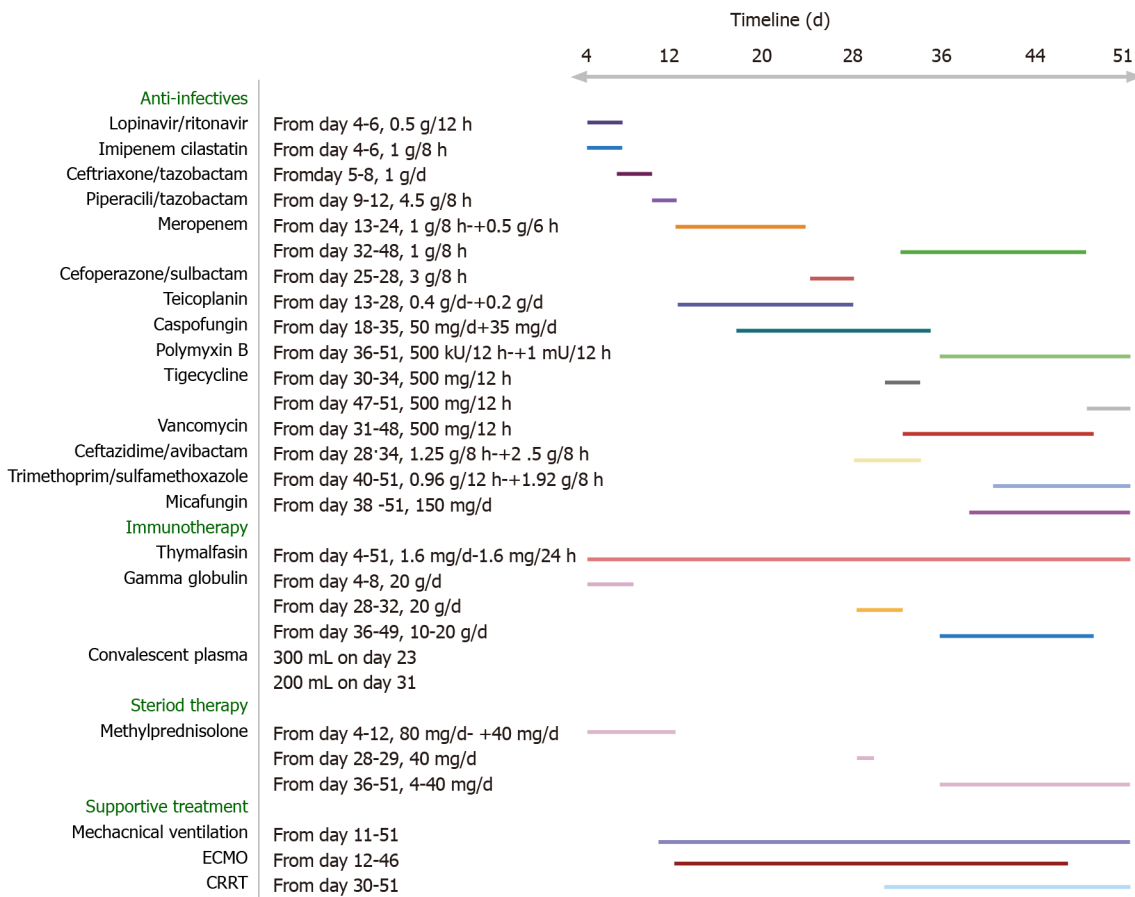
To support her right ventricle function, the fluid management, ECMO perfusion, and PEEP were optimised. Meanwhile, to avoid potential hepatotoxicity, the use of imipenem cilastatin sodium was discontinued and replaced with piperacillin/tazobactam. The use of vancomycin and voriconazole was also paused.

Over the next week, the patient's condition improved gradually. She demonstrated sufficient oxygenation ( $PaO_2/FiO_2$  raised to 370), partial recovery of lung function (tidal volume > 6 mL/kg in the condition of PEEP < 10 cmH<sub>2</sub>O and  $P_{peak}$  < 28 cmH<sub>2</sub>O), and improved chest radiography findings (Figure 3B). Blood tests showed that the levels of organ damage biomarkers were decreased remarkably.

**Case 2:** Treatments applied since admission were mainly supportive, concomitant with antiviral treatment (Figure 8). However, after 11 d, on February 20, 2020, the patient's condition worsened. He became severely hypotensive, requiring vasoactive support (norepinephrine at 0.15 mg/kg/min). Arterial blood gas analysis revealed severe hypoxemia and respiratory alkalosis (pH, 7.49;  $PaO_2$ , 52 mmHg;  $PaCO_2$ , 31 mmHg). The next day, intermittent non-invasive ventilation was initiated, but the patient complained of a sense of suffocation. His arterial blood gas parameters were pH of 7.50,  $PaO_2$  of 71 mmHg, and  $PaCO_2$  of 32 mmHg. Since his respiratory status did not improve and due to his intolerance of the intermittent non-invasive ventilation, MV was applied (BIPAP;  $FiO_2$ , 1 L/L; PEEP, 15 cmH<sub>2</sub>O). On February 22, 2020, the patient's condition deteriorated, with worsening of arterial blood gas parameters (pH, 7.29;  $PaCO_2$ , 62 mmHg;  $PaO_2$ , 65 mmHg). Failure of the conventional therapies to improve the patient's condition led to a decision to apply VV-ECMO support.

During the first 2 d of ECMO support, the patient's haemodynamics were stable and oxygenation was improved (Figure 9). Over the next 10 d, however, he developed bleeding and thrombosis. The posterior pharyngeal wall was accidentally injured during sputum suctioning, which caused repeated bleeding. A chest drain was inserted to address right-sided pleural effusion (approximately 7 cm on B-scan ultrasonography); the next day yielded a total drainage volume of 1500 mL blood. As thrombi were found in the ECMO canula, the ECMO circuit was replaced. The combination of bleeding and thrombi caused difficulty in regulating anticoagulation.





**Figure 8** Treatments and medications after admission in case 2. CRRT: Continuous renal replacement therapy; ECMO: Extracorporeal membrane oxygenation.

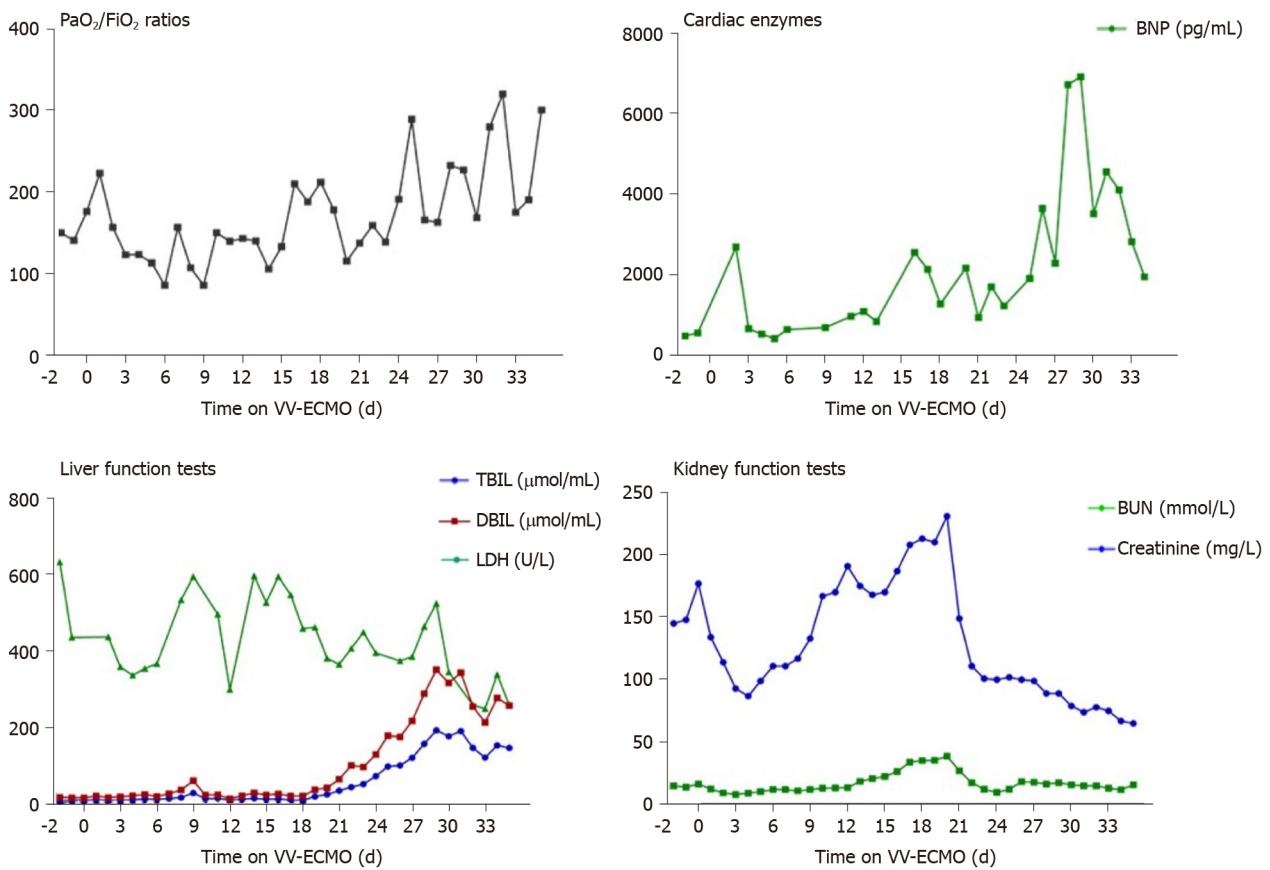
On day 18 of ECMO support, the decision was made to perform a tracheostomy, in recognition of the need for prolonged ventilation support after weaning-off of ECMO, with the condition of reducing heparin and applying normal plasma transfusion and cryoprecipitate. No significant bleeding occurred during the surgery. The continuation of antiviral therapy, vasoactive drugs, CRRT, anti-inflammation therapy, steroid therapy, and plasmapheresis facilitated a gradual improvement in the patient’s status. Cardiac function stabilised, with decreased level of BNP (from 6925 to 1957 pg/mL; normal range: < 125 pg/mL). Chest X-ray showed decreased infiltrates in bilateral lungs (Figure 4B).

On March 26, 2020, the patient was successfully weaned from VV-ECMO, after 33 d on ECMO. Unfortunately, following the weaning-off, the circulatory status became extremely unstable and increased levels of vasoactive drugs, sedatives, analgesics, and muscle relaxants were required. Over the next 10 d, the patient’s condition continued to deteriorate further. Myelosuppression developed and blood tests revealed leukopenia, thrombocytopenia, and increased levels of inflammatory biomarkers. Therapy with recombinant human granulocyte colony-stimulating factor,  $\gamma$ -globulin, and plasmapheresis was initiated.

## OUTCOME AND FOLLOW-UP

**Case 1:** The VV-ECMO therapy was stopped 21 d after ECMO application. The patient’s chest X-ray was much improved, prompting weaning from MV after 36 d of such. A chest CT scan on day 40 showed absorption of inflammatory lesions compared to day 30 (Figure 10). Her SARS-CoV-2 nucleic acid test result became negative after 40 d of admission (Figure 11). The patient was discharged from hospital to home, with normal vital signs and laboratory tests, after 46 d of admission.

**Case 2:** From April 8 to April 29, 2020, the patient’s condition stabilised, with his pulmonary compliance and circulatory status gradually improving. The result of



**Figure 9** Laboratory test results during extracorporeal membrane oxygenation in case 2. BNP: B-type natriuretic peptide; BUN: Blood urea nitrogen; DBIL: Direct bilirubin; ECMO: Extracorporeal membrane oxygenation; FiO<sub>2</sub>: Fraction of inspired oxygen; LDH: Lactate dehydrogenase; PaO<sub>2</sub>: Partial pressure of oxygen; TBIL: Total bilirubin; VV: Veno-venous.

SARS-CoV-2 nucleic acid test became negative (Figure 12). However, he had developed pulmonary fibrosis and a wide area of mucoid impaction in small airways, along with inspiratory muscle weakness. A CT scan showed diffuse ground glass opacities and honeycombing in both lungs, indicating the development of pulmonary fibrosis (day 51; Figure 5). As such, he remained on ventilatory support and (of the time of writing this report) may require a lung transplantation.

## DISCUSSION

ECMO is a life-supporting intervention, whereby an external mechanical pump collects venous blood and performs gas-exchange through an oxygenator. ECMO has been used in patients with severe ARDS for decades<sup>[5]</sup>. Since the outbreak of the COVID-19 pandemic, there has been increased usage of ECMO in supporting COVID-19 patients as an ultimate treatment to sustain their lives<sup>[6]</sup>. The advantage of ECMO in COVID-19 patients is that it maintains the oxygen supply while providing a time window for the lungs to rest and recover. However, as a highly invasive treatment, ECMO itself is associated with many life-threatening complications, such as cardiac failure, renal failure, bleeding, thrombosis, and infection. Therefore, efforts to and experience in preventing and treating ECMO-related complications are very important.

In this report, we present two COVID-19 patients who were supported by ECMO. After admission, both patients experienced a rapid deterioration of their respiratory function, with a decrease of PaO<sub>2</sub> from 91 mmHg to 62 mmHg in the female patient and 150 mmHg to 65 mmHg in the male patient within 24 h under ventilation with FiO<sub>2</sub> more than 600 mL/L. Of interest, the man (case 2) experienced various fluctuations of PaO<sub>2</sub>/FiO<sub>2</sub> ratios throughout the course of ECMO, much more so than those experienced by the woman (case 1), indicating that the outcome may not be optimal (Figure 13). As both patients developed severe hypoxemia despite maximum

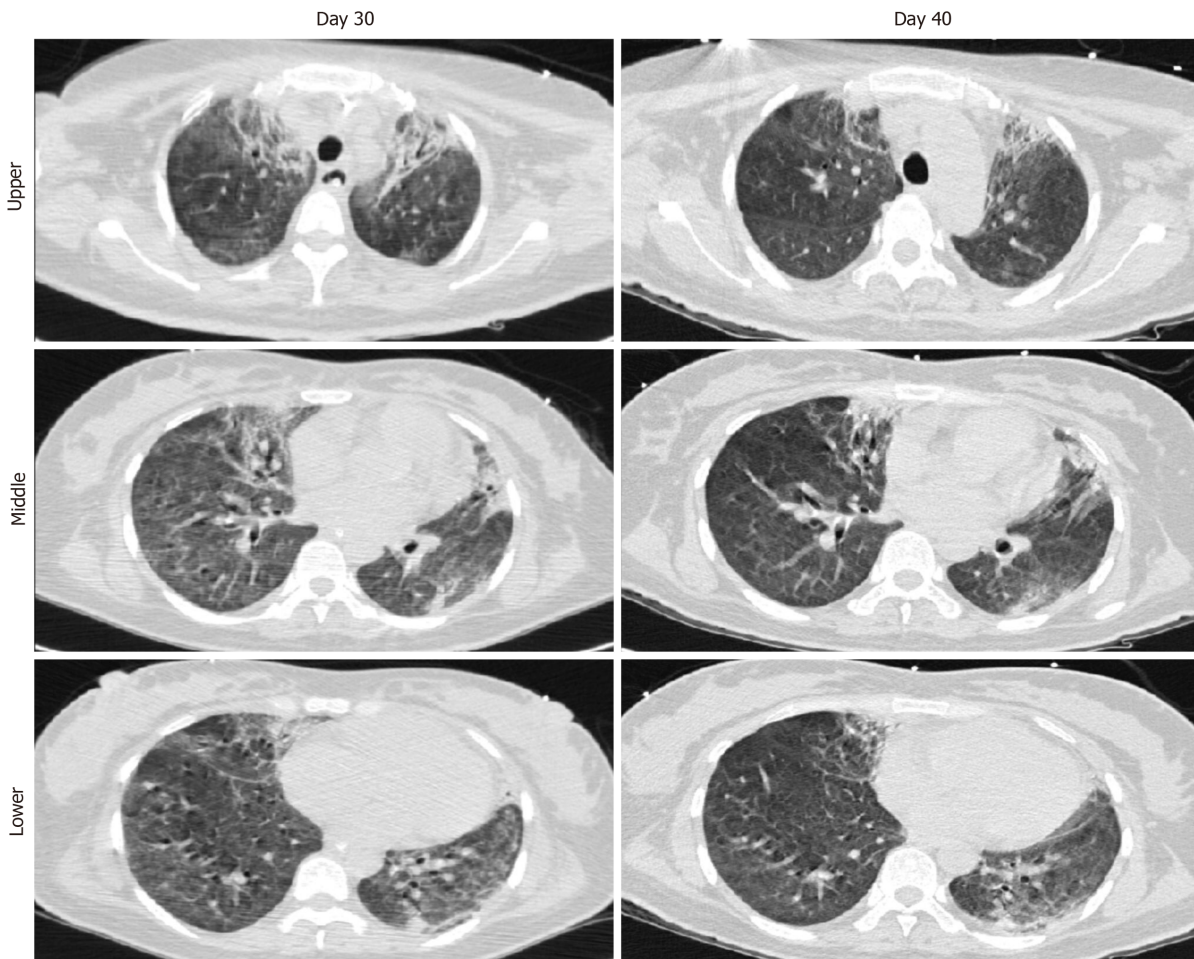


Figure 10 Chest computed tomography images of case 1.

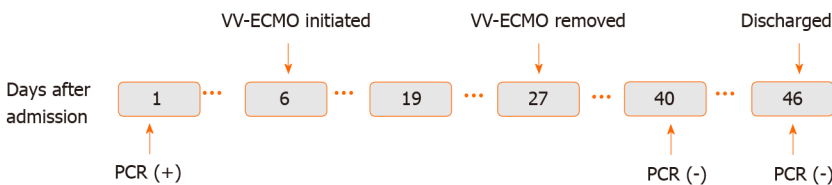


Figure 11 Severe acute respiratory syndrome coronavirus-2 nucleic acid test results of case 1. ECMO: Extracorporeal membrane oxygenation; PCR: Polymerase chain reaction; VV: Veno-venous.

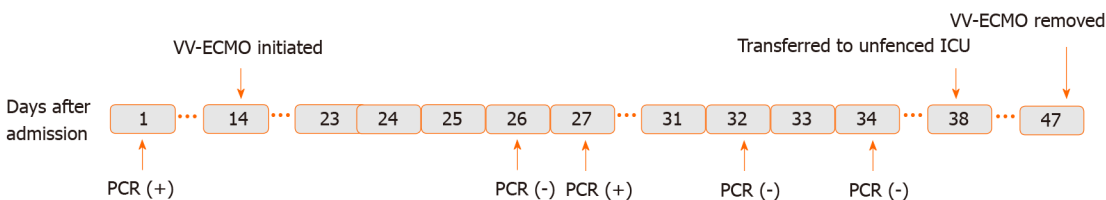
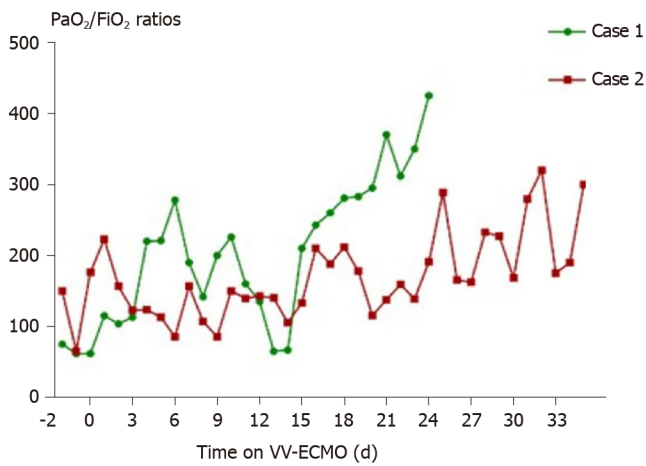


Figure 12 Severe acute respiratory syndrome coronavirus-2 nucleic acid test results of case 2. ECMO: Extracorporeal membrane oxygenation; PCR: Polymerase chain reaction; VV: Veno-venous; ICU: Intensive care unit.

conventional ventilation support, VV-ECMO support was applied. There was an immediate increase in PaO<sub>2</sub>/FiO<sub>2</sub> ratios after the initiation of ECMO, indicating the advantage of VV-ECMO for improving oxygenation in severe COVID-19 cases. In fact, the rapid deterioration experienced, also known as the “second week crash”, has been presented in multiple previous studies as a feature of COVID-19<sup>[7-10]</sup>. It is characterized as a phenomenon that occurs 7-8 d after the initial symptom onset, with some COVID-



**Figure 13 Comparisons of partial pressure of oxygen/fraction of inspired oxygen ratios of case 1 and case 2.** ECMO: Extracorporeal membrane oxygenation; FiO<sub>2</sub>: Fraction of inspired oxygen; PaO<sub>2</sub>: Partial pressure of oxygen; VV: Veno-venous.

19 patients' symptoms progressing suddenly from mild to severe. A recent immunology study revealed that this unique pattern of clinical course is associated with over-production of inflammatory factors<sup>[11]</sup>. Overall experience suggests that early application of anti-inflammatory therapies may relieve this life-threatening course, making it worthwhile to investigate its mechanism and optimal strategies in the future.

In our case series, the first patient was discharged from hospital with normal vital signs and laboratory tests, while the other remained in-hospital on ventilation support and may require a lung transplantation due to pulmonary fibrosis. Several factors may explain the outcome difference between these two patients. One of those factors is age. It has been shown that older people are at an increased risk of developing pulmonary fibrosis following COVID-19-induced ARDS ( $45.4 \pm 16.9$  vs  $33.8 \pm 10.2$  years of age)<sup>[12,13]</sup>. Similarly, retrospective studies have revealed that older patients were more prone to developing pulmonary fibrosis following SARS- or Middle East respiratory syndrome (commonly known as MERS)-induced ARDS<sup>[14]</sup>. This should be taken into consideration since ECMO is such a resource-intensive procedure and involves expensive equipment. Another possible factor is the timing of MV. For our case 1, the MV was initiated immediately after oxygen therapy failure, while for our case 2, high-concentration oxygen therapy was applied for 10 d and shortness of breath occurring over 1 d prompted MV support. Although oxygen therapy is a life-saving technique for patients with hypoxia, it has been demonstrated that continuous high-concentration oxygen therapy can cause lung injury<sup>[15]</sup>. Besides, studies have shown that the high transpulmonary pressure caused by shortness of breath can also damage the lungs<sup>[16]</sup>, which may have happened in our patient (case 2). There is probably a survival benefit to the application of MV at an earlier time for COVID-19 patients in whom oxygen therapy cannot provide a satisfactory level of oxygenation, and this needs to be investigated in the future. In addition, hospital-acquired infection may have contributed to the opposite outcomes of our patients as well. In case 1, no bacteria were detected in blood culture; in case 2, *Streptomonas maltophilia* was detected in blood culture after removing ECMO. This pathogen may have further aggravated the COVID-19-related inflammation in his lungs and deterioration of his pulmonary function.

Acute cardiac failure is one complication of ECMO. On day 10 of ECMO support, our female patient (case 1) developed acute RVD. RVD is defined as a clinical syndrome meeting at least one of the following criteria: Acute presence of right ventricle systolic dysfunction, confirmed by echocardiography; and increase of cardiac enzymes in the absence of left ventricle and renal dysfunction and moderate to severe right ventricular strain patterns detected by electrocardiogram<sup>[17,18]</sup>. RVD is a common complication of ARDS, with a reported incidence ranging from 30% to 56%<sup>[19,20]</sup>; of note, a consecutive study of 74 ARDS patients referred to ECMO found an RVD incidence of 28.6%<sup>[21]</sup>. The main direct aetiology of RVD in ARDS is right ventricle overload<sup>[22]</sup>. The most common cause of excessive right ventricle preload is fluid overload. VV-ECMO application over a long duration and high flow can also be a cause of increased right ventricle preload. As VV-ECMO provides non-pulsatile flow, it may cause a right ventricle volume overload over time<sup>[23]</sup>. Optimisations of fluid



management and ECMO flow, therefore, may serve as effective ways to treat excessive right ventricle preload-related right ventricle dysfunction. On the other hand, right ventricle overloading has been associated with hypoxic/hypercarbic vasoconstriction and high PEEP setting in MV<sup>[18,23]</sup>. Improving gas exchange and reducing PEEP may, therefore, help decrease right ventricle afterload. To prevent RVD, early diagnosis and intervention are important. There are four predictors of RVD in ARDS that have been identified recently, namely, pneumonia-caused ARDS, driving pressure of  $\geq 18$  cmH<sub>2</sub>O (calculated as the difference between plateau pressure and total PEEP), PaCO<sub>2</sub> of  $\geq 48$  mmHg, and PaO<sub>2</sub>/FiO<sub>2</sub> of  $< 150$  mmHg<sup>[20]</sup>. As severe COVID-19 patients who require VV-ECMO are always associated with at least one of these four predictors<sup>[24]</sup>, routine electrocardiogram and echocardiographic monitoring, and early application of right ventricle protective strategies should be applied in advance.

Bleeding and thrombosis are common complications of ECMO and are associated with mortality<sup>[25-29]</sup>. Since there is not a standard anticoagulation protocol currently available for ECMO<sup>[30]</sup>, anticoagulation management during ECMO is a substantial challenge facing clinical care providers. In our case series, case 1 experienced bleeding at the surgical site after receiving a tracheostomy. The event was well-controlled by temporarily halting the use of heparin and performance of a debridement by otolaryngologists. Case 2 developed a combination of bleeding and thrombosis in the ECMO tube system, both of which were alleviated by adjustments of the unfractionated heparin level, administration of plasma transfusion and cryoprecipitate, and replacement of the ECMO circuit. Our anticoagulation strategy involved heparin-coated circuits with standard-level unfractionated heparin infusion, titrated to an activated coagulation time (ACT) of 150-180 s. Evidence shows that COVID-19 has an association with reduced platelet count and elevations in D-dimers and fibrin-fibrinogen degradation products, indicating that this novel disease may have an impact on coagulation status. Thus, to achieve the best outcome for these patients, a more individualised anticoagulation regimen can be generated upon close monitoring of each patient's coagulation status. On the other hand, although ACT is a gold standard for monitoring anticoagulation during ECMO, multiple studies have shown that inadequate anticoagulation or bleeding can occur despite ACT monitoring<sup>[31-33]</sup>. Since bleeding and thrombosis represent such common life-threatening complications during ECMO, introducing alternative coagulation tests, such as the anti-Xa assay and thromboelastography, can be beneficial for COVID-19 patients.

---

## CONCLUSION

Our case series showed that ECMO provided sufficient support of gas exchange for COVID-19 patients with severe respiratory failure. Nevertheless, many complications occurred during the ECMO support application, including RVD, bleeding, thrombosis, acute renal failure, respiratory muscle weakness, and suspected pulmonary fibrosis. Our experience also supports the World Health Organization's interim guidance for ECMO to be considered only in patients with refractory respiratory failure after conventional support. The disease complexity (*e.g.*, cytokine storm, coagulation changes, and multiple organ failure) of COVID-19 may have an extra-impact on ECMO management, and more knowledge needs to be gained through focused case studies.

---

## ACKNOWLEDGEMENTS

We would like to express our sincere gratitude to those clinicians who made tremendous efforts towards saving lives during the COVID-19 pandemic. We want to thank the patients presented herein for giving permission to present their cases and to the unnamed patients who donated convalescent plasma.

---

## REFERENCES

- 1 Tsang HF, Chan LWC, Cho WCS, Yu ACS, Yim AKY, Chan AKC, Ng LPW, Wong YKE, Pei XM, Li MJW, Wong SC. An update on COVID-19 pandemic: the epidemiology, pathogenesis, prevention and treatment strategies. *Expert Rev Anti Infect Ther* 2020; 1-12 [PMID: 33306423 DOI: ]



- 10.1080/14787210.2021.1863146]
- 2 **Rizzo P**, Viecelli Dalla Sega F, Fortini F, Marracino L, Rapezzi C, Ferrari R. COVID-19 in the heart and the lungs: could we "Notch" the inflammatory storm? *Basic Res Cardiol* 2020; **115**: 31 [PMID: 32274570 DOI: 10.1007/s00395-020-0791-5]
  - 3 **Verdecchia P**, Cavallini C, Spanevello A, Angeli F. The pivotal link between ACE2 deficiency and SARS-CoV-2 infection. *Eur J Intern Med* 2020; **76**: 14-20 [PMID: 32336612 DOI: 10.1016/j.ejim.2020.04.037]
  - 4 **World Health Organization**. Clinical management of severe acute respiratory infection (SARI) when COVID-19 disease is suspected: interim guidance. [13 March 2020]. World Health Organization, 2020. Available from: <https://apps.who.int/iris/handle/10665/331446;jsessionid=4C3E879A9883ED0A8241C0609DED0322>
  - 5 **Hill JD**, O'Brien TG, Murray JJ, Dontigny L, Bramson ML, Osborn JJ, Gerbode F. Prolonged extracorporeal oxygenation for acute post-traumatic respiratory failure (shock-lung syndrome). Use of the Bramson membrane lung. *N Engl J Med* 1972; **286**: 629-634 [PMID: 5060491 DOI: 10.1056/nejm197203232861204]
  - 6 **Wang D**, Hu B, Hu C, Zhu F, Liu X, Zhang J, Wang B, Xiang H, Cheng Z, Xiong Y, Zhao Y, Li Y, Wang X, Peng Z. Clinical Characteristics of 138 Hospitalized Patients With 2019 Novel Coronavirus-Infected Pneumonia in Wuhan, China. *JAMA* 2020; **323**: 1061-1069 [PMID: 32031570 DOI: 10.1001/jama.2020.1585]
  - 7 **Heymann DL**, Shindo N; WHO Scientific and Technical Advisory Group for Infectious Hazards. COVID-19: what is next for public health? *Lancet* 2020; **395**: 542-545 [PMID: 32061313 DOI: 10.1016/S0140-6736(20)30374-3]
  - 8 **Zhang W**, Zhao Y, Zhang F, Wang Q, Li T, Liu Z, Wang J, Qin Y, Zhang X, Yan X, Zeng X, Zhang S. The use of anti-inflammatory drugs in the treatment of people with severe coronavirus disease 2019 (COVID-19): The Perspectives of clinical immunologists from China. *Clin Immunol* 2020; **214**: 108393 [PMID: 3222466 DOI: 10.1016/j.clim.2020.108393]
  - 9 **Huang C**, Wang Y, Li X, Ren L, Zhao J, Hu Y, Zhang L, Fan G, Xu J, Gu X, Cheng Z, Yu T, Xia J, Wei Y, Wu W, Xie X, Yin W, Li H, Liu M, Xiao Y, Gao H, Guo L, Xie J, Wang G, Jiang R, Gao Z, Jin Q, Wang J, Cao B. Clinical features of patients infected with 2019 novel coronavirus in Wuhan, China. *Lancet* 2020; **395**: 497-506 [PMID: 31986264 DOI: 10.1016/S0140-6736(20)30183-5]
  - 10 **Chen N**, Zhou M, Dong X, Qu J, Gong F, Han Y, Qiu Y, Wang J, Liu Y, Wei Y, Xia J, Yu T, Zhang X, Zhang L. Epidemiological and clinical characteristics of 99 cases of 2019 novel coronavirus pneumonia in Wuhan, China: a descriptive study. *Lancet* 2020; **395**: 507-513 [PMID: 32007143 DOI: 10.1016/S0140-6736(20)30211-7]
  - 11 **Giamarellos-Bourboulis EJ**, Netea MG, Rovina N, Akinosoglou K, Antoniadou A, Antonakos N, Damoraki G, Gkavogianni T, Adami ME, Katsaounou P, Ntaganou M, Kyriakopoulou M, Dimopoulos G, Koutsodimitropoulos I, Velissaris D, Koufargyris P, Karageorgos A, Katrini K, Lekakis V, Lupse M, Kotsaki A, Renieris G, Theodoulou D, Panou V, Koukaki E, Koulouris N, Gogos C, Koutsoukou A. Complex Immune Dysregulation in COVID-19 Patients with Severe Respiratory Failure. *Cell Host Microbe* 2020; **27**: 992-1000. e3 [PMID: 32320677 DOI: 10.1016/j.chom.2020.04.009]
  - 12 **Wong KT**, Antonio GE, Hui DS, Ho C, Chan PN, Ng WH, Shing KK, Wu A, Lee N, Yap F, Joynt GM, Sung JJ, Ahuja AT. Severe acute respiratory syndrome: thin-section computed tomography features, temporal changes, and clinicoradiologic correlation during the convalescent period. *J Comput Assist Tomogr* 2004; **28**: 790-795 [PMID: 15538152 DOI: 10.1097/00004728-200411000-00010]
  - 13 **Das KM**, Lee EY, Singh R, Enani MA, Al Dossari K, Van Gorkom K, Larsson SG, Langer RD. Follow-up chest radiographic findings in patients with MERS-CoV after recovery. *Indian J Radiol Imaging* 2017; **27**: 342-349 [PMID: 29089687 DOI: 10.4103/ijri.IJRI\_469\_16]
  - 14 **Spagnolo P**, Balestro E, Aliberti S, Cocconcetti E, Biondini D, Casa GD, Sverzellati N, Maher TM. Pulmonary fibrosis secondary to COVID-19: a call to arms? *Lancet Respir Med* 2020; **8**: 750-752 [PMID: 32422177 DOI: 10.1016/S2213-2600(20)30222-8]
  - 15 **Budinger GRS**, Mutlu GM. Balancing the risks and benefits of oxygen therapy in critically ill adults. *Chest* 2013; **143**: 1151-1162 [PMID: 23546490 DOI: 10.1378/chest.12-1215]
  - 16 **Mauri T**, Yoshida T, Bellani G, Goligher EC, Carreaux G, Rittayamai N, Mojoli F, Chiumello D, Piquilloud L, Grasso S, Jubran A, Laghi F, Magder S, Pesenti A, Loring S, Gattinoni L, Talmor D, Blanch L, Amato M, Chen L, Brochard L, Mancebo J; PLeUral pressure working Group (PLUG—Acute Respiratory Failure section of the European Society of Intensive Care Medicine). Esophageal and transpulmonary pressure in the clinical setting: meaning, usefulness and perspectives. *Intensive Care Med* 2016; **42**: 1360-1373 [PMID: 27334266 DOI: 10.1007/s00134-016-4400-x]
  - 17 **Konstantinides SV**, Torbicki A, Agnelli G, Danchin N, Fitzmaurice D, Galiè N, Gibbs JS, Huisman MV, Humbert M, Kucher N, Lang I, Lankeit M, Lekakis J, Maack C, Mayer E, Meneveau N, Perrier A, Pruszczyk P, Rasmussen LH, Schindler TH, Svitil P, Vonk Noordegraaf A, Zamorano JL, Zompatori M; Task Force for the Diagnosis and Management of Acute Pulmonary Embolism of the European Society of Cardiology (ESC). 2014 ESC guidelines on the diagnosis and management of acute pulmonary embolism. *Eur Heart J* 2014; **35**: 3033-3069, 3069a [PMID: 25173341 DOI: 10.1093/eurheartj/ehu283]
  - 18 **Grignola JC**, Domingo E. Acute Right Ventricular Dysfunction in Intensive Care Unit. *Biomed Res Int* 2017; **2017**: 8217105 [PMID: 29201914 DOI: 10.1155/2017/8217105]

- 19 **Vieillard-Baron A**, Schmitt JM, Augarde R, Fellahi JL, Prin S, Page B, Beauchet A, Jardin F. Acute cor pulmonale in acute respiratory distress syndrome submitted to protective ventilation: incidence, clinical implications, and prognosis. *Crit Care Med* 2001; **29**: 1551-1555 [PMID: [11505125](#) DOI: [10.1097/00003246-200108000-00009](#)]
- 20 **Mekontso Dessap A**, Boissier F, Charron C, Bégot E, Repessé X, Legras A, Brun-Buisson C, Vignon P, Vieillard-Baron A. Acute cor pulmonale during protective ventilation for acute respiratory distress syndrome: prevalence, predictors, and clinical impact. *Intensive Care Med* 2016; **42**: 862-870 [PMID: [26650055](#) DOI: [10.1007/s00134-015-4141-2](#)]
- 21 **Lazzeri C**, Cianchi G, Bonizzoli M, Batacchi S, Terenzi P, Bernardo P, Valente S, Gensini GF, Peris A. Right ventricle dilation as a prognostic factor in refractory acute respiratory distress syndrome requiring veno-venous extracorporeal membrane oxygenation. *Minerva Anestesiol* 2016; **82**: 1043-1049 [PMID: [26957118](#)]
- 22 **Bunge JHH**, Caliskan K, Gommers D, Reis Miranda D. Right ventricular dysfunction during acute respiratory distress syndrome and veno-venous extracorporeal membrane oxygenation. *J Thorac Dis* 2018; **10**: S674-S682 [PMID: [29732186](#) DOI: [10.21037/jtd.2017.10.75](#)]
- 23 **Lee SH**, Jung JS, Chung JH, Lee KH, Kim HJ, Son HS, Sun K. Right Heart Failure during Venous Extracorporeal Membrane Oxygenation for H1N1 Induced Acute Respiratory Distress Syndrome: Case Report and Literature Review. *Korean J Thorac Cardiovasc Surg* 2015; **48**: 289-293 [PMID: [26290843](#) DOI: [10.5090/kjtc.2015.48.4.289](#)]
- 24 **Barbaro RP**, MacLaren G, Boonstra PS, Iwashyna TJ, Slutsky AS, Fan E, Bartlett RH, Tonna JE, Hyslop R, Fanning JJ, Rycus PT, Hyer SJ, Anders MM, Agerstrand CL, Hryniewicz K, Diaz R, Lorusso R, Combes A, Brodie D; Extracorporeal Life Support Organization. Extracorporeal membrane oxygenation support in COVID-19: an international cohort study of the Extracorporeal Life Support Organization registry. *Lancet* 2020; **396**: 1071-1078 [PMID: [32987008](#) DOI: [10.1016/S0140-6736\(20\)32008-0](#)]
- 25 **Aubron C**, DePuydt J, Belon F, Bailey M, Schmidt M, Sheldrake J, Murphy D, Scheinkestel C, Cooper DJ, Capellier G, Pellegrino V, Pilcher D, McQuilten Z. Predictive factors of bleeding events in adults undergoing extracorporeal membrane oxygenation. *Ann Intensive Care* 2016; **6**: 97 [PMID: [27714705](#) DOI: [10.1186/s13613-016-0196-7](#)]
- 26 **Lotz C**, Streiber N, Roewer N, Lepper PM, Muellenbach RM, Kredel M. Therapeutic Interventions and Risk Factors of Bleeding During Extracorporeal Membrane Oxygenation. *ASAIO J* 2017; **63**: 624-630 [PMID: [28118261](#) DOI: [10.1097/MAT.0000000000000525](#)]
- 27 **Aubron C**, Cheng AC, Pilcher D, Leong T, Magrin G, Cooper DJ, Scheinkestel C, Pellegrino V. Factors associated with outcomes of patients on extracorporeal membrane oxygenation support: a 5-year cohort study. *Crit Care* 2013; **17**: R73 [PMID: [23594433](#) DOI: [10.1186/cc12681](#)]
- 28 **Rastan AJ**, Lachmann N, Walther T, Doll N, Gradistanac T, Gommert JF, Lehmann S, Wittekind C, Mohr FW. Autopsy findings in patients on postcardiotomy extracorporeal membrane oxygenation (ECMO). *Int J Artif Organs* 2006; **29**: 1121-1131 [PMID: [17219352](#) DOI: [10.1177/039139880602901205](#)]
- 29 **Murphy DA**, Hockings LE, Andrews RK, Aubron C, Gardiner EE, Pellegrino VA, Davis AK. Extracorporeal membrane oxygenation-hemostatic complications. *Transfus Med Rev* 2015; **29**: 90-101 [PMID: [25595476](#) DOI: [10.1016/j.tmr.2014.12.001](#)]
- 30 **Bembea MM**, Annich G, Rycus P, Oldenburg G, Berkowitz I, Pronovost P. Variability in anticoagulation management of patients on extracorporeal membrane oxygenation: an international survey. *Pediatr Crit Care Med* 2013; **14**: e77-e84 [PMID: [23287906](#) DOI: [10.1097/PCC.0b013e31827127e4](#)]
- 31 **Owings JT**, Pollock ME, Gosselin RC, Ireland K, Jahr JS, Larkin EC. Anticoagulation of children undergoing cardiopulmonary bypass is overestimated by current monitoring techniques. *Arch Surg* 2000; **135**: 1042-1047 [PMID: [10982508](#) DOI: [10.1001/archsurg.135.9.1042](#)]
- 32 **Kitchens CS**. To bleed or not to bleed? *J Thromb Haemost* 2005; **3**: 2607-2611 [PMID: [16150051](#) DOI: [10.1111/j.1538-7836.2005.01552.x](#)]
- 33 **Sievert A**, Uber W, Laws S, Cochran J. Improvement in long-term ECMO by detailed monitoring of anticoagulation: a case report. *Perfusion* 2011; **26**: 59-64 [PMID: [21057061](#) DOI: [10.1177/0267659110385513](#)]



Published by **Baishideng Publishing Group Inc**  
7041 Koll Center Parkway, Suite 160, Pleasanton, CA 94566, USA

**Telephone:** +1-925-3991568

**E-mail:** [bpgoffice@wjgnet.com](mailto:bpgoffice@wjgnet.com)

**Help Desk:** <https://www.f6publishing.com/helpdesk>

<https://www.wjgnet.com>

