


# Acute Lower Limb Ischemia in Patients Infected with COVID-19

This article was published in the following Dove Press journal:  
*International Journal of General Medicine*

Nabil Al-zoubi   
Nawaf Shatnawi  
Hamza Jarbo

Department of General Surgery/Vascular  
Surgery, Jordan University of Science and  
Technology, Irbid, Jordan

**Background:** The aim of this study was to investigate the prevalence of acute lower limb ischemia (ALLI) among patients infected with COVID-19 and to review their characteristics and outcomes.

**Methods:** This study was performed at King Abdullah University Hospital (KAUH) in the north of Jordan. All patients with ALLI and COVID-19 infection, between November 1, 2020 and December 31, 2020, were retrospectively identified and reviewed.

**Results:** A total number of 1300 COVID-19 patients were admitted to KAUH during the period of the study. Seven patients (0.54%) had ALLI. Of them, 5 were males (71.4%) with a mean age of  $68 \pm 3$  years and 2 were females (28.6%) with a mean age of  $58 \pm 7$  years. Five patients (71.4%) were admitted as COVID-19 infection and developed ALLI during hospitalization, all of them were males, had COVID-19 related pneumonia, and died within 24 hours of ALLI diagnosis. While 2 patients were presented with ALLI and found to have positive COVID-19, all of them were females, underwent successful thrombo-embolectomy, and had no deaths, however, one of them had recurrent ALLI which resulted in below knee amputation.

**Conclusion:** The prevalence of ALLI in patients infected with COVID-19 was 0.54%. We observed that patients with COVID-19 related pneumonia who develop ALLI during hospitalization had a high mortality.

**Keywords:** ALLI, COVID-19, KAUH

## Introduction

Since the identification of first case cluster in Wuhan, China, in December 2019, the COVID-19 pandemic has swept the entire world.<sup>1</sup> Jordan has more than 294,494 confirmed cases of COVID-19 and almost 3834 deaths since the first reported case of COVID-19 in Jordan on March 2, 2020. Although ALLI is a rare complication of COVID-19,<sup>2</sup> there have been increasing number of reports of peripheral arterial thrombosis in COVID-19 patients.<sup>3</sup> At our institution, we also observed that some COVID-19 patients had ALLI. Therefore, this study was performed to investigate the prevalence of ALLI among patients infected with COVID-19 and to review their characteristics and outcomes.

## Methods

This study was approved by IRB of Jordan university of science and technology (JUST) and KAUH. Patient informed consent was not required due to the de-identified data without breach of confidentiality, and that this study was conducted in accordance with the Declaration of Helsinki. It is a single-center study in which

Correspondence: Nabil Al-zoubi  
Department of Surgery, Faculty of  
Medicine, Jordan University of Science  
and Technology, P.O. Box 3030, Irbid,  
22110, Jordan  
Tel + 962 7955774637  
Email dr\_nabeil\_z3bi@yahoo.com

**Table 1** Patients Characteristics and Outcomes

Variable	Pt 1	Pt 2	Pt 3	Pt 4	Pt 5	P 6	P7
Demographic Data							
Age	62	55	60	67	75	75	65
Sex	Female	Female	Male	Male	Male	Male	Male
BMI kg/m <sup>2</sup>	33	34	33	36	29	24	23
Clinical Data							
Presentation	ALLI first	ALLI first	COVID-19 first	COVID-19 first	COVID-19 first	COVID-19 first	COVID-19 first
Site of occlusion	Distal SFA	CFA	Distal Aorta/iliac	Popliteal	CFA	SFA+PFA	SFA
Duration of Ischemia	10 days	2 days					
Duration of COVID-19 before ALLI			5 days	3 days	2 weeks	1 week	1 week
COVID-19-related pneumonia	No	No	Yes	Yes	Yes	Yes	Yes
Death within 24 Hours	No	No	Yes	Yes	Yes	Yes	Yes
Cause of death	–	–	Respiratory failure	Respiratory failure	Respiratory failure	Respiratory failure	Respiratory failure
Amputation	Yes	No					
DM	No	Yes	Yes	Yes	Yes	No	No
HTN	No	Yes	Yes	Yes	Yes	Yes	Yes
Hyperlipidemia	No	No	Yes	Yes	Yes	No	No
Smoking	Yes	Yes	Yes	No	Yes	Yes	Yes
Chronic Renal Disease	No	No	No	No	No	No	No
Chronic medications	Aspirin	Gabapentin Hydroxyurea Atorvastatin Thiazide Aspirin Insulin	Aspirin, insulin Isosorbide dinitrate Atorvastatin Atenolol Enalapril Carbamazepine Metformin	Enalapril Amlodipine Aspirin, Lansoprazole Atorvastatin Insulin	Atenolol, Enalapril, Aspirin, Metformin Glimipride	Allopurinol Atorvastatin, Furosemide, Clopidogrel Irbesartan	Aspirin Enalapril
Covid-19 symptoms	Asymptomatic	Asymptomatic	Loss of taste and smell, General fatigue Fever	Hypoxia	Cough Fever	Fever	Shortness of breath
			Hypoxia	Fever	Shortness of breath	Shortness of breath	Cough
Anticoagulation prior to ALLI	No	No	Prophylactic LMWH	Prophylactic LMWH	Prophylactic LMWH	Prophylactic LMWH	Prophylactic LMWH

(Continued)

**Table 1** (Continued).

Variable	Pt 1	Pt 2	Pt 3	Pt 4	Pt 5	P 6	P7
Laboratory Tests at time of ALLI diagnosis							
White-cell count	7.7	19.2	13.3	12.2	3.5	11.1	10.8
Total neutrophils	6822	12,400	11,438	11,102	3010	9271	2378
Total lymphocytes	431	5376	665	732	315	1217	788
Total monocytes	480	9600	1037	219	122	558	580
Platelet count	306	1430	332	352	190	244	233
Hemoglobin	14.1	9.7	14.5	11	11.2	13.6	11.3
Prothrombin time	15.3	18.2	19.2	15	14.5	13	16
Fibrinogen	None	None	None	None	None	None	None
D-dimer	>20	None	None	None	5.19	None	19
C-reactive protein	152.7	232.8	214.5	177	65	None	100
K	4.4	5.72	5.1	3.99	4	3.5	4.1
Na	137	134	132	137	138	135	139
Urea	9.1	12.8	11.4	4.7	8.2	31.7	4.8
Creatinine	118	274	55	75	71	161	133
Albumin	30.9	None	31.7	43	28.9	None	33
Total bilirubin	7.5	None	8.3	8.5	9.6	None	7.9
Direct bilirubin	3.8	None	6.2	2.8	5.6	None	2.3
Alkaline phosphatase	67	None	87	85	69	None	64
ALT	21.9	None	63.1	15.6	27.6	None	17.4
AST	31.7	None	106.7	19.9	43	None	41
Gamma GT	21	None	241	20	25	None	23

**Abbreviations:** Pt, patient; SFA, superficial femoral artery; CFA, common femoral artery; PFA, profunda femoris artery; ALLI first, acute lower limb ischemia first presentation; COVID-19 first, coronavirus disease first presentation; LMWH, low molecular weight heparin; BMI, body mass index; DM, diabetes mellitus; HTN, hypertension.

all patients with ALLI at KAUH who diagnosed with COVID-19 (during hospitalization or presented to emergency department) from November 1, 2020 to December 31, 2020 were retrospectively identified and reviewed. Demographic, clinical and laboratory data were analyzed. The diagnosed of COVID-19 was done

by nasopharyngeal swab using real-time reverse-transcriptase rRT-PCR. ALLI evaluations include history, physical examinations and investigations. The diagnosis of ALLI was done clinically and confirmed by imaging studies. CT-Angiogram (CTA) and arterial duplex U/S were performed to confirm the diagnosis and to plan for

intervention. Thrombo-prophylaxis was given to all COVID-19 in-patients according to our treatment guidelines. Therapeutic anti-coagulation was immediately started for all patients at the time of ALLI diagnosis. Thrombo-embolctomy was done through standard femoral approach.

## Results

A total number of 1300 COVID-19 patients were admitted to KAUH between November 1, 2020 and December 31, 2020. Seven patients (0.54%) had ALLI. Of them, 5 were males (71.4%) with a mean age of  $68 \pm 3$  years and 2 were females (28.6%) with a mean age of  $58 \pm 7$  years. Five patients (71.4%) were admitted as COVID-19 and developed ALLI during hospitalization, all of them were males, had COVID-19 related pneumonia, and died within 24 hours of ALLI diagnosis. While 2 patients were presented with ALLI and found to have positive COVID-19, all of them were females, underwent successful thrombo-embolctomy, and had no deaths, however, one of them had recurrent ALLI which resulted in below knee amputation. The overall mortality among admitted COVID-19 patients was 26.0% (338/1300). Of them, 5 patients (1.48%) had ALLI. Demographic and clinical data are presented in Tables 1 and 2.

## Discussion

ALLI is a sudden decrease in limb perfusion that threatens limb viability and represents a major vascular emergency.<sup>4</sup>

**Table 2** Baseline Characteristics in COVID-19 with ALLI and All COVID-19 Patients

	COVID-19 with ALLI (n=7)	All COVID-19 Patients (n=1300)
Age, m $\pm$ SD	65.56 $\pm$ 1.13	39.90 $\pm$ 16.59
Sex/males	5 (71.42%) males	585 (45.0%) males
BMI $\geq$ 30 kg/m <sup>2</sup>	4 (57.14%)	401 (30.85%)
DM	4 (57.14%)	160 (12.31%)
HTN	6 (85.71%)	273 (21.0%)
Hyperlipidemia	3 (42.86%)	112 (8.62%)
Smoking	6 (85.71%)	416 (32.0%)
Hypoxia	5 (71.43%)	338 (26.0%)

**Abbreviations:** m  $\pm$  SD, mean  $\pm$  slandered deviation; BMI, body mass index; DM, diabetes mellitus; HTN, hypertension.

It results from arterial embolus, in situ thrombosis, or bypass graft thrombosis.<sup>5</sup> The most common etiology of ALLI is an arterial embolism, the majority of the emboli originating in the heart.<sup>2</sup> It is one of the most common vascular surgery emergencies with significant rates of mortality and limb loss which have traditionally been reported to be as high as 20–40% and 12–50%, respectively.<sup>5</sup>

Coronavirus is a single-stranded, enveloped RNA virus with a helical capsid.<sup>2</sup> It was first considered to cause solely respiratory dysfunction; however, various clinical presentations have shown that COVID-19 is a systemic disease, not restricted to the lungs.<sup>6</sup> Many patients suffered a number of other problems, such as renal failure, cardiac arrhythmia, myocarditis and coagulative disorders.<sup>7</sup> Thrombotic complications secondary to hypercoagulable state have recently been reported in which pulmonary embolism (PE) was the commonest reported event in patients with COVID-19 on intensive care units.<sup>3</sup> Although arterial thrombosis involving upper and lower extremity is being noted among COVID-19 patients, multiple retrospective analyses have demonstrated incidents of thrombosis ranging from 12% to 31% with a minority of these events are arterial.<sup>3,8</sup> Some studies demonstrated that arterial thrombosis accounts for about 4% of thromboembolic complications due to COVID-19 infection.<sup>9</sup> Any arterial segment can be involved in this condition, there have been reports of arterial thrombosis of brachial artery, radial artery, aorta, iliac and femoral arteries, superior mesenteric artery and even prosthetic vascular grafts as well.<sup>3</sup>

The pathophysiology behind this hypercoagulable state is multifactorial. First, COVID-19 directly attacks vascular endothelial cells causing endothelial damage and activating the coagulation cascade which leads to vessels thrombosis in peripheral arteries and the aorta, and causes major vascular events such as acute arterial ischemia.<sup>10,11</sup> Second, the association of COVID-19 with increased levels of pro-inflammatory cytokines (IL-2, IL-6, IL-7, G-CSF, TNF, IP-10, MCP1, MIP1- $\alpha$ , etc.) in patients with a severe disease, which leads to cytokine release syndrome (CRS).<sup>2</sup> Third, the immobility and hypoxia of critically ill patients.

In Italy, an observational study was performed to investigate the incidence and outcomes of 20 patients with acute limb ischemia which showed that the incidence of acute limb ischemia to be greater in the previous few months of 2020 compared with 2019, and

they attributed the higher incidence to the increase in cases caused by thromboembolic disease associated with COVID-19.<sup>12</sup>

In our study, we observed that increased number of patients with ALLI compared to the same period (from November 1, 2019 to December 31, 2019) in the past year (1 patient vs 7 patients) which is 7-fold increase. Moreover, the number of cases of ALLI in the two months just prior to COVID-19 infection hospitalization was also 1 case in 2 months. Although ALLI is a well-known complication in critically ill patients, we noticed an increase in ALLI among COVID-19 patients in the ICUs (two cases in the last year compared to 5 cases in 2 months). All these data suggest the existence of a hypercoagulable state in patients with COVID-19 disease.<sup>13</sup>

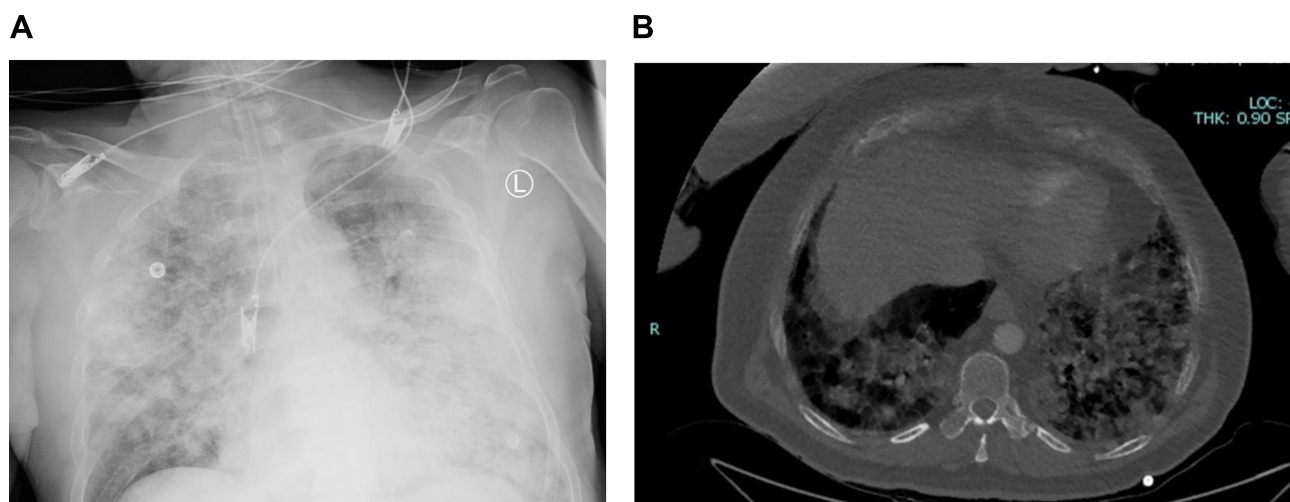
During the two months of this study, 7 patients (0.54%) had concomitant ALLI and COVID-19 infection **Figure 1**. Two patients (28.57%) presented to emergency department with ALLI and found to have asymptomatic COVID-19 infection, while 5 patients (71.43%) developed ALLI during their admission due to COVID-19. The two patients with asymptomatic COVID-19 infection underwent successful surgical thrombo-embolectomy without mortality through femoral approach. One of them had recurrent ALLI to the same limb after 45 days of discharge and unfortunately she ended with below knee amputation. Arterial thrombotic events causing ALLI associated with COVID-19 infection are mainly located within micro-circulation vessels, with associated high rate of recurrent

thrombosis. Therefore, Mietto et al suggested a more aggressive regimen of prompt and full anticoagulation with intravenous UFH and selective intra-arterial thrombolysis.<sup>14</sup> In the other hand, the five patients who developed ALLI during hospitalization had similarities. First, all of them had COVID-19 related pneumonia **Figure 2**. Second, they were managed in the critical care units. Third, they were all male had the traditional cardiovascular risk factors. Forth, they were unfit for revascularization surgery. Finally, all of them died within 24 hours of ALLI diagnosis. Woehl et al in their 4 case series underline the fact that patients pre-disposed to endothelial lesions (hypertension, male sex, smoking, diabetes) could be more prone to infection of the endothelium induced by the virus.<sup>13</sup> This could explain the presence of traditional cardiovascular risk factors for atherosclerosis in all of our patients. Our result suggests a high mortality in COVID-19 related pneumonia which occurred within 24 hours of ALLI diagnosis. This confirms the fact that the prognosis of patients hospitalized with COVID-19 disease is often determined by the extent of pulmonary lesions and vascular complications can greatly affect outcome.<sup>13</sup>

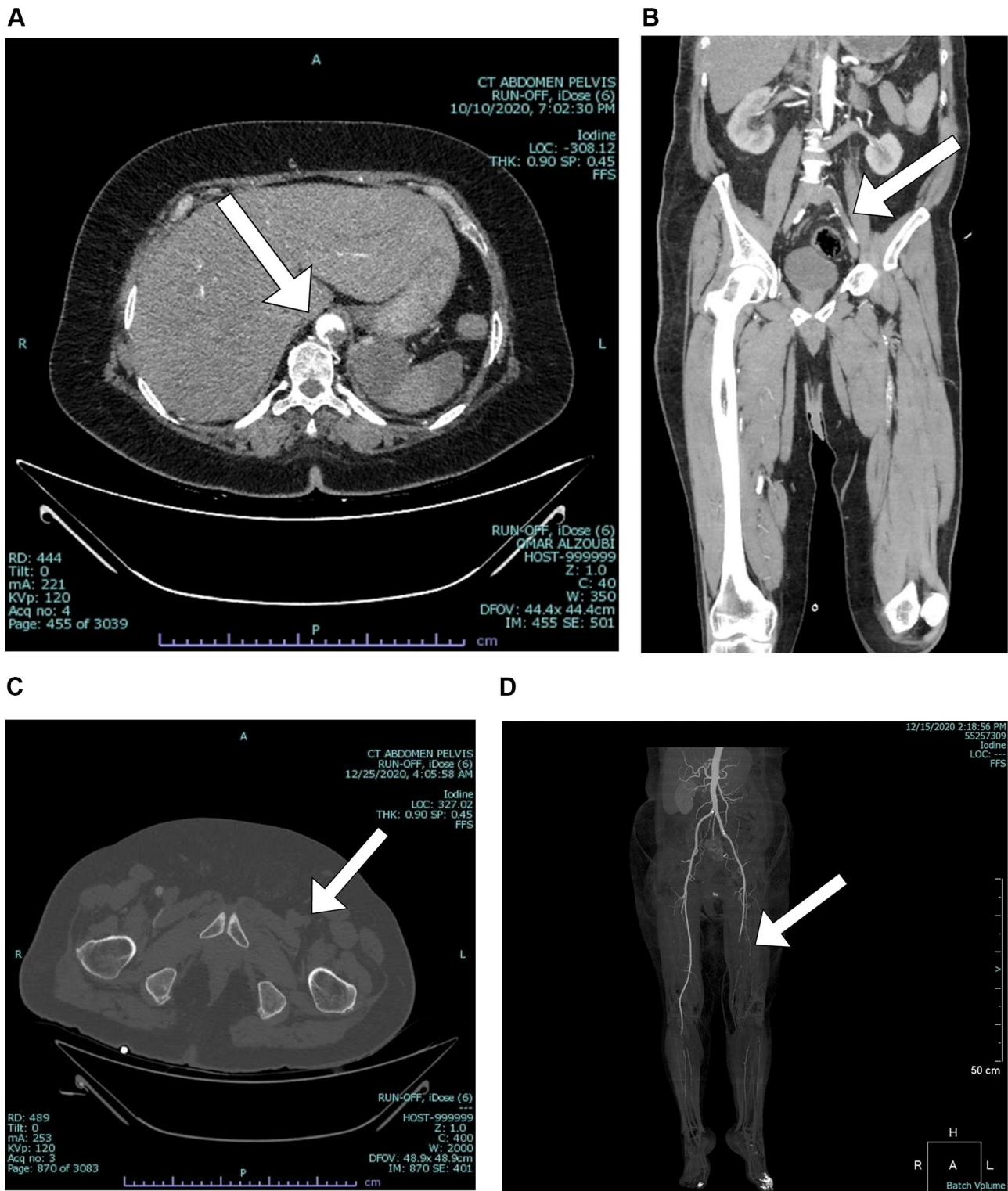
This study has limitations regarding the retrospective nature and the small number of patients included. Further studies are needed to explore the relationship between COVID-19 infection and ALLI.

## Conclusions

The prevalence of ALLI in patients infected with COVID-19 was 0.54%. We observed that patients with COVID-19



**Figure 1** COVID-19 related pneumonia. (A) x-ray. (B) CT-scan.



**Figure 2** CT-Angiograms show different arterial segments involved in ALLI. (A) Aorta. (B) Aorto-iliac. (C) Common femoral artery. (D) Distal superficial femoral artery.

related pneumonia who develop ALLI have a high mortality. Further studies are needed to explore the relationship between COVID-19 infection and ALLI.

### Author Contributions

All authors contributed to data analysis, drafting or revising the article, have agreed on the journal to which the article will

be submitted, gave final approval of the version to be published, and agree to be accountable for all aspects of the work.

## Disclosure

The authors report no conflicts of interest in this work.

## References

- Alajmi J, Jeremijenko AM, Abraham JC, et al. COVID-19 infection among healthcare workers in a national healthcare system: the Qatar experience. *Int J Infect Dis.* 2020;100:386–389. doi:10.1016/j.ijid.2020.09.027
- Hasan SA, Haque A, Nazir F. Acute limb ischemia: a rare complication of COVID-19. *Cureus.* 2020;12(11):e1148810.
- Veerasuri S, Kulkarni SR, Wilson WR, Paravastu SCV. Bilateral acute lower limb ischemia secondary to COVID-19. *Vasc Endovascular Surg.* 2020;55(2):196–199. doi:10.1177/1538574420954301
- Olinic DM, Stanek A, Tataru DA, Homorodean C, Olinic M. Acute limb ischemia: an update on diagnosis and management. *J Clin Med.* 2019;8(8):1215. doi:10.3390/jcm8081215
- Baril DT, Patel VI, Judelson DR, et al. Outcomes of lower extremity bypass performed for acute limb ischemia. *J Vasc Surg.* 2013;58(4):949–956. doi:10.1016/j.jvs.2013.04.036
- Essa RA, Ahmed SK. Case report: acute lower limb ischemia in a recovered COVID-19 patient. *F1000Research.* 2020;9:1253. doi:10.12688/f1000research.26603.1
- Vacirca A, Vacirca A, Faggioli G, et al. Unheralded lower limb threatening ischemia in a COVID-19 patient. *Int J Infect Dis.* 2020;96:590–592. doi:10.1016/j.ijid.2020.05.060
- Mecl AV, Paz V, Navas ELSY, Baig I. A case of COVID-19-associated acute limb ischemia. *Chest J.* 2020;8:520.
- Bozzani A, Arici V, Tavazzi G, et al. Acute arterial and deep venous thromboembolism in COVID-19 patients: risk factors and personalized therapy. *Surgery.* 2020;168(6):987–992. doi:10.1016/j.surg.2020.09.009
- Anwar S, Acharya S, Shabih S, Khabut A. Acute limb ischemia in COVID-19 disease: a mysterious coagulopathy. *Cureus.* 2020;12(7):9167.
- Canas EG, Gaibar AG, Lorenzo LR. Acute peripheral arterial thrombosis in COVID-19. Role of endothelial inflammation. *Br J Surg.* 2020;107(10):444–445. doi:10.1002/bjs.11904
- Ahmad H, Shubair SM, Kruer J, Hatoum CA. Acute lower-extremity ischemia in a patient with COVID-19. *Am J Case Rep.* 2020;21:928471.
- Woehl B, Lawson B, Jambert L, Tusch J, Ghassani A, Hamade A. 4 Cases of aortic thrombosis in patients with COVID-19. *Case Rep.* 2020;9(2):1397–1401.
- Mietto C, Salice V, Ferraris M, et al. Acute lower limb ischemia as clinical presentation of COVID-19 Infection. *Ann Vasc Surg.* 2020;69:80–84. doi:10.1016/j.avsg.2020.08.004

International Journal of General Medicine

Dovepress

### Publish your work in this journal

The International Journal of General Medicine is an international, peer-reviewed open-access journal that focuses on general and internal medicine, pathogenesis, epidemiology, diagnosis, monitoring and treatment protocols. The journal is characterized by the rapid reporting of reviews, original research and clinical studies

across all disease areas. The manuscript management system is completely online and includes a very quick and fair peer-review system, which is all easy to use. Visit <http://www.dovepress.com/testimonials.php> to read real quotes from published authors.

Submit your manuscript here: <https://www.dovepress.com/international-journal-of-general-medicine-journal>