

Case Report

Thoracic Intradural Extramedullary Capillary Hemangioma

David C. Abdullah, Karthikram Raghuram, C. Douglas Phillips, John A. Jane, Jr., and Bradley Miller

Summary: We report a case of a thoracic intradural extramedullary capillary hemangioma. The MR imaging appearance was nonspecific for this lesion, and it could not be distinguished from more common spinal intradural extramedullary lesions. The presence of subtly enlarged abnormal vessels on contrast MR images should, however, lead one to consider a vascular mass and order preoperative spinal arteriography.

This case report describes a rare capillary hemangioma of the spinal canal with enlarged draining veins. Our review of the literature describing capillary hemangiomas did not reveal any reference to enlarged draining veins. The MR imaging characteristics of vascular spinal tumors overlap considerably and the prospective observation of such veins may help limit the differential diagnosis and affect management.

Case Report

A 32-year-old female patient presented with a 7-month history of progressive lower back pain and lower extremity weakness (left more than right) as well as a T9 sensory level. The patient had recently developed difficulty with walking. On physical examination, she demonstrated weakness in the hip extensors and knee flexors (left more than right) and a left Babinski sign. Left-side reflexes were decreased. The patient had been initially examined at a hospital outside the United States with MR imaging, which was reported as showing an extramedullary mass lesion, likely representing a meningioma (Fig 1A-C). On the basis of this report, laminectomy was performed at T9–T10. On opening the dura, the neurosurgeon discovered enlarged vessels and a very vascular, reddish-brown lesion from which blood was aspirated with a tuberculin syringe. At this point, the surgeon elected to terminate the procedure in favor of obtaining an arteriogram with preoperative embolization, because the surgical findings were consistent with a vascular malformation.

The patient underwent a second MR imaging study and angiography on the 2nd postoperative day. Pre- and postcontrast MR imaging revealed a well-defined lesion in the left dorsal portion of the spinal canal at T10 that measured $1.7 \times 1.4 \times 1.0$ cm. The mass was sharply demarcated from the spinal cord and caused a focal widening of the spinal subarachnoid space at its inferior aspect. This lesion was isointense relative to spinal cord on T1-weighted images and hyperintense on T2-

weighted images and demonstrated intense contrast enhancement (Fig 1D-G). Spinal cord compression and edema was evident. On the basis of these findings, the mass was determined to be an intradural extramedullary lesion. The differential diagnosis was schwannoma and neurofibroma, meningioma, hemangioblastoma, or paraganglioma. On initial examination, subtle enhancing dilated serpentine venous structures coursing cephalad from the lesion on the dorsal surface of the spinal cord were not appreciated (Fig 1F and G).

The same day, the patient underwent spinal arteriography that demonstrated a lobular hypervascular tumor at T10 with arteriovenous shunting. The tumor enhanced rapidly from the peripheral to central area, and tumor stain persisted into the late venous phase. The T11 intercostal artery predominantly supplied the lesion, and early venous drainage occurred cranially via enlarged dorsal coronal perimedullary veins (Fig 2A and B). Incidentally present was a posterior spinal artery feeder from the left T11 intercostal artery, which gave off a large radiculomedullary branch (Fig 2A). The presence of this vessel supplying the spinal cord prevented preoperative embolization. The patient returned to surgery, where the tumor was successfully excised in toto with insignificant blood loss. The lesion was inseparable from a solitary nerve root that was sacrificed during surgery. The tumor was easily separable from the spinal cord. Surgical excision was facilitated by the arteriogram that revealed the anatomy.

Histopathologic analysis of the lesion revealed a multilobular vascular neoplasm, compatible with diagnosis of cellular capillary hemangioma (Fig 3).

On follow-up, over the course of several weeks, the patient gradually regained lower extremity strength, sensation, and reflexes.

Postoperative MR imaging confirmed complete removal of the tumor. Residual cord edema was identified on the T2-weighted image. Postcontrast study showed enhancing dura at the site of surgery (Fig 4A-C). No residual tumor was identified.

Discussion

The differential diagnosis for enhancing intradural extramedullary lesions in the spinal canal is long and includes meningioma, hemangioma, schwannoma, hemangioblastoma, and paraganglioma. The identification of draining veins on MR images may help in differentiating the hypervascular lesions such as hemangioma, hemangioblastoma, and paraganglioma from the other nonhypervascular lesions and suggest the need for preoperative angiography and embolization.

Capillary hemangiomas, which are uncommon in the spinal canal (1–3), contain capillary networks surrounded by collagenous stroma without hemosiderin deposition. Our MR imaging findings are similar to those of prior case reports (4–10) of intraspinal capillary hemangioma. To the best of our knowledge, the presence of enlarged draining perimedullary veins has not been reported previously. They may have been

Received June 5, 2003; accepted after revision December 8.

From the Division of Neuroradiology (D.C.A., K.R., C.D.P.), Department of Neurosurgery (J.A.J., Jr.), and Division of Neuro-pathology, Department of Pathology (B.M.), University of Virginia Health System, Charlottesville, VA.

Address all correspondence to Karthikram Raghuram, MD, Department of Neuroradiology, University of Virginia Health System, P.O. Box 800170, Charlottesville, VA 22903.

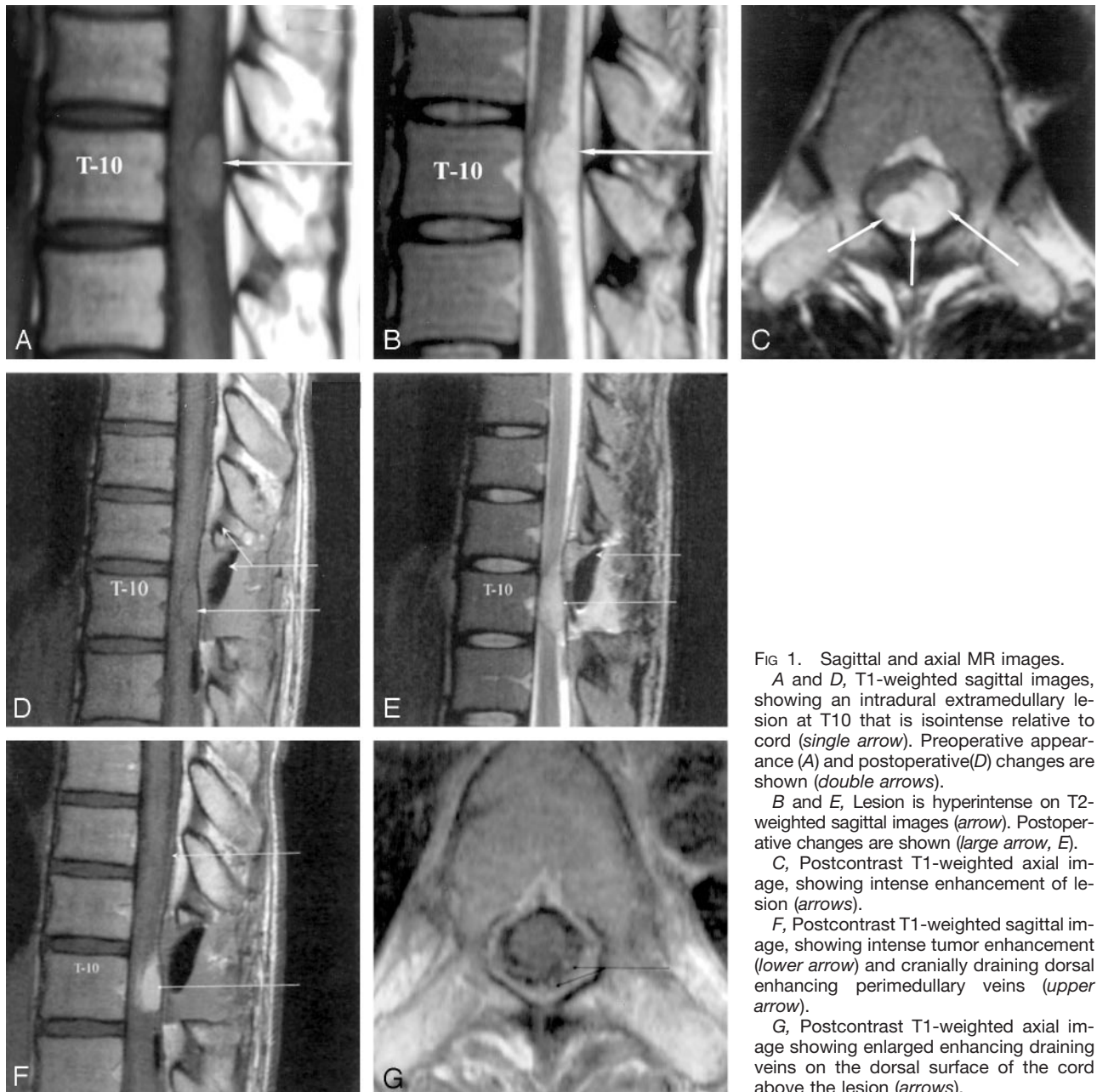


FIG 1. Sagittal and axial MR images.

A and D, T1-weighted sagittal images, showing an intradural extramedullary lesion at T10 that is isointense relative to cord (single arrow). Preoperative appearance (A) and postoperative (D) changes are shown (double arrows).

B and E, Lesion is hyperintense on T2-weighted sagittal images (arrow). Postoperative changes are shown (large arrow, E).

C, Postcontrast T1-weighted axial image, showing intense enhancement of lesion (arrows).

F, Postcontrast T1-weighted sagittal image, showing intense tumor enhancement (lower arrow) and cranially draining dorsal enhancing perimedullary veins (upper arrow).

G, Postcontrast T1-weighted axial image showing enlarged enhancing draining veins on the dorsal surface of the cord above the lesion (arrows).

overlooked on initial assessment as in this case. These enlarged draining veins would also be expected in other vascular lesions such as hemangioblastoma or paraganglioma. This lesion was hypervascular at angiography and demonstrated an early tumorlike blush with inhomogeneous peripheral enhancement that rapidly became more intense and homogeneous as the hemangioma filled in from the periphery to the center. The tumor stain persisted throughout the venous phase. Also noted was rapid opacification of perimedullary coronal plexus of veins dorsal to the spinal cord above the lesion.

When enlarged draining veins are associated with an intraspinal mass on MR images, the possibility of an extremely vascular tumor or vascular malformation should be entertained, and preoperative spinal

arteriography or contrast-enhanced MR angiography should be considered. In addition, preoperative embolization may aid in the surgical resection of these vascular lesions, although in our case this was not technically possible.

References

1. Cosgrove GR, Bertrand G, Fontaine S, et al. Cavernous angiomas of the spinal cord. *J Neurosurg* 1988;68:31-36
2. Heimberger K, Schnaberth G, Koos W, et al. Spinal cavernous hemangiomas (intradural-extramedullary) underlying repeated subarachnoid haemorrhage. *J Neurol* 1982;226:289-293
3. Richardson RR, Cerullo LJ. Spinal epidural cavernous hemangioma. *Surg Neurol* 1979;12:266-268
4. Hanakita J, Suwa H, Nagayasu S, Suzuki H. Capillary hemangioma in the cauda equina: neuroradiological findings. *Neuroradiology* 1991;33:458-461

FIG 2. Spinal arteriogram.

A, Early arterial phase image, showing a hypervascular nodule (*large arrowhead*) that demonstrates predominantly peripheral lobular inhomogeneous enhancement. Feeder from the left T11 intercostal artery (*large single arrow*), radiculomedullary feeder to the cord (*single small arrow*), and draining veins (*double arrows*) are seen.

B, Late arterial phase image, showing that the tumor nodule enhances more homogeneously (*arrow*).

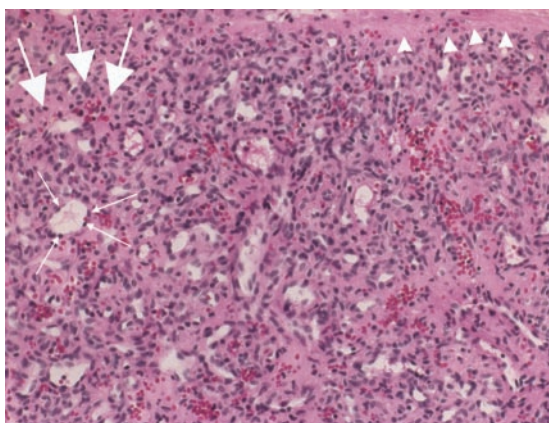
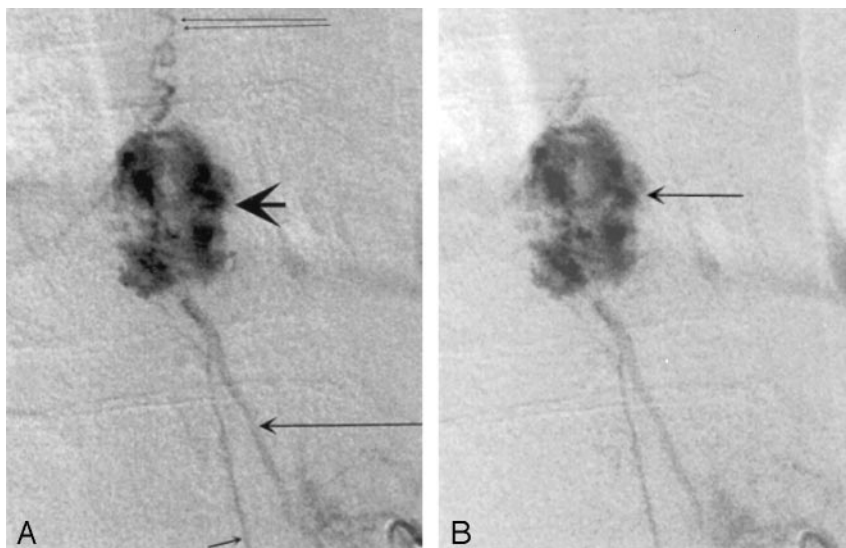


FIG 3. Hematoxylin and eosin-stained microscopic image (Ocular 10 \times , Stage 40 \times). A, Stromal cells (*large arrows*) and endothelial cells (*small arrows*) lining the capillary spaces. *Arrowheads* at the top right point to normal neural tissue from the nerve root to which the tumor was attached.

5. Shin JH, Lee HK, Jeon SR, Park SH. **Spinal intradural capillary hemangioma: MR findings.** *AJNR Am J Neuroradiol* 2000;21:954–956
6. Badinand B, Morel C, Kopp N, et al. **Dumbbell shaped epidural capillary hemangioma.** *AJNR Am J Neuroradiol* 2003;24:190–192
7. Holtzman RN, Brisson PM, Pearl RE, Gruber ML. **Lobular capillary hemangioma of the cauda equina: case report.** *J Neurosurg* 1999;90:239–241
8. Hida K, Tada M, Iwasaki Y, Abe H. **Intramedullary disseminated capillary hemangioma with localized spinal cord swelling: case report.** *Neurosurgery* 1993;33:1099–1101
9. Mawk JR, Leibrock LG, McComb RD, Trembath EJ. **Metameric capillary hemangioma producing complete myelographic block in an infant.** *J Neurosurg* 1987;67:456–459
10. Burrows PE, Mulliken JB, Fellows KE, Strand RD. **Childhood hemangiomas and vascular malformations: angiographic differentiation.** *AJR Am J Roentgenol* 1983;141:483–488

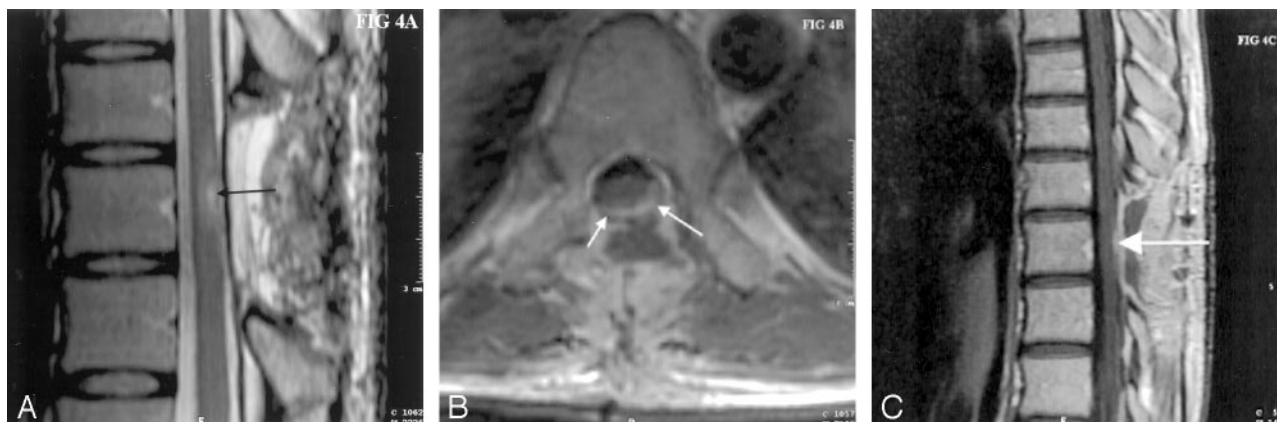

FIG 4. Postoperative MR images.

A, Sagittal T2-weighted image showing edema (*arrow*) in the spinal cord at the site of tumor resection.

B, Axial postcontrast image, showing enhancing dura (*arrow*) at the site of surgery, but no residual tumor.

C, Sagittal T1-weighted postcontrast image, showing enhancing dura (*arrow*) at the site of surgery, but no residual tumor.