

Type of Gradient Recalled-Echo Sequence Results in Size and Number Change of Cerebral Microbleeds

Microbleeds (MBs) are thought to be clusters of hemosiderin-containing macrophages and are more commonly observed in hypertensive microangiopathy (lacunar infarct or intracerebral hemorrhage), cerebral amyloid angiopathy, or cerebral autosomal dominant arteriopathy with subcortical infarcts and leukoencephalopathy (CADASIL) but not exclusively in them.¹ Although they are usually defined as the focal signal intensity loss of less than 5 or 10 mm, the conditions of gradient recalled-echo (GRE) varied among numerous previous studies about MBs (ie, TEs, were from 15 ms to 50 ms).^{2,3} We found that MBs are influenced in size and number by lengthening TE of GRE, as seen in the following case.

The GRE (TR, 700 ms; TE, 17 ms; flip angle, 20°) of an elderly hypertensive woman with right thalamic hemorrhage and multiple lacunar infarcts showed numerous MBs in the basal ganglia, thalami, pons, cerebellum, and cerebral white matter (Fig 1). The sizes and numbers of these MBs increased as the TE was lengthened (Fig 1). The numbers of MBs in this figure were 12 (TE, 10 ms), 14 (TE, 17 ms), and 20 (TE, 23 ms). The average diameter of MBs, which was 2.6 mm with a TE of 10 ms, became 3.8 (TE, 17 ms) and 4.5 mm (TE, 23 ms).

In general, the T2*-based signal intensity loss increases mainly by lengthening TE and decreasing the flip angle.⁴ To the best of our knowledge, no one has reported how the appearance of MBs changes

with these parameters. As we have shown, MBs changed considerably in size and number as TE was prolonged. Therefore, the MR imaging parameter must be taken into account, especially when discussing the number or size of MBs.^{2,3} GRE with longer TE raises sensitivity of MBs, but the pathophysiological significance is to be clarified in the future.

References

1. Koennecke HC. **Cerebral microbleeds on MR imaging: Prevalence, associations, and potential clinical implications.** *Neurology* 2006;66:165–71
2. Fazekas F, Kleinert R, Roob G, et al. **Histopathologic analysis of foci of signal intensity loss on gradient-echo T2*-weighted images in patients with spontaneous intracerebral hemorrhage: evidence of microangiopathy-related microbleeds.** *AJNR Am J Neuroradiol* 1999;20:637–42
3. Greenberg SM, Eng JA, Ning MM, et al. **Hemorrhage burden predicts recurrent intracerebral hemorrhage after lobar hemorrhage.** *Stroke* 2004;35:1415–20
4. Mulhern RV. **Fast imaging principles.** In: Atlas SW, ed. *MR Imaging of the Brain and Spine*, 3rd ed. Philadelphia: Lippincott Williams & Wilkins; 2002:176–78

S. Tatsumi

T. Ayaki

M. Shinohara

T. Yamamoto

Department of Neurology

Saiseikai Nakatsu Hospital and Medical Center

Osaka, Japan

DOI 10.3174/ajnr.A0908

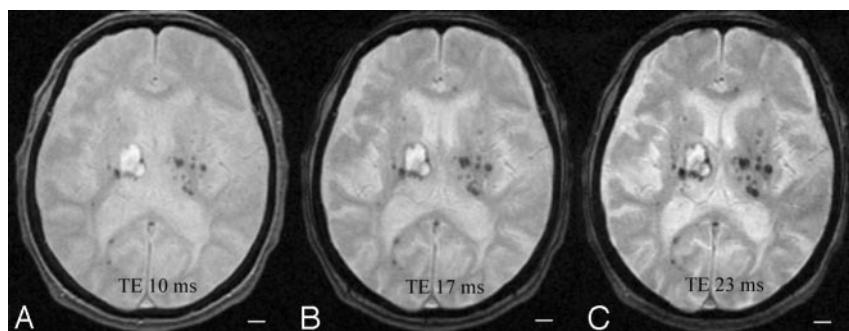


Fig 1. The size and number of microbleeds increased by lengthening TE on GRE. Scale bar, 10 mm.