

EUS-through-the-needle microbiopsy forceps in pancreatic cystic lesions: A systematic review

Vasile Daniel Balaban^{1,2}, Irina M. Cazacu^{3,4}, Larisa Pinte⁵, Mariana Jinga^{1,2}, Manoop S. Bhutani⁴, Adrian Saftoiu³

¹Internal Medicine and Gastroenterology Clinic, "Carol Davila" University of Medicine and Pharmacy, Craiova, Romania; ²Department of Gastroenterology, "Dr. Carol Davila" Central Military Emergency University Hospital, Bucharest, Romania; ³Department of Gastroenterology, Research Center of Gastroenterology and Hepatology, University of Medicine and Pharmacy, Craiova, Romania; ⁴Department of Gastroenterology, Hepatology and Nutrition, MD Anderson Cancer Center, University of Texas, Houston, Texas, USA; ⁵Department of Internal Medicine, Colentina Clinical Hospital, Bucharest, Romania

ABSTRACT

Pancreatic cystic lesions (PCLs) are being increasingly encountered in clinical practice, and sometimes, they can represent a diagnostic challenge. Recently, a through-the-needle micro forceps biopsy (MFB) device was introduced in the endosonography practice to facilitate EUS-guided sampling of PCLs. The aim was to perform a systematic review of studies evaluating the technical aspects, safety, and efficacy of the EUS-guided MFB for PCLs. A literature search was performed in three major databases, PubMed, Embase, and Web of Science in September 2019 using the search terms: "through-the-needle," "biopsy forceps," "microforceps," "endoscopic ultrasound," and "endosonography." Case reports and case series with <10 patients were excluded from the analysis. Altogether nine studies reporting on 463 patients were included in our systematic review. The mean age of the patients was 68.3 years, with a slight female predominance (60.9%). Most of the cysts were located in the body/tail of the pancreas (61.2%), with an overall mean size of 33 mm. The technical success of EUS-guided MFB was reported in 98.5%. The tissue acquisition yield reported was 88.2%, and the diagnostic accuracy was 68.6%. Adverse events were reported in 9.7%. EUS-guided MFB is technically feasible, safe, and has a high diagnostic accuracy for PCLs.

Key words: diagnostic accuracy, EUS, microbiopsy forceps, pancreatic cyst

INTRODUCTION

Pancreatic cystic lesions (PCLs) are being increasingly encountered in clinical practice due to the widespread use of high-resolution imaging. The prevalence of pancreatic cysts detected incidentally varies from 2% on computed tomography scans^[1] to 9.3% on 3T magnetic resonance imagings of the abdomen.^[2]

The wide spectrum of PCLs includes benign and malignant lesions, and therefore, an accurate diagnosis is mandatory to decide the best management. In clinical practice, the challenge is to differentiate between nonneoplastic and neoplastic PCLs and to determine whether one should undergo either

This is an open access journal, and articles are distributed under the terms of the Creative Commons Attribution-NonCommercial-ShareAlike 4.0 License, which allows others to remix, tweak, and build upon the work non-commercially, as long as appropriate credit is given and the new creations are licensed under the identical terms.

For reprints contact: WKHLRPMedknow_reprints@wolterskluwer.com

How to cite this article: Balaban VD, Cazacu IM, Pinte L, Jinga M, Bhutani MS, Saftoiu A. EUS-through-the-needle microbiopsy forceps in pancreatic cystic lesions: A systematic review. *Endosc Ultrasound* 2021;10:19-24.

Access this article online

Quick Response Code:



Website:

www.eusjournal.com

DOI:

10.4103/eus.eus_23_20

Address for correspondence

Dr. Adrian Saftoiu, 66 1 Mai Blvd, Craiova 200638, Romania. E-mail: adriansaftoiu@gmail.com

Received: 2019-12-06; **Accepted:** 2020-04-09; **Published Online:** 2020-07-01

surveillance or surgery. This carries the risk of either sending a patient to unnecessary surgery or missing the opportunity to resect a potentially malignant lesion. Several guidelines have been published over the years, some of them favoring surgery, others being more prudent, and balancing towards surveillance.¹³⁻⁶¹ Analysis of management decisions, according to these guidelines, has shown significant deficits.

Until recent years, EUS-FNA of PCLs with cyst fluid analysis was used for management decisions, but this has proven suboptimal performance due to scant cellularity and poor diagnostic accuracy of biomarkers.

In the last years, though, there has been a growing interest for tissue acquisition in PCLs, and diagnosis has evolved from cyst fluid sampling to histological criteria by means of needle-based confocal endomicroscopy, through-the-needle cystoscopy, and through-the-needle intracystic biopsy.¹⁷¹ Among these techniques, cyst wall sampling using through-the-needle micro biopsy (TTNB) forceps has gained the most interest. The Moray micro forceps biopsy (MFB) device (US Endoscopy, Ohio, US) is a disposable tissue acquisition device that can be passed through a 19G needle and allows for tissue sampling of the cyst wall.

Our aim was to review the current data regarding TTNB in PCLs, with respect to feasibility, diagnostic accuracy, and safety.

METHODS

The literature search was performed in September 2019 in three major databases: PubMed, Embase, and Web of Science. The search terms used were: “endoscopic ultrasound”/”eus” and “biopsy forceps” or “microforceps.” No search restrictions were applied. We also searched abstracts from scientific meetings.

The initial search yielded 386 articles (Embase 110, PubMed 202, Web of Science 74).

After title and abstract screening and removing duplicates, 48 records remained for a detailed assessment of eligibility.

After excluding review, case reports, case series with <10 patients, articles without available full-text and

articles reporting duplicate data, a total of 9 articles, comprising 463 patients (range: 27–114), were enrolled in the systematic review [Figure 1].

Definitions of performance and outcome measures for the TTNB forceps were reviewed for all articles. *Technical success* was defined as the successful puncture of the lesion, mounting the forceps, and performing the biopsy. *Tissue acquisition yield* was reported as the ability to obtain at least one tissue sample. *Diagnostic accuracy* was set against the correct final diagnosis as defined by surgery or a multidisciplinary board based on cross section imaging, EUS characterization, cyst fluid markers and/or cytology.

Adverse events were reported according to the American Society for Gastrointestinal Endoscopy severity criteria, as defined in Cotton *et al.*¹⁸¹

RESULTS

Altogether nine studies¹⁹⁻¹⁷¹ (9 retrospective, 1 prospective) reporting on 463 patients with 464 cysts (there was one patient with two lesions punctured in the study by Hrad¹⁷¹) were included in our systematic review. The mean age of the patients was 68.3 years, with a slight female predominance (60.9%). The size of the PCLs ranged from 11 to 88 mm (mean 33 mm) and most of them were located in the body-tail of the pancreas (61.2%) [Table 1].

The most frequently used needle was Expect (Boston Scientific, Marlborough, Mass, USA), but punctures were also performed with EchoTip (Cook Medical, Bloomington, IN, USA) and SharkCore (Medtronic, Dublin, Ireland). All samplings were done using Moray MFB device (US Endoscopy, US).

Technical success of EUS-guided MFB device was reported in 456/463 cases (98.5%; 95% confidence interval [CI]: 89%–100%). The main reasons for technical difficulties were the inability to access the cyst, while the echoendoscope was fully flexed, difficulty to push the instrument through the needle, and difficulty to visualize the forceps on EUS scan. The tissue acquisition yield reported was 367/416 (88.2%; 95% CI: 79%–97%) [Table 2].

EUS-guided MFB was able to establish the correct final diagnosis in 312 PCLs out of 455 (diagnostic accuracy 68.6%; 95% CI, 61%–76%).

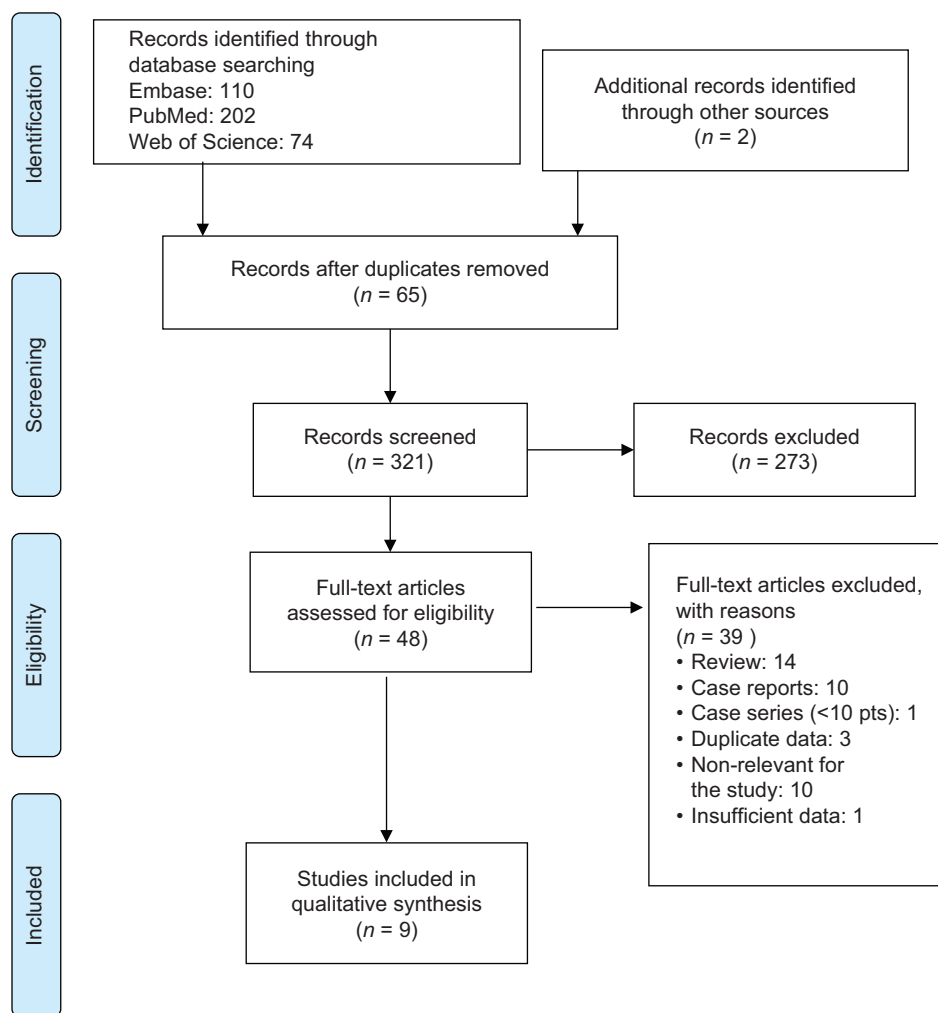


Figure 1. PRISMA 2009 flow diagram

Table 1. Patient demographics and pancreatic cystic lesions characteristics

	Study design	Number patient	Age (mean)	Sex (% female)	Cyst size (mean mm)	Cyst location (head* + istmus/body + tail)
Basar <i>et al.</i> , 2018 ^[12]	Retrospective	42	69	23/42	28.2	16/26 (38.1/61.9%)
Barresi <i>et al.</i> , 2018 ^[13]	Retrospective	56	57.5	39/56	38.6	27/29 (48.2/51.8%)
Zhang <i>et al.</i> , 2018 ^[14]	Retrospective	48	69.6	25/48	31	15/33 (31.2/68.8%)
Mittal <i>et al.</i> , 2018 ^[15]	Retrospective	27	65	16/27	37.8	14/13 (51.9/48.1%)
Kovacevic <i>et al.</i> , 2018 ^[16]	Retrospective	31	69.9	15/31	33.5	N/A
Hrad <i>et al.</i> , 2018 ^[17]	Retrospective	37	71	27/37	30.6	13/25 (34.2/65.8%)
Yang <i>et al.</i> , 2018 ^[10]	Retrospective	47	66.2	26/47	30.7	22/25 (46.8/53.2%)
Yang <i>et al.</i> , 2019 ^[11]	Prospective	114	64.2	64/114	35	39/71 (34.2/62.3%) 4 not specified (3.5%)
Crinò <i>et al.</i> , 2019 ^[9]	Retrospective	61	50.2	47/61	40.7	18/43 (29.5/70.5%)
Total		463	68.3	282/463 (60.9%)	33	164/265 (37.9/61.2%)

*Including uncinate process. N/A: Not available

Forty-five patients (9.7%) having 46 adverse events were reported among the studies: abdominal pain-4, intracystic hemorrhage-26, peripancreatic bleeding-1, mild acute pancreatitis-11, postprocedural infection-3, and atrial fibrillation after procedure-1 case.

DISCUSSION

Over the time, diagnosis of PCLs evolved from EUS-based morphological assessment, to cyst fluid analysis by means of FNA (cellularity, amylase, glucose,

Table 2. Feasibility, diagnostic accuracy and safety of through-the-needle microbiopsy

	Needle used	Tehncial succes	Tissue acquisition yield	Diagnostic accuracy	AE	AE (details)
Basar <i>et al.</i> , 2018 ^[12]	19G flex	42/42	38/42	15/42	2	Self-limited ICB -1 Mild abdominal pain - 1
Barresi <i>et al.</i> , 2018 ^[13]	19G EchoTip, \19G Expect and Expect flex and 19G SharkCore	56/56	52/56	47/56	9	Self-limited ICB - 6 Abdominal pain - 2 Both ICB and abdominal pain -1
Zhang <i>et al.</i> , 2018 ^[14]	19G FNA needle	48/48	N/A	36/48	0	-
Mittal <i>et al.</i> , 2018 ^[15]	19G Expect or EchoTip Ultra	27/27	24/27	21/27	0	-
Kovacevic <i>et al.</i> , 2018 ^[16]	19G Expect Flex	27/31	22/31	12/22	3	Mild AP - 1 Mild infection - 2
Hrad <i>et al.</i> , 2018 ^[17]	19G needle	38/38	35/38	35/38	2	AP - 1 Atrial fibrillation - 1
Yang <i>et al.</i> , 2018 ^[10]	19G EchoTip Ultra	46/47	40/47	26/47	2	self-limited ICB - 1 AP - 1
Yang <i>et al.</i> , 2019 ^[11]	19G FNA needle	111/114	95/114	75/114	13	self-limited ICB - 7 AP - 6
Crinò <i>et al.</i> , 2019 ^[9]	19G expect	61/61	61/61	45/61	14	self-limited ICB -10 mild AP -2 peripancreatic bleed45ing - 1 transitory fever - 1
Total		456/463 (98.5%)	367/416 (88.2%)	312/455 (68.6%)	45 (9.7%)	abdominal pain - 4 ICB - 26 peripancreatic bleeding - 1 AP - 11 Mild infection - 3 Atrial fibrillation - 1

AP: Acute pancreatitis; ICB: Intracystic bleed; AE: Adverse events; N/A: Not available; FNA: Fine needle aspiration

carcinoembryonic antigen [CEA], CA 19-9, molecular markers) and recently by sampling the tissue wall.

EUS morphology alone has a modest diagnostic yield in distinguishing mucinous from nonmucinous pancreatic cysts, with variable diagnostic accuracy (48%–94%), sensitivity (36%–91%) and specificity (45%–81%).^[5] Regarding cyst fluid analysis, CEA, with a cutoff value of 192 ng/mL, is considered the most accurate marker (52%–78% sensitivity; 63%–91% specificity) for differentiating nonmucinous from mucinous pancreatic cysts and is the preferred marker in low-volume aspirates.^[5,18] Various studies showed that CEA values <5 ng/mL had 50% sensitivity and 95% specificity for serous cystadenoma (SCA) or pseudocyst diagnosis, while CEA >800 ng/mL had 48% sensitivity and 98% specificity in differentiating between mucinous and nonmucinous cysts.^[19,20]

Cyst fluid amylase levels <250 U/L, although not useful in distinguishing between mucinous and nonmucinous cysts, may exclude pancreatic pseudocysts with a 44% sensitivity and a 98% specificity.^[20,21] In addition, CEA >192 ng/mL values associating with amylase values below or above 250 U/L might guide the

diagnosis towards mucinous cystic neoplasm (MCN) or intraductal papillary mucinous neoplasm.^[19]

Cyst fluid glucose ≤ 50 mg/dL compared to CEA >192 ng/mL cutoff,^[22] has been proven to be more sensitive (92% *vs.* 58%), more accurate (90% *vs.* 69%) but less specific (87% *vs.* 96%) in diagnosing mucinous pancreatic cysts. Similar results regarding sensitivity (88% *vs.* 50%) and diagnostic accuracy (94% *vs.* 89%) were also obtained for fluid glucose <41 mg/dL and CEA >184 ng/mL.^[23] However, the measurement of both intracystic glucose and CEA might have significantly increased sensitivity in diagnosing mucinous cysts.^[24]

The cytopathological examination of PLCs has a specificity higher than 93%.^[25,26] and until now was the most accurate test for determining malignancy risk. Despite its potential to provide a definite diagnosis, it is less sensitive in diagnosing a malignant cyst (75%–78%)^[12,25] and its use remains limited mostly because of low cellularity acquisition during EUS-FNA and gastrointestinal wall cell contamination, but also possibly due to the examiner's lack of experience.^[12]

Considering this suboptimal performance of cyst fluid analysis in setting the correct management of PLCs,

a need for better diagnostic tools has emerged. Thus, a growing interest has developed around the idea of targeting the cyst lining by the use of a microbiopsy forceps device. Several case reports and small case series have been reported.^[27-29]

One of the anticipated issues regarding the MFB was the ability to perform the puncture, especially in positions known to be difficult even for conventional FNA, such as the transduodenal route. In this systematic review, a high rate of technical success was reported-98.5%, but these are results of expert centers. Technical failures were represented by punctures attempted with the echoendoscope in fully flexed position (by transduodenal route); there was one case with failed transgastric puncture but in fact it was reported as a failure because of transient hypoxia which leads to abortion of the procedure.

Regarding tissue acquisition yield, this was very high-88.2%, however, not all studies reported the number of biopsies performed per cyst. A lower rate of successful sampling of the epithelial lining was seen in tail-located cysts,^[10,12] but this could be due to the higher frequency of MCNs and SCAs located in the tail and the fact that epithelial cyst denudation has been previously reported in these lesions.^[30,31]

The diagnostic yield of the TTNB forceps was 68.6%. Six of the studies included in our review providing comparative information regarding diagnostic accuracy concluded that MFB is better than EUS-FNA in differentiating nonneoplastic from neoplastic PCLs and diagnosing the specific type of cyst.

Yang *et al.* were able to diagnose mucinous cysts in 34.3% of the cases by using TTNB alone, rather than by using biomarkers such as CEA >192 ng/mL alone (6.3%) or CEA >192 ng/mL and FNA cytology combination (9.4%).^[11] Barresi *et al.* showed that TTNB diagnostic yield was significantly higher than needle cystic wall biopsy combined with fluid cytology analysis (83.9% *vs.* 41.6%).^[13]

MFB also proved to be more accurate than EUS in diagnosing the specific type of cyst. MFB provided a specific diagnosis in 35.7%–50% of the cases compared to conventional analysis of cyst fluid 4.8%–18.8%.^[12,14]

The impact of EUS-TTNB was clinically meaningful, as it provided a diagnosis of the specific type of cyst in

significantly more cases than the conventional methods. A change in the presumed diagnosis/management was reported in 19.4%–26% of cases.^[15,16]

Adverse events (AE) rate was highly variable among the reported studies-from 0% AE^[14,15] 22.9%.^[9] Intracystic bleeding was one of the most frequently reported AE. In most of the cases, bleeding was self-limiting and asymptomatic and did not require medical intervention. In some cases, bleeding was associated with abdominal pain caused by increased intracystic pressure.^[9] Another potentially severe AE was acute pancreatitis, which was reported in 3%–7% of cases.^[10,16]

There was significant heterogeneity of studies included in this systematic review. Not all studies reported on the morphology of the cysts-unilocular/septated, biopsy protocol, or mean number of biopsies per cyst [Supplementary Table 1], whether the biopsy site was targeted (from mural nodules or septations) or random from the wall. Furthermore, half of the studies were single center and sample sizes were small.

Another significant limitation is that 8 out of 9 studies were retrospective. Also, pathologists were not blinded to follow-up of patients, and comparison with a surgical specimen was available in a limited number of cases. Molecular analysis of cyst fluid was also missing in most studies, which could have had an impact on the management decision, as it is known to improve the diagnostic yield of cytology alone.^[32] Quality of specimens was not reported throughout all studies; this should be considered as an outcome measure in future trials.

Not least, the encouraging results of the studies included in our systematic review reflect the experience of high-volume centers with expert endosonographers and pathologists, which might not be replicated in a real-world setting.

Experience with this new technique is growing, and better insight about the indications and safety of MFB is expected from future studies. The cost of using TTNB forceps could be an issue given the expenses associated with EUS-FNA, but taking into account the change in management reported in up to 1 in 4 patients, it could prove to be cost-effective; this aspect should be certainly addressed in further studies.

CONCLUSIONS

EUS-guided MFB is technically feasible, safe, and has a high diagnostic accuracy for PCLs. The results of our systematic review should be interpreted with caution. Given the novelty of this technique, further ongoing studies are expected to offer a better understanding of the safety profile and diagnostic accuracy of EUS-MFB.

Supplementary Materials

Supplementary information is linked to the online version of the paper on the Endoscopic Ultrasound website.

Financial support and sponsorship

Nil.

Conflicts of interest

There are no conflicts of interest.

REFERENCES

- Laffan TA, Horton KM, Klein AP, et al. Prevalence of unsuspected pancreatic cysts on MDCT. *AJR Am J Roentgenol* 2008;191:802-7.
- de Oliveira PB, Puchnick A, Szejnfeld J, et al. Prevalence of incidental pancreatic cysts on 3 tesla magnetic resonance. *PLoS One* 2015;10:e0121317.
- Tanaka M, Fernández-del Castillo C, Adsay V, et al. International consensus guidelines 2012 for the management of IPMN and MCN of the pancreas. *Pancreatol* 2012;12:183-97.
- Tanaka M, Castillo CF, Kamisawa T, et al. Revisions of international consensus Fukuoka guidelines for the management of IPMN of the pancreas. *Pancreatol* 2017;17:738-53.
- European Study Group on Cystic Tumours of the Pancreas. European evidence-based guidelines on pancreatic cystic neoplasms. *Gut* 2018;67:789-804.
- Elta GH, Enestvedt BK, Sauer BG, et al. ACG Clinical Guideline: Diagnosis and management of pancreatic cysts. *Am J Gastroenterol* 2018;113:464-79.
- Alvarez-Sánchez MV, Napoléon B. New horizons in the endoscopic ultrasonography-based diagnosis of pancreatic cystic lesions. *World J Gastroenterol* 2018;24:2853-66.
- Cotton PB, Eisen GM, Aabakken L, et al. A lexicon for endoscopic adverse events: Report of an ASGE workshop. *Gastrointest Endosc* 2010;71:446-54.
- Crinò SF, Bernardoni L, Brozzi L, et al. Association between macroscopically visible tissue samples and diagnostic accuracy of EUS-guided through-the-needle microforceps biopsy sampling of pancreatic cystic lesions. *Gastrointest Endosc* 2019;90:933-43.
- Yang D, Samarasena JB, Jamil LH, et al. Endoscopic ultrasound-guided through-the-needle microforceps biopsy in the evaluation of pancreatic cystic lesions: A multicenter study. *Endosc Int Open* 2018;6:E1423-E30.
- Yang D, Trindade AJ, Yachimski P, et al. Histologic analysis of endoscopic ultrasound-guided through the needle microforceps biopsies accurately identifies mucinous pancreas cysts. *Clin Gastroenterol Hepatol* 2019;17:1587-96.
- Basar O, Yuksel O, Yang DJ, et al. Feasibility and safety of microforceps biopsy in the diagnosis of pancreatic cysts. *Gastrointest Endosc* 2018;88:79-86.
- Barresi L, Crinò SF, Fabbri C, et al. Endoscopic ultrasound-through-the-needle biopsy in pancreatic cystic lesions: A multicenter study. *Dig Endosc* 2018;30:760-70.
- Zhang ML, Arpin RN, Brugge WR, et al. Moray micro forceps biopsy improves the diagnosis of specific pancreatic cysts. *Cancer Cytopathol* 2018;126:414-20.
- Mittal C, Obuch JC, Hammad H, et al. Technical feasibility, diagnostic yield, and safety of microforceps biopsies during EUS evaluation of pancreatic cystic lesions (with video). *Gastrointest Endosc* 2018;87:1263-9.
- Kovacevic B, Klausen P, Hasselby JP, et al. A novel endoscopic ultrasound-guided through-the-needle microbiopsy procedure improves diagnosis of pancreatic cystic lesions. *Endosc* 2018;50:1105-11.
- Hrad V, Meidinger R, Peng HQ, et al. EUS-guided cyst wall biopsy is highly effective in definitive diagnosis of pancreatic cysts: 69. *Am J Gastroenterol* 2018;113:S40-1.
- Ngamruengphong S, Lennon AM. Analysis of pancreatic cyst fluid. *Surg Pathol Clin* 2016;9:677-84.
- Kaplan JH, Gonda TA. The use of biomarkers in the risk stratification of cystic neoplasms. *Gastrointest Endosc Clin N Am* 2018;28:549-68.
- van der Waaij LA, van Dullemen HM, Porte RJ. Cyst fluid analysis in the differential diagnosis of pancreatic cystic lesions: A pooled analysis. *Gastrointest Endosc* 2005;62:383-9.
- Al-Rashdan A, Schmidt CM, Al-Haddad M, et al. Fluid analysis prior to surgical resection of suspected mucinous pancreatic cysts. A single centre experience. *J Gastrointest Oncol* 2011;2:208-14.
- Carr RA, Yip-Schneider MT, Simpson RE, et al. Pancreatic cyst fluid glucose: Rapid, inexpensive, and accurate diagnosis of mucinous pancreatic cysts. *Surgery* 2018;163:600-5.
- Simons-Linares CR, Bhatt A, Jang S, et al. 157-The utility of intracystic glucose levels in differentiating mucinous from non-mucinous pancreatic cysts. *Gastroenterol* 2018;154:S-43.
- Figueiredo M, Zaarour A, Eisendrath P. Intracystic glucose and CEA measurement: A quick tool for diagnosing mucinous pancreatic cysts. *Endoscopy* 2018;50:eP180V.
- Scourtas A, Dudley JC, Brugge WR, et al. Preoperative characteristics and cytological features of 136 histologically confirmed pancreatic mucinous cystic neoplasms. *Cancer Cytopathol* 2017;125:169-77.
- Thornton G, McPhail M, Nayagam S, et al. Endoscopic ultrasound guided fine needle aspiration for the diagnosis of pancreatic cystic neoplasms: A meta-analysis. *Pancreatol* 2013;13:48-57.
- Shakhatreh MH, Naini SR, Brijbassie AA, et al. Use of a novel through-the-needle biopsy forceps in endoscopic ultrasound. *Endosc Int Open* 2016;4:E439-42.
- Huelsen A, Cooper C, Saad N, et al. Endoscopic ultrasound-guided, through-the-needle forceps biopsy in the assessment of an incidental large pancreatic cystic lesion with prior inconclusive fine-needle aspiration. *Endoscopy* 2017;49:E109-10.
- Pham KD, Engjom T, Kolleset HG, et al. Diagnosis of a mucinous pancreatic cyst and resection of an intracystic nodule using a novel through-the-needle micro forceps. *Endoscopy* 2016;48 Suppl 1:E125-6.
- Collins BT. Serous cystadenoma of the pancreas with endoscopic ultrasound fine needle aspiration biopsy and surgical correlation. *Acta Cytol* 2013;57:241-51.
- Gómez V, Majumder S, Smyrk TC, et al. Pancreatic cyst epithelial denudation: A natural phenomenon in the absence of treatment. *Gastrointest Endosc* 2016;84:788-93.
- Springer S, Wang Y, Dal Molin M, et al. A combination of molecular markers and clinical features improve the classification of pancreatic cysts. *Gastroenterol* 2015;149:1501-10.

Supplementary Table 1. Number of passes performed with the Moray forceps

Author, year	Study methods on number of passes/cyst
Basar, 2018	If the biopsy specimen seemed insufficient in size for histology, additional passes were made
Barresi, 2018	The number of passes performed with the biopsy forceps was at the discretion of each endosonographer 1 biopsy-3 (5.3%), 2-7 (12.5%), 3-32 (57.1%), 4-11 (19.6%), 5-3 (5.3%)
Zhang, 2018	More than one biopsy was obtained if initial biopsies appeared inadequate macroscopically
Mittal, 2018	3-4 passes were made with microforceps (or until 3-4 visible tissue fragments were obtained)
Kovacevic, 2018	Median of 3 biopsies per patient (interquartile range 2-4)
Hrad, 2018	Not mentioned
Yang, 2018 (retrospective)	Median number of passes of one (range 1-2). Two to three “bites” of microforceps biopsy specimens were obtained under EUS-guidance with each pass of the microforceps
Yang, 2019 (prospective)	Two to 3 bites were obtained from the cyst wall, septations, nodules, or adjacent solid components with each pass of the microforceps
Crino, 2019	In the absence of intracystic bleeding, the procedure was repeated until 3 visible specimens were obtained