

Pericardial effusion uncovering underlying hypothyroidism

Anoosha Ponnappalli  | Smit S. Deliwala  | Yazan Zayed | Ghassan Bachuwa

Department of Internal Medicine, Michigan State University at Hurley Medical Center, Flint, MI, USA

Correspondence

Anoosha Ponnappalli, Department of Internal Medicine, Michigan State University at Hurley Medical Center, One Hurley Plaza, Flint, MI 48503.
Email: aponnap1@hurleymc.com

Abstract

Pericardial effusion may be the tipping point to unravel hypothyroidism. Large effusions may not correlate with severity of cardiovascular compromise. Medical therapy over surgical intervention is appropriate if no evidence of cardiac tamponade.

KEYWORDS

hypothyroidism, myxedema, pericardial disease, pericardial effusion

1 | CASE HISTORY

Primary hypothyroidism has been associated with many undue adverse effects. Its cardiovascular manifestations include reductions in heart rate and contractility with the development of hypertension, angina, heart failure, and pericardial effusion consistent with hypothyroid heart. Early recognition and treatment can help mitigate these advanced features.[1]

Question: What are the cardiac implications of untreated hypothyroidism?

Answer: We present a case of pericardial effusion from primary hypothyroidism.

A 70-year-old woman with a history of chronic obstructive pulmonary disease (COPD), chronic arthritis with no documented hypothyroidism presented to the emergency department with dyspnea evolving over the last month, generalized weakness, and arthritic pain. Initial vitals were notable for bradycardia and hypoxia, with an oxygen saturation of 80% necessitating supplemental oxygen. She was awake, appeared frail, and was not in acute distress. The examination revealed muffled heart sounds, jugular venous distention,

and features consistent generalized myxedema (Figure 1). Initial workup revealed pancytopenia with macrocytosis and revealed an unremarkable chemistry panel with a brain natriuretic peptide (BNP) of 133.4 PG/ML. Imaging revealed cardiomegaly and pulmonary congestion on chest radiography (Figure 2), while computerized tomography (CT) chest with contrast revealed a moderate to large pericardial effusion (Figure 3). Thyroid-stimulating hormone (TSH) was 102.94 UIU/ML (normal range 0.30-5.50 UIU/ML) with a free T₄ less than 0.1 NG/DL (normal range 0.9-1.8 NG/DL). A transthoracic echocardiogram confirmed a large circumferential pericardial effusion without tamponade physiology and severe concentric left ventricular hypertrophy (Figure 4). She was initially treated with a single dose of intravenous levothyroxine 300 mcg, followed by 100 mcg daily. Also received hydrocortisone 50 mg every 8 hours. Following clinical improvement was transitioned to oral levothyroxine 100 mcg daily, and hydrocortisone was slowly discontinued. Repeat echocardiogram prior to discharge revealed significant improvement, showing only moderate effusion adjacent to the left ventricle. She was discharged on an oral course of levothyroxine with close follow-up with a cardiologist.

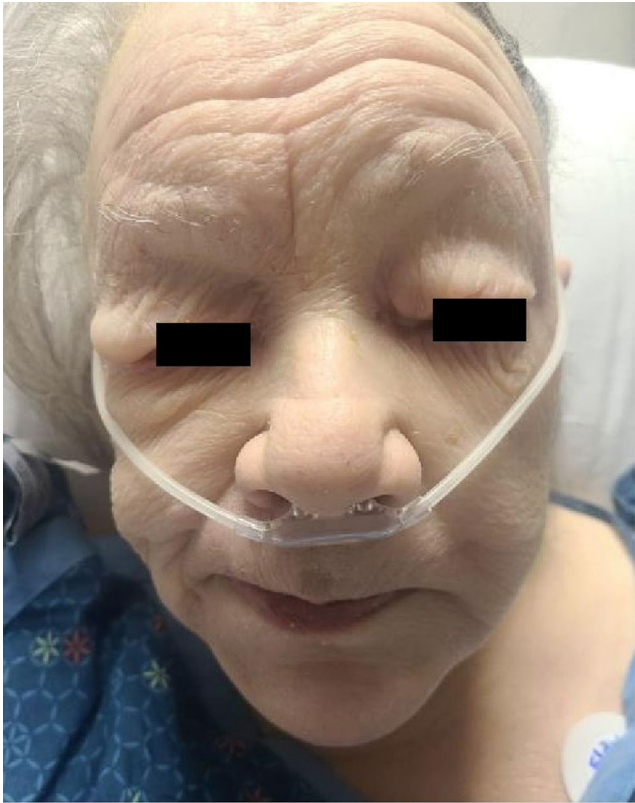

FIGURE 1 Myxedema demonstrating features of hypothyroidism

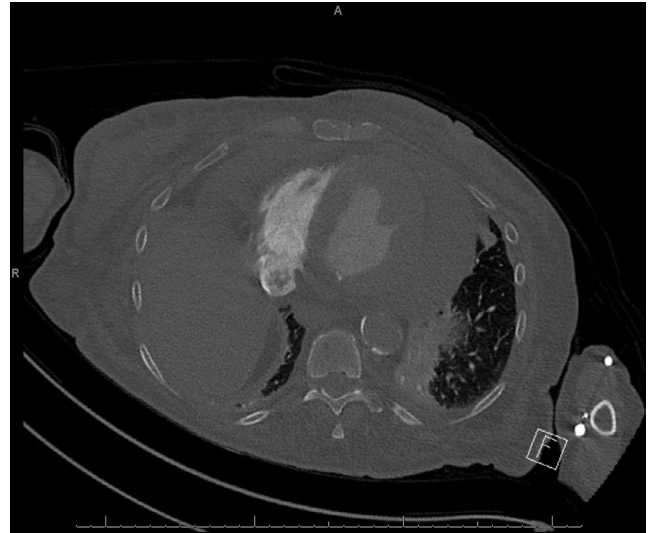

FIGURE 3 Computerized Tomography (CT) demonstrating large pericardial effusion

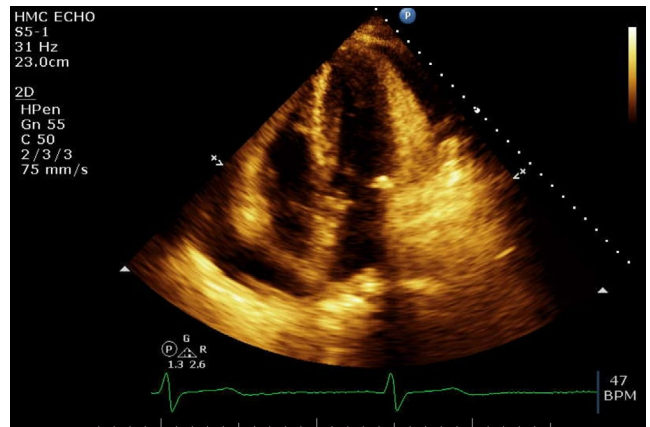


FIGURE 4 Transthoracic echocardiogram with four-chamber view showing pericardial effusion

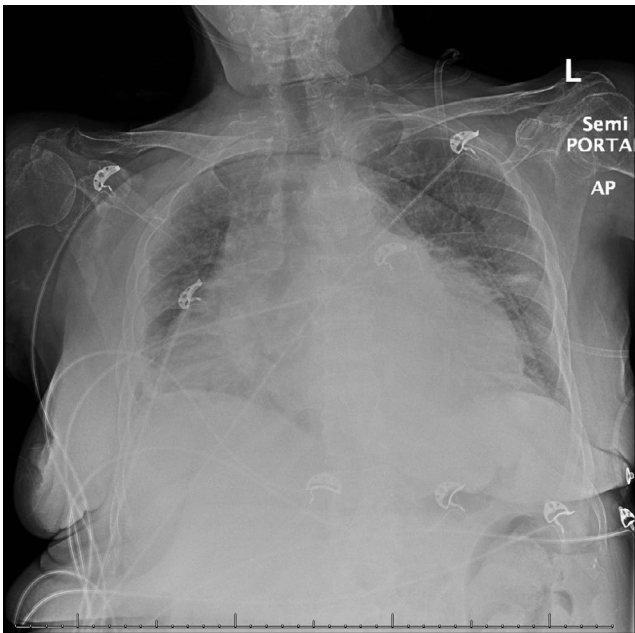


FIGURE 2 Chest radiograph demonstrating enlarged cardiac silhouette

ACKNOWLEDGMENTS

Published with written consent of the patient.

CONFLICT OF INTEREST

None to declare.

AUTHOR CONTRIBUTIONS

Anoosha Ponnappalli: designed the manuscript, collected the data, and reviewed the manuscript. Smit S. Deliwala: collected the data, prepared the manuscript, and reviewed the

manuscript. Yazan Zayed: reviewed the manuscript. Ghassan Bachuwa: reviewed the manuscript.

ETHICAL STATEMENT

Informed consent was obtained from the patient for the publication of this case report.

DATA AVAILABILITY STATEMENT

Data sharing was not applicable as no datasets were generated or analyzed for this article.

ORCID

Anoosha Ponnappalli  <https://orcid.org/0000-0001-9223-9411>

Smit S. Deliwala  <https://orcid.org/0000-0001-5239-9533>

REFERENCES

1. Chahine J, Ala CK, Gentry JL, Pantalone KM, Klein AL. Pericardial diseases in patients with hypothyroidism. *Heart*. 2019;105(13):1027-1033..

How to cite this article: Ponnappalli A, Deliwala SS, Zayed Y, Bachuwa G. Pericardial effusion uncovering underlying hypothyroidism. *Clin Case Rep*. 2021;9:1816–1818. <https://doi.org/10.1002/ccr3.3857>