

Clinical Epidemiology and Management of Hidradenitis Suppurativa

Christopher J. Sayed, MD, Jennifer L. Hsiao, MD, and Martin M. Okun, MD, PhD, for the Hidradenitis Suppurativa Foundation Women's Health Subcommittee

Hidradenitis suppurativa is a chronic immune-mediated inflammatory skin disease with a prevalence of 0.1–1%, characterized by nodules and abscesses in the axillae, groin, and inframammary areas, sometimes developing into tunnels (or fistulas) and scars. Because hidradenitis suppurativa is more common in women and in those aged 18–40 years, obstetrician-gynecologists (ob-gyns) have the opportunity to diagnose, educate, initiate treatment, and coordinate care with ancillary health care professionals. The recently published North American treatment guidelines, along with management information for patients with hidradenitis suppurativa who are pregnant or breastfeeding, are summarized. By diagnosing and optimizing hidradenitis suppurativa treatment early in the disease course, ob-gyns can reduce morbidity, with the potential to favorably alter disease trajectory.

(*Obstet Gynecol* 2021;137:731–46)

DOI: 10.1097/AOG.0000000000004321

Obstetrician-gynecologists (ob-gyns) often serve as the primary medical contact for female patients with hidradenitis suppurativa. The first North American clinical management guidelines from the

From the Department of Dermatology, University of North Carolina at Chapel Hill School of Medicine, Chapel Hill, North Carolina; the Division of Dermatology, Department of Medicine, University of California, Los Angeles, Los Angeles, California; and Fort HealthCare, Fort Atkinson, Wisconsin.

Each author has confirmed compliance with the journal's requirements for authorship.

The authors thank the other members of the Hidradenitis Suppurativa Foundation Women's Health Subcommittee: Amit Garg, MD, Iltefat Hamzavi, MD, FAAD, Joslyn S. Kirby, MD, MS, Hadar Lev-Tov, MD, MAS, and Lauren A.V. Orenstein, MD, for assistance with manuscript drafting, review, and feedback.

Corresponding author: Martin M. Okun, MD, PhD, Fort HealthCare, Fort Atkinson, WI; email: martinmokun@gmail.com.

Financial Disclosure

Christopher J. Sayed, MD, has been a speaker for AbbVie and Novartis, an advisor for UCB and AbbVie, and an investigator for InflaRx, UCB, Novartis, AbbVie, Chemocentryx, Incyte and GSK. Martin M. Okun, MD, PhD, has been a speaker for AbbVie and a consultant for AbbVie, Azora Therapeutics, Boehringer Ingelheim, Gilead, Glaxo Smith Kline, Incyte, Innovaderm, InflaRx, Genentech, Pfizer, Regeneron, and Seattle Genetics. The other author did not report any potential conflicts of interest.

© 2021 The Author(s). Published by Wolters Kluwer Health, Inc. This is an open-access article distributed under the terms of the Creative Commons Attribution-Non Commercial-No Derivatives License 4.0 (CCBY-NC-ND), where it is permissible to download and share the work provided it is properly cited. The work cannot be changed in any way or used commercially without permission from the journal.

ISSN: 0029-7844/21

U.S. and Canadian Hidradenitis Suppurativa Foundations (NAHS guidelines hereafter) have been recently published,^{1,2} which creates an opportunity to summarize these guidelines and other recent related literature for ob-gyns.

Morbidity and mortality in hidradenitis suppurativa cannot be overstated: pain and malodorous drainage torment patients, and the condition is independently associated with increased mortality after adjusting for other comorbidities.³ Early intervention requires establishing the diagnosis soon after initial symptoms, but evidence suggests that current efforts are insufficient. The average time from symptom onset to diagnosis is 10 years, with 65% of patients having six or more physician visits before diagnosis.⁴ This delay, coupled with multiple misdiagnoses, fragmented care, and inappropriate treatments contributes to disease progression and morbidity. Acute lesions are painful inflammatory nodules (solid, raised, round-oval lesions without puncta associated with redness and tenderness) and abscesses (fluctuant, exquisitely tender lesions that can drain purulent fluid), typically in axillary, inframammary, and inguinal areas (Fig. 1). More than half of patients experience disease flares at least weekly.⁴ Over time, hypertrophic scars or tunneling sinus tracts may develop that drain purulent, malodorous fluid and

limit range of motion. Almost 15% report disease-related disability.⁴ Approximately 5% of patients with hidradenitis suppurativa report that ob-gyns were the physicians who correctly diagnosed their disease, positioning ob-gyns to help shorten diagnostic delay.⁴

Diagnosis is based on the clinical criteria of 1) typical inflammatory lesions: abscesses, nodules, and tunnels (openings at the skin surface, sometimes draining malodorous fluid), 2) in intertriginous locations (eg, axilla, inframammary areas, crural folds), with 3) history of recurrence.¹ Disease progression can be staged using the Hurley classification system: stage I connotes the absence of tunnels or scarring, stage II connotes the presence of tunnels or scarring interspersed among areas of normal skin, stage III connotes diffuse tunnels or scarring replacing all, or nearly all, normal skin in an entire anatomic region.¹ Female and male patients with hidradenitis suppurativa have a similar likelihood of axillary involvement, with females more commonly having disease activity in mammary, intermammary, and inguinofemoral regions, and males more commonly having sequelae in perianal, perineal, and buttock regions⁵; it is unknown whether the frequency of misdiagnosis differs for men and women. Principal diseases in the differential diagnosis include inflamed epidermal inclusion cyst (or epidermoid cyst), nodulocystic acne, and furuncle (or carbuncle) (Fig. 2 and Table 1). Furuncles and inflamed epidermal inclusion cysts typically have a punctum, are not predominantly localized in intertriginous areas, and with inflamed cysts there is typically a chronic history of a noninflamed cyst present before onset of inflammation. Nodulocystic acne typically is localized to the face and torso, and acne lesions do not typically form tunnels.

Hidradenitis suppurativa is hypothesized to be an inflammatory, not infectious, disease of the hair follicle. Follicular hyperkeratosis, with subsequent rupture of the hair follicle and spillage of contents into the dermis, provokes intense inflammation associated with upregulation of multiple pro-inflammatory cytokines. Though dysbiosis and colonization with biofilm-forming bacteria occurs, its role in disease pathogenesis is unclear.⁶

EPIDEMIOLOGY AND COMORBIDITIES

The most comprehensive prevalence estimates in the United States and United Kingdom range from 0.1% to 1%.^{1,7,8} Most patients are aged 18–40 years. The standardized point prevalence in U.S. women is approximately 2.4-fold higher than in men⁷ and 3-fold higher among Black patients than White patients.⁷ Increased body mass index (BMI, calculated

as weight in kilograms divided by height in meters squared) is positively associated with presence and severity of hidradenitis suppurativa,^{5,9} and smoking tobacco is a risk factor.¹⁰

As a chronic inflammatory disease, hidradenitis suppurativa exemplifies the link between integumentary and comorbid systemic disease through shared inflammatory pathways. Patients have double the comorbidity burden compared with the general population,¹¹ and hidradenitis suppurativa has independent associations with several individual comorbid diseases (Table 2). Polycystic ovarian syndrome (PCOS) prevalence among women with hidradenitis suppurativa is 9.0%, approximately twice the independent odds for patients who do not have hidradenitis suppurativa,¹² yet there is no evidence of biochemical hyperandrogenism in women with hidradenitis suppurativa compared with matched controls.¹³

The most frequent, and perhaps most severe, comorbidities in hidradenitis suppurativa are psychiatric. Depression prevalence is estimated to be as high as 43%.^{4,14,15} Suicidal ideation or attempt has been reported in 12% of patients,⁴ who tragically demonstrate increased rates of completed suicide,¹⁶ particularly among women.¹⁷ The devastating effect of physical pain presumably leads to the greater reported risk for substance use disorder (4% prevalence).¹⁸ Patients with hidradenitis suppurativa were observed to have a 53% greater risk of chronic opioid use compared with controls in adjusted analyses.¹⁹

MANAGEMENT

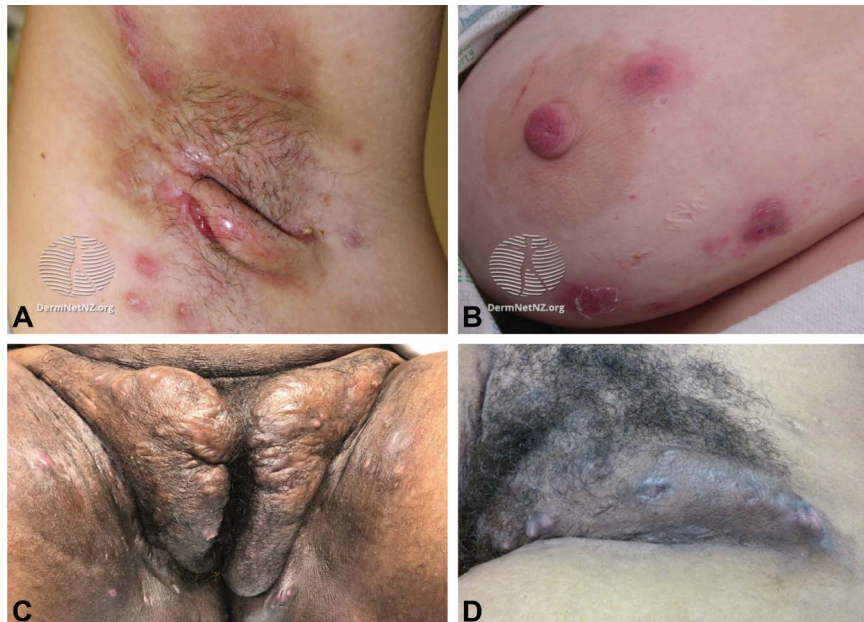Treatment plans must address both acute control of symptoms such as pain and drainage as well as management of chronic problems such as tunneling, disfigurement and progression. In patients with active inflammation, pharmacologic treatment is first line for all levels of disease activity. Excision is typically reserved for disease inadequately responsive to pharmacologic intervention, or for localized disease.

LIFESTYLE MODIFICATIONS

Lifestyle modifications such as smoking cessation, weight loss, or modifications in shaving or antiperspirants²⁰ are not supported by high-quality evidence and can be considered medical and surgical treatment adjuncts. It is unclear whether changes in smoking status influence hidradenitis suppurativa severity, treatment response, or disease duration^{5,21–25} (though smoking cessation is encouraged to improve overall health²⁶).

Inconsistent and limited evidence supports an association between increasing BMI and worsening

Fig. 1. Hidradenitis suppurativa involving left axilla, with multiple inflammatory nodules and a sinus tract in the axillary vault (A), right breast, with multiple abscesses and atrophic scars (B), groin (C–D), chronic changes of hyperpigmentation and hypertrophic scarring, with persistent inflammatory activity. Figures 1A and 1B are reprinted from DermNet AZ. Accessed December 3, 2020. <https://dermnetnz.org/topics/hidradenitis-suppurativa-images/?stage=Live>. These images are reprinted under a Creative Commons Attribution-Non-Commercial-NoDerivs 3.0 (New Zealand) license, available at <https://creativecommons.org/licenses/by-nc-nd/3.0/nz/legalcode>. No changes were made from the original. Figures 1C and 1D are courtesy of Christopher J. Sayed, MD. Used with permission.



Sayed. *Hidradenitis Suppurativa Management Update. Obstet Gynecol* 2021.

hidradenitis suppurativa severity.^{5,27} Despite limited evidence and possible confounding variables (Rayner CR. Pathogenesis, clinical features and management of hidradenitis suppurativa [letter]. *Ann R Coll Surg Engl* 1997;79:309),^{28–31} screening for and treating obesity (BMI 30 or higher) is encouraged.³² Though insufficient evidence exists, benefits from avoiding dairy³³ and brewer's yeast (*Saccharomyces cerevisiae*)³⁴ have been described.

Case reports and a survey study suggest that tight-fitting clothing or other sources of rubbing contribute

to hidradenitis suppurativa flares.^{35–39} Whether personal care practices such as hair removal (eg, shaving) and use of deodorant or antiperspirant exacerbates this condition²² is unclear because research is limited by recall bias.^{40,41}

Patients with hidradenitis suppurativa often show high interest in complementary and alternative medical therapy,⁴² but it should be considered adjunctive owing to limited evidence. An uncontrolled prospective study of zinc gluconate at 90 mg daily in 22 patients was associated with a 36% rate of clinical

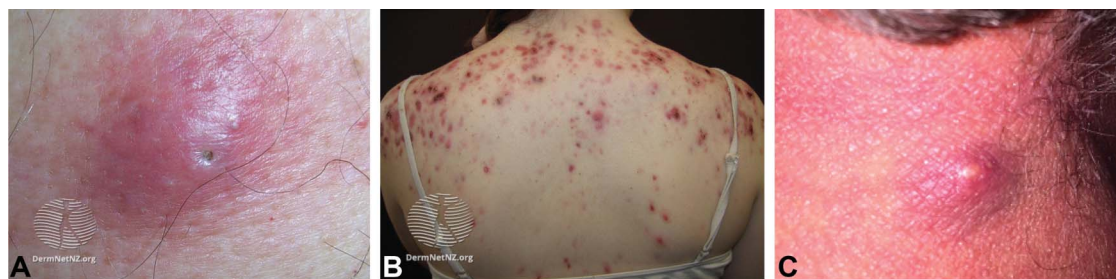

Fig. 2. Differential diagnosis for hidradenitis suppurativa includes: epidermal inclusion cyst, which typically has a central punctum lacking in hidradenitis suppurativa (A), nodulocystic acne, with its different distribution (B), and furuncle, with an acute course and central pustule (C). Figure 2A is reprinted from DermNetNZ. Lam M. Epidermoid cyst. Accessed December 3, 2020. <https://dermnetnz.org/topics/epidermoid-cyst/>. Figure 2B is reprinted from DermNet NZ. Acne affecting the back images. Accessed December 3, 2020. <https://www.dermnetnz.org/topics/acne-affecting-the-back-images/>. Figures 2A and 2B are reprinted under a Creative Commons Attribution-NonCommercial-NoDerivs 3.0 (New Zealand) license, available at <https://creativecommons.org/licenses/by-nc-nd/3.0/nz/legalcode>. No changes were made from the original. Figure 2C is reprinted with permission from the Department of Dermatology at the Waikato District Health Board.

Sayed. *Hidradenitis Suppurativa Management Update. Obstet Gynecol* 2021.

Table 1. Differential Diagnosis for Hidradenitis Suppurativa

Disease	Presentation	Differentiating From Hidradenitis Suppurativa
Inflamed epidermal inclusion cyst	Epidermal cyst, often with a visible punctum or plug, can become inflamed if ruptured	Typically solitary (multiple 2–10-mm asymptomatic cysts on labia majora can occur) Not localized to intertriginous areas Chronic, can express malodorous, “cheesy” keratinous debris
Nodulocystic acne	Comedones and inflamed nodules and cysts	Involves head, neck, and torso, with only occasional intertriginous involvement
Furuncles or carbuncles	Inflamed, tender, fluctuant abscesses	May have superficial and visible pustule Can be associated with circumferential erythema, lymphangitis, and fever No history of periodic waxing and waning Arises in any location
Endometriosis	Red-brown-violaceous nodule	Flares with menses (some patients with hidradenitis suppurativa also have menstrual flares) Not purulent Not localized to intertriginous areas
Bartholin gland cyst	Cyst, sometimes inflamed or infected, localized to posterior introitus	Not localized to intertriginous areas
Lymphadenopathy	Skin-colored nodules	No epidermal component Localized to areas with lymph nodes
Cutaneous Crohn’s disease	Anal canal fissures, sometimes associated with ulcers or fistulas	Lesions typically localized only to perianal or anal area Other symptoms of Crohn’s disease (eg, diarrhea, abdominal pain) typically present

remission.^{43,44} An uncontrolled prospective study of vitamin D supplementation in 14 patients noted that all had evidence of vitamin D deficiency (serum 25-hydroxyvitamin D3 levels less than 30 ng/mL) at baseline, with serum levels negatively correlated with disease severity, and that supplementation tailored to patients’ measured vitamin D level was associated with a 51% reduction in inflammatory nodule count.⁴⁵ Insufficient evidence exists to generally recommend use of zinc or vitamin D.

PHARMACOLOGIC THERAPY

Topical therapy is appropriate for most patients with hidradenitis suppurativa. Based on expert opinion, the NAHS guidelines support the use of chlorhexidine, benzoyl peroxide, or zinc pyrithione antimicrobial washes; topical retinoid therapy is not recommended.² Clindamycin 1% solution twice daily is recommended, based on placebo- and active-controlled trials,^{46,47} and concomitant use of benzoyl peroxide is suggested to reduce development of antibiotic resistance.² For acute flares, intralesional triamcinolone 10 mg/mL (0.2–2.0 mL) may rapidly reduce pain and inflammation.^{48,49}

The four recommended classes of systemic therapy include antibiotics, hormonal therapy, oral reti-

noids, and immunosuppressants, though comparative studies are lacking, with detailed dosing and duration information recently reviewed.⁵⁰ The NAHS guidelines do not include a treatment algorithm flow diagram to tier these classes.

The NAHS guidelines make five specific recommendations for systemic antibiotics: 1) tetracyclines; 2) clindamycin combined with rifampin^{51–54}; 3) moxifloxacin, metronidazole, and rifampin in combination; 4) dapsone; and 5) IV ertapenem, with tetracyclines and clindamycin plus rifampin receiving top-line recommendations (Table 3). Efficacy of clindamycin monotherapy (150 mg four times daily) has also been described⁵⁵ as an alternative to combination therapy. Chronic therapy with clindamycin and rifampin in combination is not recommended in the NAHS guidelines, presumably because of the paucity of long-term safety data, though a critical appraisal of the literature suggests that long-term treatment may not substantially increase risks over short-term treatment.⁵⁶ Because hidradenitis suppurativa is an inflammatory disease, it is unclear whether antibiotics’ efficacy is due to anti-inflammatory effects or disruption of host–microbiome interactions that fuel inflammation. Recurrence of disease activity frequently follows therapy interruption or

Table 2. Comorbid Conditions Associated With Hidradenitis Suppurativa

Organ System	Comorbid Disease	Risk Elevation vs Normal Population*	
		OR	HR
Cutaneous	Acne vulgaris and conglobata ¹³⁰		
Endocrinologic or metabolic	Pyoderma gangrenosum ¹³¹		
	Polycystic ovarian syndrome ¹²	2.14	
Cardiovascular	Diabetes mellitus ¹³²	1.58	
	Metabolic syndrome ¹³³	2.22	
	Myocardial infarction ¹³⁴		1.21
Gastrointestinal	Cerebrovascular accident ¹³⁴		1.22
	Crohn's disease ¹³⁵	3.05	
Psychiatric	Depression ^{4,14–16,136}	1.13, ^{†16} 9% (HS) vs 6% (control) ^{†,15}	
	Suicide ¹⁶	1.7, ¹³⁷	2.42
	Substance use disorder ^{18,133} (tobacco, ¹⁰ alcohol, opioids, cannabis)	1.50	
Pulmonary	Obstructive sleep apnea ¹³⁷	1.45	
Lymphatic	Lymphoma ¹³⁸	2.00–4.31	

OR, odds ratio; HR, hazard ratio; HS, hidradenitis suppurativa.

* Risk elevation is significant unless otherwise specified.

† Not significant.

discontinuation. Bacterial culture should not be routinely performed (unless secondary soft tissue infection is suspected) and does not typically guide antibiotic selection.¹

Hormonal effect in hidradenitis suppurativa is suggested by typical disease onset around or after puberty, exacerbation during pregnancy for some patients (Fig. 3), association with PCOS, and worsening with menstrual cycles.^{12,57,58} The mechanism by which hormones affect the disease is unclear (there is no evidence for significant differences between hidradenitis suppurativa and control patients in mean basal levels of estrogen and other sex hormones),⁵⁹ yet clinical evidence suggests that combination oral contraceptives, spironolactone, and finasteride can be effective (Table 3). Both ethinyl estradiol with norgestrel and ethinyl estradiol with cyproterone acetate resulted in similar improvement, with 50% (12/24) of patients improving or clearing completely.⁶⁰ Progestin-only contraceptives should be used cautiously; a case series suggests these may sometimes trigger hidradenitis suppurativa.⁶¹ Spironolactone or finasteride should be considered as monotherapy in women with mild-to-moderate symptoms or as adjunctive agents for more severe disease. Patients reporting hidradenitis suppurativa flares around menses or with features of PCOS may more likely benefit.^{62,63} Metformin, 500 mg 2–3 times daily, was associated with significant improvement in a 24-week uncontrolled, prospective study. Most patients (22/25) were women with features of PCOS.⁶⁴

Oral retinoids are typically either ineffective in hidradenitis suppurativa, or have efficacy limited mostly to milder cases.^{65–67} Expert opinion suggests acitretin is superior to isotretinoin, but comparative evidence is lacking. Oral retinoids should be prescribed by those familiar with side effects, including teratogenicity, and laboratory monitoring, and mostly considered if nodulocystic acne is concomitant.

Broad immunomodulators such as methotrexate, azathioprine, and cyclosporine have shown limited efficacy in scarce published data and generally are not recommended.^{68–72} Prednisone can be effective at a dose of 10 mg daily as an adjunct to other therapies, though the benefits of prolonged use should be balanced against the risks of hyperglycemia, osteoporosis, and immunosuppression.⁷³ Prednisone or prednisolone pulses (0.5–0.7 mg/kg/d tapered over several weeks) can be used as rescue therapy for flares or to bridge between long-term therapies.⁷⁴

The cornerstone of therapy for moderate-to-severe hidradenitis suppurativa is immunomodulation targeting tumor necrosis factor (TNF). Adalimumab 40 mg weekly is approved by the U.S. Food and Drug Administration for treating moderate-to-severe hidradenitis suppurativa in patients aged 12 and older (dosing is 40 mg every other week for adolescents weighing less than 132 pounds) (Fig. 4).⁷⁵ Two parallel double-blind placebo controlled phase 3 trials (PIONEER 1 and PIONEER 2) evaluated a primary end point of hidradenitis suppurativa clinical response

Table 3. Medical Management of Hidradenitis Suppurativa

Medication	Dose and Frequency	Comment
Tetracycline Doxycycline	500 mg twice daily 100 mg twice daily	Use for mild–moderate HS for up to 12 wk
Clindamycin and rifampin	300 mg and 300 mg twice daily	2nd-line therapy for mild–moderate HS for up to 12 wk
Oral contraceptive pills; prefer combination contraceptive because progestin-only may exacerbate	As directed	Monotherapy for mild–moderate disease, adjunctive therapy for moderate–severe disease
Spironolactone	75–150 mg daily	Monotherapy or adjunctive for mild–moderate disease
Finasteride	1.25–5 mg daily	Limited to case reports
Metformin	500 mg twice or 3 times daily	Monotherapy or adjunctive for mild–moderate disease
Isotretinoin, acitretin	Dosing varies	Refer to dermatologist for collaborative management
Prednisone	0.5–1 mg/kg/d	Used as week-long or multiweek-long tapers as rescue therapy for flares
Adalimumab (adults and adolescents 132 lb or more)	160 mg at wk 0, 80 mg at wk 2, and then 40 mg weekly starting at wk 4	Used for moderate–severe HS
Adalimumab (adolescents less than 132 lb)	80 mg at wk 0, 40 mg at wk 1, and then 40 mg every other week starting at wk 3	Used for moderate–severe HS
Infliximab	7.5–10 mg/kg every 4–8 wk	Often a second-line immunomodulator, used for moderate–severe HS

HS, hidradenitis suppurativa.

at 12 weeks. Hidradenitis suppurativa clinical responses for adalimumab compared with placebo were 42% and 26%, respectively ($P=.003$), in PIONEER 1 and 59% and 28%, respectively ($P<.001$), in PIONEER 2.⁷⁶ Infliximab has been investigated in smaller studies and has shown potential.^{77,78} Low-level evidence suggests efficacy for other TNF inhibitors and inhibitors of interleukin (IL)-12, IL-23, IL-17, and IL-1 as next-line therapies. Biologic therapies are best prescribed by practitioners familiar with their adverse effect profile.

SURGICAL THERAPY

Incision and drainage can be performed with local anesthesia. New-onset (ie, acute) abscesses are more likely to heal with incision and drainage than lesions that have recurred at a site where a previous lesion had been present (ie, chronic), though substantial short-term pain relief is provided for acute and chronic lesions.^{79–82} Wound packing does not improve outcomes so is best avoided given the associated pain and morbidity.⁸³ Instead of a blade, using a 4–6-mm punch tool for incision with secondary intention healing allows for drainage in the subsequent days and may prevent short-term recurrences.

Other surgical options include deroofting, excision, or laser therapy. Deroofting involves probing

chronic tunnels and sinuses, removing overlying skin, and beveling wound edges with scissor, blade, electrosurgical tools, or ablative lasers to create a broad-based wound that heals by secondary intention (Fig. 5),^{80,84–86} with detailed explanations and videos recently published.⁵⁰ Deroofting may be used for recurrent nodules, abscesses, or interconnected sinuses, and typically leaves a relatively superficial (dermal or subcutaneous) wound.

Excisions may be local (specific lesion) or wide, depending on disease extent, typically limited to superficial subcutis but may extend if deeper involvement is encountered intraoperatively. Healing by secondary intention or immediate or delayed closure using grafts, flaps, or skin substitutes have been described.¹ Smaller, stepwise excisions are less morbid than wider procedures, and may allow for gradual improvement without prolonged school, work, or lifestyle disruptions. More extensive excision provides more dramatic improvement in a single procedure.^{87,88} Excision recurrence rates were similar to derooftings in one series (approximately 25%),⁷⁹ whereas, in others, the recurrence rates of wide excision using traditional or carbon dioxide laser excision were less than 5%.^{81,89} Risk factors for recurrence include younger age, multiple surgical sites, and perianal, vulvar, and inframammary sites. Although 95% of

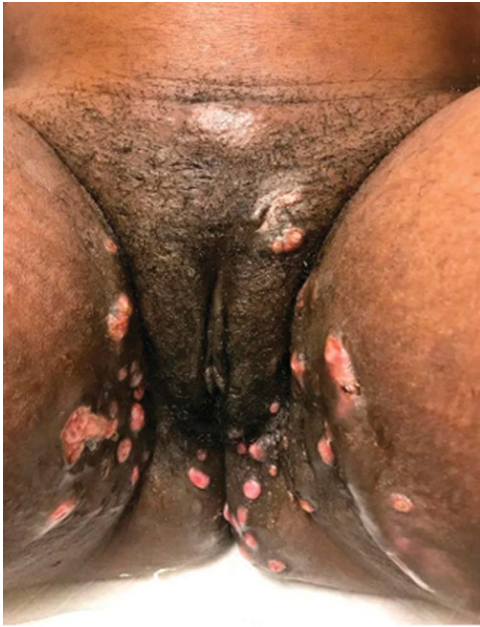

Fig. 3. Woman with hidradenitis suppurativa on the vulva, groin, and upper inner thighs, whose hidradenitis suppurativa flared during pregnancy. Given the large disease burden and location of her hidradenitis suppurativa, the patient had discussions with her ob-gyn and ultimately had a cesarean delivery. Image courtesy of Jennifer L. Hsiao, MD. Used with permission.

Sayed. Hidradenitis Suppurativa Management Update. Obstet Gynecol 2021.

patients in one survey still reported disease-specific life restrictions postoperatively, 80% were satisfied or very satisfied after surgery.⁹⁰

Follicular destruction with neodymium:yttrium-aluminum-garnet or alexandrite lasers, or diodes and intense pulsed light reduces disease activity, and is likely particularly important in early disease.⁹¹⁻¹⁰¹ Multiple sessions are required, but risks are low with high potential for improvement. Carbon dioxide laser requires specialized equipment and training and may lead to prolonged healing, but outcomes of excision, marsupialization, and vaporization are typically excellent.

The NAHS guidelines recommend continuing medical therapy, including biologics perioperatively because theoretical effects on wound healing from medication is less likely than the risk of perioperative disease flares that complicate recovery (Benjamin L, Cohen PF, SV Kane, Herfarth HH, Palekar N, Farraye FA, et al. 415a—Anti-tumor necrosis factor therapy is not associated with post-operative infection: results from prospective cohort of ulcerative colitis and Crohn’s disease patients undergoing surgery to

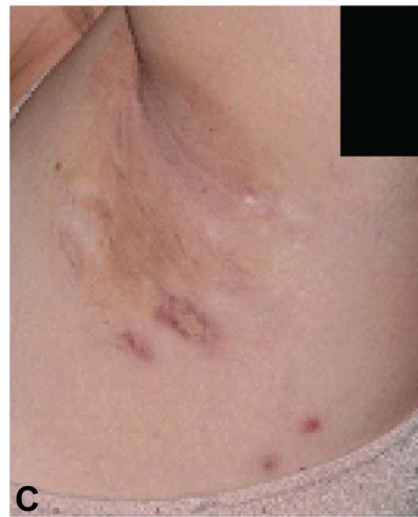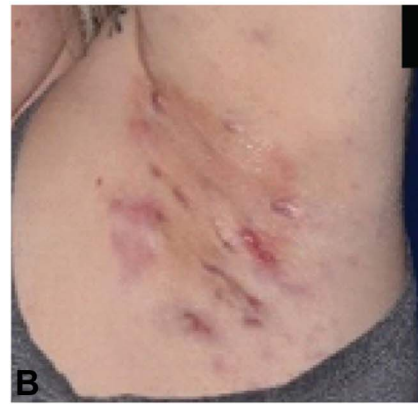
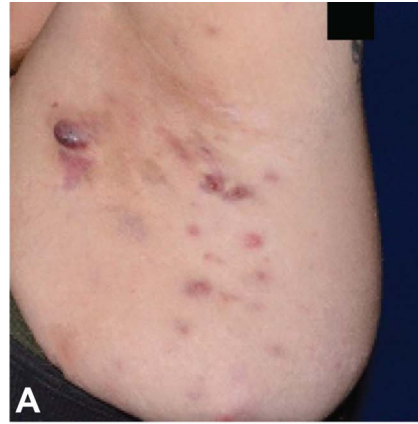


Fig. 4. Hidradenitis suppurativa patient before and during treatment with adalimumab. Baseline (A), week 12 (B), and week 52 (C). Images courtesy of Martin M. Okun, MD, PhD. Used with permission.

Sayed. Hidradenitis Suppurativa Management Update. Obstet Gynecol 2021.

identify risk factors for postoperative infection I (Puccini) [abstract]. *Gastroenterology* 2019;156:S-80).^{102,103}

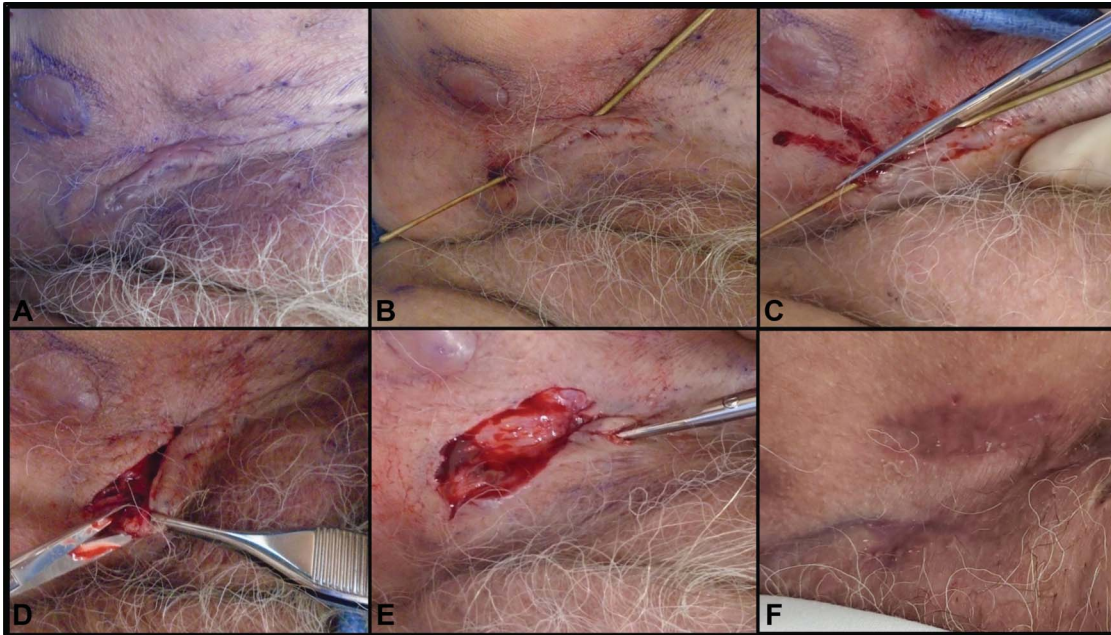


Fig. 5. Deroofing procedure for a female, age 71 years, with long-standing hidradenitis suppurativa. **A.** Cutaneous tunnel of inguinal region with multiple dilated follicular openings. **B.** Double-ended fistula probe entering and exiting two dilated openings. Iris scissors opening the tunnel at the level of the probe (**C**), excising the loose tissue edge from the roof of the tunnel (**D**), and probing and opening a small extension at the superior tip of the deroofted wound (**E**). A thick layer of petrolatum is applied before application of nonstick bandaging. **F.** Follow-up at postoperative week 21 with absence of inflammatory nodules, abscesses, or tunnels. Images courtesy of Christopher J. Sayed, MD. Used with permission.

Sayed. *Hidradenitis Suppurativa Management Update. Obstet Gynecol* 2021.

PAIN MANAGEMENT

Uncontrolled pain is a major cause of morbidity among individuals living with hidradenitis suppurativa. Many pain-management guidelines distinguish between nociceptive and neuropathic pain for treatment selection.^{104–107} Pain has been found to be both nociceptive (a direct consequence of disease activity, described as “throbbing,” “aching,” and “gnawing”) and neuropathic (dysfunction in central or peripheral nervous system, described as “burning,” “stabbing,” “stinging,” or like an electric shock)^{108,109} and both are exacerbated by comorbid anxiety and depression.¹⁰⁹ Owing to this complexity, multimodal therapy is essential.

The NAHS guidelines suggest that pain treatment begins with improved disease control,¹ but current therapies are sometimes inadequate,¹¹⁰ in which case pharmacologic and nonpharmacologic symptomatic treatments are indicated. Acute hidradenitis suppurativa flares may be treated with topical or systemic analgesics including acetaminophen, nonsteroidal antiinflammatory drugs, and limited courses of immediate release opioids (lowest dose and shortest possible duration, typically less than 2 weeks and fewer than 20 pills).^{111,112} The same pharmacologic classes

can be employed for management of chronic nociceptive pain when topical therapies are insufficient (Table 4). A multidisciplinary approach including physical therapy, wound care, and mental or behavioral health often yields the best outcomes for chronic pain.¹¹³ A pain specialist can help explore further options such as anticonvulsants, chronic opioids, implantable devices, and nerve blocks. In our experience, referral is appropriate when a patient: 1) has had at least two failed pharmacologic pain treatments, 2) has medically refractory hidradenitis suppurativa and debilitating pain deemed unlikely to improve despite maximal medical therapy, 3) is already using chronic opioids, or 4) is at high risk for substance use disorder.

DRESSINGS

Hidradenitis suppurativa wounds may be a consequence of disease or surgery, and require meticulous medical and surgical management. Drainage from tunnels and ulcers is an important concern for patients, so absorptive dressings that meet the dynamic needs of the wound or tunnel should be selected. Superabsorbent (eg, gelling polymers and fibers), absorbent (eg, abdominal pads), or calcium alginates and foams, in order of decreasing absorbency, can be used.¹¹⁴ Gentle

Table 4. Pharmacologic Analgesia for Chronic Pain in Hidradenitis Suppurativa

Medication	Starting Dose	Titration	Maximum Daily Dose	Risks
Gabapentin*	300 mg daily	300 mg for 1 d, 300 mg twice daily for 1 d, 300 mg 3 times daily for 1 d to max tolerated or therapeutic	3,600 mg	Drowsiness
Pregabalin†	150 mg daily divided twice or 3 times daily	After 1 wk, increase to 300 mg daily; in 2–4 more wk may increase to 600 mg daily	600 mg	Faster onset than gabapentin Crosses blood–brain barrier, causing euphoria
Duloxetine*	30 mg daily	After 1 wk, increase to 60 mg daily	120 mg	GI intolerance is common Occasional sexual dysfunction Black box warning for suicidality if 24 y or younger
Venlafaxine†	37.5–75 mg every day	Every week, increase dose by 75 mg/d	225 mg	In addition to duloxetine’s risks: Higher risk of QT _C prolongation and drowsiness than duloxetine
Desipramine	25 mg every bedtime	Every 3–7 d, increase dose by 25 mg/d	150 mg	Risk of QT _C prolongation; obtain pretreatment potassium for all patients and EKG if cardiac symptoms present or other QT _C prolonging meds Drowsiness Mild anticholinergic effects and weight gain
Nortriptyline†	25 mg every bedtime	Every 3–7 d, increase dose by 25 mg/d	150 mg	In addition to desipramine’s risks: Higher risk of anticholinergic effects
Amitriptyline	25 mg every bedtime	Every 3–7 d, increase dose by 25 mg/d	150 mg	In addition to nortriptyline and desipramine’s risks: Much higher risk of anticholinergic effects Much more sedating Weight gain

GI, gastrointestinal; EKG, electrocardiogram.

When long-term nonselective nonsteroidal antiinflammatory drugs (NSAIDs) must be used, a proton-pump inhibitor should be added. Naproxen is the NSAID of choice in individuals with high risk of cardiovascular disease.¹³⁹

* First-line for chronic neuropathic pain, second-line for chronic nociceptive pain.

† Second-line for chronic neuropathic pain.

adhesive borders reduce irritation and pain during dressing changes. Cost remains a significant barrier (silver-impregnated 4×4-inch foam sheets retail for approximately \$10 per sheet). Wound colonization and biofilms may be mitigated with antiseptic washes such as chlorhexidine and its derivatives or silver-based dressings (in exudative wounds). For postsurgical wound management, negative pressure wound therapy (NPWT) with delayed reconstruction for large axillary wounds may be useful.^{115,116}

SPECIAL POPULATIONS: PEDIATRICS AND PREGNANT

Pediatrics

Pediatric hidradenitis suppurativa is especially devastating because it strikes during the most formative years of children’s emotional development. As with

adults, pediatric patients bear a higher risk of metabolic syndrome, PCOS and psychiatric comorbidities. The NAHS guidelines recommend evaluating patients with hidradenitis suppurativa younger than 11 years for precocious puberty. Medical and surgical treatment options for pediatric and adult patients are similar. For acute flares antibiotics can be used, but in our practice, we limit treatment duration to 6 months, and avoid tetracyclines in children younger than 9 years. In 2018, adalimumab was approved by the U.S. Food and Drug Administration for adolescents aged 12 years and older with moderate-to-severe symptoms.

Pregnancy

Information on hidradenitis suppurativa and pregnancy is limited. Two European patient survey studies found an improvement during pregnancy in 20–30.2% and worsening in 8–16.7%,^{58,117} and 62%

flared during pregnancy in a U.S.-based retrospective chart review.¹¹⁸ More than 10% of these patients continued smoking cigarettes and marijuana, highlighting the importance of cessation counseling. Gestational diabetes, gestational hypertension, and preeclampsia were more common in this cohort compared with the general U.S. population, so screening is warranted; no statistically significant differences were found for miscarriage, stillbirth, cesarean delivery, and perinatal mortality.¹¹⁹

Hidradenitis suppurativa treatment during pregnancy is challenging, and co-management with dermatology is recommended. Topical agents such as benzoyl peroxide wash and clindamycin lotion, gel, or solution are safe. Acetaminophen is the analgesic of choice, and oral antibiotic options include clindamycin, rifampin, metronidazole,¹²⁰ and in the author's experience, cephalixin and some penicillin derivatives such as amoxicillin with clavulanate. For severe disease, a course of intravenous ertapenem may also be considered. Other systemic therapies to consider include metformin and zinc gluconate. In our practice, for the appropriately selected patient with active disease uncontrolled with other therapies, benefits of TNF antagonist therapy (such as adalimumab or infliximab) are considered to outweigh risks, particularly during the 1st and 2nd trimesters, with a recalibration of the risk-benefit analysis necessary during 3rd trimester because of increased placental transfer of monoclonal antibodies during this time.¹²¹ Neonates born to mothers who are continually treated with biologic agents should avoid live vaccinations (eg, rotavirus) for 6 months.¹²² Certolizumab is a pegylated TNF antagonist that does not cross the placental barrier, but there is a paucity of data regarding its use in hidradenitis suppurativa,^{123,124} and insurance coverage may be a barrier.

Although few safety data exist for procedures for hidradenitis suppurativa during pregnancy, intralesional triamcinolone and laser-based follicular destruction are likely safe. Excision with local anesthesia after the first trimester is also reasonable for recalcitrant areas.¹²⁰ Treatment with cryoinsufflation has been reported during pregnancy, but vagal reactions may occur.¹²⁵

Although expert consensus does not exist regarding how anogenital disease should affect delivery methods, author experience and survey data suggest it sometimes leads to recommendation for cesarean delivery, at times with specific use of high transverse or midline vertical incision to avoid involved areas (Fig. 3). These decisions should rely on open communication and shared decision-making between ob-gyns and patients.

Hidradenitis suppurativa may interfere with breast feeding. Of 134 infants born to affected mothers, about a quarter were bottle-fed, and maternal breast hidradenitis suppurativa was significantly associated with not breastfeeding.¹¹⁹ Painful axillary lesions making it difficult to lift the infant also interfere with breastfeeding, so proactive management during pregnancy and early counseling is important for supporting mothers planning to breastfeed.²⁰ Clindamycin and rifampin are compatible with breastfeeding.¹²⁰ Cephalixin, amoxicillin with clavulanate, and ertapenem are also compatible, though may cause infant diarrhea. Metformin has minimal excretion in breast milk without significant effect on infants.^{126,127} Adalimumab and infliximab appear to be safe during lactation though more data are needed.^{120,128}

CONCLUSIONS

Successful management of hidradenitis suppurativa is challenging and at times requires comprehensive care from a coordinated team of health care professionals, including dermatologists, general or plastic surgeons, experts in pain management and wound care, and gastroenterologists or rheumatologists. Patients most often seek care with primary care physicians, including ob-gyns, and only one in five Americans with hidradenitis suppurativa have an established relationship with a dermatologist.¹²⁹ Ob-gyns are uniquely poised to be front-line physicians for diagnosing and treating women with hidradenitis suppurativa, including partnering with dermatologists to significantly improve their care.

REFERENCES

1. Alikhan A, Sayed C, Alavi A, Alhusayen R, Brassard A, Burkhart C, et al. North American clinical management guidelines for hidradenitis suppurativa: a publication from the United States and Canadian hidradenitis suppurativa Foundations. Part I: diagnosis, evaluation, and the use of complementary and procedural management. *J Am Acad Dermatol* 2019;81:76–90. doi: 10.1016/j.jaad.2019.02.067
2. Alikhan A, Sayed C, Alavi A, Alhusayen R, Brassard A, Burkhart C, et al. North American clinical management guidelines for hidradenitis suppurativa: a publication from the United States and Canadian Hidradenitis Suppurativa Foundations: part II: topical, intralesional, and systemic medical management. *J Am Acad Dermatol* 2019;81:91–101. doi: 10.1016/j.jaad.2019.02.068
3. Reddy S, Strunk A, Garg A. All-cause mortality among patients with hidradenitis suppurativa: a population-based cohort study in the United States. *J Am Acad Dermatol* 2019;81:937–42. doi: 10.1016/j.jaad.2019.06.016
4. Garg A, Neuren E, Cha D, Kirby JS, Ingram JR, Jemec GBE, et al. Evaluating patients' unmet needs in hidradenitis suppurativa: results from the global survey of impact and healthcare needs (VOICE) project. *J Am Acad Dermatol* 2020;82:366–76. doi: 10.1016/j.jaad.2019.06.1301

5. Canoui-Poitrine F, Revuz JE, Wolkenstein P, Viallette C, Gabison G, Pouget F, et al. Clinical characteristics of a series of 302 French patients with hidradenitis suppurativa, with an analysis of factors associated with disease severity. *J Am Acad Dermatol* 2009;61:51–7. doi: 10.1016/j.jaad.2009.02.013
6. Vossen ARJV, van der Zee HH, Prens EP. Hidradenitis suppurativa: a systematic review integrating inflammatory pathways into a cohesive pathogenic model. *Front Immunol* 2018;9:2965. doi: 10.3389/fimmu.2018.02965
7. Garg A, Kirby JS, Lavian J, Lin G, Strunk A. Sex- and age-adjusted population analysis of prevalence estimates for hidradenitis suppurativa in the United States. *JAMA Dermatol* 2017;153:760–4. doi: 10.1001/jamadermatol.2017.0201
8. Ingram JR, Jenkins-Jones S, Knipe DW, Morgan CLI, Cannings-John R, Piguet V. Population-based Clinical Practice Research Datalink study using algorithm modelling to identify the true burden of hidradenitis suppurativa. *Br J Dermatol* 2018;178:917–24. doi: 10.1111/bjd.16101
9. Revuz JE, Canoui-Poitrine F, Wolkenstein P, Viallette C, Gabison G, Pouget F, et al. Prevalence and factors associated with hidradenitis suppurativa: results from two case-control studies. *J Am Acad Dermatol* 2008;59:596–601. doi: 10.1016/j.jaad.2008.06.020
10. Garg A, Papagermanos V, Midura M, Strunk A. Incidence of hidradenitis suppurativa among tobacco smokers: a population-based retrospective analysis in the U.S.A. *Br J Dermatol* 2018;178:709–14. doi: 10.1111/bjd.15939
11. Reddy S, Strunk A, Garg A. Comparative overall comorbidity burden among patients with hidradenitis suppurativa. *JAMA Dermatol* 2019;155:797–802. doi: 10.1001/jamadermatol.2019.0164
12. Garg A, Neuren E, Strunk A. Hidradenitis suppurativa is associated with polycystic ovary syndrome: a population-based analysis in the United States. *J Invest Dermatol* 2018;138:1288–92. doi: 10.1016/j.jid.2018.01.009
13. Barth JH, Layton AM, Cunliffe WJ. Endocrine factors in pre- and postmenopausal women with hidradenitis suppurativa. *Br J Dermatol* 1996;134:1057–9.
14. Matusiak L, Bieniek A, Szepietowski JC. Psychophysical aspects of hidradenitis suppurativa. *Acta Derm Venereol* 2010;90:264–8. doi: 10.2340/00015555-0866
15. Onderdijk AJ, van der Zee HH, Esmann S, Lophaven S, Dufour DN, Jemec GB, et al. Depression in patients with hidradenitis suppurativa. *J Eur Acad Dermatol Venereol* 2013;27:473–8. doi: 10.1111/j.1468-3083.2012.04468.x
16. Thorlacius L, Cohen AD, Gislason GH, Jemec GBE, Egeberg A. Increased suicide risk in patients with hidradenitis suppurativa. *J Invest Dermatol* 2018;138:52–7. doi: 10.1016/j.jid.2017.09.008
17. Tiri H, Huilaja L, Jokelainen J, Timonen M, Tasanen K. Women with hidradenitis suppurativa have an elevated risk of suicide. *J Invest Dermatol* 2018;138:2672–4. doi: 10.1016/j.jid.2018.06.171
18. Garg A, Papagermanos V, Midura M, Strunk A, Merson J. Opioid, alcohol, and cannabis misuse among patients with hidradenitis suppurativa: a population-based analysis in the United States. *J Am Acad Dermatol* 2018;79:495–500.e1. doi: 10.1016/j.jaad.2018.02.053
19. Reddy S, Orenstein LAV, Strunk A, Garg A. Incidence of long-term opioid use among opioid-naïve patients with hidradenitis suppurativa in the United States. *JAMA Dermatol* 2019;155:1284–90. doi: 10.1001/jamadermatol.2019.2610
20. Collier E, Shi VY, Parvataneni RK, Lowes MA, Hsiao JL. Special considerations for women with hidradenitis suppurativa. *Int J Womens Dermatol* 2020;6:85–8. doi: 10.1016/j.ijwd.2020.02.005
21. Sartorius K, Emtestam L, Jemec GB, Lapins J. Objective scoring of hidradenitis suppurativa reflecting the role of tobacco smoking and obesity. *Br J Dermatol* 2009;161:831–9. doi: 10.1111/j.1365-2133.2009.09198.x
22. Zouboulis CC, Bechara FG, Fritz K, Kurzen H, Liakou AI, Marsch WC, et al. S1 guideline for the treatment of hidradenitis suppurativa/acne inversa * (number ICD-10 L73.2) [in German]. *J Dtsch Dermatol Ges* 2012;10(suppl 5):S1–31. doi: 10.1111/j.1610-0387.2012.08006.x
23. Schrader AM, Deckers IE, van der Zee HH, Boer J, Prens EP. Hidradenitis suppurativa: a retrospective study of 846 Dutch patients to identify factors associated with disease severity. *J Am Acad Dermatol* 2014;71:460–7. doi: 10.1016/j.jaad.2014.04.001
24. Denny G, Anadkat MJ. The effect of smoking and age on the response to first-line therapy of hidradenitis suppurativa: An institutional retrospective cohort study. *J Am Acad Dermatol* 2017;76:54–9. doi: 10.1016/j.jaad.2016.07.041
25. Simonart T. Hidradenitis suppurativa and smoking. *J Am Acad Dermatol* 2010;62:149–50. doi: 10.1016/j.jaad.2009.08.001
26. Patnode CD, Henderson JT, Thompson JH, Senger CA, Fortmann SP, Whitlock EP. behavioral counseling and pharmacotherapy interventions for tobacco cessation in adults, including pregnant women: a review of reviews for the U.S. Preventive Services Task Force. *Ann Intern Med* 2015;163:608–21. doi: 10.7326/m15-0171
27. Vazquez BG, Alikhan A, Weaver AL, Wetter DA, Davis MD. Incidence of hidradenitis suppurativa and associated factors: a population-based study of Olmsted County, Minnesota. *J Invest Dermatol* 2013;133:97–103. doi: 10.1038/jid.2012.255
28. Boer J. Resolution of hidradenitis suppurativa after weight loss by dietary measures, especially on frictional locations. *J Eur Acad Dermatol Venereol* 2016;30:895–6. doi: 10.1111/jdv.13059
29. Thomas CL, Gordon KD, Mortimer PS. Rapid resolution of hidradenitis suppurativa after bariatric surgical intervention. *Clin Exp Dermatol* 2014;39:315–8. doi: 10.1111/ced.12269
30. Scheinfeld N. Hidradenitis suppurativa: a practical review of possible medical treatments based on over 350 hidradenitis patients. *Dermatol Online J* 2013;19:1
31. Kromann CB, Ibler KS, Kristiansen VB, Jemec GB. The influence of body weight on the prevalence and severity of hidradenitis suppurativa. *Acta Derm Venereol* 2014;94:553–7. doi: 10.2340/00015555-1800
32. LeBlanc E, O'Connor E, Whitlock EP, Patnode C, Kapka T. Screening for and management of obesity and overweight in adults. Report no.: 11-05159-EF-1. Agency for Healthcare Research and Quality (US); 2011.
33. Danby FW. Diet in the prevention of hidradenitis suppurativa (acne inversa). *J Am Acad Dermatol* 2015;73(5 Suppl 1):S52–4. doi: 10.1016/j.jaad.2015.07.042
34. Cannistrà C, Finocchi V, Trivisonno A, Tambasco D. New perspectives in the treatment of hidradenitis suppurativa: surgery and brewer's yeast-exclusion diet. *Surgery* 2013;154:1126–30. doi: 10.1016/j.surg.2013.04.018

35. Boer J, Mihajlovic D. Boils at frictional locations in a patient with hidradenitis suppurativa. *Acta Dermatovenerol Croat* 2016;24:303-4.
36. Dufour DN, Bryld LE, Jemec GB. Hidradenitis suppurativa complicating naevus comedonicus: the possible influence of mechanical stress on the development of hidradenitis suppurativa. *Dermatology (Basel, Switzerland)* 2010;220:323-5. doi: 10.1159/000287261
37. Bettoli V, Toni G, Ricci M, Zauli S, Virgili A. Hidradenitis suppurativa-acne inversa-like lesions complicating naevus comedonicus: second case supporting the mechanical stress as a triggering factor. *G Ital Dermatol Venereol* 2016;151:306-7.
38. de Winter K, van der Zee HH, Prens EP. Is mechanical stress an important pathogenic factor in hidradenitis suppurativa? *Exp Dermatol* 2012;21:176-7. doi: 10.1111/j.1600-0625.2012.01443.x
39. von der Werth JM, Williams HC. The natural history of hidradenitis suppurativa. *J Eur Acad Dermatol Venereol* 2000;14:389-92. doi: 10.1046/j.1468-3083.2000.00087.x
40. Edlich RF, Silloway KA, Rodeheaver GT, Cooper PH. Epidemiology, pathology, and treatment of axillary hidradenitis suppurativa. *J Emerg Med* 1986;4:369-78. doi: 10.1016/0736-4679(86)90214-3
41. Morgan WP, Leicester G. The role of depilation and deodorants in hidradenitis suppurativa. *Arch Dermatol* 1982;118:101-2.
42. Kearney N, Byrne N, Kirby B, Hughes R. Complementary and alternative medicine use in hidradenitis suppurativa. *Br J Dermatol* 2019;182:484-5. doi: 10.1111/bjd.18426
43. Brocard A, Knol AC, Khammari A, Dreno B. Hidradenitis suppurativa and zinc: a new therapeutic approach. A pilot study. *Dermatology* 2007;214:325-7. doi: 10.1159/000100883
44. Hessam S, Sand M, Meier NM, Gambichler T, Scholl L, Bechara FG. Combination of oral zinc gluconate and topical triclosan: an anti-inflammatory treatment modality for initial hidradenitis suppurativa. *J Dermatol Sci* 2016;84:197-202. doi: 10.1016/j.jdermsci.2016.08.010
45. Guillet A, Brocard A, Bach Nghouh K, Graveline N, Leloup AG, Ali D, et al. Verneuil's disease, innate immunity and vitamin D: a pilot study. *J Eur Acad Dermatol Venereol* 2015;29:1347-53. doi: 10.1111/jdv.12857
46. Clemmensen OJ. Topical treatment of hidradenitis suppurativa with clindamycin. *Int J Dermatol* 1983;22:325-8. doi: 10.1111/j.1365-4362.1983.tb02150.x
47. Jemec GB, Wendelboe P. Topical clindamycin versus systemic tetracycline in the treatment of hidradenitis suppurativa. *J Am Acad Dermatol* 1998;39:971-4. doi: 10.1016/s0190-9622(98)70272-5
48. Riis PT, Boer J, Prens EP, Saunte DM, Deckers IE, Emtestam L, et al. Intralesional triamcinolone for flares of hidradenitis suppurativa (HS): a case series. *J Am Acad Dermatol* 2016;75:1151-5. doi: 10.1016/j.jaad.2016.06.049
49. Zouboulis CC, Tzellos T, Kyrgidis A, Jemec GBE, Bechara FG, Giamarellos-Bourboulis EJ, et al. Development and validation of the International Hidradenitis Suppurativa Severity Score System (IHS4), a novel dynamic scoring system to assess HS severity. *Br J Dermatol* 2017;177:1401-9. doi: 10.1111/bjd.15748
50. Orenstein LAV, Nguyen TV, Damiani G, Sayed C, Jemec GBE, Hamzavi I. Medical and surgical management of hidradenitis suppurativa: a review of international treatment guidelines and implementation in general dermatology practice. *Dermatology* 2020;236:393-412. doi: 10.1159/000507323
51. Bettoli V, Zauli S, Borghi A, Toni G, Minghetti S, Ricci M, et al. Oral clindamycin and rifampicin in the treatment of hidradenitis suppurativa-acne inversa: a prospective study on 23 patients. *J Eur Acad Dermatol Venereol* 2014;28:125-6. doi: 10.1111/jdv.12127
52. Gener G, Canoui-Poitrine F, Revuz JE, Faye O, Poli F, Gabison G, et al. Combination therapy with clindamycin and rifampicin for hidradenitis suppurativa: a series of 116 consecutive patients. *Dermatology* 2009;219:148-54. doi: 10.1159/000228334
53. van der Zee HH, Boer J, Prens EP, Jemec GB. The effect of combined treatment with oral clindamycin and oral rifampicin in patients with hidradenitis suppurativa. *Dermatology* 2009;219:143-7. doi: 10.1159/000228337
54. Mendonça CO, Griffiths CE. Clindamycin and rifampicin combination therapy for hidradenitis suppurativa. *Br J Dermatol* 2006;154:977-8. doi: 10.1111/j.1365-2133.2006.07155.x
55. Caposiena Caro RD, Cannizzaro MV, Botti E, Di Raimondo C, Di Matteo E, Gaziano R, et al. Clindamycin versus clindamycin plus rifampicin in hidradenitis suppurativa treatment: Clinical and ultrasound observations. *J Am Acad Dermatol* 2019;80:1314-21. doi: 10.1016/j.jaad.2018.11.035
56. Albrecht J, Baine PA, Ladizinski B, Jemec GB, Bigby M. Long-term clinical safety of clindamycin and rifampicin combination for the treatment of hidradenitis suppurativa. A Critically Appraised Topic. *Br J Dermatol* 2019;180:749-55. doi: 10.1111/bjd.17265
57. Riis PT, Ring HC, Themstrup L, Jemec GB. The role of androgens and estrogens in hidradenitis suppurativa—a systematic review. *Acta Dermatovenerol Croat* 2016;24:239-49.
58. Vossen AR, van Straalen KR, Prens EP, van der Zee HH. Menses and pregnancy affect symptoms in hidradenitis suppurativa: a cross-sectional study. *J Am Acad Dermatol* 2017;76:155-6. doi: 10.1016/j.jaad.2016.07.024
59. Harrison BJ, Kumar S, Read GF, Edwards CA, Scanlon MF, Hughes LE. Hidradenitis suppurativa: evidence for an endocrine abnormality. *Br J Surg* 1985;72:1002-4. doi: 10.1002/bjs.1800721223
60. Mortimer PS, Dawber RP, Gales MA, Moore RA. A double-blind controlled cross-over trial of cyproterone acetate in females with hidradenitis suppurativa. *Br J Dermatol* 1986;115:263-8. doi: 10.1111/j.1365-2133.1986.tb05740.x
61. Stellon AJ, Wakeling M. Hidradenitis suppurativa associated with use of oral contraceptives. *BMJ* 1989;298:28-9. doi: 10.1136/bmj.298.6665.28
62. Khandalavala BN, Do MV. Finasteride in hidradenitis suppurativa: a "male" therapy for a predominantly "female" disease. *J Clin Aesthet Dermatol* 2016;9:44-50.
63. Kraft JN, Searles GE. Hidradenitis suppurativa in 64 female patients: retrospective study comparing oral antibiotics and antiandrogen therapy. *J Cutan Med Surg* 2007;11:125-31. doi: 10.2310/7750.2007.00019
64. Verdolini R, Clayton N, Smith A, Alwash N, Mannello B. Metformin for the treatment of hidradenitis suppurativa: a little help along the way. *J Eur Acad Dermatol Venereol* 2013;27:1101-8. doi: 10.1111/j.1468-3083.2012.04668.x

65. Boer J, Nazary M. Long-term results of acitretin therapy for hidradenitis suppurativa. Is acne inversa also a misnomer?. *Br J Dermatol* 2011;164:170–5. doi: 10.1111/j.1365-2133.2010.10071.x
66. Huang CM, Kirchoff MG. A new perspective on isotretinoin treatment of hidradenitis suppurativa: a retrospective chart review of patient outcomes. *Dermatology* 2017;233:120–5. doi: 10.1159/000477207
67. Nazary M, van der Zee HH, Prens EP, Folkerts G, Boer J. Pathogenesis and pharmacotherapy of Hidradenitis suppurativa. *Eur J Pharmacol* 2011;672:1–8. doi: 10.1016/j.ejphar.2011.08.047
68. Anderson MD, Zauli S, Bettoli V, Boer J, Jemec GB. Cyclosporine treatment of severe Hidradenitis suppurativa—a case series. *J Dermatolog Treat* 2016;27:247–50. doi: 10.3109/09546634.2015.1088128
69. Bianchi L, Hansel K, Stingeni L. Recalcitrant severe hidradenitis suppurativa successfully treated with cyclosporine A. *J Am Acad Dermatol* 2012;67:e278–9. doi: 10.1016/j.jaad.2012.06.011
70. Buckley DA, Rogers S. Cyclosporin-responsive hidradenitis suppurativa. *J R Soc Med* 1995;88:289–90P.
71. Jemec GBE. Methotrexate is of limited value in the treatment of hidradenitis suppurativa. *Clin Exp Dermatol* 2002;27:528–9. doi: 10.1046/j.1365-2230.2002.11125.x
72. Nazary M, Prens EP, Boer J. Azathioprine lacks efficacy in hidradenitis suppurativa: a retrospective study of nine patients. *Br J Dermatol* 2016;174:639–41. doi: 10.1111/bjd.14086
73. Wong D, Walsh S, Alhusayen R. Low-dose systemic corticosteroid treatment for recalcitrant hidradenitis suppurativa. *J Am Acad Dermatol* 2016;75:1059–62. doi: 10.1016/j.jaad.2016.06.001
74. Zouboulis CC, Desai N, Emtestam L, Hunger RE, Ioannides D, Juhász I, et al. European S1 guideline for the treatment of hidradenitis suppurativa/acne inversa. *J Eur Acad Dermatol Venereol* 2015;29:619–44. doi: 10.1111/jdv.12966
75. HUMIRA® [Package insert]. North Chicago, IL. AbbVie, Inc.; 2020.
76. Kimball AB, Okun MM, Williams DA, Gottlieb AB, Papp KA, Zouboulis CC, et al. Two phase 3 trials of adalimumab for hidradenitis suppurativa. *N Engl J Med* 2016;375:422–34. doi: 10.1056/NEJMoa1504370
77. Moriarty B, Jiyad Z, Creamer D. Four-weekly infliximab in the treatment of severe hidradenitis suppurativa. *Br J Dermatol* 2014;170:986–7. doi: 10.1111/bjd.12713
78. Oskardmay AN, Miles JA, Sayed CJ. Determining the optimal dose of infliximab for treatment of hidradenitis suppurativa. *J Am Acad Dermatol* 2019;81:702–8. doi: 10.1016/j.jaad.2019.05.022
79. Kohorst JJ, Baum CL, Otley CC, Roenigk RK, Schenck LA, Pemberton JH, et al. Surgical management of hidradenitis suppurativa: outcomes of 590 consecutive patients. *Dermatol Surg* 2016;42:1030–40. doi: 10.1097/DSS.0000000000000806
80. Mehdizadeh A, Hazen PG, Bechara FG, Zwingerman N, Moazenzadeh M, Bashash M, et al. Recurrence of hidradenitis suppurativa after surgical management: a systematic review and meta-analysis. *Meta-analysis review. J Am Acad Dermatol* 2015;73(5 suppl 1):S70–7. doi: 10.1016/j.jaad.2015.07.044
81. Ritz JP, Runkel N, Haier J, Buhr HJ. Extent of surgery and recurrence rate of hidradenitis suppurativa. *Int J Colorectal Dis* 1998;13:164–8. doi: 10.1007/s003840050159
82. Kohorst JJ, Baum CL, Otley CC, Roenigk RK, Pemberton JH, Dozois EJ, et al. Patient satisfaction and quality of life following surgery for hidradenitis suppurativa. *Dermatol Surg* 2017;43:125–33. doi: 10.1097/DSS.0000000000000942
83. O'Malley GF, Dominici P, Giraldo P, Aguilera E, Verma M, Lares C, et al. Routine packing of simple cutaneous abscesses is painful and probably unnecessary. *Acad Emerg Med* 2009;16:470–3. doi: 10.1111/j.1553-2712.2009.00409.x
84. van der Zee HH, Prens EP, Boer J. Deroofing: a tissue-saving surgical technique for the treatment of mild to moderate hidradenitis suppurativa lesions. *J Am Acad Dermatol* 2010;63:475–80. doi: 10.1016/j.jaad.2009.12.018
85. Lin CH, Chang KP, Huang SH. deroofing: an effective method for treating chronic diffuse hidradenitis suppurativa. *Case reports letter. Dermatol* 2016;42:273–5. doi: 10.1097/DSS.0000000000000609
86. van Hattem S, Spoo JR, Horvath B, Jonkman MF, Leeman FW. Surgical treatment of sinuses by deroofing in hidradenitis suppurativa. *Dermatol Surg* 2012;38:494–7. doi: 10.1111/j.1524-4725.2011.02255.x
87. Miedema J, Sayed C. Staged excision in the outpatient setting for the treatment of axillary hidradenitis suppurativa. *Case reports letter. Dermatol* 2016;42:267–9. doi: 10.1097/DSS.0000000000000620
88. Tchernev G, Temelkova I. Hidradenitis suppurativa (Hurley I/II): serial excisions with primary wound closure under local anesthesia as most adequate treatment approach. *Open Access Maced J Med Sci* 2019;7:400–2. doi: 10.3889/oamjms.2019.148
89. Silverberg B, Smoot CE, Landa SJ, Parsons RW. Hidradenitis suppurativa: patient satisfaction with wound healing by secondary intention. *Plast Reconstr Surg* 1987;79:555–9.
90. Kofler L, Schweinzer K, Heister M, Kohler M, Breuninger H, Häfner HM. Surgical treatment of hidradenitis suppurativa: an analysis of postoperative outcome, cosmetic results and quality of life in 255 patients. *J Eur Acad Dermatol Venereol* 2018;32:1570–4. doi: 10.1111/jdv.14892
91. Tierney E, Mahmoud BH, Hexsel C, Ozog D, Hamzavi I. Randomized control trial for the treatment of hidradenitis suppurativa with a neodymium-doped yttrium aluminium garnet laser. *Dermatol Surg* 2009;35:1188–98. doi: 10.1111/j.1524-4725.2009.01214.x
92. Xu LY, Wright DR, Mahmoud BH, Ozog DM, Mehregan DA, Hamzavi IH. Histopathologic study of hidradenitis suppurativa following long-pulsed 1064-nm Nd:YAG laser treatment. *Randomized Controlled Trial Research Support, Non-U.S. Gov't. Arch Dermatol* 2011;147:21–8. doi: 10.1001/archdermatol.2010.245
93. Jain V, Jain A. Use of lasers for the management of refractory cases of hidradenitis suppurativa and pilonidal sinus. *J Cutan Aesthet Surg* 2012;5:190–2. doi: 10.4103/0974-2077.101377
94. John H, Manoloudakis N, Stephen Sinclair J. A systematic review of the use of lasers for the treatment of hidradenitis suppurativa. *J Plast Reconstr Aesthet Surg.* 2016;69:1374–81. doi: 10.1016/j.bjps.2016.05.029
95. Zerbinati N, D'Este E, Ini L, et al. Clinical and histological changes in Hidradenitis suppurativa following 1064 nm nd: YAG intralesional laser treatment. *J Biol Regul Homeost Agents* 2017;31(2 suppl 2):131–40.
96. Downs A. Smoothbeam laser treatment may help improve hidradenitis suppurativa but not Hailey-Hailey disease. *J Cosmet Laser Ther* 2004;6:163–4. doi: 10.1080/14764170410003002

97. Sehgal VN, Verma P, Sawant S, Paul M. Contemporary surgical treatment of hidradenitis suppurativa (HS) with a focus on the use of the diode hair laser in a case. Case reports review. *J Cosmet Laser Ther* 2011;13:180–90. doi: 10.3109/14764172.2011.594066
98. Fabbrocini G, Franca K, Lotti T, Marasca C, Annunziata MC, Cacciapuoti S, et al. Intralesional diode laser 1064 nm for the treatment of hidradenitis suppurativa: a report of twenty patients. *Open Access Maced J Med Sci* 2018;6:31–4. doi: 10.3889/oamjms.2018.045
99. Highton L, Chan WY, Khwaja N, Laitung JK. Treatment of hidradenitis suppurativa with intense pulsed light: a prospective study. *Plast Reconstr Surg* 2011;128:459–66. doi: 10.1097/PRS.0b013e31821e6fb5
100. Piccolo D, Di Marcantonio D, Crisman G, Cannarozzo G, Sannino M, Chiricozzi A, et al. Unconventional use of intense pulsed light. *Biomed Res Int* 2014;2014:618206. doi: 10.1155/2014/618206
101. Saunte DM, Lapins J. Lasers and intense pulsed light hidradenitis suppurativa. *Dermatol Clin* 2016;34:111–9. doi: 10.1016/j.det.2015.08.001
102. Adamina M, Bonovas S, Raine T, Spinelli A, Warusavitarne J, Armuzzi A, et al. ECCO guidelines on therapeutics in Crohn's disease: surgical treatment. *J Crohns Colitis* 2020;14:155–168. doi: 10.1093/ecco-jcc/ijz187
103. Xu Y, Yang L, An P, Zhou B, Liu G. Meta-analysis: the influence of preoperative infliximab use on postoperative complications of Crohn's disease. *Inflamm Bowel Dis* 2019;25:261–9. doi: 10.1093/ibd/izy246
104. Jongen JL, Hans G, Benzou HT, Huygen F, Hartrick CT. Neuropathic pain and pharmacological treatment. *Pain Pract* 2014;14:283–95. doi: 10.1111/papr.12085
105. Dworkin RH, O'Connor AB, Audette J, Baron R, Gourlay GK, Haanpää ML, et al. Recommendations for the pharmacological management of neuropathic pain: an overview and literature update. *Mayo Clin Proc* 2010;85(3 Suppl):S3–14. doi: 10.4065/mcp.2009.0649
106. Chou R, Fanciullo GJ, Fine PG, Adler JA, Ballantyne JC, Davies P, et al. Clinical guidelines for the use of chronic opioid therapy in chronic noncancer pain. *J Pain* 2009;10:113–30. doi: 10.1016/j.jpain.2008.10.008
107. Bruce RD, Merlin J, Lum PJ, Ahmed E, Alexander C, Corbett AH, et al. 2017 HIVMA of IDSA clinical practice guideline for the management of chronic pain in patients living with HIV. *Clin Infect Dis* 2017;65:e1–37. doi: 10.1093/cid/cix636
108. Nielsen RM, Lindsø Andersen P, Sigsgaard V, Theut Riis P, Jemec GB. Pain perception in patients with hidradenitis suppurativa. *Br J Dermatol* 2020;182:166–74. doi: 10.1111/bjd.17935
109. Huilaja L, Hirvonen MJ, Lipitsä T, Vihervaara A, Harvima R, Sintonen H, et al. Patients with hidradenitis suppurativa may suffer from neuropathic pain: a Finnish multicenter study. *J Am Acad Dermatol* 2019;82:1232–4. doi: 10.1016/j.jaad.2019.11.016
110. Kimball AB, Sundaram M, Shields AL, Hudgens S, Okun M, Foley C, et al. Adalimumab alleviates skin pain in patients with moderate-to-severe hidradenitis suppurativa: Secondary efficacy results from the PIONEER I and PIONEER II randomized controlled trials. *J Am Acad Dermatol* 2018;79:1141–3. doi: 10.1016/j.jaad.2018.05.015
111. Brouwers MC, Kho ME, Browman GP, Burgers JS, Cluzeau F, Feder G, et al. Development of the AGREE II, part 2: assessment of validity of items and tools to support application. *CMAJ* 2010;182:E472–8. doi: 10.1503/cmaj.091716
112. Hegmann KT, Weiss MS, Bowden K, Branco F, DuBrueler K, Els C, et al. ACOEM practice guidelines: opioids for treatment of acute, subacute, chronic, and postoperative pain. *J Occup Environ Med* 2014;56:e143–59. doi: 10.1097/JOM.0000000000000352
113. Kamper SJ, Apeldoorn AT, Chiarotto A, Smeets RJ, Ostelo RW, Guzman J, et al. Multidisciplinary biopsychosocial rehabilitation for chronic low back pain: Cochrane systematic review and meta-analysis. *BMJ* 2015;350:h444. doi: 10.1136/bmj.h444
114. Alavi A, Sibbald RG, Kirsner RS. Optimal hidradenitis suppurativa topical treatment and wound care management: a revised algorithm. *J Dermatolog Treat* 2018;29:383–4. doi: 10.1080/09546634.2017.1385719
115. Gonzaga TA, Endorf FW, Mohr WJ, Ahrenholz DH. Novel surgical approach for axillary hidradenitis suppurativa using a bilayer dermal regeneration template: a retrospective case study. *J Burn Care Res* 2013;34:51–7. doi: 10.1097/BCR.0b013e31826a7be7
116. Pearce FB, Richardson KA. Negative pressure wound therapy, staged excision and definitive closure with split-thickness skin graft for axillary hidradenitis suppurativa: a retrospective study. *J Wound Care* 2017;26(suppl 1):S36–42. doi: 10.12968/jowc.2017.26.Sup1.S36
117. Kromann CB, Deckers IE, Esmann S, Boer J, Prens EP, Jemec GB. Risk factors, clinical course and long-term prognosis in hidradenitis suppurativa: a cross-sectional study. *Br J Dermatol* 2014;171:819–24. doi: 10.1111/bjd.13090
118. Lyons AB, Peacock A, McKenzie SA, Jacobsen G, Naik HB, Shi VY, et al. Evaluation of hidradenitis suppurativa disease course during pregnancy and postpartum. *JAMA Dermatol* 2020;156:681–5. doi: 10.1001/jamadermatol.2020.0777
119. Lyons AB, Peacock A, McKenzie SA, Jacobsen G, Naik HB, Shi VY, et al. Retrospective cohort study of pregnancy outcomes in hidradenitis suppurativa. *Br J Dermatol* 2020;183:945–7. doi: 10.1111/bjd.19155
120. Perng P, Zampella JG, Okoye GA. Management of hidradenitis suppurativa in pregnancy. *J Am Acad Dermatol* 2017;76:979–89. doi: 10.1016/j.jaad.2016.10.032
121. Androulakis I, Zavos C, Christopoulos P, Mastorakos G, Gazouli M. Safety of anti-tumor necrosis factor therapy during pregnancy in patients with inflammatory bowel disease. *World J Gastroenterol* 2015;21:13205–11. doi: 10.3748/wjg.v21.i47.13205
122. Smith CH, Yiu ZZN, Bale T, Burden AD, Coates LC, Edwards W, et al. British Association of Dermatologists guidelines for biologic therapy for psoriasis 2020: a rapid update. *Br J Dermatol* 2020;83:628–37. doi: 10.1111/bjd.19039
123. Savage KT, Flood KS, Porter ML, Kimball AB. TNF- α inhibitors in the treatment of hidradenitis suppurativa. *Ther Adv Chronic Dis* 2019;10:2040622319851640. doi: 10.1177/2040622319851640
124. Naik HB, McGinness A, Shinkai K. Concurrent anticytokine biologics for the management of severe hidradenitis suppurativa: are they safe and effective? *Cutis* 2018;101:163;164;176.
125. Pagliarello C, Fabrizi G, Feliciani C, Di Nuzzo S. Cryoinsufflation for Hurley stage II hidradenitis suppurativa: a useful

treatment option when systemic therapies should be avoided. *JAMA Dermatol* 2014;150:765–6. doi: 10.1001/jamadermatol.2014.430

126. Hale T, Kristensen J, Hackett L, Kohan R, Ilett K. Transfer of metformin into human milk. *Adv Exp Med Biol* 2004;554: 435–6. doi: 10.1007/978-1-4757-4242-8_58
127. Briggs GG, Ambrose PJ, Nageotte MP, Padilla G, Wan S. Excretion of metformin into breast milk and the effect on nursing infants. *Obstet Gynecol* 2005;105:1437–41. doi: 10.1097/01.AOG.0000163249.65810.5b
128. Menter A, Strober BE, Kaplan DH, Kivelevitch D, Prater EF, Stoff B, et al. Joint AAD-NPF guidelines of care for the management and treatment of psoriasis with biologics. *J Am Acad Dermatol* 2019;80:1029–72. doi: 10.1016/j.jaad.2018.11.057
129. Garg A, Lavian J, Strunk A. Low utilization of the dermatology ambulatory encounter among patients with hidradenitis suppurativa: a population-based retrospective cohort analysis in the USA. *Dermatology* 2017;233:396–8. doi: 10.1159/000480379
130. Wertenteil S, Strunk A, Garg A. Overall and subgroup prevalence of acne vulgaris among patients with hidradenitis suppurativa. *J Am Acad Dermatol* 2019;80:e131–2. doi: 10.1016/j.jaad.2018.11.022
131. Tannenbaum R, Strunk A, Garg A. Overall and subgroup prevalence of pyoderma gangrenosum among patients with hidradenitis suppurativa: a population-based analysis in the United States. *J Am Acad Dermatol* 2019;80:1533–7. doi: 10.1016/j.jaad.2019.02.004
132. Garg A, Birabakaran M, Strunk A. Prevalence of type 2 diabetes mellitus among patients with hidradenitis suppurativa in the United States. *J Am Acad Dermatol* 2018;79:71–6. doi: 10.1016/j.jaad.2018.01.014
133. Tzellos T, Zouboulis CC, Gulliver W, Cohen AD, Wolkenstein P, Jemec GB. Cardiovascular disease risk factors in patients with hidradenitis suppurativa: a systematic review and meta-analysis of observational studies. *Br J Dermatol* 2015;173:1142–55. doi: 10.1111/bjd.14024
134. Reddy S, Strunk A, Jemec GBE, Garg A. Incidence of myocardial infarction and cerebrovascular accident in patients with hidradenitis suppurativa. *JAMA Dermatol* 2020;156:65–71. doi: 10.1001/jamadermatol.2019.3412
135. Garg A, Hundal J, Strunk A. Overall and subgroup prevalence of Crohn disease among patients with hidradenitis suppurativa: a population-based analysis in the United States. *JAMA Dermatol* 2018;154:814–8. doi: 10.1001/jamadermatol.2018.0878
136. Shavit E, Dreiherr J, Freud T, Halevy S, Vinker S, Cohen AD. Psychiatric comorbidities in 3207 patients with hidradenitis suppurativa. *J Eur Acad Dermatol Venereol* 2015;29:371–6. doi: 10.1111/jdv.12567
137. Wertenteil S, Strunk A, Garg A. Incidence of obstructive sleep apnoea in patients with hidradenitis suppurativa: a retrospective population-based cohort analysis. *Br J Dermatol* 2018; 179:1398–9. doi: 10.1111/bjd.16931
138. Tannenbaum R, Strunk A, Garg A. Association between hidradenitis suppurativa and lymphoma. *JAMA Dermatol* 2019;155:624–5. doi: 10.1001/jamadermatol.2018.5230
139. Burmester G, Lanasa A, Biasucci L, Hermann M, Lohmander S, Olivieri I, et al. The appropriate use of non-steroidal anti-inflammatory drugs in rheumatic disease: opinions of a multidisciplinary European expert panel. *Ann Rheum Dis* 2011; 70:818–22. doi: 10.1136/ard.2010.128660

PEER REVIEW HISTORY

Received September 27, 2020. Received in revised form November 19, 2020. Accepted December 3, 2020. Peer reviews are available at <http://links.lww.com/AOG/C233>.

CME FOR THE CLINICAL EXPERT SERIES

Learning Objectives for “Clinical Epidemiology and Management of Hidradenitis Suppurativa”

After completing this learning experience, the involved learner should be able to:

- Discuss the pathophysiology of hidradenitis suppurativa
- List other diagnoses that should be considered for patients presenting with symptoms of hidradenitis suppurativa
- Implement an effective management strategy for patients with this condition

Instructions for Obtaining *AMA PRA Category 1 Credits*[™]

Continuing Medical Education credit is provided through joint providership with The American College of Obstetricians and Gynecologists.

Obstetrics & Gynecology includes CME-certified content that is designed to meet the educational needs of its readers. This article is certified for 2 *AMA PRA Category 1 Credits*[™]. This activity is available for credit through April 30, 2024.

Accreditation Statement

ACCME Accreditation

The American College of Obstetricians and Gynecologists is accredited by the Accreditation Council for Continuing Medical Education (ACCME) to provide continuing medical education for physicians.

AMA PRA Category 1 Credit(s)[™]

The American College of Obstetricians and Gynecologists designates this **journal-based CME activity** for a maximum of 2 *AMA PRA Category 1 Credits*[™]. Physicians should claim only the credit commensurate with the extent of their participation in the activity.

College Cognate Credit(s)

The American College of Obstetricians and Gynecologists designates this **journal-based CME activity** for a maximum of 2 Category 1 College Cognate Credits. The College has a reciprocity agreement with the AMA that allows *AMA PRA Category 1 Credits*[™] to be equivalent to College Cognate Credits.

Disclosure of Faculty and Planning Committee Industry Relationships

In accordance with the College policy, all faculty and planning committee members have signed a conflict of interest statement in which they have disclosed any financial interests or other relationships with industry relative to article topics. Such disclosures allow the participant to evaluate better the objectivity of the information presented in the articles.

How to Earn CME Credit

To earn CME credit, you must read the article in *Obstetrics & Gynecology* and complete the quiz, answering at least 70 percent of the questions correctly. For more information on this CME educational offering, visit the Lippincott CMEConnection portal at <https://cme.lww.com/browse/sources/196> to register and to complete the CME activity online. ACOG Fellows will receive 50% off by using coupon code, **ONG50**.

Hardware/software requirements are a desktop or laptop computer (Mac or PC) and an Internet browser. This activity is available for credit through April 30, 2024. To receive proper credits for this activity, each participant will need to make sure that the information on their profile for the CME platform (where this activity is located) is updated with 1) their date of birth (month and day only) and 2) their ACOG ID. In addition, participants should select that they are board-certified in obstetrics and gynecology.

The privacy policies for the *Obstetrics & Gynecology* website and the Lippincott CMEConnection portal are available at <http://www.greenjournal.org> and <https://cme.lww.com/browse/sources/196>, respectively.

Contact Information

Questions related to transcripts may be directed to educationcme@acog.org. For other queries, please contact the *Obstetrics & Gynecology* Editorial Office, 202-314-2317 or obgyn@greenjournal.org. For queries related to the CME test online, please contact ceconnection@wolterskluwer.com or 1-800-787-8985.

Author Instructions on Editorial Manager™

Visit <http://ong.editorialmanager.com> for answers to your submission questions

Documents available online include:

- Instructions for Authors
- "Submission Guidelines At-A-Glance"
- *Guide to Writing for Obstetrics & Gynecology*
- Sample abstract for a randomized controlled trial
- Links to reporting guidelines (eg, CONSORT)
- Sample patient consent form

Questions? Call the Editorial Office at (202) 314-2317.

rev 6/2019