

Received: 2020.07.31
Accepted: 2020.12.21
Available online: 2021.02.08
Published: 2021.03.18

Primary BRAF Mutant Melanoma of the Lung Treated with Immunotherapy and Pulmonary Bilobectomy: A Case Report

Authors' Contribution:
Study Design A
Data Collection B
Statistical Analysis C
Data Interpretation D
Manuscript Preparation E
Literature Search F
Funds Collection G

ADE 1 **Laura Bernal**
ABCDEF 2 **Juliana Restrepo**
ABCDEF 1 **Martha L. Alarcón**
BDF 3 **Carlos Carvajal**
ADF 1 **Carlos E. Bonilla**
ADF 3 **Ana Maria Ramírez**
ADF 3 **Rafael Beltrán**

1 Department of Clinical Oncology, National Cancer Institute, El Bosque University, Bogotá, Colombia
2 Department of Surgical Oncology, National Cancer Institute, Nueva Granada Military University, Bogotá, Colombia
3 Department of Thoracic Surgery, National Cancer Institute, El Bosque University, Bogotá, Colombia

Corresponding Author: Juliana Restrepo, e-mail: julirpo85@gmail.com
Conflict of interest: None declared

Patient: Female, 59-year-old
Final Diagnosis: Melanoma malignant • mucosal melanoma
Symptoms: Cough • hemoptysis • weigh loss
Medication: —
Clinical Procedure: Lymph node excision • pulmonary bilobectomy
Specialty: Oncology • Surgery

Objective: Rare disease
Background:





Primary melanoma of the lung is a rare tumor that represents 0.01% of primary lung tumors, with only 40 cases reported in the literature. Mucosal melanomas are tumors with a biological and clinical presentation that differs from that of cutaneous melanomas; therefore, the therapeutic approach differs as well. Survival rates of patients with primary melanoma of the lung are much lower than those of patients with cutaneous melanoma, and there are no diagnostic or treatment guidelines for this entity. Radical surgery is the treatment of choice when disease is resectable. The effectiveness of current established treatments for cutaneous melanoma (eg, immunotherapy and targeted therapy) is unknown in this particular subgroup.

Case Report: We present the case of a patient who presented with cough and hemoptysis. The fiberoptic bronchoscopy revealed an endobronchial mass and the computed tomography images suggested an unresectable mass. The patient was initially diagnosed with an unresectable primary lung melanoma with a clinical stage IIIB (T4N2M0). This lesion achieved partial response after treatment with Pembrolizumab, which allowed radical surgery to be performed, achieving complete resection with negative margins and adequate postoperative evolution. Despite the delays in our health care system, she is currently alive and disease-free more than 24 months after diagnosis.

Conclusions: Immunotherapy can reduce the size of mucosal melanoma to the point that it can be resectable and this therapeutic approach increases the survival opportunities of these patients.

Keywords: Case Reports • Immunotherapy • Melanoma • Pneumonectomy • Proto-Oncogene Proteins B-raf

Full-text PDF: <https://www.amjcaserep.com/abstract/index/idArt/927757>

 2243   3  11



Background

Melanoma is a heterogeneous disease, including neoplasms that arise from the melanocytes of the skin, the uveal epithelium, and mucosal surfaces. Although the vast majority of cases correspond to skin melanomas, approximately 3% to 5% originate from the uveal tract of the eye and 1% to 2% from mucosal surfaces [1].

Mucosal melanomas are tumors with a biological and clinical presentation that differs from that of cutaneous melanomas; therefore, the therapeutic approach differs as well. They can arise from the epithelia of the mucosa lining the genitourinary, gastrointestinal, and respiratory tracts. Those emerging from the pulmonary mucosa are extremely rare; there are only 40 cases reported in literature, and represent 0.01% of all primary lung tumors [2].

We present the case of a female patient diagnosed with primary melanoma of the lung, which represented a challenge from the diagnostic and therapeutic point of view. Treatment with immunotherapy and subsequent surgery has not been previously reported in the literature.

Case Report

Our patient was a 59-year-old woman with a medical history of smoking (15 pack-year), with controlled comorbidities (arterial hypertension and type 2 diabetes mellitus), and surgical history of a gastric sleeve as treatment for morbid obesity. She presented after 1 year of recurrent respiratory infections, during which time she had multiple admissions to the Emergency Department. Cough was the predominant symptom, occasionally associated with hemoptysis, and progressive dyspnea. She was hospitalized with a diagnosis of pneumonia, for which she received treatment. The symptoms persisted and progressed, and were furthermore associated with weight loss.

In March 2018, she had a new episode of hemoptysis that was interpreted as upper-digestive tract bleeding, for which an esophagogastroduodenoscopy was performed, revealing extrinsic compression of the esophagus.

Fiberoptic bronchoscopy (**Figure 1**) revealed an endobronchial mass occluding 100% of the intermediate bronchus, located 3 cm from the carina. A biopsy was taken, which initially reported a poorly differentiated small-cell malignant tumor. A wide panel of immunohistochemistry was done (**Figure 2**) being suggestive of melanoma with strong positivity for S100 and HMB45 and negativity for CD45, AE1/AE3, synaptophysin, P40, P63, TTF1, CD56, desmin, CD 34, CD31, CD99 and caldesmon, melan A, Mif1-1, and PNL02; Ki67 was 50%. A right para-hilar mass with soft tissue density measuring 56×75 mm in diameter and a subcarinal adenopathy of 34 mm was observed in the chest tomography, with involvement of the azygo-esophageal recess and right interlobar artery (**Figure 3**).

Positron emission tomography (PET-CT) with 18-FDG revealed a hypermetabolic mass with SUV of 10 partially occluding the intermediate bronchus (**Figure 3**), as well as subcarinal lymphadenopathies (the only station with hypermetabolism), of which a biopsy performed by thoracoscopy was negative. PET-CT showed no evidence of disease in any other location. An exhaustive dermatological and gynecological checkup was performed, excluding the presence of skin or mucosal lesions. Being diagnosed with an unresectable clinical stage IIIB primary pulmonary melanoma, T4 (mass larger than 7 cm and invades mediastinum) N2 (nonspecific hypermetabolism station 7) M0, this case was discussed in a multidisciplinary meeting and images were reviewed. It was concluded that the possibility of R0 resection was very low and it was an unresectable tumor.

Treatment with anti-PD1 (Pembrolizumab) was selected because the report of BRAF mutation status was not available at the time treatment started (in our health system, this type

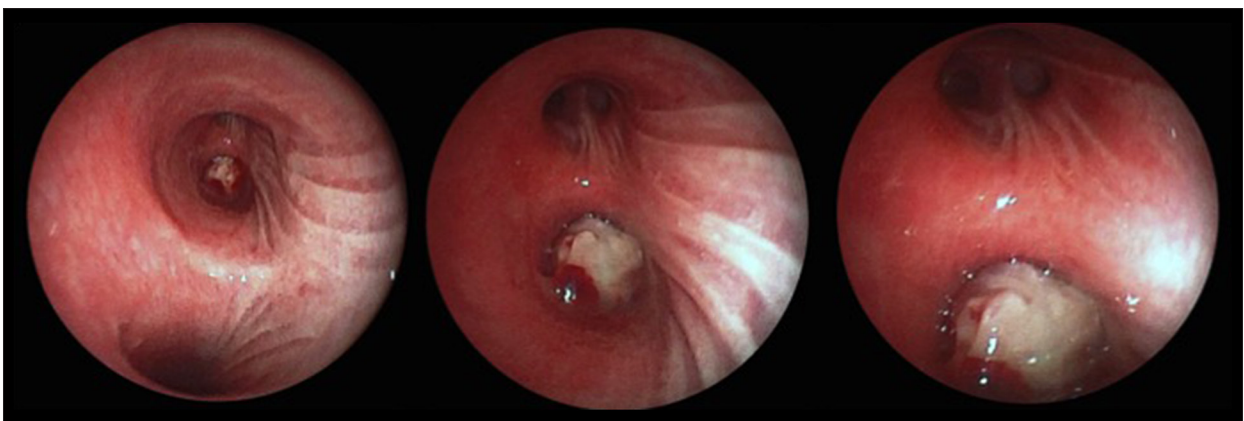

Figure 1. Images corresponding to fiberoptic bronchoscopy with an endoluminal tumor in the intermediate bronchus that creates complete bronchial obstruction.

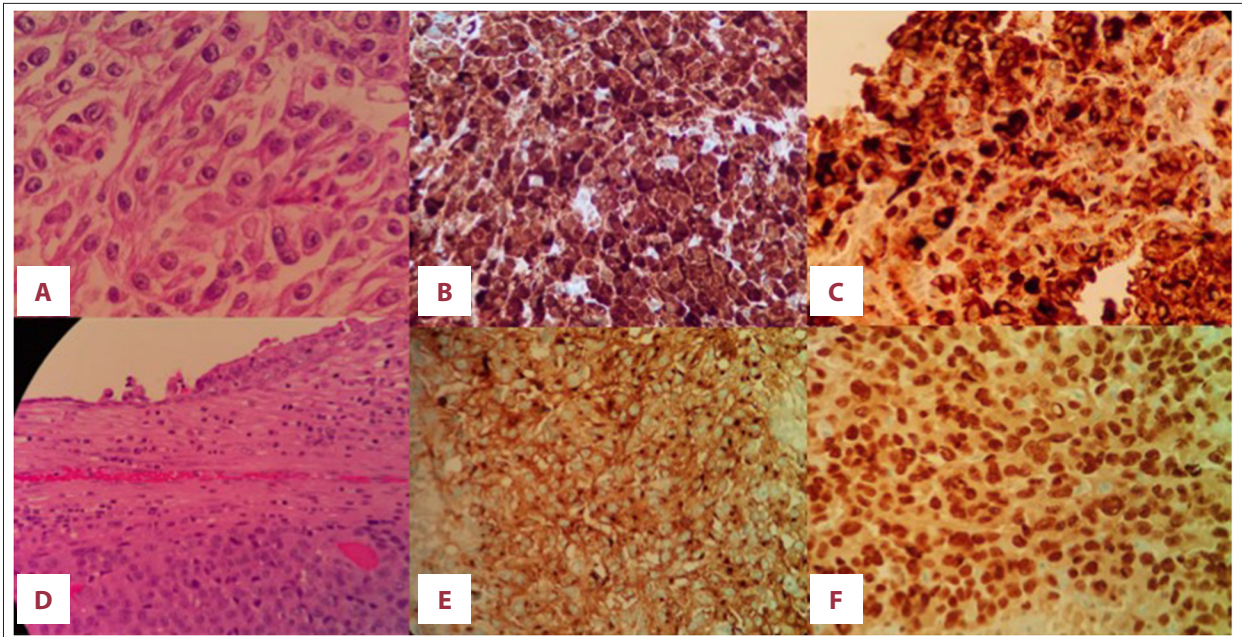


Figure 2. (A) Malignant epithelioid-like tumor cells with prominent nucleolus, compatible with endobronchial malignant melanoma. Hematoxylin-Eosin staining on initial biopsy. (B) Tumor cells positive for HMB 45 on initial biopsy. (C) Tumor cells positive for S100 on initial biopsy. (D) Hematoxylin-Eosin staining of the surgical specimen. (E) Tumor cells positive for Melan A. (F) Tumor cells positive for SOX 10. All pathology images are 40× magnification, except for images D and E, which are 10×.

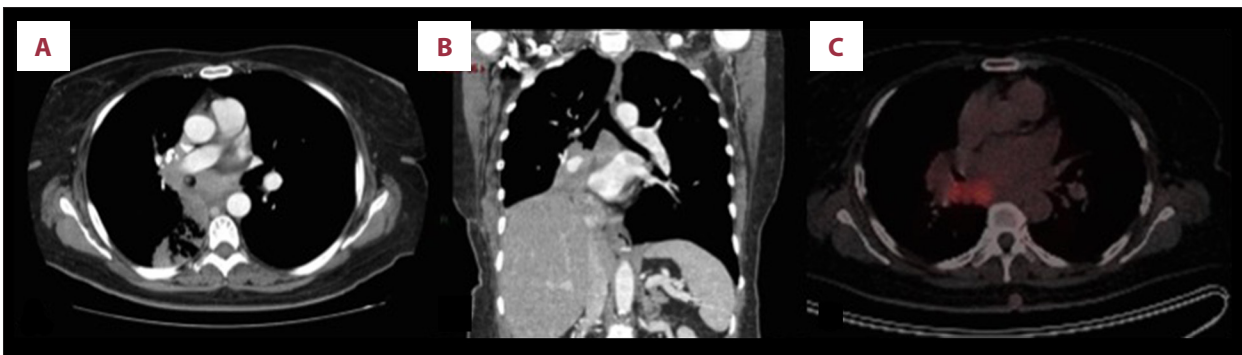

Figure 3. (A, B) In the axial image and the coronal reconstruction of the chest tomography with contrast, a mass with a soft tissue density is observed, which completely compromises the lumen of the intermediate bronchus and the right lower lobe, and partially compromises the lumen of the middle lobar bronchus with associated post-obstructive atelectasis. (C) Positron emission tomography shows the hypermetabolic mass of poorly defined margins, located in the upper segment of the right lower lobe, approximately 59×59×81 mm (APxTxL) (max SUV 18.6).

of report usually takes longer than in high-income countries). She started treatment in August 2018 and achieved a partial response, evidenced in a follow-up CT scan taken at 6 months from start of treatment, which showed improvement in the mediastinal component. With systemic therapy, she remained asymptomatic with a good quality of life. In January 2020, her symptoms reappeared and atelectasis of the middle and lower lobe recurred, with an increase in the mediastinal component, so it was decided to perform surgical resection. A bilobectomy with simple bronchoplasty of the stump and intrapericardial control of the inferior pulmonary vein, with mediastinal lymph

node resection by posterolateral right thoracotomy, were performed. A frozen section of the proximal section edge of the intermediate bronchus was negative. Surgery was performed without complications and the postoperative evolution was satisfactory, with adequate expansion of the right upper lobe. She was discharged 3 days after surgery. Surgical pathology showed evidence of a 5×5×4 cm endobronchial malignant melanoma with a 2×2×1 cm satellite nodule, lymphovascular involvement, and no compromise of the vascular, bronchial or parenchymal margins; the parenchymal border was less than 1 mm and there were no involved lymph nodes out of 19

resected (stations 3A, 7, 8, 10, and 11). An immunohistochemistry study was positive for HMB45, S100, SOX 10, MELAN A, VIMENTINA, and CALDES MON and negative for CKE1/AE3, CK7, CK20, NAPSIN A, TTF1, CD 56, LCA, EMA, CD34, CD99, AML, DESMIN, and HHF35, with a Ki67 index of 40%. During the postoperative period, immunotherapy was resumed, with adjuvant intention, planned for 1 more year. The patient is currently disease-free and in very good clinical condition. At the last follow-up, which had to be virtual due to the SARS-Cov2 pandemic, she reported no symptoms and a new PET-CT was ordered by the oncologist.

The patient gave informed consent for this case report and even with the health care difficulties in Colombia, she could get the latest therapeutic strategies and is content with her treatment so far.

Discussion

Melanoma is an entity that includes a heterogeneous group of malignancies that all have melanocytes as the cell of origin. Every year around 160 000 new cases of melanoma are diagnosed worldwide [3]. Mucosal melanoma (MM) is part of the spectrum of this disease, accounting for 2% of cases; it is less common than cutaneous melanoma and has a different clinical and biological behavior [2].

In contrast to cutaneous melanoma, the age of onset of MM is on average 10 years older, with a median of 59-70 years old [2-4]. It behaves more aggressively, with more than 50% of cases being diagnosed at an advanced stage [3,4] and the 5-year survival is 25%, which is much worse than for cutaneous melanoma [1]. The median overall survival of patients with advanced MM is 9.1 months and there are no significant differences in outcomes according to the mucous membrane of origin [5].

Primary melanoma of the lung (PPM) is extremely rare, accounting for only 0.4% of MM; it is usually endobronchial and exhibits symptoms such as cough, hemoptysis, post-obstructive pneumonia, lobar collapse, atelectasis, weight loss, and fatigue [6]. Up to 30% are diagnosed as incidental findings, being asymptomatic at the time of diagnosis [7]. Lymph node involvement is found in 40% of patients; in the case presented here, the patient had no positive nodes [6]. Immunohistochemical stains can be applied to distinguish MPP from other primary lung tumors, but it is similar to other primary melanomas. MPP is rarely positive for cytokeratin or neuroendocrine markers, such as chromogranin, and is generally positive for S100 and HMB-45 [5]. There is diversity of expression of the common antigens of melanoma and only 73.3% of cutaneous melanomas are positive for Melan A. This antigen heterogeneity

could explain why this primary PPM was positive for S100 and HMB-45, but negative for melan A in the initial biopsy, but due to tumor heterogeneity, melan A was positive in the surgical specimen [11].

PPM can be difficult to differentiate from metastatic malignant melanoma of the lung. The presence of multiple pulmonary nodules favors lung metastases; however, because lung metastasis can also present as a solitary mass, it is important to obtain an accurate history regarding previous pigmented skin lesions and to exclude other primary non-pulmonary sites. Our patient had an exhaustive physical exam in which skin, uveal, or other mucosal lesions were ruled out. PET-CT with 18-FDG was also performed, which was negative for disease in other locations.

The biological characteristics of MM differ significantly when compared to cutaneous melanoma: BRAF mutation is present in about 50% of skin melanomas, whereas it is rare in MM (less than 10% of cases). c-KIT mutation reaches a frequency of 15% to 20%. MM is suspected to be less immunogenic; PD-L1 expression is lower with respect to skin melanoma, and it has been found that the mutational load is also lower, with a 5 to 10 times lower rate of mutations compared to cutaneous melanomas [8,9].

Given its very low frequency, there are no established guidelines of management for this disease. If possible, surgical resection should be performed, with lobectomy or pneumonectomy, plus mediastinal lymph node dissection [3]. Usually, it is diagnosed at an advanced stage, and the anatomical location in many cases prevents complete resection of the lesion, making it difficult to achieve negative margins [5]. Radical surgical resection could improve median overall survival up to 30 months [6]. In the present case report, the patient had an unresectable disease, which became resectable with the immune therapy, so surgical resection was performed after an initial conversion treatment. Since she had an unresectable condition at the beginning, even though she did not have positive lymph nodes, this aggressive disease was locally advanced and any relapse in this area, where so many vital organs are located, would be catastrophic, which is why adjuvant treatment was continued after surgery.

Until the availability of immunotherapy and targeted therapy, chemotherapy was the only option for these patients, with very low objective response rates (ORRs) of less than 10% [5]. The increased frequency of c-KIT mutations in MM prompted studies of tyrosine kinase inhibitors such as Imatinib and Dasatinib, but findings have been divergent and the response is short-lived [10].

Immunotherapy with anti-PD-1 (Nivolumab and Pembrolizumab) and anti-CTL-4 (Ipilimumab) is currently the cornerstone treatment of metastatic melanoma. Although its efficacy in patients with MM is less characterized due to the low frequency of presentation, the clinical trials that evaluated these molecules did not exclude patients with mucosal melanomas. In 2017, a pooled analysis was published, collecting outcomes from patients with metastatic mucosal melanoma treated with single-agent Nivolumab or the combination of Ipilimumab and Nivolumab, comparing the results with those of patients with cutaneous melanoma [8]. This combined analysis confirmed that patients with metastatic MM might benefit from treatment with immunotherapy regimens routinely used for patients with metastatic cutaneous melanoma; however, response rates were lower. Monotherapy with Nivolumab achieves a response rate of 23.3% in patients with MM versus 40.9% in patients with skin disease. The combination therapy of Ipilimumab and Nivolumab was associated with a response rate of only 37.1% compared to the 60.4% observed in patients with metastatic cutaneous melanoma [8]. Despite lower response rates, immunotherapy is the alternative with the best clinical evidence and the highest reported efficacy for MM. The best response rates described with this combination should be balanced with the highest rate of treatment-related adverse events (incidence of grade 3 and 4 adverse events up to 55%) [8]. In this case, monotherapy was chosen because the national drug regulatory agency had not given approval for the combined treatment for melanoma. Our patient had a good tolerability, achieving a partial response that allowed for a radical surgical resection with negative margins. Therapeutic decisions should be made by weighing risks versus benefits, without leaving aside factors such as quality of life and patient preferences.

Targeted therapy with MEK and BRAF inhibitors have shown response rates of up to 64% in cutaneous melanomas, but there are no specific data for MM and it is not usually the first treatment option for these patients, taking into account the low incidence of BRAF mutation. This case is unique in that the patient also had a BRAF mutation, which offers another therapeutic possibility in the future if there is disease progression, with significant efficacy [9].

The follow up of this patient had been difficult because she lives in a small town 10 hours away from Bogotá by car and the SARS-Cov-2 pandemic has delayed all consults and insurance approvals for follow-up images and medication. A new PET-CT is pending to assess her current disease status.

This case report has several limitations due to the intrinsic limitations of the Colombian health care system. These limitations include the delayed BRAF mutation status report, the unavailability of video mediastinoscope, the unavailability of PD-L1 measurement at the time of this diagnosis, and lack of liquid biopsy for follow-up. Also, there has been a delay in nationwide approvals to use certain new treatments and there are few centers where PET-CT can be performed in Colombia.

Conclusions

Mucosal melanoma is considered the most aggressive subtype of melanoma; its low incidence makes it a great challenge, with no clear diagnostic, staging, and treatment protocols. Within this group, primary lung melanoma is extremely rare and this is the only case reported with a positive BRAF mutation. Surgical treatment offers the only curative option for these patients; however, in cases where the disease is unresectable or negative margins cannot be achieved, systemic therapy is a valuable tool to obtain disease control. Evidence for modern treatments is extrapolated from advances in the therapeutic arsenal of cutaneous melanoma and, without a doubt, it has contributed to improved outcomes in MM as well, although with less efficacy. With immunotherapy and targeted therapy, we have the possibility of modifying the course of this disease. A joint effort is required to expand and deepen the knowledge of this entity and its biology, in order to optimize treatment.

Acknowledgements

Thanks to the pathology group of the National Cancer Institute in Bogotá D.C, for the surgical pathology photos and figure legends.

Conflict of Interest

None.

References:

1. Chang AE, Karnell LH, Menck HR. The National Cancer Data Base Report on cutaneous and noncutaneous melanoma: A summary of 84,836 cases from the past decade. The American College of Surgeons Commission on Cancer and the American Cancer Society. *Cancer*. 1998;83(8):1664-78
2. Yde SS, Sjoegren P, Heje M, Stolle LB. Mucosal melanoma: A literature review. *Curr Oncol Rep*. 2018;20(3):28-37
3. Kyriakopoulos C, Zarkavelis G, Andrianopoulou A, et al. Primary pulmonary malignant melanoma: Report of an important entity and literature review. *Case Rep Oncol Med*. 2017;2017:8654326
4. Seetharamu N, Ott P, Pavlick A. Mucosal melanomas: A case-based review of the literature. *Oncologist*. 2010;15(7):772-81
5. Komatsubara KM, Jeter J, Carvajal RD, et al. Advances in the treatment of advanced extracutaneous melanomas and nonmelanoma skin cancers. *Am Soc Clin Oncol Educ B*. 2017;37:641-50
6. dos Santos C, Fernandes L, Meruje M, Barata F. Primary pulmonary melanoma: The unexpected tumour. *BMJ Case Rep*. 2013;2013: bcr2013200706
7. Yunce M, Selinger S, Krimsky W, Harley DP. Primary malignant melanoma of the lung: A case report of a rare tumor and review of the literature. *J Community Hosp Intern Med Perspect*. 2018;8(1):29-31
8. D'Angelo SP, Larkin J, Sosman JA, et al. Efficacy and safety of Nivolumab alone or in combination with Ipilimumab in patients with mucosal melanoma: A pooled analysis. *J Clin Oncol*. 2017;35(2):226-35
9. Furney SJ, Turajlic S, Stamp G, et al. Genome sequencing of mucosal melanomas reveals that they are driven by distinct mechanisms from cutaneous melanoma. *J Pathol*. 2013;230(3):261-69
10. Carvajal R, Antonescu C, Wolchok J, et al. KIT as a therapeutic target in metastatic melanoma. *JAMA*. 2014;305(22):2327-34
11. Viray H, Bradley WR, Schalper KA, et al. Marginal and joint distributions of S100, HMB-45, and Melan-A across a large series of cutaneous melanomas. *Arch Pathol Lab Med*. 2013;137(8):1063-73