

Melioidosis in a Tertiary Care Center from South India: A 5-year Experience

Vithiya Ganesan¹, Mariappan Murugan², Raja Sundaramurthy³, Geni VG Soundaram⁴

ABSTRACT

The present study was done with the objective to know the clinical presentation, microbiological features, and treatment outcome of melioidosis patients in our hospital, which is an emerging infection in India, and to know the differences in clinical course and outcome between bacteremic and nonbacteremic patients. This retrospective observational study was carried out over a period of 5 years from January 2015 to December 2019. Thirty-five cases of culture-confirmed melioidosis were identified with age range between 5 and 74 years. A large number of patients ($n = 31$) presented with uncontrolled diabetes mellitus. Six patients died of septic shock, and the outcome of eight patients was unknown as they were discharged against medical advice. There were no relapses observed. Melioidosis growing as a neglected tropical disease in India warrants awareness among all clinicians across the country.

Keywords: Melioidosis, Neuromelioidosis, Osteomyelitis, Septicemia.

Indian Journal of Critical Care Medicine (2021): 10.5005/jp-journals-10071-23766

INTRODUCTION

Melioidosis is an emerging infectious disease in India, mainly reported from coastal regions of Karnataka, Kerala, Tamil Nadu, Pondicherry, and Odisha. Most of the reports are from few large medical centers with well-equipped laboratories and microbiologists. Many new regions and states are being reported with unusual clinical presentations such as infected aneurysms and brain abscess in recent times. We speculate the occurrence of another hidden hot spot in Madurai, south central region of Tamil Nadu. Our tertiary care center in Madurai has more than 2000 beds and receives referred cases from neighboring districts with many inpatient admissions and outpatient visits. Following our first case of melioidosis presenting with osteomyelitis detected in 2015, we are regularly reporting cases of melioidosis.^{1,2} With continuous interactions with clinicians, we have encountered 35 culture-confirmed cases of melioidosis in a period of 5 years. Detailed clinical and microbiological features of these cases are presented here.

MATERIALS AND METHODS

This is a retrospective observational chart review of patients diagnosed with culture-proven melioidosis. Thirty-five patients who were diagnosed with culture-proven melioidosis during the period from January 2015 to December 2019 form the study group. They were classified as bacteremic or nonbacteremic melioidosis, depending on whether their blood cultures were positive or negative for *Burkholderia pseudomallei*. Information on demography, clinical features, risk factors, laboratory and radiological findings, treatment, and outcome was extracted from the records. Ethics committee approval was taken for this study.

Microbiological Methods

Clinical specimens were processed as per the standard microbiological culture techniques. For blood culture, at least 10 mL of blood was collected aseptically and inoculated into BACTEC (BD) blood culture bottles and incubated in the BACTEC FX40 automated

^{1,3,4}Department of Microbiology, Velammal Medical College Hospital and Research Institute, Madurai, Tamil Nadu, India

²Department of Radiodiagnosis, Velammal Medical College Hospital and Research Institute, Madurai, Tamil Nadu, India

Corresponding Author: G Vithiya, Department of Microbiology, Velammal Medical College Hospital and Research Institute, Madurai, Tamil Nadu, India, Phone: +91 8508871967, e-mail: vidhya.md@gmail.com

How to cite this article: Ganesan V, Murugan M, Sundaramurthy R, Soundaram GVG. Melioidosis in a Tertiary Care Center from South India: A 5-year Experience. *Indian J Crit Care Med* 2021;25(3):327–330.

Source of support: Nil

Conflict of interest: None

blood culture system. Pus, wound swab, sputum, and endotracheal aspirate were plated on blood, chocolate, and MacConkey agar media. *B. pseudomallei* was identified by the growth of silver white colonies on blood agar with metallic sheen. Pus from deep abscess was also processed for acid-fast stain, anaerobic bacterial and fungal culture. None of the samples showed acid-fast bacilli, anaerobes, or fungus. Phenotypic identification of *B. pseudomallei* was performed by a combination of the following tests, i.e., characteristic metallic sheen and wrinkled appearance of colonies, oxidase positive, motile, gram-negative bacilli with bipolar staining with a “safety-pin” appearance, and resistance to polymyxins antibiotics (colistin 10 µg and polymyxin B 300 U disks) along with arginine dihydrolase positive reaction. The identification of isolates was also confirmed by VITEK 2 system. The following antibiotics (ceftazidime, meropenem, trimethoprim–sulfamethoxazole, and doxycycline) were tested by disk diffusion test.

Statistical Methods

Statistical analyses were performed using SPSS software ver. 22.0 (IBM, Armonk, NY, USA) and MedCalc program for Windows.

Table 1: Demography, clinical course, and outcome of 35 culture-proven cases

Sl. No.	Age	Sex	Month/year	Diagnosis	Mode of discharge	Duration of hospitalization (days)	Time taken from hospitalization to culture positive (days)	Specimen type	Bacteremia
1.	31	M	Jan 2015	Osteomyelitis with intramuscular abscess	Died	4		Pus	N
2.	69	M	Dec 2015	Liver abscess, septicemia	AMA	13	14	Blood	Y
3.	56	M	Dec 2015	Elbow and knee arthritis, encephalopathy, anoxic brain damage	AMA	20	5	Synovial fluid	N
4.	51	M	Jan 2016	Foot cellulitis	Improved	22	4	Wound swab	N
5.	35	F	Jan 2016	Gluteal abscess	Improved	9	3	Pus	N
6.	49	M	Sep 2016	Arthritis, pyelonephritis	Improved	18	4	Synovial fluid	N
7.	70	M	Oct 2016	Septicemia, cellulitis leg	Improved	6	4	Wound swab, blood	Y
8.	55	M	Dec 2016	Liver and spleen abscess	Improved	13	7	Pus	N
9.	5	F	Jun 2017	Parotid abscess	Improved	11	5	Pus, blood	Y
10.	45	M	Jul 2017	Fever	Improved	11	7	Blood	Y
11.	38	M	Jul 2017	Liver abscess, acute renal failure	Improved	19	5	Pus	N
12.	59	M	Aug 2017	Septicemia, chronic renal failure, encephalopathy	Died	14	6	Blood	Y
13.	64	M	Sep 2017	Liver and spleen abscess, acute pancreatitis	Improved	16	9	Pus	N
14.	44	M	Oct 2017	Septicemia, bronchopneumonia	Died	10	4	Blood	Y
15.	74	M	Oct 2017	Septicemia	Died	21	7	Blood	Y
16.	59	M	Oct 2017	Synovitis and tenosynovitis	Improved	5	5	Pus, blood	Y
17.	56	M	Nov 2017	Abscess of salivary gland	Improved	14	11	Pus	N
18.	53	F	May 2018	Acidosis, chronic renal failure, pulmonary edema, anemia	AMA	2	4	Blood	Y
19.	50	M	Jun 2018	Intracranial and intraspinal abscess	AMA	11	4	Pus, blood	Y
20.	50	M	Aug 2018	Acute peritonitis	Improved	14	3	Pus, blood	Y
21.	53	M	Oct 2018	Septicemia	AMA	6	6	Sputum, blood	Y
22.	67	M	Dec 2018	Pneumonia, cellulitis limb	Improved	29	16	Sputum, pus	N
23.	66	M	Jan 2019	Cellulitis limb, osteomyelitis	Improved	32	3	Blood	Y
24.	28	M	Feb 2019	RTA, injury to head, abdomen, lower back, liver, and spleen	Improved	74	14	Pus, blood	Y
25.	33	M	Jun 2019	Septicemia	AMA	4	8	Blood	Y
26.	49	F	Jun 2019	Soft tissue infection	Improved	7	5	Pus	N
27.	55	F	Jun 2019	Soft tissue infection, acute inflammation of orbit	Improved	11	5	Pus	N
28.	37	M	Jul 2019	Spleen abscess	Improved	7	2	Pus	N
29.	53	M	Sep 2019		Improved	10	9	Pus	N
30.	43	M	Sep 2019	Septicemia	AMA	7	10	Blood	Y
31.	40	F	Nov 2019	Septicemia	Died	2	6	Endotracheal aspirate, blood	Y
32.	40	M	Nov 2019	Liver abscess	Improved	6	5	Pus	N
33.	55	M	Dec 2019	Septicemia, pneumonia, osteomyelitis, ARDS	Died	1	4	Blood	Y
34.	39	M	Dec 2019	Intracranial abscess	AMA	16	9	Blood	Y
35.	20	F	Dec 2019	Liver, spleen abscess, osteomyelitis, chronic pancreatitis	Improved	13	8	Pus, blood	Y

AMA, against medical advice; RTA, road traffic accident; ARDS, acute respiratory distress syndrome

Continuous variables were reported as mean and range, and categorical variables were compared using chi-square test. *p* value less than 0.05 was considered as statistically significant.

RESULTS

Over a study period of 5 years, 35 cases of culture-confirmed melioidosis were identified. Demography, clinical course, and outcome of all the cases are shown in Table 1. The median age was 50 years (range = 5 and 74 years), of which 28 (80%) were male. Eighty-eight percent (31/35) had underlying risk factors. Diabetes mellitus (31/35, 88%) was the single commonest factor, others being alcoholism (13/35, 37%) and chronic renal failure (8/35, 23%). Case clustering was identified during the months of postrainy season (September to January). There has been a steady increase in the reported cases over the years.

Infection was localized in 16 patients and disseminated in nineteen patients, which include all the bacteremic individuals.

Of 35 culture-confirmed cases, 11 patients were positive by blood culture alone, and eight patients were culture positive for *B. pseudomallei* from blood as well as pus/sputum/endotracheal aspirate and others had localized infection. Demography, clinical course, and outcome of bacteremic and nonbacteremic cases are shown in Table 2. There was no statistically significant difference in age, duration of hospitalization, and time taken for culture positivity among bacteremic and nonbacteremic cases. Forty-six percent case fatality among bacteremic cases versus 6.2% case fatality in nonbacteremic cases, *p* = 0.017, which is statistically significant.

Drug susceptibility to carbapenem, ceftazidime, cotrimoxazole, and doxycycline was 100, 100, 94.2, and 100%, respectively.

Eighteen patients were admitted to intensive care units. Six patients died of septic shock, and the outcome of eight patients

was unknown as they were discharged against medical advice due to financial constraints. The average duration of hospitalization was 14 days. As the average time taken for diagnosis by culture was 6.5 days, almost all the patients were on empirical antibiotic therapy. Seven cases that presented with liver and/or spleen abscess were provisionally diagnosed as melioidosis. All other cases were clinically diagnosed as pyogenic arthritis/osteomyelitis, tuberculous lymphadenitis, tuberculous meningitis, and pyrexia of unknown origin. After culture sensitivity reports, intravenous meropenem was administered at the recommended dosage of 25 mg/kg body weight, 8th hourly in 11 cases of septicemia for 2 weeks, and in all other cases, ceftazidime was administered at the recommended dosage of 50 mg/kg body weight, 8th hourly for 2 weeks. Cotrimoxazole was the drug of choice for the eradication phase in most of the patients for 8 weeks. In two individuals with in vitro resistance to cotrimoxazole, doxycycline was administered in the eradication phase. Patients were followed for an average duration of 3 months to 1 year. There were no relapses observed.

DISCUSSION

Mean age, male gender predisposition, and diabetes mellitus as the most important risk factors and seasonal influence are comparable to other studies reported from India.^{3,4} Melioidosis is a disease with protean manifestations. This term has been overused as to have become a cliché. In the present study, the most common presentation was septicemia, followed by deep visceral abscess and skin and soft tissue infection. Some of the unusual presentations were two cases of neuromelioidosis and one patient presenting with acute septicemia following road traffic accident.

CNS melioidosis is rare. A recent systematic review found 120 cases reported worldwide with only 16 cases from India.^{5,6} Only 1.5–5% of cases present with craniospinal manifestations. However, mortality in neuromelioidosis remains high. CNS melioidosis has varied manifestations including encephalomyelitis, cerebral abscess, cranial nerve deficit, and isolated meningitis. In the present study, one of the cases was identified with subdural collection in frontal region and pansinusitis (Fig. 1), and in

Table 2: Demography, clinical course, and outcome of bacteremic and nonbacteremic cases

Characteristics	Bacteremic cases	Nonbacteremic cases	<i>p</i> value
Age, mean (range)	46 (5–74)	49 (31–67)	0.5
Gender (male:female)	15:4	12:4	
Duration of hospitalization, days (range)	14 (1–74)	14 (6–29)	1
Mean time taken from hospitalization to culture positive, days (range)	7 (3–14)	6 (2–16)	0.3
Focus of infection, <i>n</i> (%)	Liver abscess (2) Parotid abscess (1) Synovitis (1) Osteomyelitis (1) Intracranial abscess (2)	Liver and/or spleen abscess (5) Salivary gland abscess (1) Septic arthritis (2) Osteomyelitis (1) Pneumonia (1) Soft tissue infection (6)	
Case fatality rate, <i>n</i> (%)	8(42%)	1(6.2%)	0.017

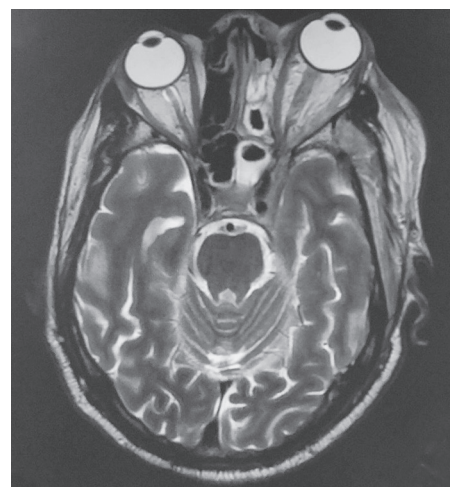

Fig. 1: MRI postcontrast T1W axial left sphenoidal and ethmoidal sinusitis with left cavernous sinus thrombosis and proptosis

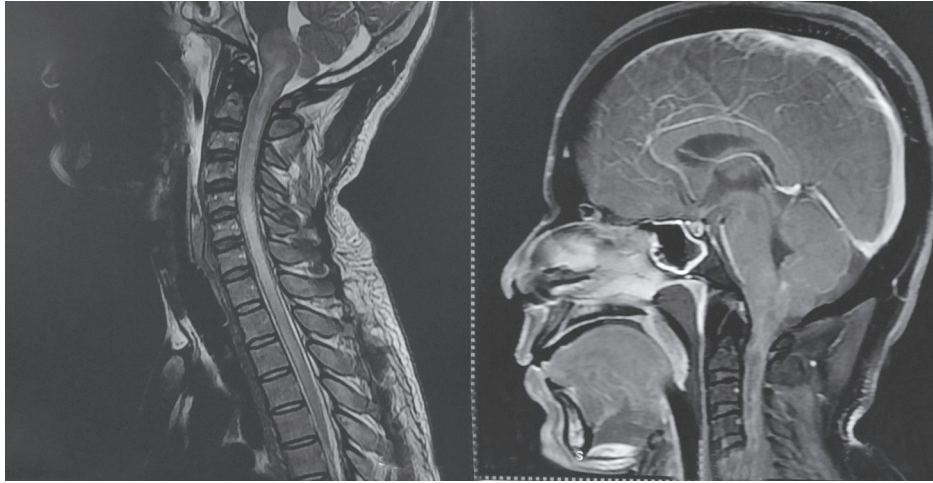


Fig. 2: MRI T2W and postcontrast T1W sagittal showing leptomeningitis with brainstem encephalitis and rim-enhancing abscess in brainstem extending into spinal cord with rim-enhancing intraspinal abscess

other individuals, MRI brain showed features of leptomeningitis and rim-enhancing abscess in brainstem and spinal cord (Fig. 2).

Pediatric melioidosis is another entity that warrants awareness among the pediatricians. Children account for only 5–15% of cases overall.⁷ Melioidosis is recognized as a pediatric disease in endemic areas. There are many case series and case reports of pediatric melioidosis from India.⁸ Most common presentation with acute and localized infection involving head and neck in immunocompetent children could be attributed to ingestion of contaminated water. Diabetes mellitus, thalassemia, and cystic fibrosis are recognized risk factors of melioidosis in children. In the present study, we had a 5-year-old immunocompetent girl presenting with parotid abscess and lymphadenitis, which was misdiagnosed as tuberculous lymphadenitis. Apart from diabetes mellitus, other risk factors found in the study include alcohol use and chronic renal failure. Other risk factors looked for include steroid therapy, malnutrition, and COPD.

Despite India being known for its endemicity for melioidosis by a plethora of case reports, case series, and environmental reporting of isolates, it is unfortunate that many clinicians are still unaware of this condition. Most of the reports are from few centers of excellence with well-equipped microbiological laboratories and trained intensivists. Foremost, awareness should be raised among all clinicians and microbiologists even in remote areas across the country. With a fertile environment harmony to the bacteria, booming diabetic population much of them from rural background, and rickety healthcare system, melioidosis is definitely one of the neglected tropical diseases adding to the existing list of India.

ORCID

Vithiya Ganesan  <https://orcid.org/0000-0003-0949-2841>

Mariappan Murugan  <https://orcid.org/0000-0002-3071-1933>

Raja Sundaramurthy  <https://orcid.org/0000-0001-9867-9784>

Geni VG Soundaram  <https://orcid.org/0000-0002-0882-3787>

REFERENCES

1. Vijaykumar GS, Thilakavathy P, Jeremiah SS, Vithiya G. Osteomyelitis of humerus and intramuscular abscess due to melioidosis. *Kathmandu Univ Med J* 2016;14(54):184–185. PMID: 28166079.
2. Ganesan V, Sundaramoorthy R, Subramanian S. Melioidosis-series of seven cases from Madurai, Tamil Nadu, India. *Indian J Crit Care Med* 2019;23(3):149–151. DOI: 10.5005/jp-journals-10071-23139.
3. Mukhopadhyay C, Shaw T, Varghese GM, Dance DAB. Melioidosis in South Asia (India, Nepal, Pakistan, Bhutan and Afghanistan). *Trop Med Infect Dis* 2018;3(2):51. DOI: 10.3390/tropicalmed3020051.
4. Koshy M, Jagannati M, Ralph R, Victor P, David T, Sathyendra S, et al. Clinical manifestations, antimicrobial drug susceptibility patterns, and outcomes in melioidosis cases, India. *Emerg Infect Dis* 2019;25(2):316–320. DOI: 10.3201/eid2502.170745.
5. Wongwandee M, Linasmita P. Central nervous system melioidosis: a systematic review of individual participant data of case reports and case series. *PLoS Negl Trop Dis* 2019;13(4):e0007320. DOI: 10.1371/journal.pntd.0007320.
6. Prasad GL, Nair RP, Menon GR. Intracranial melioidosis: First report in a human immunodeficiency virus positive individual manifesting as cranial osteomyelitis. *Neurol India* 2017;65(6):1423–1426. DOI: 10.4103/0028-3886.217952.
7. Sanderson C, Currie BJ. Melioidosis—a pediatric disease. *Pediatr Infect Dis J* 2014;33(7):770–771. DOI: 10.1097/INF.0000000000000358.
8. Mukhopadhyay C, Eshwara VK, Kini P, Bhat V. Pediatric melioidosis in Southern India. *Indian Pediatr* 2015;52(8):711–712. PMID: 26388638.