

# SARS-CoV-2 infection triggering recurrence of Kawasaki disease in a 10-year-old child

Ashok Renganathan,<sup>1</sup> Ankit Garg,<sup>2</sup> Sona Chowdhary,<sup>1</sup> Dinesh Raj<sup>1</sup>

<sup>1</sup>Department of Pediatrics, Holy Family Hospital, New Delhi, India

<sup>2</sup>Department of Pediatric Cardiology, Fortis Escorts Heart Institute and Research Centre, New Delhi, India

## Correspondence to

Dr Dinesh Raj;  
dr\_aiims@yahoo.co.in

Accepted 15 March 2021

## SUMMARY

SARS-CoV-2 infection has recently been related to a spectrum of hyper-inflammatory states in children. There is a striking similarity between these hyper-inflammatory states and Kawasaki disease (KD). We present an interesting case of KD recurrence in a 10-year-old child, who had previously developed KD at 4 years of age. His symptoms included fever, maculopapular rash and altered sensorium. Investigations showed noticeably elevated inflammatory markers, and an echocardiography revealed dilated coronary arteries. SARS-CoV-2 IgG antibodies were positive. The child responded dramatically to intravenous immunoglobulin and intravenous methylprednisolone. It is possible that SARS-CoV-2 infection triggered the recurrence of KD in this child who might have been genetically predisposed to KD.

## BACKGROUND

Kawasaki disease (KD) is the second most common vasculitis of unclear aetiology. Likely aetiology might include an unidentified micro-organism or an immunological response to variety of triggers.<sup>1</sup> SARS-CoV-2 infection has been related to a spectrum of hyper-inflammatory states in children with striking similarity to atypical KD and Kawasaki disease shock syndrome.<sup>2</sup> In April 2020, several reports of children presenting with clinical features similar to incomplete KD and toxic shock syndrome were published from the UK, in temporal association with COVID-19. Subsequently, this entity was also reported from other parts of the world and labelled as multisystem inflammatory syndrome in children (MIS-C). MIS-C has considerable phenotypic overlap with KD. In a case series of 570 children, approximately half of children with MIS-C fulfilled criteria for complete or incomplete KD.<sup>3</sup>

The KD associated with SARS-CoV-2 infection typically involves older children with a mean age of around 10 years compared with the classic KD, which characteristically affects infants and young children.<sup>4</sup> Recurrence of KD is uncommon and usually occurs within 2 years of the first episode. We present an interesting case of a 10-year-old child who developed a recurrence of KD, possibly triggered by SARS-CoV-2 infection, 6 years after the first episode.

## CASE PRESENTATION

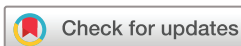A 10-year-old boy presented with high-grade fever along with fronto-temporal headache, erythematous maculopapular rash and altered sensorium in the form of irritability and disoriented speech

for 3 days. Vital signs at admission revealed tachycardia (heart rate at 120 bpm), respiratory rate at 20 breaths per minute, oxygen saturation 98% on room air and blood pressure of 110/70 mm Hg. Systemic examination was unremarkable.

Child had a history of fever 4 weeks prior to hospitalisation, and during evaluation, he tested positive for SARS-CoV-2 by reverse transcriptase PCR (RT-PCR; Altona Diagnostics, Germany). He was afebrile after 3 days of illness and tested negative for SARS-CoV-2 after 2 weeks.

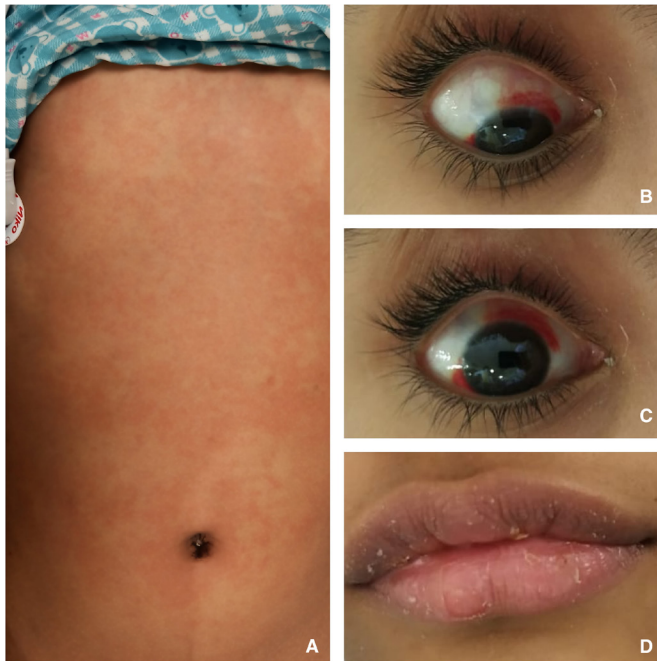The child's medical history was significant with him having developed KD at 4 years of age with dilated coronary arteries, for which he was appropriately treated with a single dose of intravenous immunoglobulin (IVIG) at a dose of 2 g/kg and low-dose aspirin for 6 months. Child was followed up subsequently with serial two-dimensional echocardiography (2D ECHO), and the last 2D ECHO, performed 4 years before, was normal.

The clinical impression at admission was acute meningoencephalitis. He was initially managed with intravenous ceftriaxone and acyclovir along with supportive care. Complete blood counts revealed haemoglobin 14.0 g/dL (N: 11.0–14.5 g/dL), platelet count  $426 \times 10^9/L$  (N:  $150\text{--}450 \times 10^9/L$ ), total leucocyte count  $9.4 \times 10^9/L$  (N:  $4\text{--}12 \times 10^9/L$ ) with differential leucocyte count of neutrophils 53%; lymphocytes 38%; monocytes 8%; and eosinophils 1%. C reactive protein (CRP) was significantly elevated at 7.38 mg/dL (N:  $<0.1$  mg/dL). Kidney and liver function tests were within normal limits. Dengue serology and malarial antigen were tested negative. RT-PCR testing done from nasopharyngeal swab for SARS-CoV-2 was negative. Chest radiograph and abdominal sonography were normal. Lumbar puncture revealed clear fluid under normal pressure. Cerebrospinal Fluid (CSF) was acellular with normal protein and sugar. An MRI of the brain showed diffuse encephalitis. Neurological symptoms improved over 24 hours of hospitalisation, but the fever persisted. On the second day of hospitalisation, the child developed conjunctival congestion, dry cracked lips and peeling of skin from the back of trunk (figure 1). A 2D ECHO done on the second day of hospitalisation showed normal coronary artery Z-scores and normal myocardial function (figure 2A,B). Blood, CSF and urine cultures were sterile. Given the persisting high-grade fever with the negative results from infective workup, a possibility of MIS-C was considered. Tests for inflammatory markers were repeated, and the markers were noted to have increased markedly from baseline levels at admission (erythrocyte sedimentation rate 30 mm in the



© BMJ Publishing Group Limited 2021. No commercial re-use. See rights and permissions. Published by BMJ.

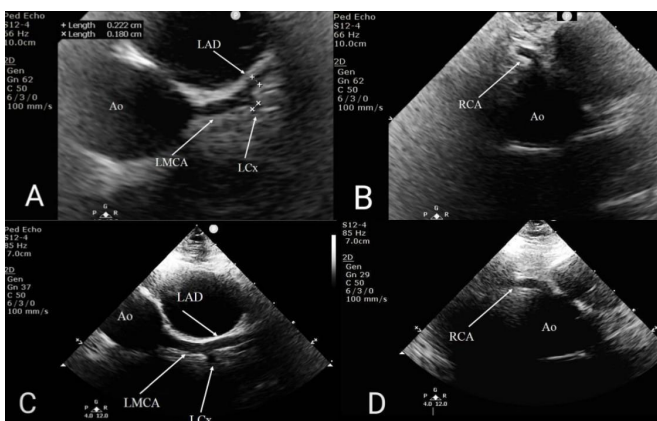
**To cite:** Renganathan A, Garg A, Chowdhary S, et al. *BMJ Case Rep* 2021;**14**:e240972. doi:10.1136/bcr-2020-240972



**Figure 1** (A) Erythematous maculopapular rash over trunk. (B and C) Conjunctival congestion and subconjunctival haemorrhage. (D) Dry cracked lips.

first hour (N: <10)), CRP 18.4 mg/dL and D-dimers (865 ng/mL (N: 0–280 ng/mL)). His pro-brain natriuretic peptide (pro-BNP) was elevated (7690 pg/mL (N: 0–125 pg/mL)). **Table 1** summarises the levels of inflammatory markers over the course of his illness.

Test for SARS-CoV-2 IgG antibodies were conducted using chemiluminescence immunoassay technique (Roche Inc, Germany) and reported elevated levels of 66.2 AU/mL (normal <12.0 AU/mL). A 2D ECHO repeated after 72 hours showed coronary artery dilatation (**figure 2C,D**). The case fulfilled the criteria for both atypical KD (based on the American Heart Association guidelines) and MIS-C (based on WHO case definition).<sup>15</sup> The presence of SARS-CoV-2 IgG antibodies and the unusual age suggested the possibility of recent SARS-CoV-2



**Figure 2** Transthoracic echocardiography, parasternal short axis view. (A) Aorta (Ao) in cross-section with normal calibre LMCA, LAD and LCX. (B) Ao in cross-section and non-dilated, tapering RCA. (C) Dilated LMCA; dilated, non-tapering LAD and LCX. (D) Dilated, non-tapering RCA. LAD, left anterior descending coronary artery; LCX, left circumflex coronary artery; LMCA, left main coronary artery; RCA, right coronary artery.

**Table 1** Inflammatory markers during the course of illness

Parameter	4th day of illness	7th day of illness	12th day of illness
Haemoglobin (g/dL) (N: 11.0–14.5 g/dL)	14.0	12.9	11.2
Total leucocyte count ( $\times 10^9/L$ ) (N: 4–12 $\times 10^9/L$ )	9.4	7.1	6.0
Absolute lymphocyte count ( $\times 10^9/L$ ) (N: 1.5–4 $\times 10^9/L$ )	3.5	2.2	4.8
Platelets ( $\times 10^9/L$ ) (N: 150–450 $\times 10^9/L$ )	176	164	152
Serum albumin (mg/dL) (N: 3.5–5.5 g/dL)	5.2	4.8	4.6
CRP (mg/dL) (N: <0.1 mg/dL)	7.38	18.40	1.50
ESR (mm first hour) (N: <10)	30	30	
Procalcitonin (ng/mL) (N: <0.05 ng/mL)	7.60	33.45	0.31
LDH (U/L) (N 140–280 U/L)	359	337	284
Serum ferritin ( $\mu g/L$ ) (N: 20–250 ng/mL)	425	1263	357
D-dimer (ng/mL) (N: 0–280 ng/mL)	875	892	559
Pro-BNP (pg/mL) (N: 0–125 pg/mL)		7690	4800

CRP, C reactive protein; ESR, erythrocyte sedimentation rate; LDH, Lactate dehydrogenase; ; pro-BNP, pro-brain natriuretic peptide.

infection as the trigger. IVIG was started at 2 g/kg along with intravenous methylprednisolone (2 mg/kg/day). Inflammatory markers showed significant improvement with completion of IVIG (**table 1**). A cardiac MRI was done before discharge and reported normal.

#### OUTCOME AND FOLLOW-UP

The patient was discharged with a prescription of oral steroids (planned for a total of 4 weeks) and followed up in the outpatient department. A 2D ECHO done 1 month after discharge showed normal coronary artery Z-scores and normal myocardial function. Currently, the child is doing well on low dose aspirin.

#### DISCUSSION

KD is the second most common vasculitis of childhood, and its aetiology remains unclear despite 70 years of research. Epidemiology of KD is intriguing with peculiar seasonal and regional predilection.<sup>6</sup> Epidemics of KD have been noted in Japan, and incidence has almost doubled between 2000 and 2012.<sup>7</sup> A variety of theories have been proposed for the aetiology of KD based on pathological, epidemiological and demographic data.<sup>8</sup> The most accepted hypothesis is an aberrant response of the immune system to one or more unidentified pathogens in genetically predisposed patients.<sup>8,9</sup> Kao *et al*<sup>9</sup> studied the epidemiology, spatial and temporal clustering of KD cases and suggested that an infectious agent triggers the immunological cascade of KD. Rowley *et al*<sup>10</sup> discovered that during acute KD, IgA plasma cells infiltrate vascular tissues (as coronary artery walls) and non-vascular tissues, primarily in the trachea supporting the hypothesis of an infective agent entering through the respiratory tract.

Amidst the COVID-19 pandemic, initially infection in children was thought to be mild but subsequently case series of MIS-C were reported from the UK.<sup>2,3,11</sup> Though the initially reported cases mentioned serious illness including shock and myocardial dysfunction, subsequent case series revealed a spectrum of hyperinflammatory states with varying severity.<sup>3</sup> Latent class analysis to identify different subtypes of this syndrome revealed three subgroups based on underlying similarities: MIS-C without overlap with acute COVID-19 or KD (35% cases), MIS-C overlapping with severe acute COVID-19 (30% cases) and MIS-C overlapping with KD (35% cases).<sup>3</sup> However, it is interesting to note that most of these cases of MIS-C developed after the acute infection (2–4 weeks later) rather than during the acute stage.<sup>11</sup>

Most of the cases of MIS-C have been reported from Europe and the USA, which is quite unlike the epidemiology of classic KD, which is much more common in children of Asian descent.<sup>6</sup> The age profiles of children afflicted with MIS-C and KD are also quite different. Classic KD affects infants and young children, whereas MIS-C affects older children. These observations suggest that there is much more to the development of KD (genetics and environmental factors) than just the presence of an infectious trigger.

It is difficult to differentiate between classical KD and MIS-C as they have overlapping clinical features. Rowley has proposed a few differences.<sup>12</sup> Abdominal pain significant enough to prompt advanced imaging and surgical consultation is rare in KD but quite characteristic of MIS-C. Severe lymphopaenia and myocardial dysfunction are characteristic of MIS-C but rare in KD. Although N-terminal pro-BNP is a potential biomarker of KD and reported to be elevated up to 7000 pg/mL, the extent of elevation is even higher in MIS-C.<sup>12</sup> Our patient fulfilled the case definition for both atypical KD and MIS-C; however, the clinico-laboratory picture was more towards KD.

Guleria *et al*<sup>13</sup> studied the clinical and laboratory profile of child who experienced recurrence of KD in children and reported that the mean age of incidence is 36 months, and the episodes of recurrence happens within 2 years of first episode. In our case, the recurrence occurred after 6 years. Almost 90% of the cases of classic KD occurs within 5 years of age, and recurrence is uncommon in older children.<sup>13</sup>

We hypothesise that in our patient, SARS-CoV-2 infection could be the possible trigger for the development of recurrence of KD with probability of underlying genetic susceptibility.<sup>8</sup> The mysterious link between SARS-CoV-2 infection and KD is just

unravelling with active research being done in this area. Detailed epidemiological, genetic and experimental research is needed to unravel the similarities and differences between MIS-C and KD which may answer the long-awaited question: what is the aetiology of KD?

**Twitter** Dinesh Raj @infectious disease

**Contributors** AR and DR: literature review. AR, SC and DR: manuscript writing. AR, AG and SC: clinical management of the patient. AG: provided paediatric cardiology support.

**Funding** The authors have not declared a specific grant for this research from any funding agency in the public, commercial or not-for-profit sectors.

**Competing interests** None declared.

**Patient consent for publication** Obtained.

**Provenance and peer review** Not commissioned; externally peer reviewed.

This article is made freely available for use in accordance with BMJ's website terms and conditions for the duration of the covid-19 pandemic or until otherwise determined by BMJ. You may use, download and print the article for any lawful, non-commercial purpose (including text and data mining) provided that all copyright notices and trade marks are retained.

## REFERENCES

- 1 McCrindle BW, Rowley AH, Newburger JW, *et al*. Diagnosis, treatment, and long-term management of Kawasaki disease: a scientific statement for health professionals from the American heart association. *Circulation* 2017;135:e927–99.
- 2 Hoste L, Van Paemel R, Haerynck F. Multisystem inflammatory syndrome in children related to COVID-19: a systematic review. *Eur J Pediatr* 2021;18:1–16.
- 3 Godfred-Cato S, Bryant B, Leung J, *et al*. COVID-19-Associated Multisystem Inflammatory Syndrome in Children - United States, March-July 2020. *MMWR Morb Mortal Wkly Rep* 2020;69:1074–80.
- 4 Pouletty M, Borocco C, Ouldali N, *et al*. Paediatric multisystem inflammatory syndrome temporally associated with SARS-CoV-2 mimicking Kawasaki disease (Kawa-COVID-19): a multicentre cohort. *Ann Rheum Dis* 2020;79:999–1006.
- 5 World Health Organization. Multisystem inflammatory syndrome in children and adolescents with COVID-19: scientific brief, 2020. Available: <https://www.who.int/publications-detail/multisystem-inflammatory-syndrome-in-children-and-adolescents-with-covid-19> [Accessed 15 Feb 2021].
- 6 Singh S, Vignesh P, Burgner D. The epidemiology of Kawasaki disease: a global update. *Arch Dis Child* 2015;100:1084–8.
- 7 Takahashi K, Oharaseki T, Yokouchi Y. Pathogenesis of Kawasaki disease. *Clin Exp Immunol* 2011;164 Suppl 1:20–2.
- 8 Onouchi Y. The genetics of Kawasaki disease. *Int J Rheum Dis* 2018;21:26–30.
- 9 Kao AS, Getis A, Brodine S, *et al*. Spatial and temporal clustering of Kawasaki syndrome cases. *Pediatr Infect Dis J* 2008;27:981–5.
- 10 Rowley AH, Shulman ST, Mask CA, *et al*. Iga plasma cell infiltration of proximal respiratory tract, pancreas, kidney, and coronary artery in acute Kawasaki disease. *J Infect Dis* 2000;182:1183–91.
- 11 Radia T, Williams N, Agrawal P. Multi-system inflammatory syndrome in children & adolescents (MIS-C): A systematic review of clinical features and presentation. *Paediatr Respir Rev* 2020;30:117–2.
- 12 Rowley AH. Multisystem inflammatory syndrome in children and Kawasaki disease: two different illnesses with overlapping clinical features. *J Pediatr* 2020;224:129–32.
- 13 Guleria S, Paliana RK, Jindal AK, *et al*. Recurrent Kawasaki disease at a tertiary care center in Chandigarh, North West India: 24 years of clinical experience. *Int J Rheum Dis* 2019;22:1183–7.

## Learning points

- ▶ SARS-CoV-2 infection may lead to a spectrum of hyperinflammatory states in children that share peculiar similarities with Kawasaki disease (KD).
- ▶ Classic KD is usually seen in infants and young children unlike multisystem inflammatory syndrome in children (MIS-C) which is uniformly seen in older children.
- ▶ Though there are differences in the clinical presentation of MIS-C and classic KD, treatment principles remain the same.
- ▶ Early diagnosis and therapy lead to prompt clinical response in both MIS-C and KD.
- ▶ More research is warranted to unravel the mysterious link between SARS-CoV-2 infection and KD.

Copyright 2021 BMJ Publishing Group. All rights reserved. For permission to reuse any of this content visit <https://www.bmj.com/company/products-services/rights-and-licensing/permissions/>  
BMJ Case Report Fellows may re-use this article for personal use and teaching without any further permission.

Become a Fellow of BMJ Case Reports today and you can:

- ▶ Submit as many cases as you like
- ▶ Enjoy fast sympathetic peer review and rapid publication of accepted articles
- ▶ Access all the published articles
- ▶ Re-use any of the published material for personal use and teaching without further permission

### Customer Service

If you have any further queries about your subscription, please contact our customer services team on +44 (0) 207111 1105 or via email at [support@bmj.com](mailto:support@bmj.com).

Visit [casereports.bmj.com](http://casereports.bmj.com) for more articles like this and to become a Fellow