

LETTER

Different hair loss patterns in two pediatric patients with COVID-19-associated multisystem inflammatory syndrome in children

Dear Editor,

Coronavirus disease 2019 (COVID-19) affects many organs and systems with varying clinical presentation among different age groups. During the early stages of the pandemic, pediatric population was relatively protected and the symptoms were mild in affected children. As the disease spread, more pediatric cases with severe symptoms were reported and a new syndrome, multisystem inflammatory syndrome in children (MIS-C), was identified in pediatric patients with COVID-19. MIS-C is associated with fever, multiple involvement, elevated inflammatory markers and mucocutaneous symptoms.¹ Here, we present two patients with different hair loss patterns who were diagnosed with MIS-C.

A 10-year-old boy (patient 1) was referred to dermatology outpatient clinic with diffuse hair loss. The hair loss started 4 weeks ago. Dermatologic examination showed reduction in hair volume with no visible alopecic patches (Figure 1). No erythema, scaling, crusts, erosions or follicular plugging was observed and dermatoscopic examination was within normal ranges. The hair pull test was positive over the entire scalp. The patient was diagnosed with telogen effluvium (TE) and detailed laboratory workup was performed to exclude other causes of diffuse hair loss including iron deficiency anemia, vitamin deficiencies and thyroid abnormalities. All laboratory parameters were within normal ranges. Two months ago, the patient was admitted to the hospital with high fever and severe cough. He tested positive for severe acute respiratory syndrome coronavirus 2 (SARS-CoV-2) and he was hospitalized. Soon after, he developed COVID-19-associated MIS-C.

A 13-year-old patient (patient 2) was consulted to dermatology department with a recently developed alopecic patch. Dermatological evaluation performed by a dermatology specialist showed an alopecic patch on the scalp with a diameter of 1 cm (Figure 2). The hair pull test was negative. The patient had no previous history of alopecia areata (AA) or other autoimmune diseases. The family history for AA was also negative. A month ago, he was also diagnosed with COVID-19-associated MIS-C with hepatic and gastrointestinal involvements.

Skin and mucous membranes are frequently effected in patients with MIS-C. Mucocutaneous symptoms are similar to Kawasaki disease and toxic shock syndrome.¹ Rash is the most frequent mucocutaneous finding and it is seen in almost 60% of the patients.¹ Conjunctivitis, cheilitis, strawberry tongue, erythema and edema of extremities are other common cutaneous features of MIS-C.¹ To the

best of our knowledge, hair loss was not reported in MIS-C patients. We observed two different types of hair loss, AA and TE, in two pediatric patients with COVID-19-related MIS-C. Hair loss is a common postinfectious cutaneous manifestation of adults and it was reported by 24.1% of the patients.² Both AA and TE were observed in adults previously diagnosed with COVID-19.^{3,4} The cause of hair loss in COVID-19 patients is unknown but stress and anxiety were the proposed precipitating factors. Severe COVID-19 infection with multi-system involvement may also cause anxiety and stress that may lead to AA and TE in pediatric population.

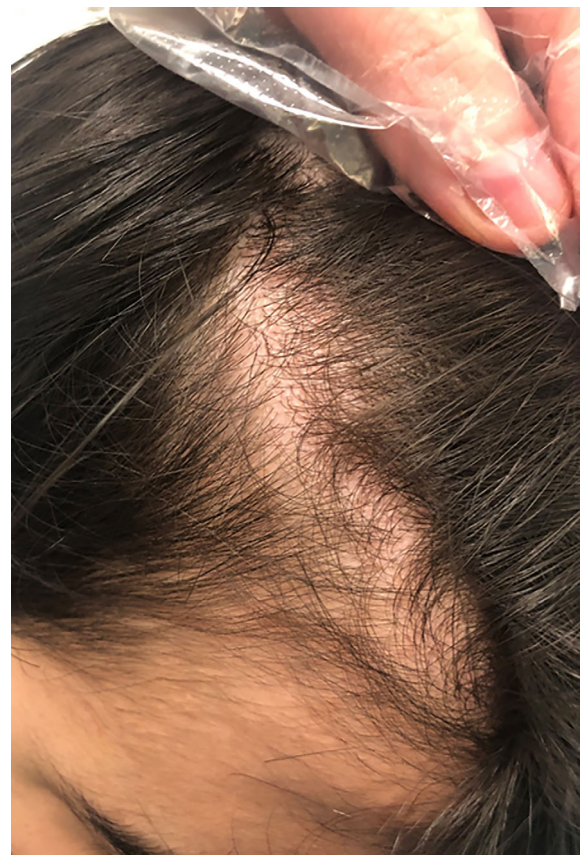

FIGURE 1 Reduction in hair volume with no visible alopecic patches

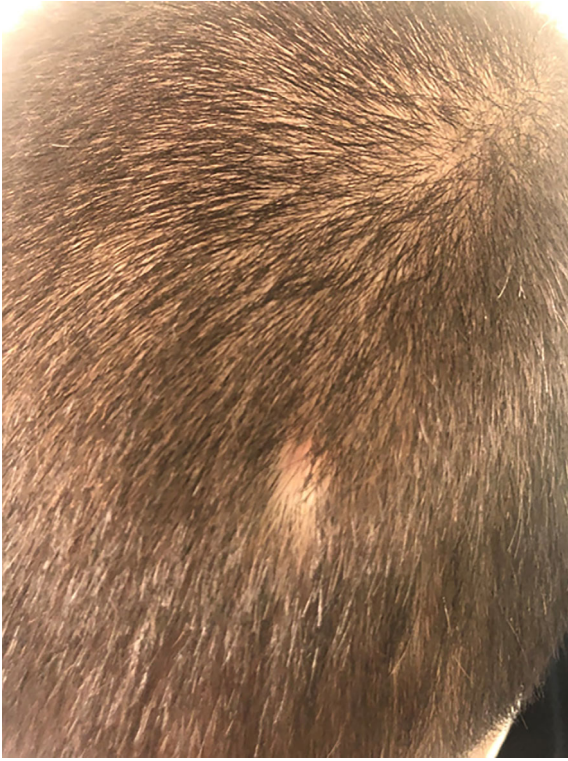

FIGURE 2 Alopecia areata on the scalp

CONFLICT OF INTEREST

The authors declare no potential conflict of interest.


AUTHOR CONTRIBUTIONS

Yıldız Hayran: Conception and planning of the study; interpretation of the data; writing of the manuscript; critical review of the literature; critical review of the manuscript. **Ahu Yorulmaz:** Interpretation of the data; writing of the manuscript; critical review of the literature; critical

review of the manuscript. **Güneş Gür:** Interpretation of the data; critical review of the literature; critical review of the manuscript. **Akın Aktaş:** Interpretation of the data; critical review of the literature; critical review of the manuscript.

DATA AVAILABILITY STATEMENT

Research data are not shared.

Yıldız Hayran 

Ahu Yorulmaz

Güneş Gür

Akın Aktaş

Department of Dermatology, Ankara City Hospital, Ankara, Turkey

Correspondence

Yıldız Hayran, Department of Dermatology, Ankara City Hospital, Üniversiteler, Bilkent Blv. No: 1, 06800 Çankaya, Ankara, Turkey.

Email: yildiz_kantarci@yahoo.com

ORCID

Yıldız Hayran  <https://orcid.org/0000-0003-1942-7285>

REFERENCES

1. Aronoff SC, Hall A, Del Vecchio MT. The natural history of SARS-Cov-2 related multisystem inflammatory syndrome in children (MIS-C): a systematic review. *J Pediatric Infect Dis Soc.* 2020.
2. Miyazato Y, Morioka S, Tsuzuki S, et al. Prolonged and late-onset symptoms of coronavirus disease 2019. *Open Forum Infect Dis.* 2020;7(11):ofaa507.
3. Mieczkowska K, Deutsch A, Borok J, et al. Telogen effluvium: a sequela of COVID-19. *Int J Dermatol.* 2020;60(1):122-124. <https://doi.org/10.1111/jjd.15313>. Epub 2020 Nov 23.
4. Flvenson D. COVID-19: association with rapidly progressive forms of alopecia areata. *Int J Dermatol.* 2020;60(1):127. <https://doi.org/10.1111/jjd.15317>. Epub 2020 Nov 23.