

# Wide-awake Local Anesthesia with No Tourniquet: An Updated Review

Joey S. Kurtzman, BA  
Jennifer I. Etcheson, MD  
Steven M. Koehler, MD

**Background:** The wide-awake local anesthesia with no tourniquet (WALANT) technique has become popularized for various hand/upper extremity procedures. Before surgery, patients receive local anesthetic, consisting of lidocaine with epinephrine, and remain awake for the entire procedure. The purpose of this review was to investigate the advantages, diverse application, outcomes, cost benefits, use in challenging environments, patient considerations, and contraindications associated with WALANT.

**Methods:** A comprehensive review of the literature on the WALANT technique was conducted. Search terms included: WALANT, wide-awake surgery, no tourniquet, local anesthesia, hand, wrist, cost, and safety.

**Results:** The WALANT technique has proven to be successful for common procedures such as flexor tendon repair, tendon transfer, trigger finger releases, Dupuytren disease, and simple bony procedures. Recently, the use of WALANT has expanded to more extensive soft-tissue repair, fracture management, and bony manipulation. Advantages include negating preoperative evaluation and testing for anesthesia clearance, eliminating risk of monitored anesthesia care, removal of anesthesia providers and ancillary staff, significant cost savings, and less waste produced. Intraoperative evaluations can be performed through active patient participation, and postoperative recovery and monitoring time are reduced. WALANT is associated with high patient satisfaction rates and low infection rates.

**Conclusions:** The WALANT technique has proven to be valuable to both patients and providers, optimizing patient satisfaction and providing substantial health-care savings. As its application continues to grow, current literature suggests positive outcomes. (*Plast Reconstr Surg Glob Open* 2021;9:e3507; doi: [10.1097/GOX.0000000000003507](https://doi.org/10.1097/GOX.0000000000003507); Published online 26 March 2021.)

## INTRODUCTION

Over a decade ago, Dr. Donald H. Lalonde first described the wide-awake local anesthesia with no tourniquet (WALANT) technique for the purpose of treating elective and select hand trauma cases in the outpatient setting.<sup>1,2</sup> Since its introduction, the adoption of the anesthetic technique has gained significant traction for its favorable outcomes and patient satisfaction.<sup>3-5</sup> With the wide-awake method, analgesia is delivered directly to the operative site through a local injection containing lidocaine and epinephrine.<sup>6</sup> The ability to perform common

hand procedures without the use of a tourniquet avoids pain and discomfort experienced by the awake patient while providing optimal pain control and hemostasis.<sup>2,7</sup> The inherent advantages of WALANT offer patients the convenience of fewer office visits while sidestepping the need to obtain preoperative clearances and preprocedure fasting.<sup>5</sup> Moreover, procedures can be performed in an office setting, resulting in sizable cost savings.<sup>8,9</sup> Despite early criticism for its combined use of lidocaine with epinephrine, the proposed risks of vasoconstrictive-induced ischemia and tissue necrosis have been negligible, and

*From the Department of Orthopaedic Surgery and Rehabilitation Medicine, State University of New York (SUNY), Downstate Medical Center, Brooklyn, N.Y.*

*Received for publication September 30, 2020; accepted December 9, 2020.*

*Copyright © 2021 The Authors. Published by Wolters Kluwer Health, Inc. on behalf of The American Society of Plastic Surgeons. This is an open-access article distributed under the terms of the [Creative Commons Attribution-Non Commercial-No Derivatives License 4.0 \(CCBY-NC-ND\)](https://creativecommons.org/licenses/by-nc-nd/4.0/), where it is permissible to download and share the work provided it is properly cited. The work cannot be changed in any way or used commercially without permission from the journal.*

*DOI: [10.1097/GOX.0000000000003507](https://doi.org/10.1097/GOX.0000000000003507)*

**Disclosure:** Dr. Koehler is a committee member of the American Society for Surgery of the Hand (ASSH), a paid consultant and speaker for Integra LifeSciences, Inc., a paid consultant for Tissium, Inc., a stockholder and member of the medical advisory board for Reactiv, Inc., a member of the advisory board for Androes, LLC, and a speaker for TriMed, Inc. The other authors have no financial interest to declare in relation to the content of this article.

Related Digital Media are available in the full-text version of the article on [www.PRSGlobalOpen.com](http://www.PRSGlobalOpen.com).

promising outcomes have provided supporting evidence for its continued use.<sup>1,7,10–16</sup> Additionally, the effects of epinephrine vasoconstriction can be reversed with phentolamine in a rescue setting. As such, the purported benefits of WALANT have made this anesthetic method an attractive option for surgeons, patients, and healthcare stakeholders. Guided by current literature on WALANT, this review outlines the advantages, wide-spread application, perioperative outcomes, cost benefits, implementation of the technique in challenging environments, patient considerations, and contraindications.

### ADVANTAGES OF WALANT

The advantages unique to WALANT have driven the recognition and utilization of the technique.<sup>2</sup> Patient safety and comfort is a principle benefit of avoiding tourniquet use, as potential nerve damage and pain from limb ischemia are circumvented in the awake patient.<sup>7,17</sup> Furthermore, the overall perioperative process has become streamlined with the technique. For procedures performed under WALANT, patients are not required to obtain preoperative clearances, fasting before the procedures is no longer necessary, and halting of medications is not warranted.<sup>18</sup> This is particularly ideal for patients with comorbidities, whom could benefit from surgical treatment, but would otherwise require extensive health clearances before undergoing general anesthesia.<sup>18</sup> The risks of monitored anesthesia care (MAC), commonly used in main operating rooms (ORs), have been well-documented, with older, overweight, and/or comorbid patients in particular facing higher risks.<sup>19,20</sup> Removing the need for MAC circumvents these risks and benefits for both patients and surgeons.<sup>2,21</sup>

With the wide-awake technique, anesthesia providers are no longer essential for obtaining surgical clearance, the administration of sedation, or monitoring the patient.<sup>22,23</sup> Moreover, OR ancillary staff and inpatient providers are no longer needed, which significantly saves healthcare resources and minimizes the financial strain placed on the health system.<sup>9</sup> In addition, minimal sterile draping and a smaller sterile field drive down associated procedure costs and contribute to the overall “green” nature of the approach.<sup>22,24</sup> There is mounting evidence suggesting no meaningful difference in infection rates with field sterility in ambulatory settings compared to fully sterile ORs for hand surgery.<sup>14</sup> A single drape, 4 surgical towels, gloves, a mask, and no gown or antibiotics are typically used for field sterility. With field sterility, both LeBlanc et al<sup>24</sup> and Rhee et al<sup>18</sup> report a low incidence of postoperative wound infection in carpal tunnel release and in a variety of hand procedures performed at a military medical center, respectively. Furthermore, our center recently conducted a study investigating the safety of performing hand/upper extremity procedures outside the main OR using minor field sterility with WALANT by evaluating superficial and deep infection rates across a diverse series of cases, including distal radius fracture open reduction internal fixation. We found a 0% 14-day and 0.3% 30-day infection rate (submitted, unpublished data) for procedures performed in a minor procedure room with field sterility.

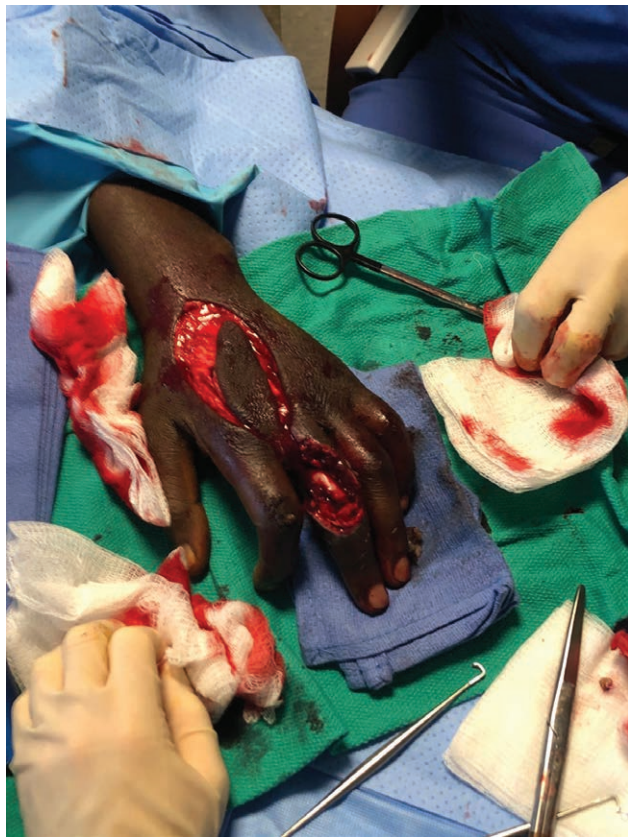Additionally, intraoperative evaluation of the strength and function of repairs and reductions is permitted through active patient participation, which has been associated with lower rerupture tendon rates and improved clinical outcomes.<sup>25,26</sup> Postoperative recovery time is optimized through the avoidance of common side effects accompanying general anesthesia, and as a result, postoperative anesthesia care unit monitoring is negated. Current literature highlights the increased efficiency, superior comfort, and safety benefits associated with WALANT.<sup>1,7,10–16</sup>

### DIVERSE APPLICATION

Since its development, WALANT has been accepted for its utility in a growing range of hand and wrist procedures.<sup>27</sup> Encouraging clinical outcomes for common procedures including flexor tendon repair, tendon transfer, trigger finger releases, and Dupuytren disease popularized WALANT early on.<sup>16,25,28–30</sup> However, multiple additional procedures have since been adopted. Hagert and Lalonde<sup>28</sup> reported using the wide-awake method in a case series of 9 patients that had undergone arthroscopic and open wrist arthroscopy for triangular fibrocartilage repair. Liu et al<sup>31</sup> describes wrist and small joint arthroscopy as being particularly suitable for the application of WALANT. In another report, Lalonde described the efficacy and utility of the wide-awake technique for carpal tunnel release, whereas Farhangkhoe et al<sup>32</sup> detailed the WALANT technique for performing wide-awake surgery for the basal joint trapeziectomy procedure. WALANT has also been used for trapeziometacarpal joint prosthesis implantation with no complications.<sup>33</sup> Additionally, Tang et al<sup>34</sup> and Xing and Tang<sup>34</sup> extended the use of the WALANT to flap harvesting and transfer in the hand. The authors reported successful execution of the extended Segmuller flap, the homodigital reverse digital artery flap, the dorsal metacarpal artery perforator flap, and the atasoy advancement flap on 27 patients using WALANT.<sup>23,34</sup> We have likewise, successfully performed hand-based dorsal metacarpal artery perforator (Quaba) flaps in addition to first dorsal metacarpal artery (kite) flaps with excellent results (Fig. 1).

The success of WALANT in simple bony procedures has also been well described and validated. The metacarpal and phalangeal fracture fixation with Kirschner wires demonstrates that WALANT was an appropriate alternative to general anesthesia.<sup>35</sup> Similarly, Rhee et al<sup>18</sup> reported fixation of phalange fractures could be achieved under wide-awake anesthesia and removal of hardware. Feldman et al<sup>36</sup> found that closed reduction and internal fixation or open reduction and internal fixation (ORIF) of metacarpal fractures can be performed successfully using WALANT.

The suitability of the WALANT technique for more extensive fracture management and bony manipulation has been less explored; however, recent studies demonstrate its successful application. In a randomized control trial of 169 patients with isolated distal radius fractures, Tahir et al<sup>37</sup> reported fewer complications when using WALANT compared to general anesthesia. In a series of 5 patients with intraarticular distal radius fractures



**Fig. 1.** Dorsal metacarpal artery perforator (Quaba) flap via WALANT.

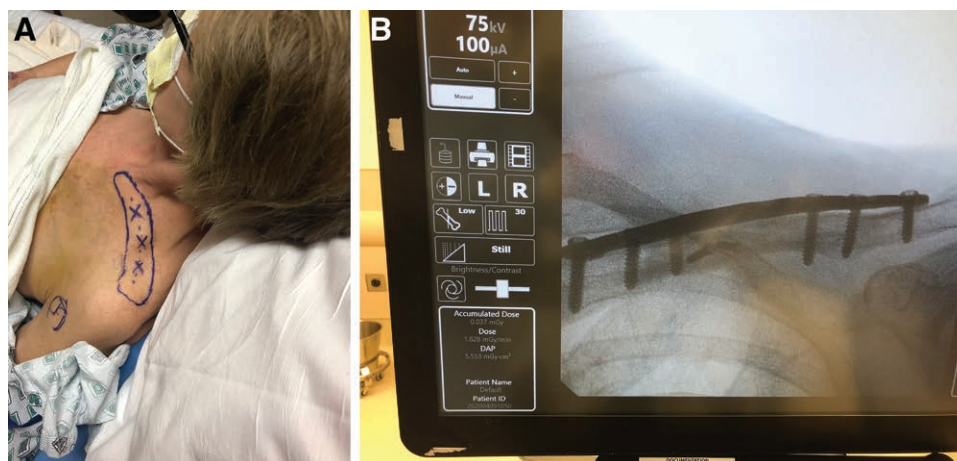
undergoing ORIF, Orbach et al<sup>38</sup> encountered zero complications and reported that the procedure was well-tolerated by all patients. Similarly, in separate studies, Ahmad et al<sup>39</sup> and Huang et al<sup>40</sup> reported no adverse events, infection, or implant failure when performing ORIF with plating for distal radius fractures. WALANT was also recently reported as a safe alternative to general anesthesia for plating clavicle fractures.<sup>41</sup> We have similarly had great success with WALANT for clavicle fixation (Fig. 2). In

another study, olecranon fracture plating was successfully completed without pain using WALANT.<sup>42</sup>

There are limited data on the use of the WALANT for lower extremity procedures; however, recent reports indicate its suitability. Li et al<sup>43</sup> reported no complications when using WALANT for ORIF of ankle fractures. Bilgetekin et al<sup>44</sup> used WALANT for medial malleolus fractures, lateral malleolus fractures, Achilles tendon ruptures, Lisfranc injury, medial malleolus + syndesmotic injury, deltoid ligament + syndesmotic injury, and fifth metatarsal fractures. The authors reported a median visual analog pain score of 1 (range 0–4) during surgery and no complications.<sup>44</sup> Poggetti et al<sup>45</sup> conducted a randomized study of 60 patients who underwent distal fibula hardware removal. Compared to the locoregional anesthesia with the tourniquet group, the WALANT group experienced significantly reduced postoperative pain and no difference in postoperative complication rates.<sup>45</sup> In the lower extremity, we have applied WALANT in ankle fracture fixation and local propeller flaps (Fig. 3). The literature supports the suitability of WALANT for wide-spread application and promising clinical results warrant further investigation.

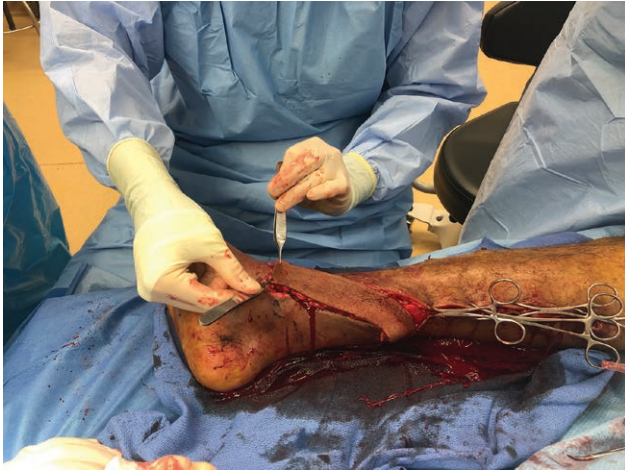## OUTCOMES

Postsurgical outcomes serve as surrogate markers of quality-of-care delivered, by which surgeons and reimbursement models can assess performance of a procedure, efficacy of resource utilization, and guide improvements.<sup>46</sup> In a series of reports by Lalonde and colleagues evaluating flexor tendon repairs, the authors describe several benefits of including the nonsedated patient in testing repairs. By asking the patient to actively flex and extend the flexor tendon repair, the surgeon has the opportunity to vent pulleys, which may be prohibiting full range of motion of the finger<sup>47,48</sup> (**Video 1**). (See **Video [online]**, which displays a zone II flexor tendon repair demonstrating the advantages of WALANT to vent pulleys.) Furthermore, gaps in the repair, which have been found in up to 7% of cases before final closure, may be repaired to prevent postoperative rerupture.<sup>26</sup> Additionally, visualizing the integrity of the repair in full active flexion and



**Fig. 2.** Clavicle fixation with WALANT. A, Outline of clavicle with preoperative injection sites marked with X. B, Intraoperative radiograph demonstrating clavicle fixation via WALANT (courtesy of Dr. Jeffrey Gelfand).





**Fig. 3.** Propeller flap via WALANT.

extension enables the surgeon and physical therapist to confidently permit a half-fist of full active flexion 3 days postprocedure.<sup>49</sup> With regards to joint fusion, wide-awake patients can perform a full range of active motion, thus guiding the final angle in thumb metacarpophalangeal joint (MP) and finger interphalangeal (IP) arthrodesis to achieve optimal function and cosmesis.<sup>21</sup> In ORIF of distal radius fractures using a volar plate, complications such as tendon rupture and nerve irritation can be avoided with direct visualization of flexor pollicis longus tendon gliding and median nerve irritation under physiologic motion. Additionally, patients have the ability to perform the active range of motion, enabling surgeons to identify possible impingement of implants.<sup>40</sup> The advantages of active patient participation in evaluating the strength and function of repairs and reductions have been attributed to superior clinical outcomes reported with WALANT.

Although traditional outcome measures provide an objective method to gauge efficacy of a surgical procedure, patient-centered outcomes, such as the patients' perception of care, are becoming an increasingly important component in evaluating healthcare delivery. Therefore, optimizing the patient's experience has garnered mounting attention, as patients may report dissatisfaction with their care, despite a successful surgery. Davison et al<sup>3</sup> found that patients undergoing WALANT for carpal tunnel release (CTR) reported lower preoperative anxiety than patients receiving intravenous sedation ( $2.3 \pm 2.68$  versus  $3.4 \pm 2.81$ ,  $P = 0.007$ ), as reported on a visual analog scale (0–10; 0 = lowest, 10 = highest) ( $P = 0.007$ ), and found no difference in preoperative and intraoperative anxiety among wide-awake patients ( $2.3 \pm 2.68$  versus  $2.1 \pm 2.49$ ,  $P > 0.05$ ). Bilgetekin et al<sup>44</sup> reported a median visual analog anxiety score of 1 (range 0–3) during surgery for patients undergoing foot and ankle injury repair using WALANT. Similarly, in a postoperative questionnaire, Teo et al<sup>50</sup> found that patients who had undergone WALANT for various hand procedures reported low levels of anxiety during their experience and described their pain during surgery as similar to a dental procedure. These reports support the notion that WALANT provides a comfortable patient experience.

Opioid-based pain medications are effective for providing postoperative analgesia; however, awareness surrounding the growing narcotic epidemic has driven efforts to minimize their administration. Miller et al<sup>51</sup> hypothesized that wide-awake patients undergoing TFR and CTR would require increased opioid-based medications to control postprocedure pain compared to patients receiving MAC. However, the authors found no difference in total pills consumed between the WALANT and MAC cohorts (3.85 versus 3.95,  $P = 0.86$ ), respectively.<sup>51</sup> The authors found that despite the use of longer-acting anesthetic, marcaine, in the MAC cohort, improved pain control was not observed. Similarly, Chapman et al<sup>52</sup> found that opioid consumption was comparable for patients undergoing CTR with WALANT or sedation (4.9 versus 3.9 pills,  $P = 0.22$ ), respectively. For minor hand surgeries, Ki Lee et al<sup>53</sup> reported a significantly longer duration of anesthetic effect, lower injection pain, and lower postoperative pain scores until the first day after surgery for WALANT patients versus those who received conventional anesthesia. Huang et al<sup>54</sup> found that WALANT patients with distal radius fractures experienced less postoperative pain than general anesthesia patients, whereas Kang et al<sup>55</sup> found that using WALANT for cubital and carpal tunnel surgery was superior for pain. These findings suggest effective analgesia can be achieved safely without the additional side effects of traditional anesthetic regimens. Moreover, we recently found a significant benefit to WALANT over MAC. In our study, 94 patients who underwent hand/upper extremity surgery via WALANT were prospectively enrolled and instructed to only use over-the-counter (OTC) nonopioid analgesics for pain control. Our control group consisted of 125 patients undergoing hand/upper extremity procedures via MAC. These patients were divided into (MAC+Opioids,  $n = 63$ ) and (MAC+OTC,  $n = 62$ ) groups. Pain was effectively managed in 97.9% of WALANT patients without postoperative opioid pain management. WALANT patients also experienced less pain at 14 days postoperation compared to patients who underwent MAC procedures without opioids. Postoperative day 14 mean visual analog scale scores were 0.37, 3.95, and 3.42 for the WALANT, MAC+Opioids, and MAC+OTC groups, respectively. Additionally, a greater proportion of MAC patients sought opioid prescriptions from outside providers (19.4%) for postoperative pain management in comparison to WALANT patients (2.1%). These results suggest that the WALANT technique improves postoperative pain outcomes compared to MAC.<sup>56</sup>

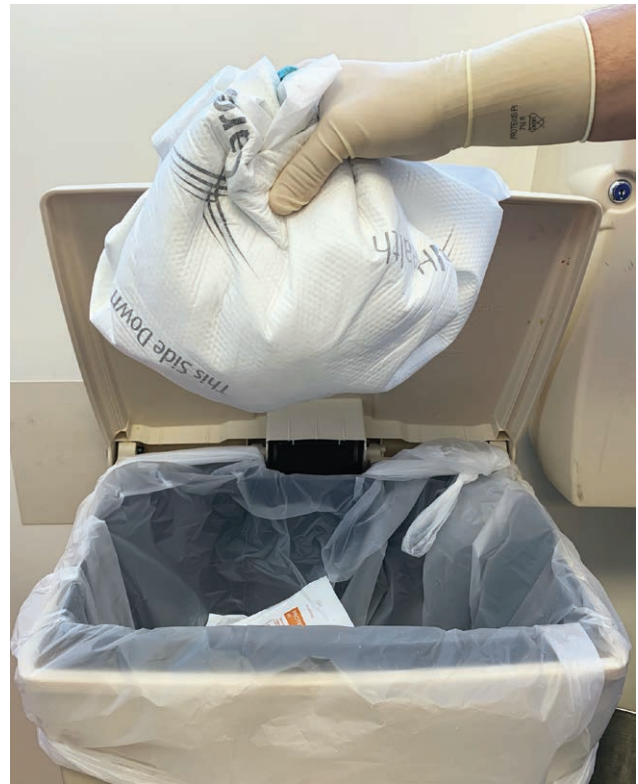### COST BENEFITS

Legislative pressures have spurred efforts to optimize value of care while driving down healthcare expenditures.<sup>46</sup> The WALANT technique has demonstrated favorable cost savings through improved patient satisfaction, avoiding costly preoperative testing requirements, decreased operative times, reduced utilization of hospital resources and staff, and time spent in the hospital.<sup>15,21</sup> Generally, patients undergoing wide-awake procedures are not required to obtain preoperative evaluation and testing for anesthesia clearance. As such, the costs associated with standardized preoperative laboratory tests, medical evaluations, and

clinic visits are avoided. Davison et al<sup>3</sup> found that wide-awake patients required far less preoperative testing when compared to patients that received intravenous sedation for carpal tunnel release (3% versus 48%,  $P < 0.001$ ). Furthermore, wide-awake patients spent significantly less time in hospital compared to their counterparts undergoing carpal tunnel release with sedation (2.6 versus 4.0 h,  $P < 0.001$ ). Similarly, Alter et al<sup>57</sup> reported postanesthesia times of 84 minutes for intravenous sedation and 7 minutes for WALANT patients undergoing carpal tunnel release procedures. Codding et al<sup>9</sup> reported significantly shorter postanesthesia care unit times for patients receiving WALANT compared to MAC (30.2 versus 72.3 min;  $P < 0.01$ ) for a single trigger finger release. In addition, the authors found that more costs were incurred by the MAC cohort, suggesting anesthesia type is a significant factor.

By circumventing the need for patient monitoring under anesthesia, the medical setting in which wide-awake procedures may be performed contributes to the cost savings of WALANT. Leblanc et al<sup>22</sup> performed an efficiency and cost analysis of performing carpal tunnel release in a fully sterile main hospital OR compared to ambulatory settings, including an office and a clinic, with field sterility. The authors reported their team could complete nine carpal tunnel release procedures in a 3-hour period in the ambulatory setting compared to 4 in the main OR, which translated to a cost savings of 70% per procedure when performed in the ambulatory setting. The surgeons' fee per case was the same in all settings. Using WALANT in ambulatory settings with field sterility leads to significant cost improvements for both surgeons and patients.<sup>27,58</sup> In a similar study, Chatterjee et al<sup>8</sup> reported that performing open carpal tunnel release in the clinic setting was one-fourth the cost of performing the procedure in a tertiary healthcare center (\$985 versus 2237). Alter et al<sup>57</sup> reported that patients undergoing carpal tunnel release using WALANT spent \$1320–\$1613 less than those who received intravenous sedation. Maliha et al<sup>59</sup> reported shorter turnover times for A1 pulley release procedures using WALANT in a procedure room versus the OR ( $31.1 \pm 11.1$  and  $65.3 \pm 17.7$  min) ( $P < 0.001$ ). Additionally, the cost of the instrument tray used in the OR was \$3304.25 versus \$993.79 in the procedure room. The cost per minute in the OR was \$44; this cost was absent for the procedure room.<sup>59</sup> Kazmers et al<sup>60</sup> found a 6.3-fold and 11.0-fold increase in cost for local anesthesia in the OR and MAC in the OR, respectively, compared to local anesthesia in a procedure room for open carpal tunnel release. For patients who are unable to receive surgery due to the high costs of MAC and OR fees, the substantially lower cost of WALANT increases access to necessary procedures.<sup>14</sup>

More recently, patient satisfaction has become an important metric utilized to determine hospital reimbursement in advanced payment models. Ayhan and Akasian<sup>61</sup> investigated the patient perspective in individuals who had undergone bilateral carpal tunnel release using intravenous local anesthesia in 1 hand and WALANT on the contralateral side. In a postoperative questionnaire, the investigators found that 83.3% of patients preferred WALANT for reoperation anesthesia. Ki Lee et al<sup>53</sup> found that patients who underwent WALANT for hand procedures were



**Fig. 4.** Collection of all disposable materials from 1 CTR procedure.

significantly more satisfied with surgery than those who received conventional anesthesia. Similarly, Xing and Tang<sup>34</sup> reported 96% of wide-awake patients who underwent flap harvest and transfer in the hand would choose WALANT again. Likewise, Davison et al<sup>3</sup> found that 93% of wide-awake patients undergoing carpal tunnel release would choose WALANT for future procedures.

It has been estimated that healthcare facilities in the United States produce 4 billion pounds of waste per year, 30%–70% of which is estimated to come from the OR.<sup>62,63</sup> Efforts to reduce surgical waste throughout the United States have shown promising results. Examples of initiative focuses include proper waste sorting,<sup>62,64</sup> recycling blue polypropylene wrap used for surgical equipment sterilization,<sup>63–65</sup> and streamlining surgical equipment trays and disposable packs.<sup>65–68</sup> Moving hand procedures from the main OR to the minor OR accomplishes similar goals by minimizing surgical equipment use and reducing disposable material waste, as reported by Van Demark et al.<sup>69</sup> Their initiative saved \$13,250.42 and 2.8 tons of waste over a 14-month period including 1099 hand cases. **Figure 4** displays the few waste materials generated during 1 procedure following the WALANT protocol. Waste reduction goes hand in hand with cost savings, making field sterility an attractive solution for institutions and their hand surgeons.

## WALANT IN CHALLENGING ENVIRONMENTS

Upper extremity trauma accounts for the majority of injuries among active soldiers and veterans, and consumes



the largest allocation of healthcare resources within the military health system. Challenging environments are commonplace in military medicine, as procedures are often required in resource limited settings where sterility is a significant factor.<sup>70</sup> As such, there is a significant role for WALANT, whereby this method can improve access to care while obviating the need for preprocedure testing and an extensive sterile field.<sup>24</sup> Rhee et al<sup>18</sup> examined patient satisfaction and cost savings associated with CTR, TFR, and deQuervain release (dQR) (66 patients, total of 71 procedures) performed in a military medical center orthopedic clinic by 1 hand surgeon over a 21-month period. The authors reported that 94% (62/66) of patients would choose WALANT again if they had to undergo the same procedure, and 71% (47/66) reported less intraoperative pain than a dental procedure performed with local anesthesia. Furthermore, the authors found this approach rendered a cost savings of \$393,099.53 over the study period by performing hand procedures under WALANT in the orthopedic clinic, rather than the OR. Wide-spread military adoption of the wide-awake technique is warranted, as substantial cost savings for the US military health system is likely.

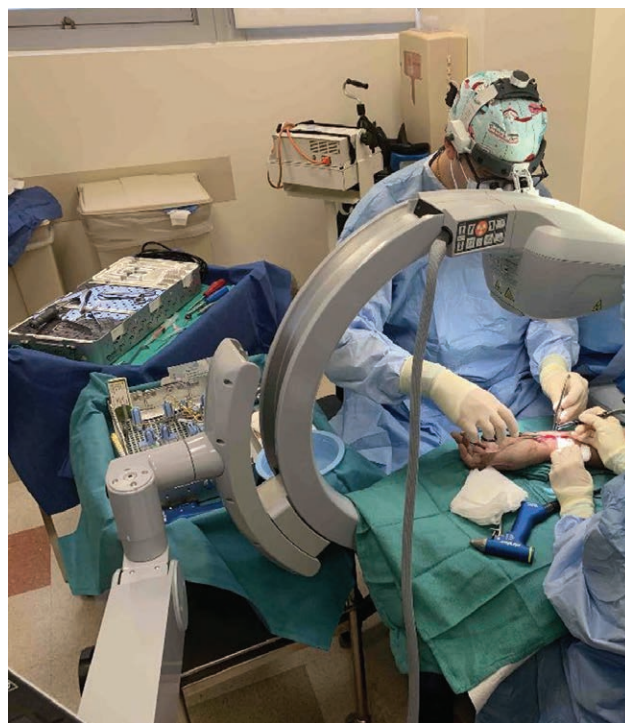In low- and middle-income countries, there is an estimated unmet need of 3383–6495 surgical operations per 100,000 people due to lack of facilities, proper equipment, and expertise.<sup>71,72</sup> Because of the decreased cost and resources necessary for WALANT, implementing the technique has the potential to make surgery more accessible to economically disadvantaged patients. For instance, Dr. Akbar Khan has been able to offer more tendon transfer procedures for leprosy patients in Nellore, India, due to the efficiency and lower cost of WALANT.<sup>73</sup> Additionally, leprosy patients reported being comfortable with WALANT and requested it for future surgery.<sup>73</sup> In 2017, North American hand surgeons collaborated with surgeons in Ghana to establish an affordable wide-awake hand surgery facility in Kumasi, Ghana. In its first year, 360 surgeries were performed at a much lower cost for local patients who otherwise would not have been able to afford hand reconstruction.<sup>74</sup> WALANT has proven potential to make surgical intervention more accessible to vulnerable populations.

### WALANT DURING COVID-19

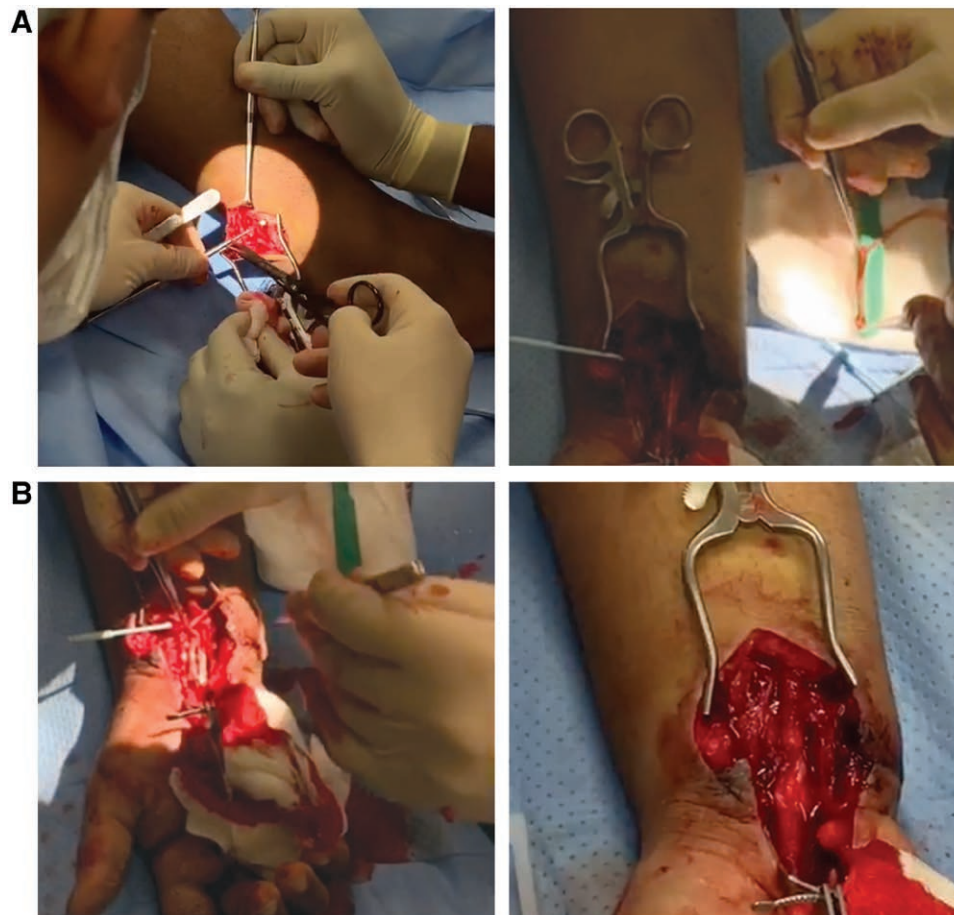
Currently, in times where limiting unnecessary exposure between healthcare providers and patients is paramount, WALANT presents a unique opportunity to provide continued care to patients. The intrinsic benefits, including bypassing preoperative testing requirements, minimizing the number and need for OR and postoperative anesthesia care unit personnel, and reducing medical waste through a limited field of sterility and draping make this mode of anesthesia an attractive choice. Although there is currently no published data surrounding the utilization of WALANT during the COVID-19 pandemic, its use may be appropriate, as the technique allows procedures to be performed in an outpatient setting rather than the OR. Our anecdotal experiences support these assertions.

Based in New York City, which was the initial epicenter of COVID-19 in the United States, our center was faced with the challenge to deliver care to our vulnerable community.<sup>75</sup> The Brooklyn Upper Limb Center is the provider of quaternary upper extremity subspecialty care in Brooklyn, home to 2.65 million people—1/3 of which are medically underserved. Complicating our ability to deliver care, the governor designated one of our hospitals as a “COVID-19 only” facility, whereas other hospitals have become overrun with COVID-19.<sup>76,77</sup> In March 2020, New York mandated the postponement or cancellation of all elective surgical procedures and for clinics to focus resources on urgent and emergency patient care only, following CDC guidelines.<sup>78</sup>

We had already made a significant transition to perform various common surgical procedures, including repair of tendon, nerve, and fractures, under WALANT, sparing patients anesthesia risks (Videos 2 and 3). (See Video 2 [online], which displays a zone III flexor tendon repair using WALANT.) (See Video 3 [online], which displays a pediatric WALANT ORIF of the forearm.) With few staff required, these procedures utilized minimal disposable items during this time of national shortages. We had already achieved low and comparable infection rates (0% 14-d and 0.3% 30-d infection rate—unpublished data) to an OR and were able to safely expand our procedural complexity (Videos 4 and 5). (See Video 4 [online], which displays median nerve reconstruction with sural nerve autograft using WALANT.) (See Video 5 [online], which displays



**Fig. 5.** Following restrictions on surgical procedures during the COVID-19 pandemic, we have since performed 72 cases during a 3-month “lockdown” under WALANT. The office-based minor procedure room setup and equipment are depicted here.



**Fig. 6.** Median nerve reconstruction (A) with sural nerve autograft (B).

showing peroneal nerve reconstruction with nerve allograft using WALANT.)

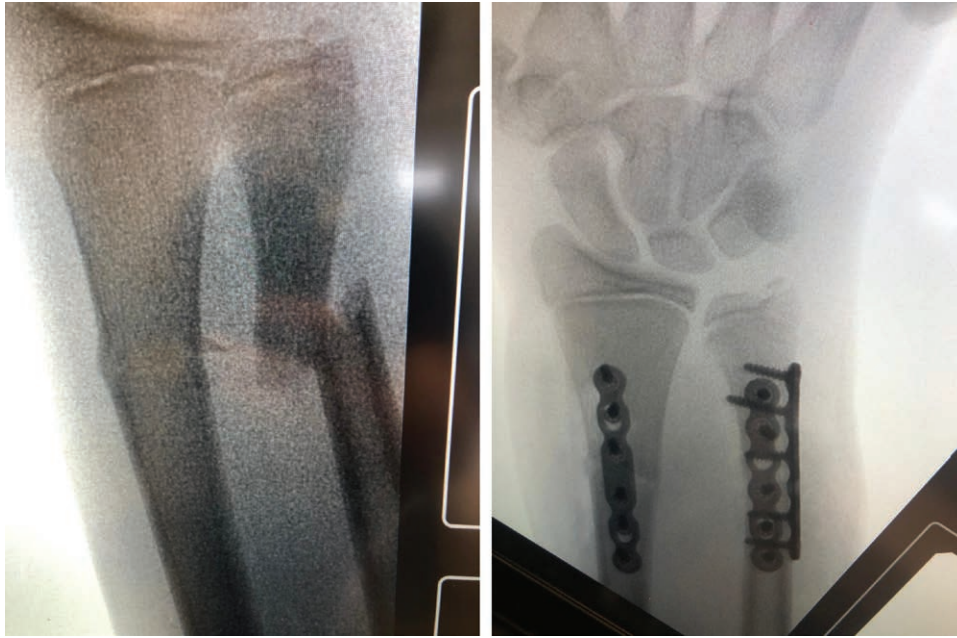During the height of the pandemic from March 16 to June 23, 2020, 72 cases were performed under WALANT, including a median nerve reconstruction with sural nerve, extensor tendon laceration repair, finger amputation, both bone forearm fracture fixation, and distal radius fracture fixation (Figs. 5–9). Combined with rigorous pre-clinic and on-site screening, we have been able to offer our patients urgent upper extremity surgical care in a safe environment while utilizing resources efficiently; all the while avoiding anesthesia-related risks and aerosolizing procedures. Despite the fact that hospital-based ORs and ambulatory surgery centers have been safely reopened, office-based WALANT has been demonstrated as a means to safely and effectively provide urgent adult and pediatric upper extremity care.

### **PATIENT CONSIDERATIONS AND CONTRAINDICATIONS**

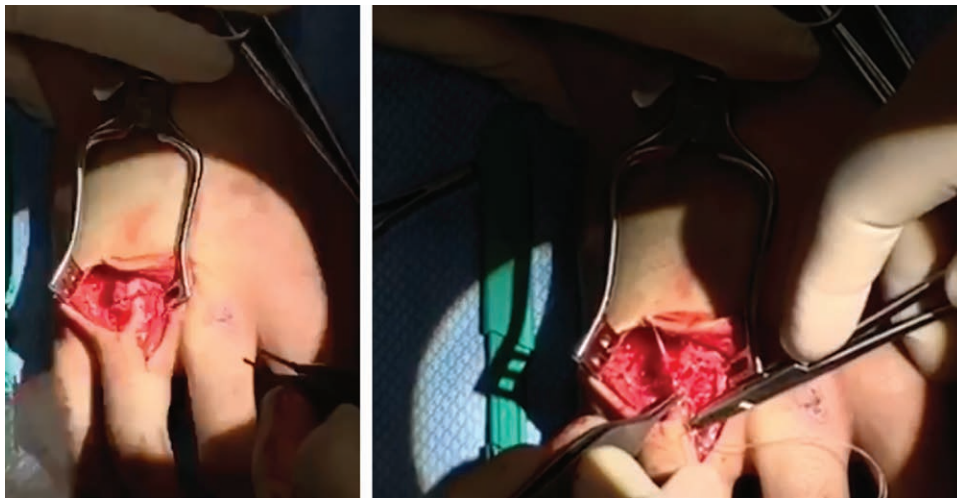
The WALANT technique provides many benefits to both patients and physicians; however, it is important to discuss patient considerations and contraindications associated with the technique. First, before surgery, patients

with compromised peripheral circulation or severe pre-operative ischemia from previous vascular injury, or diseases including scleroderma, Raynaud disease, Buerger disease, or vasculitis should be identified and possibly excluded from WALANT surgery.<sup>10</sup> We currently do not offer WALANT as an option for any of the aforementioned vascular diseases. For patients with cardiovascular concerns, there has been concern that epinephrine can induce unsafe tachycardia, especially in an unmonitored setting. However, we routinely recommend and perform WALANT in high-risk cardiovascular patients without reservations or complications. Recently, we submitted our outcomes of nearly 200 consecutive WALANT procedures in patients with an average Charlson Comorbidity Index of 1.27 for publication. There were no instances of LAST. Second, to successfully implement WALANT, physicians must ensure that patients are not hypersensitive to lidocaine and/or epinephrine and that they do not have allergies to the anesthetic medication. Recently, we encountered a patient with glucose-6-phosphate dehydrogenase deficiency, of which local anesthetics have been demonstrated to induce hemolysis.<sup>79</sup> This patient was operated on in the main OR under extensive monitoring. Patients' personalities, psychological conditions, anxiety levels, and comfort levels with WALANT must be assessed

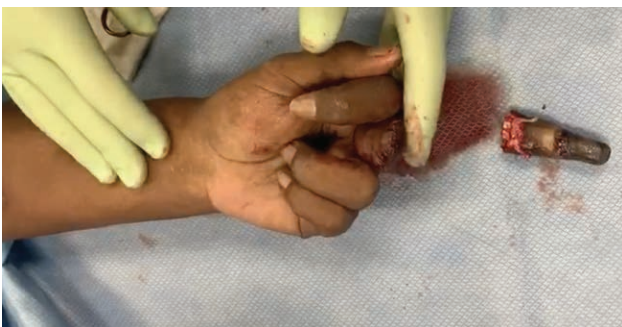



**Fig. 7.** Pediatric both bone forearm fracture fixation.



**Fig. 8.** Zone 4 extensor tendon laceration repair.



**Fig. 9.** Finger amputation.

before surgery, as not all patients are amenable to wide-awake procedures.<sup>40</sup> Those patients may be better suited for MAC. It is critical that surgeons provide an honest description of the WALANT procedure, and that patients have a full understanding of the procedure and administration of local anesthetic before surgery. However, we have found that many patients are receptive and even enthusiastic, yet when faced with fear and anxiety, preoperative video viewing and patient testimonials can be powerful tools in alleviating concerns. Even with a suitable temperament, some patients may experience distress, tremors, or nervousness after receiving the local anesthetic injection. In addition, patients may experience a



vasovagal syncope adverse reaction as a result of the injection.<sup>80</sup> As a result, in our practice, we recommend patients undergo injections while supine. Surgeons should be prepared to counsel patients who may experience these symptoms, and instruct them to lie down and or/elevate their feet to increase cerebral irrigation.<sup>80</sup> Furthermore, if patients experience adverse symptoms before or during surgery, surgeons must be prepared to provide monitoring to ensure patient safety.

## CONCLUSIONS

The WALANT method of anesthesia has demonstrated its value with regards to optimizing patient satisfaction and outcomes in various hand and wrist procedures. Minimal consumption of healthcare resources has translated to tangible annual health care savings. The utility of the wide-awake method has grown exponentially since its introduction, and has been tested in a broad scope of settings with positive results.

Steven M. Koehler, MD

Department of Orthopaedic Surgery and Rehabilitation  
Medicine  
SUNY Downstate Medical Center  
450 Clarkson Ave, BSB 3-07  
Brooklyn, NY 11203  
E-mail: Steven.Koehler@downstate.edu

## REFERENCES

- Lalonde D, Bell M, Benoit P, et al. A multicenter prospective study of 3,110 consecutive cases of elective epinephrine use in the fingers and hand: The Dalhousie Project clinical phase. *J Hand Surg Am.* 2005;30:1061–1067.
- Lalonde D, Martin A. Epinephrine in local anesthesia in finger and hand surgery: the case for wide-awake anesthesia. *J Am Acad Orthop Surg.* 2013;21:443–447.
- Davison PG, Cobb T, Lalonde DH. The patient's perspective on carpal tunnel surgery related to the type of anesthesia: a prospective cohort study. *Hand (N Y).* 2013;8:47–53.
- Gunasagaran J, Sean ES, Shivdas S, et al. Perceived comfort during minor hand surgeries with wide awake local anaesthesia no tourniquet (WALANT) versus local anaesthesia (LA)/tourniquet. *J Orthop Surg (Hong Kong).* 2017;25:2309499017739499.
- O'Neill N, Abdall-Razak A, Norton E, et al. Use of wide-awake local anaesthetic no tourniquet (WALANT) in upper limb and hand surgery: a systematic review protocol. *Int J Surg Protoc.* 2020;20:8–12.
- Lalonde DH. "Hole-in-one" local anesthesia for wide-awake carpal tunnel surgery. *Plast Reconstr Surg.* 2010;125:1642–1644.
- Mustoe TA, Buck DW, Lalonde DH. The safe management of anesthesia, sedation, and pain in plastic surgery. *Plast Reconstr Surg.* 2010;126:165e–176e.
- Chatterjee A, McCarthy JE, Montagne SA, et al. A cost, profit, and efficiency analysis of performing carpal tunnel surgery in the operating room versus the clinic setting in the United States. *Ann Plast Surg.* 2011;66:245–248.
- Codding JL, Bhat SB, Ilyas AM. An economic analysis of MAC versus WALANT: a trigger finger release surgery case study. *Hand (N Y).* 2017;12:348–351.
- Thomson CJ, Lalonde DH, Denkler KA, et al. A critical look at the evidence for and against elective epinephrine use in the finger. *Plast Reconstr Surg.* 2007;119:260–266.
- Fitzcharles-Bowe C, Denkler K, Lalonde D. Finger injection with high-dose (1:1,000) epinephrine: does it cause finger necrosis and should it be treated? *Hand.* 2007;2:5–11.
- Herman A, Kalimian T, Segal O, et al. Keeping the finger on the pulse: cardiac arrhythmias in hand surgery using local anesthesia with adrenaline. *Plast Reconstr Surg.* 2020;146:54E–60E.
- Steiner MM, Calandruccio JH. Use of wide-awake local anesthesia no tourniquet in hand and wrist surgery. *Orthop Clin North Am.* 2018;49:63–68.
- Lalonde DH. Latest advances in wide awake hand surgery. *Hand Clin.* 2019;35:1–6.
- Van Demark RE Jr, Becker HA, Anderson MC, et al. Wide-awake anesthesia in the in-office procedure room: lessons learned. *Hand (N Y).* 2018;13:481–485.
- Warrender WJ, Lucasti CJ, Ilyas AM. Wide-awake hand surgery: principles and techniques. *JBJS Rev.* 2018;6:e8.
- Ruxasagulwong S, Kraissarin J, Sananpanich K. Wide awake technique versus local anesthesia with tourniquet application for minor orthopedic hand surgery: a prospective clinical trial. *J Med Assoc Thai.* 2015;98:106–110.
- Rhee PC, Fischer MM, Rhee LS, et al. Cost savings and patient experiences of a Clinic-based, wide-awake hand surgery program at a Military Medical Center: a critical analysis of the first 100 procedures. *J Hand Surg Am.* 2017;42:e139–e147.
- Li G, Warner M, Lang BH, et al. Epidemiology of anesthesia-related mortality in the United States, 1999–2005. *Anesthesiology.* 2009;110:759–765.
- McAlister FA, Bertsch K, Man J, et al. Incidence of and risk factors for pulmonary complications after nonthoracic surgery. *Am J Respir Crit Care Med.* 2005;171:514–517.
- Lalonde D, Martin A. Tumescent local anesthesia for hand surgery: improved results, cost effectiveness, and wide-awake patient satisfaction. *Arch Plast Surg.* 2014;41:312–316.
- Leblanc MR, Lalonde J, Lalonde DH. A detailed cost and efficiency analysis of performing carpal tunnel surgery in the main operating room versus the ambulatory setting in Canada. *Hand (N Y).* 2007;2:173–178.
- Tang JB, Gong KT, Xing SG, et al. Wide-awake hand surgery in two centers in China: experience in Nantong and Tianjin with 12,000 patients. *Hand Clin.* 2019;35:7–12.
- Leblanc MR, Lalonde DH, Thoma A, et al. Is main operating room sterility really necessary in carpal tunnel surgery? A multicenter prospective study of minor procedure room field sterility surgery. *Hand (N Y).* 2011;6:60–63.
- Lalonde DH. Wide-awake flexor tendon repair. *Plast Reconstr Surg.* 2009;123:623–625.
- Higgins A, Lalonde DH, Bell M, et al. Avoiding flexor tendon repair rupture with intraoperative total active movement examination. *Plast Reconstr Surg.* 2010;126:941–945.
- Lalonde D. Minimally invasive anesthesia in wide awake hand surgery. *Hand Clin.* 2014;30:1–6.
- Hagert E, Lalonde D. Wide-awake wrist arthroscopy and open TFCC repair. *J Wrist Surg.* 2012;1:55–60.
- Nelson R, Higgins A, Conrad J, et al. The wide-awake approach to Dupuytren's disease: fasciectomy under local anesthetic with epinephrine. *Hand (N.Y).* 2010;5:117–124.
- Tang JB. Wide-awake primary flexor tendon repair, tenolysis, and tendon transfer. *Clin Orthop Surg.* 2015;7:275–281.
- Liu B, Ng CY, Arshad MS, et al. Wide-awake wrist and small joints arthroscopy of the hand. *Hand Clin.* 2019;35:85–92.
- Farhangkhoei H, Lalonde J, Lalonde DH. Wide-awake trapeziectomy: video detailing local anesthetic injection and surgery. *Hand (N Y).* 2011;6:466–467.
- Müller CT, Christen T, Heidekruger PI, et al. Wide-awake anesthesia no tourniquet trapeziometacarpal joint prosthesis implantation. *Plast Reconstr Surg Glob Open.* 2018;6:e1714.
- Xing SG, Tang JB. Extending applications of local anesthesia without tourniquet to flap harvest and transfer in the hand. *Hand Clin.* 2019;35:97–102.

35. Gregory S, Lalonde DH, Fung Leung LT. Minimally invasive finger fracture management: wide-awake closed reduction, K-wire fixation, and early protected movement. *Hand Clin.* 2014;30:7–15.
36. Feldman G, Orbach H, Rinat B, et al. Internal fixation of metacarpal fractures using wide awake local anesthesia and no tourniquet. *Hand Surg Rehabil.* 2020;39:214–217.
37. Tahir M, Zaffar Z, Anwar K, et al. Fixation of distal radius fractures using wide-awake local anaesthesia with no tourniquet (WALANT) technique. *Bone Joint Res.* 2020;9:429–439.
38. Orbach H, Rozen N, Rubin G. Open reduction and internal fixation of intra-articular distal radius fractures under wide-awake local anesthesia with no tourniquet. *J Int Med Res.* 2018;46:4269–4276.
39. Ahmad AA, Yi LM, Ahmad AR. Plating of distal radius fracture using the wide-awake anesthesia technique. *J Hand Surg Am.* 2018;43:1045.e1–1045.e5.
40. Huang YC, Hsu CJ, Renn JH, et al. WALANT for distal radius fracture: open reduction with plating fixation via wide-awake local anesthesia with no tourniquet. *J Orthop Surg Res.* 2018;13:195.
41. Ahmad AA, Ubaidah Mustapa Kamal MA, Ruslan SR, et al. Plating of clavicle fracture using the wide-awake technique. *J Shoulder Elb Surg.* 2020;29:2319–2325.
42. Ahmad AA, Sabari SS, Ruslan SR, et al. Wide-awake anesthesia for olecranon fracture fixation. *Hand.* 2019:19.
43. Li YS, Chen CY, Lin KC, et al. Open reduction and internal fixation of ankle fracture using wide-awake local anaesthesia no tourniquet technique. *Injury.* 2019;50:990–994.
44. Bilgetekin YG, Kuzucu Y, Öztürk A, et al. The use of the wide-awake local anesthesia no tourniquet technique in foot and ankle injuries. *Foot Ankle Surg.* 2020:2–5 (E-pub ahead of print).
45. Poggetti A, Del Chiaro A, Nicasastro M, et al. A local anesthesia without tourniquet for distal fibula hardware removal after open reduction and internal fixation: the safe use of epinephrine in the foot. A randomized clinical study. *J Biol Regul Homeost Agents.* 2018;32(6 suppl 1):57–63.
46. McGlaston TJ, Kim DW, Schrodell P, et al. Few insurance-based differences in upper extremity elective surgery rates after healthcare reform. *Clin Orthop Relat Res.* 2012;470:1917–1924.
47. Lalonde DH, Kozin S. Tendon disorders of the hand. *Plast Reconstr Surg.* 2011;128:1e–14e.
48. Woo SH, Yoo MJ, Ahn HC. Lessons learned in the authors' first years of wide-awake hand surgery at the W Hospital in Korea. *Hand Clin.* 2019;35:59–66.
49. Lalonde DH, Martin AL. Wide-awake flexor tendon repair and early tendon mobilization in zones 1 and 2. *Hand Clin.* 2013;29:207–213.
50. Teo I, Lam W, Muthayya P, et al. Patients' perspective of wide-awake hand surgery—100 consecutive cases. *J Hand Surg Eur Vol.* 2013;38:992–999.
51. Miller A, Kim N, Ilyas AM. Prospective evaluation of opioid consumption following hand surgery performed wide awake versus with sedation. *HAND (N Y).* 2017;12:606–609.
52. Chapman T, Kim N, Maltenfort M, et al. Prospective evaluation of opioid consumption following carpal tunnel release surgery. *Hand (N Y).* 2017;12:39–42.
53. Ki Lee S, Gul Kim S, Sik Choy W. A randomized controlled trial of minor hand surgeries comparing wide awake local anesthesia no tourniquet and local anesthesia with tourniquet. *Orthop Traumatol Surg Res.* 2020;106:1645–1651.
54. Huang YC, Chen CY, Lin KC, et al. Comparison of wide-awake local anesthesia no tourniquet with general anesthesia with tourniquet for volar plating of distal radius fracture. *Orthopedics.* 2019;42:e93–e98.
55. Kang SW, Park HM, Park JK, et al. Open cubital and carpal tunnel release using wide-awake technique: reduction of postoperative pain. *J Pain Res.* 2019;12:2725–2731.
56. Dar Q-A, Avoricani A, Rompala A, et al. WALANT hand surgery does not require postoperative opioid pain management. *Plast Reconstr Surg.* 2021 (in press).
57. Alter TH, Warrender WJ, Liss FE, et al. A cost analysis of carpal tunnel release surgery performed wide awake versus under sedation. *Plast Reconstr Surg.* 2018;142:1532–1538.
58. Bismil M, Bismil Q, Harding D, et al. Transition to total one-stop wide-awake hand surgery service-audit: a retrospective review. *JRSM Short Rep.* 2012;3:23.
59. Maliha SG, Cohen O, Jacoby A, et al. A cost and efficiency analysis of the WALANT technique for the management of trigger finger in a procedure room of a major city hospital. *Plast Reconstr Surg Glob Open.* 2019;7:e2509.
60. Kazmers NH, Presson AP, Xu Y, et al. Cost implications of varying the surgical technique, surgical setting, and anesthesia type for carpal tunnel release surgery. *J Hand Surg Am.* 2018;43:971–977.e1.
61. Ayhan E, Akaslan F. Patients' perspective on carpal tunnel release with WALANT or intravenous regional anesthesia. *Plast Reconstr Surg.* 2020;145:1197–1203.
62. Lee RJ, Mears SC. Greening of orthopedic surgery. *Orthopedics.* 2012;35:e940–e944.
63. Babu MA, Dalenberg AK, Goodsell G, et al. Greening the operating room: results of a scalable initiative to reduce waste and recover supply costs. *Neurosurgery.* 2019;85:432–437.
64. Kwakye G, Brat GA, Makary MA. Green surgical practices for health care. *Arch Surg.* 2011;146:131–136.
65. Albert MG, Rothkopf DM. Operating room waste reduction in plastic and hand surgery. *Plast Surg (Oakv).* 2015;23:235–238.
66. Farrelly JS, Clemons C, Witkins S, et al. Surgical tray optimization as a simple means to decrease perioperative costs. *J Surg Res.* 2017;220:320–326.
67. Dyas AR, Lovell KM, Balentine CJ, et al. Reducing cost and improving operating room efficiency: examination of surgical instrument processing. *J Surg Res.* 2018;229:15–19.
68. Nast K, Swords KA. Decreasing operating room costs via reduction of surgical instruments. *J Pediatr Urol.* 2019;15:153.e1–153.e6.
69. Van Demark RE Jr, Smith VJS, Fiegen A. Lean and green hand surgery. *J Hand Surg Am.* 2018;43:179–181.
70. Rhee PC. The current and possible future role of wide-awake local anesthesia no tourniquet hand surgery in military health care delivery. *Hand Clin.* 2019;35:13–19.
71. Rose J, Weiser TG, Hider P, et al. Estimated need for surgery worldwide based on prevalence of diseases: a modelling strategy for the WHO Global Health Estimate. *Lancet Glob Health.* 2015;3(suppl 2):S13–20.
72. Grimes CE, Bowman KG, Dodgion CM, et al. Systematic review of barriers to surgical care in low-income and middle-income countries. *World J Surg.* 2011;35:941–950.
73. Mohammed AK, Lalonde DH. Wide awake tendon transfers in leprosy patients in India. *Hand Clin.* 2019;35:67–84.
74. Behar BJ, Danso OO, Farhat B, et al. Collaboration in outreach: the Kumasi, Ghana, model. *Hand Clin.* 2019;35:429–434.
75. New York City Department of Health. COVID-19: data. 2020. Available at: <https://www1.nyc.gov/site/doh/covid/covid-19-data.page>. Accessed September 27, 2020.
76. Cuomo A. Amid ongoing COVID-19 pandemic, Governor Cuomo issues executive order moving New York presidential primary election to June 23rd. New York State. March 28, 2020. Available at: <https://www.governor.ny.gov/news/amid-ongoing-covid-19-pandemic-governor-cuomo-issues-executive-order-moving-new-york>. Accessed September 27, 2020.



77. Skeete-Walker D. Statement on University Hospital of Brooklyn designated by Governor Cuomo as a COVID-19 ONLY Facility. SUNY Downstate Health Sciences University. March 28, 2020. Available at: [https://www.downstate.edu/news\\_releases/2020/03-28-2020.html](https://www.downstate.edu/news_releases/2020/03-28-2020.html). Accessed September 27, 2020.
78. Centers for Disease Control and Prevention. Healthcare facilities: managing operations during the COVID-19 pandemic. Updated June 28, 2020. Available at: <https://www.cdc.gov/coronavirus/2019-ncov/hcp/guidance-hcf.html>. Accessed September 28, 2020.
79. Hegedus F, Herb K. Benzocaine-induced methemoglobinemia. *Anesth Prog*. 2005;52:136–139.
80. Pires Neto PJ, Moreira LA, Las Casas PP. Is it safe to use local anesthesia with adrenaline in hand surgery? WALANT technique. *Rev Bras Ortop*. 2017;52:383–389.