



Since January 2020 Elsevier has created a COVID-19 resource centre with free information in English and Mandarin on the novel coronavirus COVID-19. The COVID-19 resource centre is hosted on Elsevier Connect, the company's public news and information website.

Elsevier hereby grants permission to make all its COVID-19-related research that is available on the COVID-19 resource centre - including this research content - immediately available in PubMed Central and other publicly funded repositories, such as the WHO COVID database with rights for unrestricted research re-use and analyses in any form or by any means with acknowledgement of the original source. These permissions are granted for free by Elsevier for as long as the COVID-19 resource centre remains active.



Letter to the editor

Re: Unilateral axillary adenopathy in the setting of COVID-19 vaccine, Clinical Imaging, January 2021

ARTICLE INFO

*Keywords*COVID-19 vaccine
Unilateral axillary adenopathy
PET/CT

We read with great interest the excellent article titled “Unilateral axillary Adenopathy in the setting of COVID-19 vaccine” by Mehta et al. in the January 2021 issue of Clinical Imaging.¹ The authors describe the phenomenon of unilateral axillary lymphadenopathy related to Covid-19 vaccine injection in the ipsilateral arm, having encountered four cases on sonography during routine breast imaging since the initiation of Covid-19 vaccination programmes. Lack of knowledge of this phenomenon can lead to erroneous diagnosis of metastatic nodal disease.

We recently encountered the same issue in our practice, in a fifty-year-old male patient who underwent PET/CT to investigate for metastatic disease. Several unilateral FDG avid axillary lymph nodes were identified (Fig. 1), which was incongruent with the site of the primary malignancy and the otherwise normal study. This posed a diagnostic

dilemma, before further inquiry revealed the patient had been inoculated with a second dose of the Pfizer mRNA Covid-19 vaccine in the ipsilateral arm 10 days prior.

The incidence of axillary lymphadenopathy following vaccination was as high as 16% in clinical trials.² As mass vaccination programmes become established it is likely that we will see the prevalence of reactive unilateral axillary lymphadenopathy rise over the coming months, which will be apparent across a spectrum of modalities including CT, MRI, ultrasound and PET/CT. It is important that radiologists are aware of this finding to avoid over staging patients.

We commend the authors for raising awareness of this phenomenon, which will help reduce unnecessary invasive investigations and patient anxiety.

<https://doi.org/10.1016/j.clinimag.2021.02.045>

Received 22 February 2021; Accepted 23 February 2021

Available online 30 March 2021

0899-7071/© 2021 Elsevier Inc. All rights reserved.

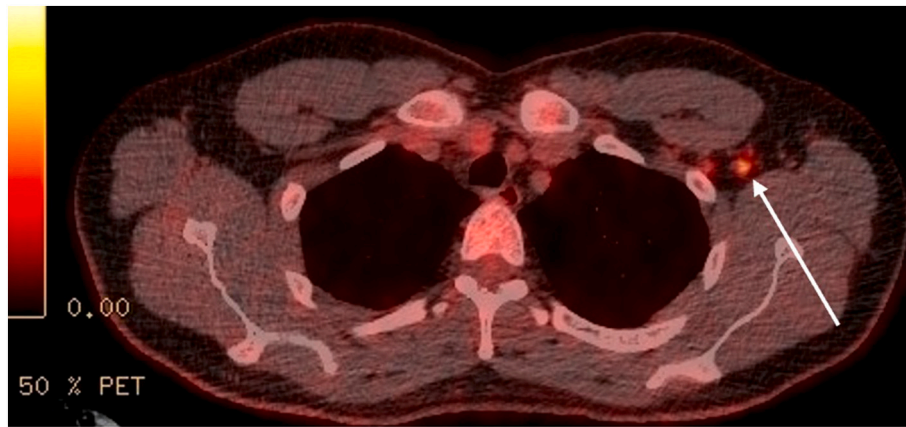


Fig. 1. PET/CT demonstrating FDG avid left axillary lymphadenopathy in a fifty year old man, 10 days after inoculation with Pfizer mRNA Covid-19 vaccine in the ipsilateral arm.

Funding sources

None.

Declaration of competing interest

No disclosures.

References

[1] Mehta N, Sales R, Babagbemi K, et al. Unilateral axillary adenopathy in the setting of COVID-19 vaccine. *Clin Imaging* 2021;75:12–5.

2. Local Reactions, Systemic Reactions, Adverse Events, and Serious Adverse Events. Moderna COVID-19 Vaccine|CDC [Internet]. Cdc.gov; 2021 [cited 14 February 2021]. Available from: <https://www.cdc.gov/vaccines/covid-19/info-by-product/moderna/reactogenicity.html>.

John Finnegan*, Pradeep Govender, William Cassar Torreggiani
Tallaght University Hospital, Tallaght, Dublin D24 NR04, Ireland

* Corresponding author.

E-mail address: John.finnegan@tuh.ie (J. Finnegan).