


## Case Report

# CSF Leak After COVID-19 Nasopharyngeal Swab: A Case Report

Rebecca Paquin, MD, DMD ; Lindsey Ryan, MD; Fernando L. Vale, MD;  
Martin Rutkowski, MD; James Kenneth Byrd, MD

The nasopharyngeal swab has been used with increased frequency since the beginning of the COVID-19 pandemic. Little has been written in the literature regarding the complications arising from this procedure, as it is generally accepted as safe. In this report, we describe a case in which a young woman sustained a traumatic skull base injury during a nasopharyngeal swab for COVID-19. We then discuss the subsequent treatment and outcome. This case demonstrates the potential for significant complications arising from this widespread procedure and the necessity for awareness of these potential complications.

**Key Words:** Coronavirus, COVID-19, CSF leak, encephalocele, nasal endoscopy.

*Laryngoscope*, 131:1927–1929, 2021

## INTRODUCTION

Coronavirus disease 19 (COVID-19) has, as of January 17, 2021, caused 94.2 million total confirmed cases and 2 million deaths worldwide.<sup>1</sup> Policymakers and researchers rely on widespread screening to understand the spread of the disease. There are now six acceptable specimen types approved by the Center for Disease Control (CDC) for screening; the recommended and most commonly deployed test is the nasopharyngeal (NP) swab.<sup>2</sup> Complications resulting from the NP swab have not been reported extensively in the literature. In this case report, we describe a traumatic cerebrospinal fluid (CSF) leak following an NP swab as well as the subsequent treatment and short-term outcome.

## CASE REPORT

The patient is a 38-year-old female who presented to our hospital after experiencing severe pain during an NP swab for COVID followed by 2 days of persistent clear watery rhinorrhea that worsened with leaning forward. She also noticed persistent headache and metallic tasting postnasal drip. The patient had no history of head trauma or surgery. She was otherwise healthy.

Initial exam, including nasal endoscopy, was unremarkable other than a small amount of clear right-sided nasal drainage. The patient underwent a computed tomography scan, which demonstrated a subtle defect in the posterior right cribriform plate (Fig. 1). She then underwent magnetic resonance imaging, which demonstrated a small encephalocele projecting from the olfactory fossa of the right superior nasal cavity (Fig. 2).

The decision was made at that time to explore and perform a skull base repair. The patient was taken to the operating room the following day for endoscopic endonasal approach with stereotactic navigation. The posterior cribriform and ethmoid roof were not visualized with lateralization of the middle turbinate, and so it was removed and its mucosa harvested for a free graft. This allowed visualization of a small encephalocele just anterior to the sphenoid rostrum at the junction between the cribriform and ethmoid roof (Fig. 3). Valsalva resulted in visible pulsation and increased flow of CSF. The surrounding bone and mucosa were removed, exposing the dura. The encephalocele was reduced with bipolar cautery. The free mucosal graft was then placed over the expanse of the exposed dura and CSF leak. Cessation of the CSF leak was confirmed (Fig. 4). Surgicel was then placed around the margin of the graft, and dural sealant was applied. This was followed by Gelfoam and a sponge packing.

The patient was placed on sinus precautions and observed overnight. She progressed appropriately and was discharged the following day. She was seen in follow-up on postoperative day 9 and reported resolution of all symptoms. The nasal sponge was removed at that time. Nasal endoscopy demonstrated appropriately healing mucosa and no signs of a persistent CSF leak.

From the Department of Otolaryngology—Head and Neck Surgery, Medical College of Georgia (R.P., L.R., J.K.B.), Augusta University, Augusta, Georgia, U.S.A.; Department of Neurosurgery, Medical College of Georgia (F.L.V., M.R.), Augusta University, Augusta, Georgia, U.S.A.

Editor's Note: This Manuscript was accepted for publication on February 5, 2021

The authors have no funding, financial relationships, or conflicts of interest to disclose.

This case report did not meet the criteria to require IRB approval.

Send correspondence to: Rebecca Paquin, MD, DMD, Department of Otolaryngology-Head and Neck Surgery, Medical College of Georgia, Augusta University, 1120 15th Street, Augusta, GA 30901. E-mail: rpaquin@augusta.edu

DOI: 10.1002/lary.29462

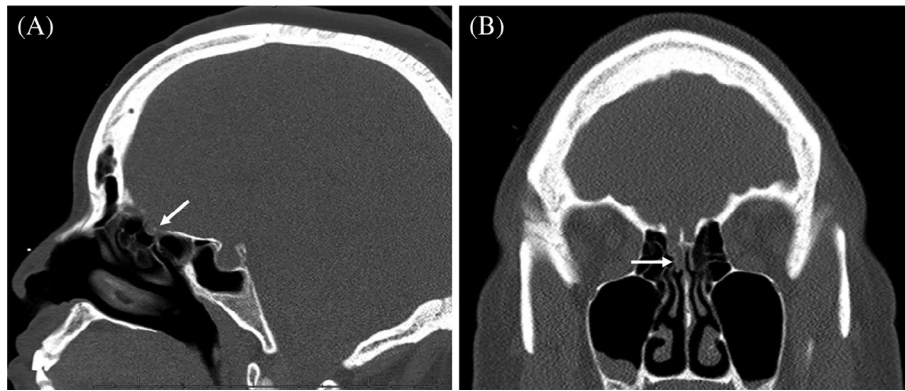


Fig. 1. Computed tomography scan without contrast in the (A) sagittal plane and (B) coronal plane demonstrating the defect in the right cribriform plate (arrows).

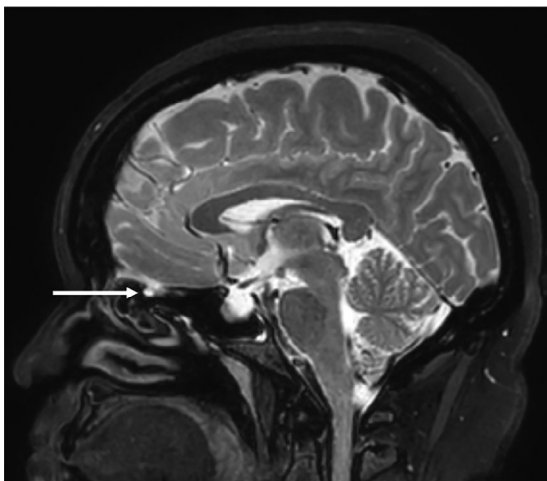


Fig. 2. T2-weighted magnetic resonance imaging brain in the sagittal plane demonstrating encephalocele projecting from the right olfactory fossa (arrow).

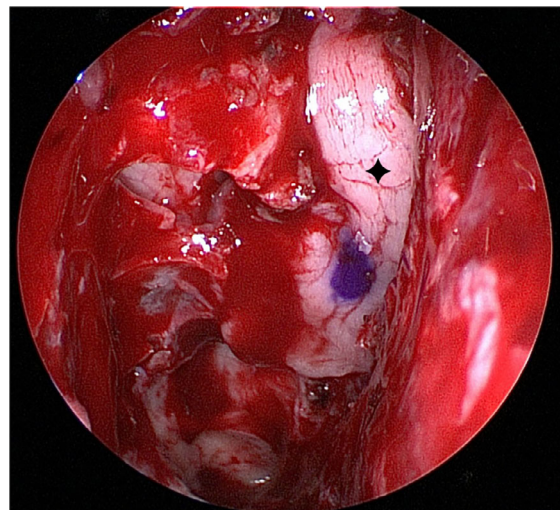


Fig. 4. Intraoperative endoscopic view of the right nasal cavity following reduction of the encephalocele with the free mucosal graft over the defect (◆). [Color figure can be viewed in the online issue, which is available at [www.laryngoscope.com](http://www.laryngoscope.com).]

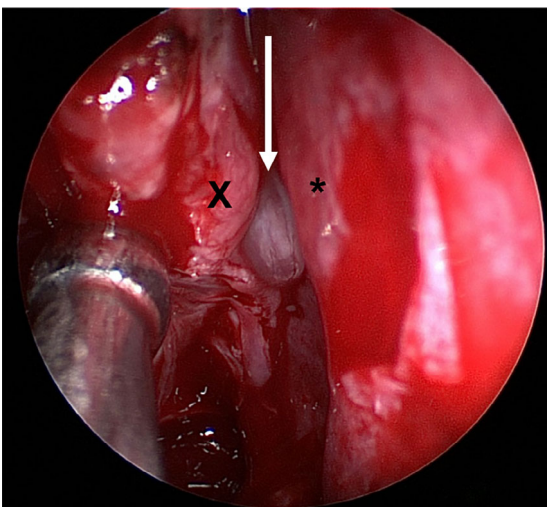


Fig. 3. Intraoperative endoscopic view of the right nasal cavity with the encephalocele visualized between the cribriform and ethmoid roof (arrow) protruding between the nasal septum (\*) and remnant middle turbinate (X). [Color figure can be viewed in the online issue, which is available at [www.laryngoscope.com](http://www.laryngoscope.com).]

## DISCUSSION

Based on review of the current literature, this is the second report of an iatrogenic CSF leak following a nasal swab. The previously reported case involved a patient with a previously undiagnosed skull base defect that was evident on imaging prior to the swab.<sup>3</sup> In that case, it was theorized that the swab itself did not result in violation of the bony skull base but rather caused trauma to the patient's pre-existing encephalocele. In the case we report here, however, there was no radiographic or visual evidence of an existing encephalocele prior to the nasal swab.

The use of the NP swab has increased significantly since the beginning of the COVID-19 pandemic. The NP swab has been utilized in the past, typically by experienced caregivers on hospitalized patients, to diagnose viral upper respiratory infections, but with the current public health strategy based on early detection and isolation, the test has been deployed on a massive scale. A recent large cohort study demonstrated the NP swab to be generally safe with

rare associated adverse events.<sup>4</sup> The possibility of adverse events, however, cannot be ruled out. These include breakage of the swab into the nose, epistaxis, and CSF leak. The concern for CSF leak is significant, as 10%–25% of patients with traumatic CSF leaks will develop meningitis.<sup>5</sup>

## CONCLUSION

CSF leak should be considered in patients with watery rhinorrhea or salty or metallic taste postnasal drip following an NP swab. This case highlights the need for education of proper NP swab technique for healthcare providers and education of the signs and symptoms of CSF rhinorrhea for patients. Furthermore, alternate testing methods should be considered in patients with known distortions in nasal or skull base anatomy, history of

sinus or skull base surgery, or conditions that may predispose the patient to skull base erosion.<sup>3</sup>

## BIBLIOGRAPHY

1. WHO Coronavirus Disease (COVID-19) Dashboard: World Health Organization; 2021 [updated 1/17/2021]. Available at: <https://covid19.who.int/>. Accessed January 19, 2021.
2. Interim Guidelines for Collecting, Handling, and Testing Clinical Specimens for COVID-19: National Center for Immunization and Respiratory Diseases (NCIRD), Division of Viral Diseases; 2021 [updated January 6, 2021]. Available at: <https://www.cdc.gov/coronavirus/2019-ncov/lab/guidelines-clinical-specimens.html>. Accessed January 19, 2021.
3. Sullivan CB, Schwalje AT, Jensen M, et al. Cerebrospinal Fluid Leak After Nasal Swab Testing for Coronavirus Disease 2019. *JAMA Otolaryngol Head Neck Surg* 2020;146:1179–1181.
4. Foh B, Borsche M, Balck A, et al. Complications of nasal and pharyngeal swabs—a relevant challenge of the COVID-19 pandemic? *Eur Respir J*. 2020.
5. Mourad M, Inman JC, Chan DM, Ducic Y. Contemporary trends in the management of posttraumatic cerebrospinal fluid leaks. *Craniofacial Trauma Reconstr* 2018;11:71–77.