



Case illustrated

***Fusarium* rhinosinusitis post chimeric antigen receptor T-cell therapy**

Supavit Chesdachai^{a,*}, Natalia E. Castillo Almeida^a, Isin Y. Comba^a, Prasuna Muppa^b,
Matthew J. Thoendel^{a,**}

^a Division of Infectious Diseases, Department of Medicine, Mayo Clinic, Rochester, MN, USA

^b Department of Laboratory Medicine and Pathology, Mayo Clinic, Rochester, MN, USA

ARTICLE INFO

Article history:

Received 15 February 2021

Received in revised form 21 March 2021

Accepted 22 March 2021

Keywords:

Chimeric antigen receptor

Neutropenia

Invasive fungal rhinosinusitis

Fusarium

ABSTRACT

Chimeric antigen receptor T-cell (CAR-T) therapy is a novel treatment for various types of hematologic malignancy. We presented a case of refractory diffuse large B cell lymphoma patient who developed acute invasive fungal rhinosinusitis (AIFR) from *Fusarium* species after CAR-T therapy. Our photos illustrated the classic clinical, endoscopic, and histopathologic findings of AIFR.

© 2021 The Author(s). Published by Elsevier Ltd. This is an open access article under the CC BY-NC-ND license (<http://creativecommons.org/licenses/by-nc-nd/4.0/>).

Case illustrated

A 64-year-old male with a history of refractory diffuse large B cell lymphoma presented with a two-week history of new hard palate lesion and epistaxis. One month before presentation, he underwent chimeric antigen receptor T cell (CAR-T) therapy after failing salvage chemotherapy regimens. Post-CAR-T, he required tocilizumab and high dose steroid for cytokine release and hemophagocytic lymphohistiocytosis syndrome. Antifungal prophylaxis was fluconazole. Physical examination revealed a left circular lesion at the hard palate (Fig. 1) with signs of inflammation. Computed Tomography scan demonstrated a dense material at the right nasal cavity extending into the ethmoid sinuses and maxillary sinus. Subsequently, nasal endoscopy revealed black necrotic area at the middle turbinate (Fig. 2). Biopsies from left hard palate and nasal cavity lesions were obtained (Fig. 3). The diagnosis of acute invasive fungal rhinosinusitis from *Fusarium* species was made. The patient underwent extensive surgical resection, in addition to liposomal amphotericin B and voriconazole.

Acute invasive fungal rhinosinusitis (AIFR) is a life-threatening condition. In patients with hematologic malignancies, the severity of neutropenia confers additional risk to develop AIFR [1]. Despite a higher risk of AIFR with chemotherapy and steroids, CAR-T therapy is not typically associated with invasive fungal infections [2]. Our patient had prolonged and severe neutropenia due to chemotherapy. AIFR diagnosis depends on radiographic and

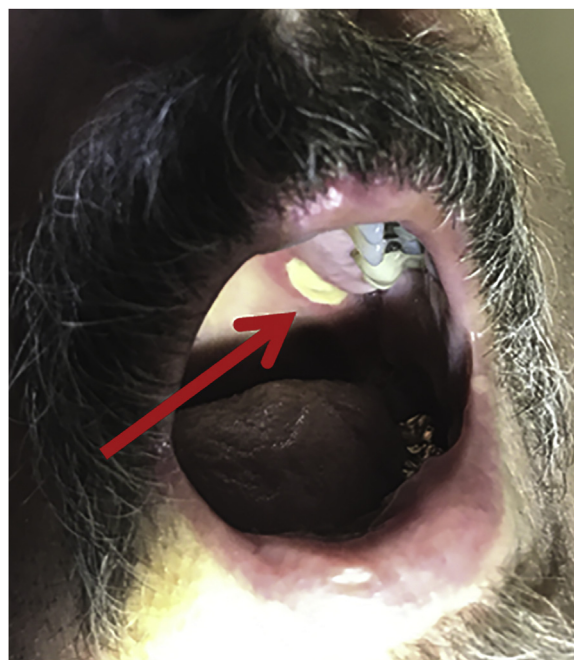


Fig. 1. Physical examination illustrated a white, one-centimeter circular lesion of the left hard palate.

* Corresponding author at: Division of Infectious Diseases, Department of Medicine, 200 First Street SW, Rochester, MN, 55905, USA.

** Corresponding author at: Division of Infectious Diseases, Department of Medicine, 200 First Street SW, Rochester, MN, 55905, USA.

E-mail addresses: chesdachai.supavit@mayo.edu (S. Chesdachai), thoendel.matthew@mayo.edu (M.J. Thoendel).

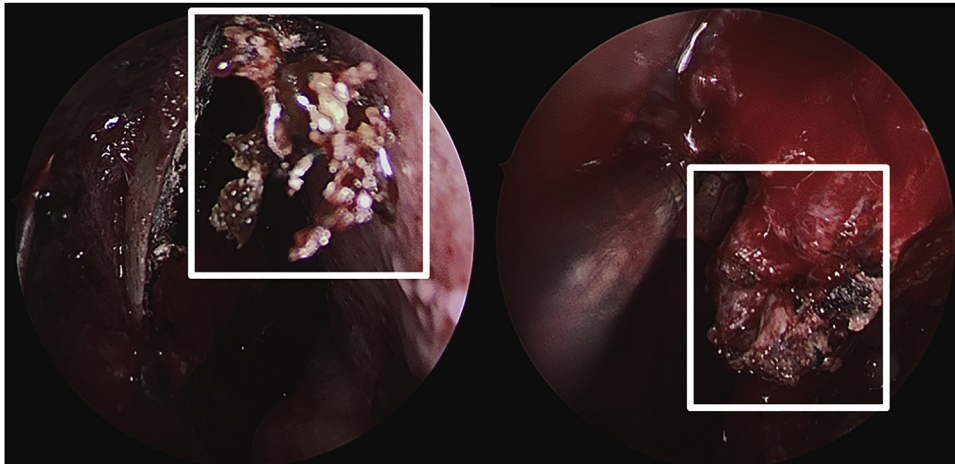


Fig. 2. Nasal endoscopy revealed black/gray necrotic appearing tissue at the head of the middle turbinate.

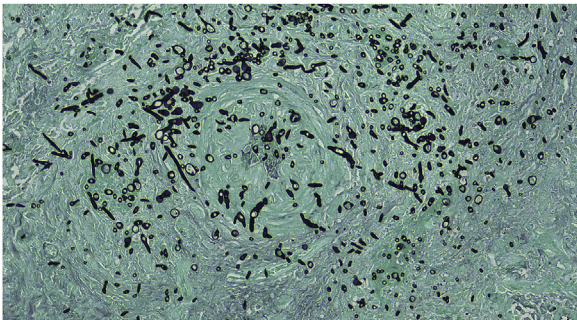


Fig. 3. Pathology of nasal cavity lesion with Grocott's methenamine silver (GMS) stain illustrated a filamentous fungus invading blood vessels.

histopathologic evidence of invasive fungal infection [3]. In a patient with high clinical suspicion for AIFR, a nasal endoscopy with biopsy should be pursued urgently. The most common causative fungal species of AIFR are *Aspergillus*, *Fusarium*, and *Mucorales* [4]. Surgery is critical for AIFR management and may provide the best survival outcomes [5]. Initial therapy consists of liposomal amphotericin B and voriconazole while awaiting susceptibilities. For immunocompromised patients, neutrophil recovery and immunosuppression reduction are also crucial for clinical recovery. Treatment duration is based mainly on host characteristics, clinical improvement, and extent of surgical resection.

Funding

The authors received no financial support for the publication of this article.

Consent

The authors have the patient's written consent for the publication of this case.

CRedit authorship contribution statement

Supavit Chesdachai: Conceptualization, Methodology, Data curation, Writing - original draft, Writing - review & editing, Project administration. **Natalia E. Castillo Almeida:** Conceptualization, Data curation, Writing - original draft, Writing - review & editing. **Isin Y. Comba:** Methodology, Data curation, Writing - review & editing. **Prasuna Muppa:** Data curation, Visualization, Writing - review & editing. **Matthew J. Thoendel:** Conceptualization, Methodology, Data curation, Writing - original draft, Writing - review & editing, Project administration, Supervision.

Declaration of Competing Interest

The authors report no declarations of interest.

References

- [1] Walsh TJ, Gamaletsou MN. Treatment of fungal disease in the setting of neutropenia. *Hematology Am Soc Hematol Educ Program* 2013;2013(1):423–7.
- [2] Wudhikarn K, Palomba ML, Pennisi M, et al. Infection during the first year in patients treated with CD19 CAR T cells for diffuse large B cell lymphoma. *Blood Cancer J* 2020;10(8):79.
- [3] deShazo RD, O'Brien M, Chapin K, Soto-Aguilar M, Gardner L, Swain R. A new classification and diagnostic criteria for invasive fungal sinusitis. *Arch Otolaryngol Head Neck Surg* 1997;123(11):1181–8.
- [4] Chang C, Gershwin ME, Thompson GR. Fungal disease of the nose and sinuses: an updated overview. *Curr Allergy Asthma Rep* 2013;13(2):152–61.
- [5] Roxbury CR, Smith DF, Higgins TS, et al. Complete surgical resection and short-term survival in acute invasive fungal rhinosinusitis. *Am J Rhinol Allergy* 2017;31(2):109–16.