

Transperineal prostate biopsy: The modern gold standard to prostate cancer diagnosis

Gernot Ortner^{1,2} , Eirini Tzanaki³ , Bhavan Prasad Rai⁴ , Udo Nagele^{1,2} , Theodoros Tokas^{1,2} 

Cite this article as: Ortner G, Tzanaki E, Rai BR, Nagele U, Tokas T. Transperineal prostate biopsy: The modern gold standard to prostate cancer diagnosis. Turk J Urol 2020; 47(Supp. 1): S19–S26.

ABSTRACT

In patients suspicious for prostate cancer, a prostate biopsy should be performed. Biopsies are possible either by the transrectal or transperineal routes. Compared with the transrectal prostate biopsy (TRPBx), transperineal prostate biopsy (TPPBx) offers a non-inferior cancer detection rate (CDR), especially in patients undergoing re-biopsy for persistently elevated PSA and in cases of active surveillance (AS), in which TPPBx seems to be superior. Moreover, the transperineal route achieves superior sampling of the anterior and apical regions, especially after previous multiple negative TRPBx. Infectious complications are nullified due to avoidance of needle passage through the rectal mucosa, and there is a highly significant evidence of reduced fever and sepsis rates when compared with TRPBx, with maintaining acceptable urinary retention rates. This is an important upcoming topic due to the increasing antibiotic resistance rates, thus reducing peri-interventional hospitalization and health care costs. To date, TPPBx is perfectly feasible in the inpatient and out-patient settings and under local anesthesia, characterized by a moderate learning curve and a good reproducibility. By applying mpMRI as a diagnostic tool, clinically significant prostate cancer (csPCa) detection seems to be comparable to transrectal MRI-fusion biopsy (TR-MRIFBx). Finally, focal treatment of localized disease is currently performed exclusively through a TP approach.

Keywords: Prostate biopsy; prostate cancer; transperineal; transrectal.

Introduction

Prostate cancer (PCa) is currently the most frequent cancer in males in Europe and the US.^[1,2] The strong increase in overall PCa detection rate (CDR) mainly relies on the introduction of the PSA screening and consequent biopsies in asymptomatic men.^[1] Nevertheless, this diagnostic strategy maintains a risk of indolent tumor detection and the consequent overtreatment, which exposes patients to a potential morbidity of treatment without benefit.^[2] Since Hodge et al.^[3] introduced the concept of random prostate sampling, various biopsy schemes have been developed to increase the diagnostic accuracy. The current standard includes a transrectal ultrasound-guided biopsy (TRPBx) with a periprostatic block, followed by a random sampling of the prostate with 10–12 biopsy cores.^[4] Nevertheless, since its introduction, the transperineal (TP) approach has been also widely accepted.^[5] To date, the debate of superiority of one method over the

other remains open. Potential drawback of the transrectal approach includes the increased febrile postprocedural urinary tract infections (UTIs). In contrast, transperineal ultrasound-guided prostate biopsies (TPPBx) have been linked to increased postprocedural urinary retention rates, appear to be more invasive than TRPBx and cannot easily be delivered in an outpatient setting, as they often need general anesthesia or sedation. However, due to increased UTI rates with multiresistant bacteria, research interest has been shifted toward further development and distribution of the TP approach in the urological community. This narrative review collects currently available data on important factors to consider, as infection rates, type of anesthesia, deliverability in an outpatient setting, and PCa detection rates, also according to tumor location. Our aim is to provide an overview of benefits and drawbacks and present the current position of TPPBx, as well as its future perspectives in a urologist's everyday clinical praxis.

¹Department of Urology and Andrology, General Hospital Hall i.T., Hall in Tirol, Austria
²Training and Research in Urological Surgery and Technology (T.R.U.S.T.)–Group
³University of Pavia, Medical School, Harvey Course, Pavia, Italy
⁴Department of Urology, Freeman Hospital, Newcastle, UK

Submitted:
07.08.2020

Accepted:
31.08.2020

Available Online Date:
09.10.2020

Corresponding Author:
Theodoros Tokas
E-mail:
ttokas@yahoo.com

©Copyright 2021 by Turkish Association of Urology

Available online at
www.turkishjournalofurology.com

PCa and clinically significant prostate cancer (csPCa) detection rates in biopsy-naive patients

The first prospective report comparing systematic TPPBx to TRPBx 6-core biopsy demonstrated more detected tumors with the transperineal approach (95% versus 79%, $p=0.012$).^[5] Nevertheless, a recent metaanalysis of 13 studies could not find statistically significant differences in CDRs, though it must be stated that the patient collective biopsy cores (sextant, extensive, saturation, and mixed) and study design was varying between included studies.^[6] Finally, in a recent large retrospective work of 1,287 men undergoing TPPBx under local anesthesia, a significantly higher CDR compared with the published TRPBx rates, reaching 50%, was demonstrated. In the same study, of 641 patients diagnosed with PCa, grade group 1 cancer was reported in 256 (39.9%), whereas csPCa in 385 (60.1%) of patients.^[7] Therefore, by taking current research into account, in terms of CDRs, there are no significant differences between TR and TP systematic biopsies in biopsy-naive patients.

Negative prior biopsies and active surveillance (AS)

Before the introduction of MRI-fusion biopsies, saturation TPBx has been frequently utilized after negative TRPBx and persistent PCa suspicion. Reported CDRs vary between 50-68%, depending on the number of cores taken and the number of prior negative biopsy sessions.^[8-11] Dimmen et al.^[8] presented a CDR of 55% in patients with prior mean 2.42 TRBxs. Of them, 53% had a Gleason score $\geq 3+4=7$. Similar results were published by Gershman et al.^[9] with a CDR of 50% (mean of 24.8 ± 7.8 cores) in patients with mean 3.7 (range 2-8) prior TRPBx. Taira et al.^[12] demonstrated a CDR of 75.9%, 55.5%, 41.7%, and 34.4% by using a template-guided mapping TPPBx approach for initial biopsy, and after 1, 2, and ≥ 3 prior negative biopsies, respectively. The detection rate of insignificant cancers was low (11.1%). Higher overall CDR of 68% by using a 36-core template-guided TPPBx approach in patients with two negative previous TRPBx

has also been reported.^[10] Finally, in a comparative study by Altok et al.^[13], overall CDR for PCa was 55% for TRPBx, and 69% for TPPBx ($p<0.001$). A much higher detection rate of csPCa was also reached in the TPPBx (34%) group when compared with the TRPBx group (16%) ($p<0.001$). In patients with prior negative TRPBx PCa was detected in 31% and 56% of patients, and csPCa in 15 and 34% in TRPBx and TPPBx, respectively. In general, saturation biopsy with the transperineal technique, detects an additional 38% of PCa. The rate of urinary retention (10%) is a drawback.^[14]

In patients on AS, csPCa has been detected in 16 and 33% in TRPBx and TPPBx, respectively ($p<0.001$).^[13] Moreover, higher upgrading rates for patients on AS were found in two other studies.^[11,15] Ayres et al.^[15] reported that 34% of patients had more significant prostate cancer on restaging TPPBx. In total, 74% of those patients with more significant disease opted for radical treatment after temporary AS. Finally, Taira et al.^[11] published an upgrading rate of 71.9% to csPCa by using a template-guided mapping TPPBx.

Anterior lesion detection rates

In a large representative study of patients undergoing primary TPPBx, the anterior zone involvement for PCa was seen in 52.7% of the cases. Interestingly, an exclusively anterior PCa was reported in 9.7% of which 4.7% were diagnosed with csPCa.^[7] The difficulty of diagnosing anterior zone PCa with TRPBx was clearly demonstrated by Bott et al.^[16] Significantly, more biopsy sessions ($p=0.007$) were required for diagnosis, and the number of positive cores as well as length of cores was significantly lower and shorter ($p=0.001$, $p=0.002$) when compared with posterior tumors.

The transperineal approach seems to achieve better CDRs for anterior lesions due to the direct anatomic access through the perineal skin. This was shown in numerous studies, including patients with prior negative TRPBx.^[8,10-12,15,17] The anterior PCa in the repeat-biopsy setting was reported in 44%^[10], 59.2%^[17], 83.3%^[18] and even 94.1%.^[9] As the number of prior biopsies increased, Taira et al.^[12] showed that only the most anterior (especially the antero-apical region) regions continued to harbor prior undetected Gleason ≥ 6 PCa. Finally, Gershman et al.^[9] published a 47% of Gleason $\geq 3+4=7$ cancer in the anterior zone which emphasizes the role of TPPBx in the repeat-biopsy setting.

Of note, after the anatomical mapping of positive cores following a template-guided saturation TPPBx in patients with an average of 2.1 negative prior TRPBx, and an overall CDR of 42.2% (43/102 patients), Merrick et al.^[17] could show that only 53.4% and 76.7% of cancers would have been diagnosed after a sextant or 12-core biopsy scheme. In this cohort, the anterior lateral, an-

Main Points:

- Transperineal prostate biopsy achieves comparable cancer detection rates with transrectal prostate biopsy in biopsy-naive patients but is superior in cases of prior transrectal biopsies and active surveillance.
- Transperineal biopsy offers a superior access to the anterior and apical prostate regions.
- Infectious complications are nullified with the transperineal method.
- Transperineal biopsy can also be performed with local anesthesia, is feasible in an outpatient setting, has a moderate learning curve and a good reproducibility.
- Multiparametric MRI augments the function of transperineal prostate biopsy and focal therapy can be easily applied transperineally.

terior apical, and transitional zone counted for 59.2% of all positive cores. Finally, Mabeesh et al.^[18] published a CDR of 26% after ≥ 2 negative TRPBx sets with a multiple core (median 30) template-guided TPPBx approach. Of them, 83.3% were in the anterior zone and more positive cores ($p=0.015$) were found in the anterior (4.9) compared with the posterior zone (1.5). Gleason score 6, 7, and ≥ 8 tumors were present in 54%, 25%, and 21% of the patients, respectively.

Complication-infection rates (Table 1)

Postprocedural complications for both techniques are usually self-limiting.^[19,20] Pain (43.6%), fever (17.5%), hematuria (65.8%), hematochezia (36.8%), and hemospermia (92.6%) have been reported within 35 days after TRPBx.^[21] Additionally, LUTS occur in up to 25%, but urinary retention is very rare ($<2\%$).^[19] However, infection-related events play a major role after TRPBx.^[19,22-25] In the era of inappropriate antibiotic treatment there is an increase of febrile postprocedural UTIs ranging 4.2%–17.5% and 0.8%–6.3% needing hospital re-admission.^[19,24] Infection-related admissions rates have increased from 0.6% in 1996 to 3.6% in 2005.^[26] *E. coli*, *Pseudomonas*, and *Klebsiella* are the common pathogens in blood cultures with 91.2%, 5.8%, and 2.9%, respectively.^[24] Additionally, quinolone-resistant bacteria occupy the rectal flora of 20%–50% of the patients and their presence has been associated with increased post-biopsy infection (6.6% versus 1.6%) and hospital admission rates (4.4% versus 0.9%).^[22] By considering its additional side effects, the European Association of Urology stopped recommending Ciprofloxacin as chemoprophylaxis for TRPBx. Alternative treatments include Fosfomycin^[27] and Carbapenem.^[28] Typical hospital admissions occur in the first 2 weeks after biopsy.^[24,27] The calculated risk for post TRPBx-bacteremia is as low as 1.5%, but patients with TRPBx related bacteremia are twice as likely to require intensive care treatment and significantly higher rates of multi-resistance are recorded.^[25]

Table 1. Reported complication rates

	TRPBx	TPPBx
LUTS	25% [21]	25% [20]
Fever due to UTIs	17.5% [21]	$<1\%$ [7, 29, 30]
Sepsis	1.5% [21]	$<0.5\%$ [31]
Infection-related Hospitalization	3.6% [26]	$<0.5\%$ [32]
Hematuria	65.8% [21]	$<10\%$ [29]
Hematochezia	36.8% [21]	$<10\%$ [29]
Hemospermia	92.6% [21]	$<10\%$ [29]
Urinary retention	$<2\%$ [19]	$<5 - 11.1\%$ [29, 31]

LUTS: lower urinary tract symptoms UTIs Urinary tract infections; TRPBx: Transrectal prostate biopsies; TPPBx: Transperineal prostate biopsies

The transperineal method is a safe way to reduce infection rates as rectal bacteria prostatic inoculation is avoided, due to the easy disinfection of perineal skin and the avoidance of passing the biopsy needle through the rectal mucosa. Infectious related events after TPPBx are below 1%^[7,29,30], sepsis rates do not exceed 0.5%^[31], and hospital re-admissions are uncommon.^[32] Antibiotic needs are minimal, and even ‘‘antibiotic-free’’ approaches appear to be harmless.^[33] In contrast, postprocedural urinary retention often complicated the TPPBx setting during the early years, mainly due to the higher number of cores with consecutive prostate swelling.^[29] Rates of up to 11.1%^[29] have been reported, but usually remain below 5%.^[31] Patients experience uncomplicated LUTS in about 25% of cases.^[20] Side effects, but not admission and emergency department visit rates are directly correlated to the number of cores taken.^[29] Nonetheless, with the introduction of MRI-fusion biopsy and the consequent reduction of biopsy cores, urinary retention rates have been significantly decreased and recent studies even published rates below 2%.^[7,30,32] Finally, hemospermia and hematuria occur in $<10\%$ of the cases and their incidence decreases dramatically when taking <12 cores.^[29]

Patient discomfort, need for anesthesia, deliverability in an outpatient setting

Patient satisfaction constitutes an important factor during and after biopsy. Interestingly, 11% of patients undergoing TRPBx report that a further biopsy would be considered a major or moderate problem. One week after biopsy this proportion increases to 20%. This negative feedback has been linked to unfavorable intraprocedural experience, mainly due to pain and bleeding.^[21] Since its introduction, TPPBx has been handicapped by the need of general anesthesia and hospital admission in most of the cases.^[17] Nevertheless, there have been a lot of efforts to optimize pain levels by using local anesthetics and minimizing perineal punctures.^[7,33-36]

The importance of a guidance needle was highlighted by an early report by Novella et al.^[36] During a 14-core TPPBx under local anesthesia, the authors found no difference in pain levels during probe insertion, transrectal ultrasonography, and execution of local anesthesia. However, pain scores during prostate sampling were significantly lower when a coaxial needle was used, due to reduced perineal punctures. Regarding the type of local anesthesia, when applied into the periapical triangle (anatomical triangle formed by the levator ani, rhabdosphincter, and external anal sphincter) via a midline perineal puncture, researchers found no significant differences in pain scores when compared with 12-core TRPBx.^[35] However, by adding a transrectal digitally guided bilateral pudendal block to the bilateral periprostatic block, others could demonstrate a superior overall pain control. About 30 procedures were needed to be performed to reach an expertise level.^[34] Furthermore, a combination of oral analgesics one hour before biopsy with a periprostatic transperineal block can achieve minimum pain levels, and 90% of patients are satisfied

and would recommend the procedure to others.^[32] By optimizing local anesthesia, decreasing procedure times, and gaining experience, an in-office TPPBx has become a feasible option with complications <5%.^[33] An optimal setting would include a local anesthesia with a bilateral periprostatic transperineal block and a minimum of 10 cores, including the anterior zone with the free-hand technique, and access over bilateral cannulas.^[7] In this setting, from patients who had experienced prior TRPBx, 67% said there was comparable discomfort, while 18% considered TPPBx and 11% considered TRPBx to be more painful.^[7] In another study by Gorin et al.^[37] of patients who had experienced TRPBx, 45% reported a preference for TPPBx, while 38% reported no preference. Lidocaine injection appears to be the most painful part (47.4% of patients), followed by the biopsy needle passage (42.1%) and ultrasound probe insertion (10.5%).

In the era of MRI and MRI/ultrasound fusion-guided prostate biopsy (Figures 1 and 2)

Conventional TRPBx are limited due to the related random and systematic errors, as the sampling of cancerous areas is linked to

chance. Systematic TRPBx misses about 20% of csPCa, mainly located in the anterior and apical gland. Thus, underdiagnosis and eventually undertreatment is the consequence.^[38] Since the introduction of MRI-TBx, the paradigm of prostate biopsy strategies in men with risk for PCa, or in patients with already diagnosed low-risk PCa undergoing AS, is shifting. The diagnostic efficacy of multiparametric MRI (mpMRI) was recently assessed in the PROMIS trial, a prospective multicenter paired-cohort validation study comparing mpMRI added and gray-scale TRPBx by using a mapping TPPBx in 570 men. A significantly higher sensitivity of mpMRI addition (93% versus. 48%) and NPV (89% versus. 74%) for the prevalence of csPCa was shown. By using mpMRI as a triage test, 25% of men might safely avoid prostate biopsy, and therefore, overdiagnosis of clinically insignificant cancer might be reduced.^[39,40] Nevertheless, general consensus has been reached in combining targeted with systemic biopsies to reach the most accurate diagnostic power for detecting csPCa.^[40]

The first study prospectively comparing transrectal MRI-fusion biopsy (TR-MRI-FBx) to transperineal MRI-fusion biopsy

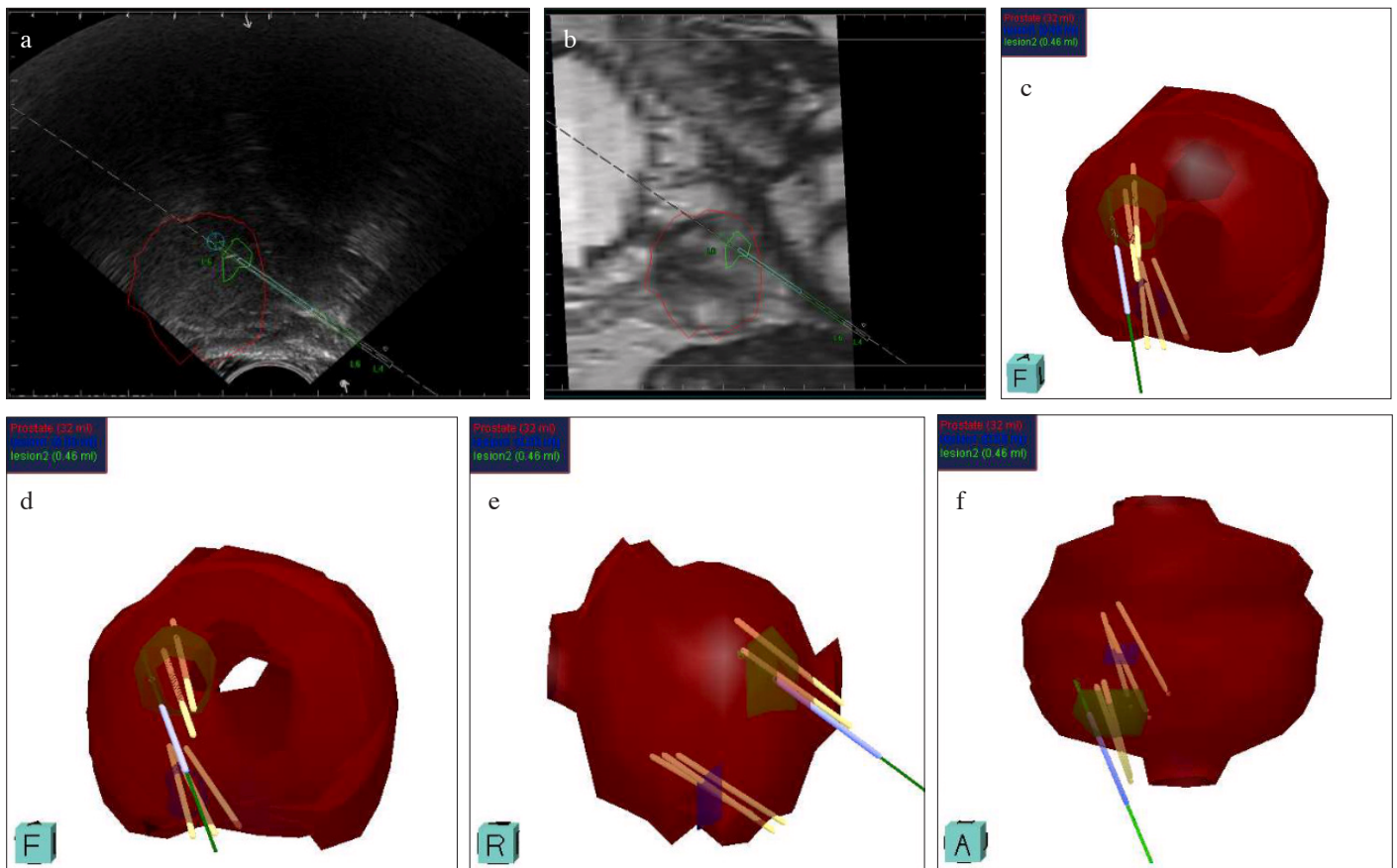


Figure 1. a-f. Transrectal MRI-fusion biopsy (TRT-MRI-FBx). (a) Lateral sonographic view demonstrating the prostate (red contour), suspicious lesion (green contour), needle (L). (b) Lateral MRI view demonstrating the prostate (red contour), suspicious lesion (green contour), needle (L). (c-f) 3D reconstruction in different views demonstrating the prostate (red), suspicious lesions (blue, green), and needle positions

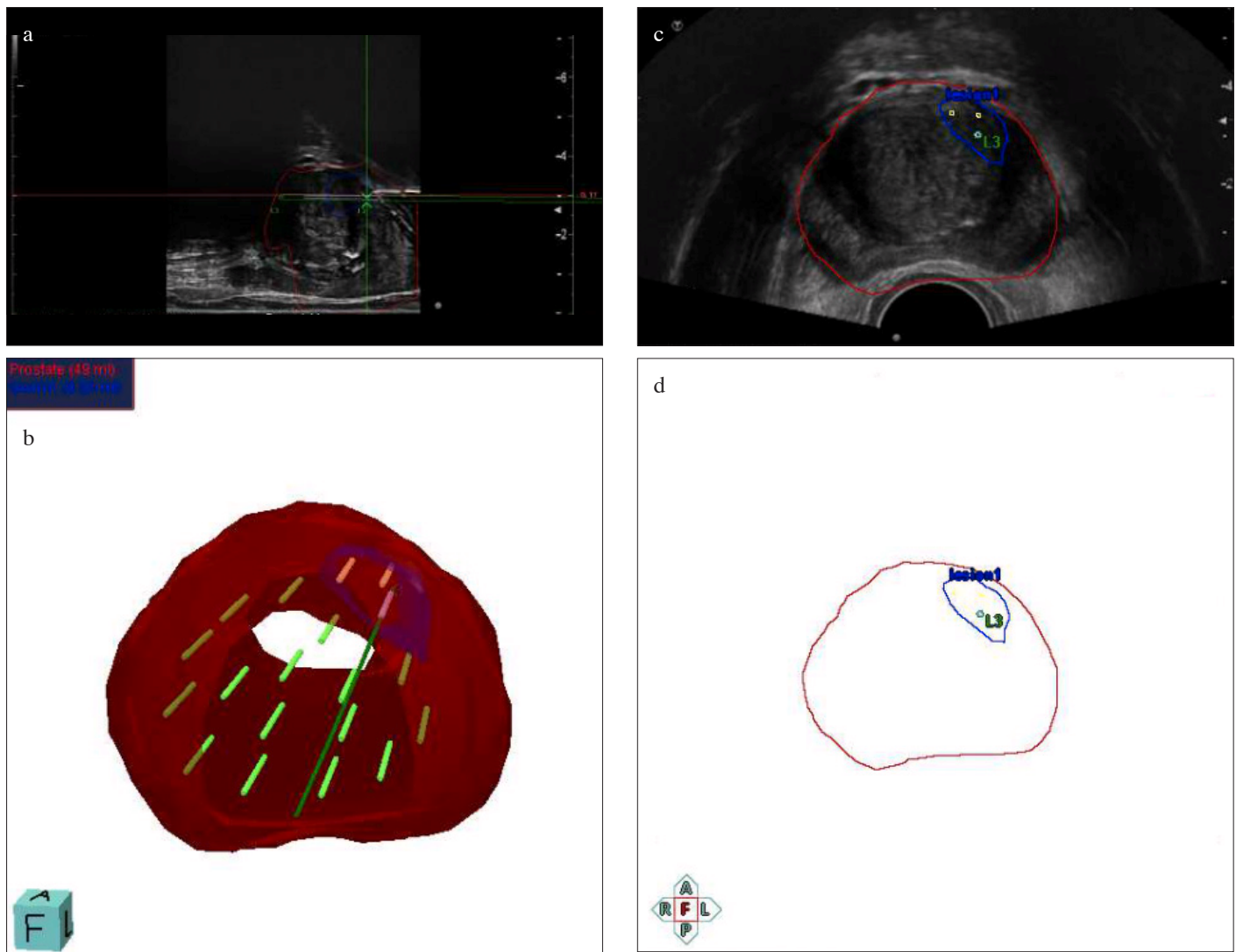


Figure 2. a-d. Transperineal MRI-fusion biopsy (TP-MRI-FBx). (a) Lateral sonographic view demonstrating the prostate (red contour), suspicious lesion (blue contour), needle (L), and template position (Q-17). (b) 3D reconstruction demonstrating the prostate (red), suspicious lesion (blue), and needle positions. (c) Transverse sonographic view demonstrating the prostate (red contour), suspicious lesion (blue contour), targeted biopsy position (3 cores), last targeted biopsy position (L3). (d) Transverse schematic view demonstrating the prostate (red contour), suspicious lesion (blue contour), and the last targeted biopsy position (L3)

(TP-MRI-FBx), each four cores per lesion, in 200 consecutive men demonstrated a greater percentage of csPCa in the anterior zone for the TP approach (93.3% versus 25%, $p=0.0001$). Recorded CDR of csPCa for target lesions was also better with the TP approach (93.3% versus 66.7; $p=0.001$).^[41] Further research showed a significant advantage of TP-MRI-FBx over TR-MRI-FBx in cases of an apical, dorsolateral, or anteriorly located tumor^[42] and some additional evidence from a multivariate analysis suggest TP-MRI-FBx be an independent predictor of csPCa detection along with PSA, rectal exam, prostate volume, PIRADS score, number of targeted biopsy cores, and surgeon experience.^[43] Finally, according to recent data by Halstuch et

al.^[44] these advantages of TP-MRI-FBx may be transferred in patients with prior negative biopsies or undergoing AS protocols. These parameters have led to an increased interest in the TP-MRI-FBx approach, and several MRI-fusion platforms have implemented the TP access in their diagnostic options.^[45] Hence, TP-MRI-FBx s are rapidly increasing worldwide.

Learning curves, reproducibility, and costs

A first definition for terms, processes as well as a minimum dataset in relation to TPPBx was made in 2013 by the Ginsburg consensus panel.^[46] The members agreed on a reproducible surgical sampling pattern depending on the size and length

of the prostate (between 24-38 cores). Mantica et al.^[47] recently introduced a five-step training model for TPPBx in inexperienced residents. By comparing the fan-technique to a free-hand biopsy, a high and comparable overall cancer detection rate of 58.2% versus 59.2% was demonstrated. The free-hand technique (81.8%) was superior to the fan-technique (45%) regarding CDRs in small prostates (<40cc) and could be performed faster (14.4 versus 15.9 minutes, $p=0.025$).^[47] Similar procedure times of 10-12 minutes were described in another large study.^[7] Halstuch et al.^[44] demonstrated that proficiency and accuracy can be achieved after 110 TRPBx and 125 TP-MRI-FBx. Procedure times decrease from 45 min to 15 min in the TR group and 55 min to 18 min in the TP group. Nonetheless, procedure times of TPPBx can be significantly reduced if patients receive local instead of general anesthesia. Cancer detection in PIRADS 3 lesions increased from 35 to 50% and 40 to 55% in TRPBx and TPPBx group, respectively.

Comparing costs of four alternative biopsy procedures to reference standard TRPBx, Altok et al.^[13] published a significant increase of x1.9 (90%), x2.5 (153%), x2.5 (150%), and x2.2 (125%) for sedation TRPBx, TPPBx with a template under general anesthesia, sedation TR-MRI-FBx and sedation in-bore MRI biopsy, respectively. Also, the main factor for increased costs was the admission of general anesthesia. If modalities would have been performed under local anesthesia, a lowered cost increase of x1.7 (66%) for TPPBx, x1.7 (68%) for fusion biopsy without MRI and x2.4 (140%) for fusion biopsy including MRI was calculated. The cost of detecting one significant cancer in TRPBx, TR-MRI-FBx and TPPBx was 8,809 \$, 10,590 \$ and 9,782 \$, respectively. If TPPBx and TR-MRI-FBx were performed under local anesthesia, costs would decrease to 6,940 \$ for TPPBx and 6,571 \$ for TR-MRI-FBx and would be lower compared with conventional TRPBx.

New perspectives (application of focal therapy of PCa)

Since 2010, there has been an upcoming interest for localized treatment for low-risk PCa by applying numerous techniques (cryotherapy, high-intensity focused ultrasound [HIFU], laser ablation, photodynamic therapy). Energy has been traditionally applied with a template-guided approach through the perineum. Before the area of mpMRI, mapping TPPBx was defined as the gold standard.^[48,49] With a 5 mm-sampling frame, researchers could identify foci measuring 2-5 mm with a certainty of 90%.^[50] The superiority of a 3D transperineal mapping TPPBx was also highlighted in a later report, in which 55% of the patient population initially diagnosed with unilateral cancer on TRPBx was upgraded to a higher Gleason score or upstaged to a bilateral cancer in 23% of the cases taking, however, a median number of 46±19 cores.^[48] Additionally, robotic systems with live intraoperative motion prostate tracking are able to minimize in vivo movements and reach moving with a median accuracy of

2.73mm and a median prostate motion of 5.46 mm.^[51] Finally, the feasibility of real-time MRI guided focal laser treatment of low-risk PCa has been demonstrated using a template-guided TP approach.^[52]

In conclusion, the transperineal approach for prostate biopsy offers superior features when compared with TRPBx and is a feasible procedure in the inpatient and outpatient setting. Multiparametric MRI offers an additional advantage to the transperineal approach. Nevertheless, prospective studies directly comparing TRPBx and TPPBx with mpMRI targeted biopsies are needed to proof superiority of either concept.

Peer-review: This manuscript was prepared by the invitation of the Editorial Board and its scientific evaluation was carried out by the Editorial Board.

Author Contributions: Concept – T.T.; Design – T.T.; Supervision – T.T.; Materials – E.T., G.O.; Data Collection and/or Processing – E.T., G.O.; Analysis and/or Interpretation – B.P.R., U.N.; Literature Search – E.T., G.O.; Writing Manuscript – G.O.; Critical Review – U.N., B.P.R.

Conflict of Interest: The authors have no conflicts of interest to declare.

Financial Disclosure: The authors declared that this study has received no financial support.

References

1. Arnold M, Karim-Kos HE, Coebergh JW, Byrnes G, Antilla A, Ferlay J, et al. Recent trends in incidence of five common cancers in 26 European countries since 1988: Analysis of the European Cancer Observatory. *Eur J Cancer* 2015;51:1164-87. [[Crossref](#)]
2. Carroll PR, Parsons JK, Andriole G, Bahnson RR, Barocas DA, Castle EP, et al. NCCN Clinical Practice Guidelines Prostate Cancer Early Detection, Version 2.2015. *J Natl Compr Canc Netw* 2015;13:1534-61. [[Crossref](#)]
3. Hodge KK, McNeal JE, Terris MK, Stamey TA. Random systematic versus directed ultrasound guided transectal core biopsies of the prostate. *J Urol* 1989;142:71-75. [[Crossref](#)]
4. Mottet N, Bellmunt J, Bolla M, Briers E, Cumberbatch MG, De Santis M, et al. EAU-ESTRO-SIOG Guidelines on Prostate Cancer. Part 1: Screening, Diagnosis, and Local Treatment with Curative Intent. *Eur Urol* 2017;71:618-29. [[Crossref](#)]
5. Emiliozzi P, Corsetti A, Tassi B, Federico G, Martini M, Pansadoro V. Best approach for prostate cancer detection: a prospective study on transperineal versus transrectal six-core prostate biopsy. *Urology* 2003;61:961-6. [[Crossref](#)]
6. Xue J, Qin Z, Cai H, Zhang C, Li X, Xu W, et al. Comparison between transrectal and transperineal prostate biopsy for detection of prostate cancer: a meta-analysis and trial sequential analysis. *Oncotarget* 2017;8:23322-36. [[Crossref](#)]
7. Stefanova V, Buckley R, Flax S, Spevack L, Hajek D, Tunis A, et al. Transperineal Prostate Biopsies Using Local Anesthesia:

- Experience with 1,287 Patients. Prostate Cancer Detection Rate, Complications and Patient Tolerability. *J Urol* 2019;201:1121-6. [\[Crossref\]](#)
8. Dimmen M, Vlatkovic L, Hole KH, Nesland JM, Brennhovd B, Axcrona K. Transperineal prostate biopsy detects significant cancer in patients with elevated prostate-specific antigen (PSA) levels and previous negative transrectal biopsies. *BJU Int* 2012;110:E69-75. [\[Crossref\]](#)
 9. Gershman B, Zietman AL, Feldman AS, McDougal WS. Transperineal template-guided prostate biopsy for patients with persistently elevated PSA and multiple prior negative biopsies. *Urol Oncol* 2013;31:1093-7. [\[Crossref\]](#)
 10. Pal RP, Elmussareh M, Chanawani M, Khan MA. The role of a standardized 36 core template-assisted transperineal prostate biopsy technique in patients with previously negative transrectal ultrasonography-guided prostate biopsies. *BJU Int* 2012;109:367-71. [\[Crossref\]](#)
 11. Taira AV, Merrick GS, Bennett A, Andreini H, Taubenslag W, Galbreath RW, et al. Transperineal template-guided mapping biopsy as a staging procedure to select patients best suited for active surveillance. *Am J Clin Oncol* 2013;36:116-20. [\[Crossref\]](#)
 12. Taira AV, Merrick GS, Galbreath RW, Andreini H, Taubenslag W, Curtis R, et al. Performance of transperineal template-guided mapping biopsy in detecting prostate cancer in the initial and repeat biopsy setting. *Prostate Cancer Prostatic Dis* 2010;13:71-7. [\[Crossref\]](#)
 13. Altok M, Kim B, Patel BB, Shih YT, Ward JF, McRae SE, et al. Cost and efficacy comparison of five prostate biopsy modalities: a platform for integrating cost into novel-platform comparative research. *Prostate Cancer Prostatic Dis* 2018;21:524-32. [\[Crossref\]](#)
 14. Moran BJ, Bracciorforte MH, Conterato DJ. Re-biopsy of the prostate using a stereotactic transperineal technique. *J Urol* 2006;176:1376-1381. [\[Crossref\]](#)
 15. Ayres BE, Montgomery BS, Barber NJ, Pereira N, Langley SE, Denham P, et al. The role of transperineal template prostate biopsies in restaging men with prostate cancer managed by active surveillance. *BJU Int* 2012;109:1170-6. [\[Crossref\]](#)
 16. Bott SR, Young MP, Kellett MJ, Parkinson MC. Contributors to the UCLHTRPD. Anterior prostate cancer: is it more difficult to diagnose? *BJU Int* 2002;89:886-9. [\[Crossref\]](#)
 17. Merrick GS, Gutman S, Andreini H, Taubenslag W, Lindert DL, Curtis R, et al. Prostate cancer distribution in patients diagnosed by transperineal template-guided saturation biopsy. *Eur Urol* 2007;52:715-23. [\[Crossref\]](#)
 18. Mabjeesh NJ, Lidawi G, Chen J, German L, Matzkin H. High detection rate of significant prostate tumours in anterior zones using transperineal ultrasound-guided template saturation biopsy. *BJU Int* 2012;110:993-7. [\[Crossref\]](#)
 19. Loeb S, Vellekoop A, Ahmed HU, Catto J, Emberton M, Nam R, et al. Systematic review of complications of prostate biopsy. *Eur Urol* 2013;64:876-92. [\[Crossref\]](#)
 20. Borghesi M, Ahmed H, Nam R, Schaeffer E, Schiavina R, Taneja S, et al. Complications After Systematic, Random, and Image-guided Prostate Biopsy. *Eur Urol* 2017;71:353-65. [\[Crossref\]](#)
 21. Rosario DJ, Lane JA, Metcalfe C, Donovan JL, Doble A, Goodwin L, et al. Short term outcomes of prostate biopsy in men tested for cancer by prostate specific antigen: prospective evaluation within ProtecT study. *BMJ* 2012;344:d7894. [\[Crossref\]](#)
 22. Liss MA, Taylor SA, Batura D, Steensels D, Chayakulkeeree M, Soenens C, et al. Fluoroquinolone resistant rectal colonization predicts risk of infectious complications after transrectal prostate biopsy. *J Urol* 2014;192:1673-8. [\[Crossref\]](#)
 23. Liss MA, Ehdai B, Loeb S, Meng MV, Raman JD, Spears V, et al. An Update of the American Urological Association White Paper on the Prevention and Treatment of the More Common Complications Related to Prostate Biopsy. *J Urol* 2017;198:329-34. [\[Crossref\]](#)
 24. Loeb S, van den Heuvel S, Zhu X, Bangma CH, Schroder FH, Roobol MJ. Infectious complications and hospital admissions after prostate biopsy in a European randomized trial. *Eur Urol* 2012;61:1110-4. [\[Crossref\]](#)
 25. Williamson DA, Roberts SA, Paterson DL, Sidjabat H, Silvey A, Masters J, et al. Escherichia coli bloodstream infection after transrectal ultrasound-guided prostate biopsy: implications of fluoroquinolone-resistant sequence type 131 as a major causative pathogen. *Clin Infect Dis* 2012;54:1406-12. [\[Crossref\]](#)
 26. Nam RK, Saskin R, Lee Y, Liu Y, Law C, Klotz LH, et al. Increasing hospital admission rates for urological complications after transrectal ultrasound guided prostate biopsy. *J Urol* 2013;189(Suppl 1):S12-18. [\[Crossref\]](#)
 27. Noreikaite J, Jones P, Fitzpatrick J, Amitharaj R, Pietropaolo A, Vasdev N, et al. Fosfomycin vs. quinolone-based antibiotic prophylaxis for transrectal ultrasound-guided biopsy of the prostate: a systematic review and meta-analysis. *Prostate Cancer Prostatic Dis* 2018;21:153-60. [\[Crossref\]](#)
 28. Seitz M, Stief C, Waidelich R, Bader M, Tilki D. Transrectal ultrasound guided prostate biopsy in the era of increasing fluoroquinolone resistance: prophylaxis with single-dose ertapenem. *World J Urol* 2017;35:1681-8. [\[Crossref\]](#)
 29. Pepe P, Aragona F. Morbidity after transperineal prostate biopsy in 3000 patients undergoing 12 vs 18 vs more than 24 needle cores. *Urology* 2013;81:1142-6. [\[Crossref\]](#)
 30. Pepdjonovic L, Tan GH, Huang S, Mann S, Frydenberg M, Moon D, et al. Zero hospital admissions for infection after 577 transperineal prostate biopsies using single-dose cephazolin prophylaxis. *World J Urol* 2017;35:1199-203. [\[Crossref\]](#)
 31. Grummet JP, Weerakoon M, Huang S, Lawrentschuk N, Frydenberg M, Moon DA, et al. Sepsis and 'superbugs': should we favour the transperineal over the transrectal approach for prostate biopsy? *BJU Int* 2014;114:384-8. [\[Crossref\]](#)
 32. Bass EJ, Donaldson IA, Freeman A, Jameson C, Punwani S, Moore C, et al. Magnetic resonance imaging targeted transperineal prostate biopsy: a local anaesthetic approach. *Prostate Cancer Prostatic Dis* 2017;20:311-7. [\[Crossref\]](#)
 33. Meyer AR, Joice GA, Schwen ZR, Partin AW, Allaf ME, Gorin MA. Initial Experience Performing In-office Ultrasound-guided Transperineal Prostate Biopsy Under Local Anesthesia Using the PrecisionPoint Transperineal Access System. *Urology* 2018;115:8-13. [\[Crossref\]](#)
 34. Iremashvili VV, Chepurov AK, Kobaladze KM, Gamidov SI. Periprostatic local anesthesia with pudendal block for transperineal ultrasound-guided prostate biopsy: a randomized trial. *Urology* 2010;75:1023-7. [\[Crossref\]](#)

35. Kubo Y, Kawakami S, Numao N, Takazawa R, Fujii Y, Masuda H, et al. Simple and effective local anesthesia for transperineal extended prostate biopsy: application to three-dimensional 26-core biopsy. *Int J Urol* 2009;16:420-3. [\[Crossref\]](#)
36. Novella G, Ficarra V, Galfano A, Ballario R, Novara G, Cavalleri S, et al. Pain assessment after original transperineal prostate biopsy using a coaxial needle. *Urology* 2003;62:689-92. [\[Crossref\]](#)
37. Gorin MA, Meyer AR, Zimmerman M, Harb R, Joice GA, Schwen ZR, et al. Transperineal prostate biopsy with cognitive magnetic resonance imaging/biplanar ultrasound fusion: description of technique and early results. *World J Urol* 2020;38:1943-9. [\[Crossref\]](#)
38. Schouten MG, van der Leest M, Pokorny M, Hoogenboom M, Barentsz JO, Thompson LC, et al. Why and Where do We Miss Significant Prostate Cancer with Multi-parametric Magnetic Resonance Imaging followed by Magnetic Resonance-guided and Transrectal Ultrasound-guided Biopsy in Biopsy-naïve Men? *Eur Urol* 2017;71:896-903. [\[Crossref\]](#)
39. Ahmed HU, El-Shater Bosaily A, Brown LC, Gabe R, Kaplan R, Parmar MK, et al. Diagnostic accuracy of multi-parametric MRI and TRUS biopsy in prostate cancer (PROMIS): a paired validating confirmatory study. *Lancet (London, England)* 2017;389:815-22. [\[Crossref\]](#)
40. Kasivisvanathan V, Rannikko AS, Borghi M, Panebianco V, Mynderse LA, Vaarala MH, et al. MRI-Targeted or Standard Biopsy for Prostate-Cancer Diagnosis. *N Engl J Med* 2018;378:1767-77. [\[Crossref\]](#)
41. Pepe P, Garufi A, Priolo G, Pennisi M. Transperineal Versus Transrectal MRI/TRUS Fusion Targeted Biopsy: Detection Rate of Clinically Significant Prostate Cancer. *Clin Genitourin Cancer* 2017;15:e33-6. [\[Crossref\]](#)
42. Giannarini G, Crestani A, Rossanese M, Ficarra V. Multiparametric Magnetic Resonance Imaging Targeted Biopsy for Early Detection of Prostate Cancer: All That Glitters Is Not Gold! *Eur Urol* 2017;71:904-6. [\[Crossref\]](#)
43. Stabile A, Dell'Oglio P, Gandaglia G, Fossati N, Brembilla G, Cristel G, et al. Not All Multiparametric Magnetic Resonance Imaging-targeted Biopsies Are Equal: The Impact of the Type of Approach and Operator Expertise on the Detection of Clinically Significant Prostate Cancer. *Eur Urol Oncol* 2018;1:120-8. [\[Crossref\]](#)
44. Halstuch D, Baniel J, Lifshitz D, Sela S, Ber Y, Margel D. Characterizing the learning curve of MRI-US fusion prostate biopsies. *Prostate Cancer Prostatic Dis* 2019;22:546-51. [\[Crossref\]](#)
45. Grummet J, Pepdjonovic L, Huang S, Anderson E, Hadaschik B. Transperineal vs. transrectal biopsy in MRI targeting. *Transl Androl Urol* 2017;6:368-75. [\[Crossref\]](#)
46. Kuru TH, Wadhwa K, Chang RT, Echeverria LM, Roethke M, Polson A, et al. Definitions of terms, processes and a minimum dataset for transperineal prostate biopsies: a standardization approach of the Ginsburg Study Group for Enhanced Prostate Diagnostics. *BJU Int* 2013;112:568-77. [\[Crossref\]](#)
47. Mantica G, Pacchetti A, Aimar R, Cerasuolo M, Dotta F, Olivero A, et al. Developing a five-step training model for transperineal prostate biopsies in a naive residents' group: a prospective observational randomised study of two different techniques. *World J Urol* 2019;37:1845-50. [\[Crossref\]](#)
48. Onik G, Barzell W. Transperineal 3D mapping biopsy of the prostate: an essential tool in selecting patients for focal prostate cancer therapy. *Urol Oncol* 2008;26:506-10. [\[Crossref\]](#)
49. Barzell WE, Melamed MR. Appropriate patient selection in the focal treatment of prostate cancer: the role of transperineal 3-dimensional pathologic mapping of the prostate--a 4-year experience. *Urology* 2007;70(Suppl 6):27-35. [\[Crossref\]](#)
50. Smeenge M, Barentsz J, Cosgrove D, de la Rosette J, de Reijke T, Eggen S, et al. Role of transrectal ultrasonography (TRUS) in focal therapy of prostate cancer: report from a Consensus Panel. *BJU Int* 2012;110:942-8. [\[Crossref\]](#)
51. Long JA, Hungr N, Baumann M, Descotes JL, Bolla M, Giraud JY, et al. Development of a novel robot for transperineal needle based interventions: focal therapy, brachytherapy and prostate biopsies. *J Urol* 2012;188:1369-74. [\[Crossref\]](#)
52. Raz O, Haider MA, Davidson SR, Lindner U, Hlasny E, Weersink R, et al. Real-time magnetic resonance imaging-guided focal laser therapy in patients with low-risk prostate cancer. *Eur Urol* 2010;58:173-7. [\[Crossref\]](#)