

## PEYRONIE'S DISEASE

## 3D-Printed Flexible Penile Model Simulator for Plaque Incision and Graft for Peyronie's Disease



Alexandre Miranda, MD, PhD, FECSM

## ABSTRACT

**Introduction:** Plaque incision and graft (PIG) is suggested for the treatment of significant Peyronie's disease (PD), but most surgeons perform very few PIG surgeries annually, and the number of PD cases requiring PIG is inadequate to maintain the necessary skills and completely master the procedure.

**Aim:** To develop and validate a new 3D-printed model of a curved penis and graft to simulate PIG surgery. This is the first PIG surgical training simulator described in the medical literature.

**Methods:** A 3D-printed model of the corpora cavernosa with a 60-degree curvature and an associated urethra was created using a flexible filament of thermoplastic polyurethane. Twenty-two urologists from Brazil were recruited to perform simulated surgery on the 3D model. The participants included 12 senior-level and 10 trainee-level urologists.

**Main outcome measures:** Evaluation of the device was based on a 15-item questionnaire using a 5-point Likert-type scale for each item.

**Results:** Each participant performed one simulated surgery with the 3D-printed model. All participants agreed that the simulation should be implemented into training programs. Participants ranked all content validity components  $\geq 4.41$  and all face validity components  $\geq 3.83$ . The mean usability score was 4.25, and the overall experience scores were 4.75 (senior) and 5.0 (trainee).

**Conclusion:** Senior and trainee urologists evaluated this first reported simulated PIG training model for penile curvature correction as an acceptable tool for training and maintaining necessary PIG skills. This model may improve PIG training and surgeon skill, thereby improving patient safety and outcomes. **A Miranda. 3D-Printed Flexible Penile Model Simulator for Plaque Incision and Graft for Peyronie's Disease. Sex Med 2021;9:100318.**

Copyright © 2021, The Authors. Published by Elsevier Inc. on behalf of the International Society for Sexual Medicine. This is an open access article under the CC BY-NC-ND license (<http://creativecommons.org/licenses/by-nc-nd/4.0/>).

**Key Words:** Peyronie's Disease; Corpora Cavernosa; Graft; Penile Curvature; Urologic Surgical Procedures; Surgery Training

## INTRODUCTION

Peyronie's disease (PD) can appear as a variety of penile deformities that can generate an impairment or inability to achieve adequate sexual intercourse. The reported prevalence rates of PD vary from 3% to 8.9%, with >75% of cases occurring in men aged 45-65 years, and 10% of patients experiencing symptoms before 40 years of age.<sup>1</sup> Furthermore, the incidence of PD after

radical prostatectomy is reported to be as high as 15.9%, and a recent study showed that penile curvature is a common finding (38.6%) during inflatable penile prosthesis implantation surgery for erectile dysfunction (ED) after prostate cancer treatment.<sup>2</sup>

Patients presenting with severe loss of penile length, significant or severe curvature, and/or prominent hourglass deformities but without underlying ED are best treated by plaque incision and graft (PIG).<sup>1</sup> Regardless of this recommendation, in a recent survey with members of several sexual medicine societies, Chung et al<sup>3</sup> reported that most surgeons (>80%) performed fewer than 10 cases of PD graft surgery in a year, and there was no significant difference observed across the principal urological and sexual medicine societies. Only 3–6% of these surgeons performed >20 PIGs in a year. Another survey showed that only 37% of urologists perform any PIG surgeries.<sup>4</sup> Therefore, there

Received November 14, 2020. Accepted December 28, 2020.

Reconstructive Urology and Andrology Section, Department of Urology, Ipanema Federal, Rio de Janeiro, Brazil

Copyright © 2021, The Authors. Published by Elsevier Inc. on behalf of the International Society for Sexual Medicine. This is an open access article under the CC BY-NC-ND license (<http://creativecommons.org/licenses/by-nc-nd/4.0/>).

<https://doi.org/10.1016/j.esxm.2020.100318>

are insufficient PD cases to maintain the necessary skills and completely master the PIG procedure.

The aim of this work was to determine whether the training of novice surgeons and maintenance of the skills of more expert surgeons could be accomplished at low costs and without the associated patient risks. For this purpose, a new simulator of a curved penis was created using a 3D printer with flexible material to simulate PIG surgery. While other researchers have created similar surgical simulators using a 3D technology for training in penile prosthesis implant.<sup>5,6</sup> This is the first attempt at creating a surgical simulator for PIG described in the medical literature.

## MATERIALS AND METHODS

### The Simulator

A model of the corpora cavernosa with 60 degrees of curvature and an attached urethra was created using a 3D modeling software (Shapr3D, version 3.23, Hungary) [Figure 1]. The model was 3D-printed (GTMax3D Core A3, GTMax3D, Brazil) using a flexible filament of thermoplastic polyurethane with a diameter of 1.75 mm (GTMax3D, Brazil) using a fused deposition modeling technique. A base was also created using an acrylonitrile butadiene styrene filament with a diameter of 1.75 mm to fix the flexible part (GTMax3D, Brazil) [Figure 2; Video 1].

The fused deposition modeling is one technique for 3D manufacturing, in which a filament of thermoplastic material is heated to a molten state and then extruded through the nozzle of the 3D printer and then deposited layer by layer, leaving behind a 3D object when the material has solidified.

### Evaluation Form

Fifteen questions were designed using a 5-point Likert scale to determine the user's perception of the simulator (Annex 1). To test for clarity, intelligibility, and appropriateness of the questionnaire, it was first administered to a small group of 10 urologists. A face-to-face interview was conducted with these urologists to check for any difficulties in understanding and interpreting the individual questions; no major difficulties were noted. Three questions addressed the realism of the simulator (overall realism, anatomy, and texture), and 4 questions evaluated the procedural steps (curvature measurement, incision of the tunica albuginea, preparation of the graft, and suturing the graft to the tunica albuginea). The final 3 questions evaluated the global difficulty, usability, and overall experience. Participants could comment at the end of the survey about the drawbacks and advantages of the model. With the data so collected, descriptive statistics were performed to analyze the measures of central tendency (mean) and distribution of data (scatter dot plot) using

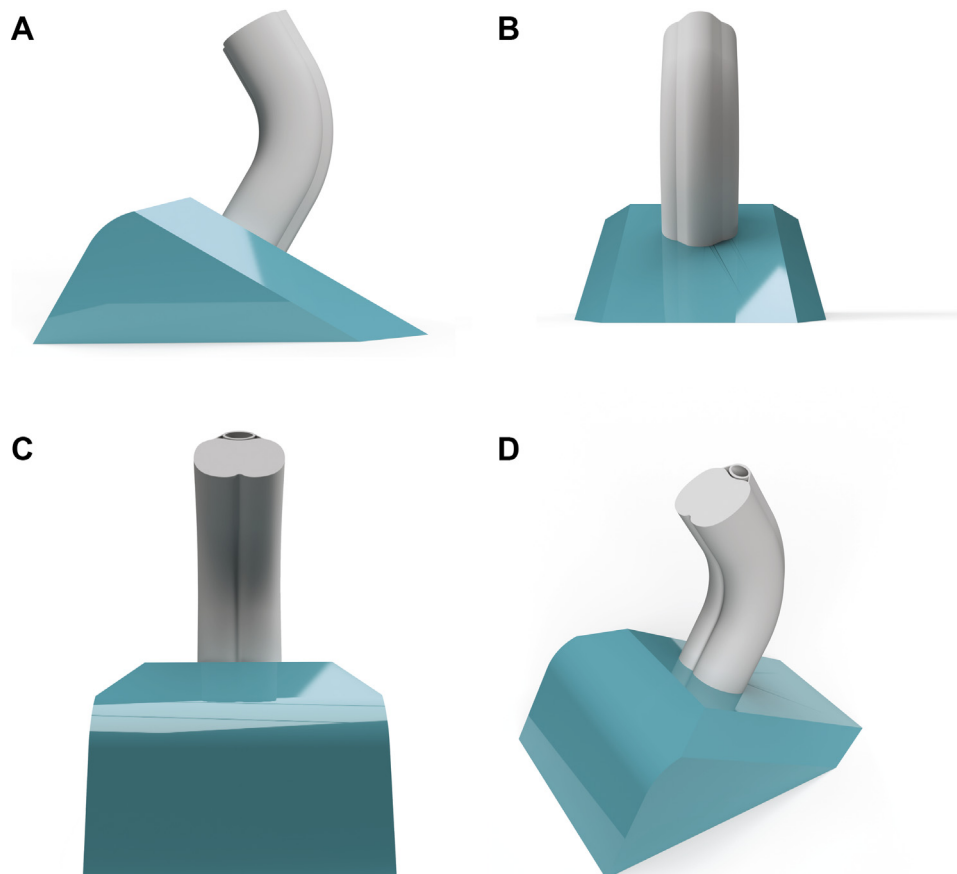
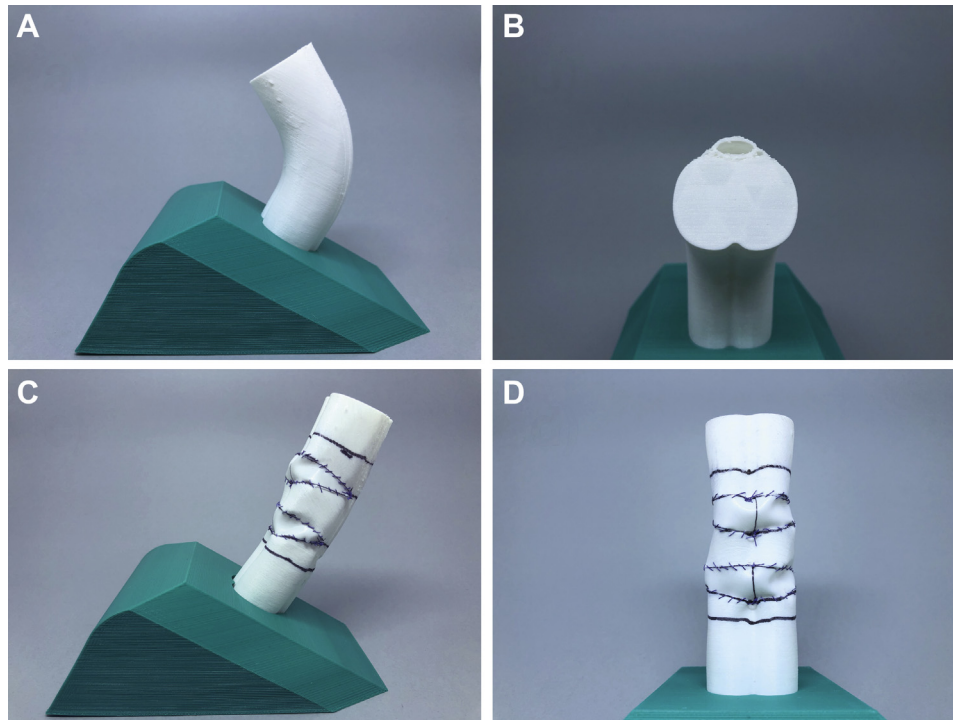


Figure 1. 3D model. a) Lateral view; b) ventral view; c) dorsal view; d) dorsolateral view.



**Figure 2.** 3D-printed model. a) Lateral view; b) dorsal view; c) lateral view after PIG simulation. The distal and proximal line was done oriented by the iGrafter APP, and they represent the beginning and the end of the curvature; d) dorsal view after PIG simulation. PIG = plaque incision and graft.

the software JASP (JASP Team (2020). JASP (Version 0.14) [computer software]).

### Tutorial

All the participants who attended a 1-day course on PD willingly gave consent for their responses to be used for this research. They were divided into pairs. Each pair received the same material composed of two 3D-printed simulators, one scalpel number 15, one needle holder, one straight Metzenbaum Scissors, tissue forceps, and 2-0 cotton thread with needle to perform the suture. Each individual simulated the PIG procedure, with the help of the other individual in the pair. Five instructors mentored all the participants.

The procedure was first explained in detail via video tutorials of a uniplanar case of PD with a 53° dorsal curvature using the previously described iGrafter 2.0 smartphone app.<sup>7,8</sup> All participants downloaded a new version of the app (iGrafter 2.0, [www.igrafter.com](http://www.igrafter.com)) to their smartphones. After calibrating the app to their smartphone's screen size, they performed the correction following the app instructions. There was no time limit to perform the procedure.

## RESULTS

### Surgeon Demographics and Experience

The participants included 10 trainee-level and 12 senior-level urology consultants. Trainees had a mean age of 35 years (range

28 to 50 years), and most were in their third year of training. They had low levels of PIG experience with <10 procedures/year. The participants in the experienced group had a mean age of 41 years (range 32 to 49 years). Two participants performed >20 PIG procedures/year, one performed 10-20 procedures/year, and 9 performed <10 procedures/year.

### Correction of the Deformity

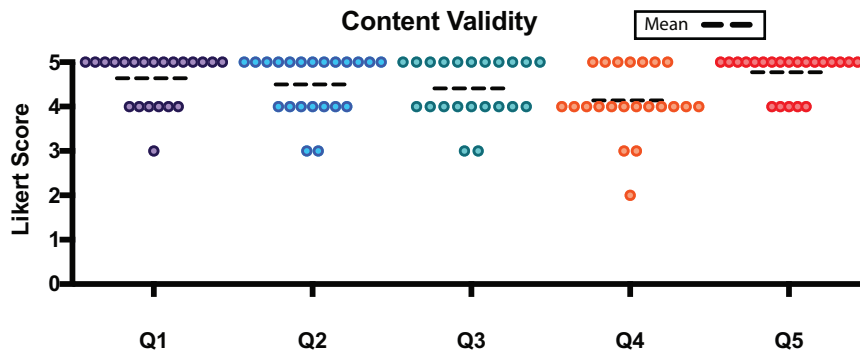
All participants achieved the correction of the deformities with the rectification of corpora cavernosa simulator.

### Content Validity

On a 5-point Likert scale, most participants believed that PIG is an effective method of treatment for penile curvature and that training for the procedure is essential (mean: 4.41). Almost all participants believed that there is a role for simulation-based training (mean: 4.64), and assessment is essential for patient safety (mean: 4.5). When asked if the model should be implemented as part of the surgeon's training to perform PIG, most participants strongly agreed (mean: 4.77) [Figure 3].

### Face Validity

To assess face validity, the experienced group answered a set of questions to grade the realism of various aspects of the simulator using a 5-point rating scale. The mean scores for realism, anatomy, and texture were 4.08, 4.33, and 3.83, respectively. The experienced group thought the steps of the procedure were fairly



**Figure 3.** Content validity—scatter dot plot. **Q1.** Is there a role for a validated Peyronie’s disease simulator for use in training? **Q2.** Is simulation-based assessment and training for Peyronie’s disease surgery essential for patient safety? **Q3.** Plaque incision and graft (PIG) for Peyronie’s disease is an effective method of treatment and training is a must. **Q4.** After performing the simulation with the 3D model, you feel more confident to perform PIG to correct penile curvature. **Q5.** Should the model be implemented as part of the surgeon’s training to perform PIG?

realistic, with mean scores for the curvature measurement, incision of the tunica albuginea, preparation of the graft, and suturing the graft to the tunica albuginea being 4.58, 4.33, 4.08, and 4.25, respectively. The trainees’ rating scores were similar [Figure 4].

**Global Difficulty and Usability**

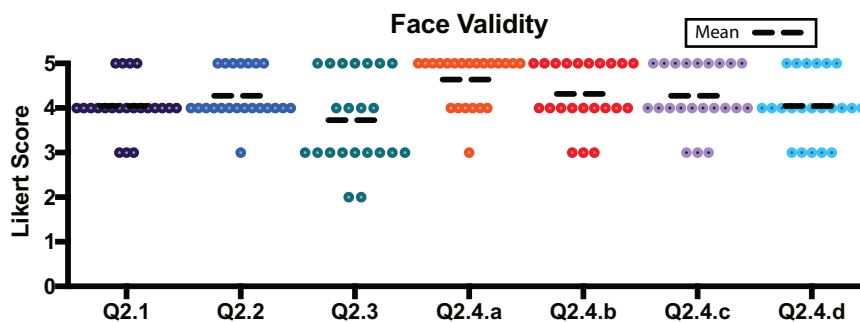
Senior and trainee urologists completed a set of questions assessing global difficulty and usability. The mean usability scores were 4.25 (senior) and 4.6 (trainee). The mean global difficulty scores assigned by the senior and trainee were 2.6 and 3.5, respectively. The overall experience performing PIG using the model was scored very high, with mean scores of 4.67 and 4.5 by the senior and trainee groups, respectively. When asked if the model can help in learning how to perform PIG, the mean scores were 4.75 and 5.0 for senior and trainee groups, respectively [Figure 5].

**DISCUSSION**

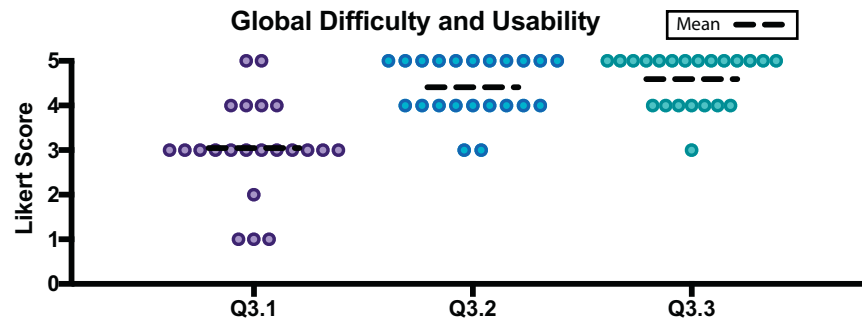
Although the principal urological and sexual medicine societies recommend PIG in cases of penile curvature with severe loss of penile length, significant or severe curvature (>60°), and/or prominent hourglass deformities in patients without ED,<sup>1,9,10</sup> we

see a low number of these surgeries in clinical practice.<sup>3,4</sup> One possible explanation could be the low number of patients who are candidates for PIG.

Mulhall et al<sup>11</sup> recruited 532 patients who presented for prostate cancer screening. A palpable penile plaque was found in 48 (9%) men. Of these men, 32 (6% of the total population) reported having noticed a penile curvature. Of these 32 men, only 14 (2.63% of the total population) received treatment. This suggests that only 29.2% of men with PD (2.63% of the total population) seek medical evaluation to receive treatment. In another research, Walsh et al<sup>12</sup> analyzed 202 men who sought medical evaluation for PD in a single tertiary referral center. He found that 88 (43.56%) patients had ED and only 8.9% of the remaining 114 (56.44%) with preserved erectile function presented with a potential indication to perform PIG (presence of >60 degree of curvature and sexual disability due to penile deformity in a patient without ED). Considering that 29.2% of patients with PD sought medical evaluation and only 8.9% of these men presented with a potential indication to perform PIG, we concluded that only 2.6% of the patients with PD could be candidates for PIG. This may be an explanation for the small number of PIG surgeries performed.



**Figure 4.** Face validity—scatter dot plot. Question: “Please rank each item according your perception of the Peyronie’s disease model”. **Q2.1.** Realistic design; **Q2.2.** Anatomy; **Q2.3.** Texture; **Q2.4.a.** Curvature measurement; **Q2.4.b.** Incision of the tunica albuginea; **Q2.4.c.** Preparation of the graft; **Q2.4.d.** Suturing the graft to the tunica albuginea.



**Figure 5.** Global difficulty and usability—scatter dot plot. Question: “Please rank each item according your perception of the Peyronie’s disease model”. **Q3.1.** Global difficulty (1 - very easy to 5 - very hard); **Q3.2.** Usability (the ease of use and learnability of the model); **Q3.3.** Overall experience.

Although the study included only a small number of participants, all believed that there is a role for simulation-based training to prepare surgeons to perform PIG. Both novices and experts recommended the 3D-printed model for use in surgical training. The model received high scores for usability and for replicating the anatomy and the surgical steps to perform PIG. One criticism was that the model simulates only the erect penis without a flaccid state, and the other was that it could not simulate the neurovascular bundle dissection from the corpora cavernosa or buck’s fascia dissection.

However, the production of this model is quite inexpensive, at around \$1.00 per unit. Anyone with a simple 3D printer can create it using the stereological file (.stl) and flexible filament. Local production eliminates the need for transportation and consequent time loss. Another potential use of the 3D-printed model is in the development of new surgical techniques and tools to correct penile deformity. The model eliminates the need for animals or cadavers for surgical training and opens a new field of research in reconstructive urology.

The 3D-printing technology brings infinite possibilities in the reconstruction of the human anatomy. It is possible to use computer tomography or magnetic resonance imaging to recreate the patient’s body segment to simulate surgery. Alternatively, we can design a template similar to the body part to construct a 3D simulation, as we did here. This technology’s limitation is the inability to model structures with less than 1 mm, making it impossible to reproduce human microanatomy. This limit in printing resolution does not allow the production of structures like the deferent duct. Therefore, it is not possible to construct, for example, a vasectomy reversion simulator. Nevertheless, we can recreate penile anatomy to simulate a penile prosthesis implant, penile plication, and other structures of size more than 1 mm.

## CONCLUSION

This is the first reported simulated model to train surgeons to perform PIG to correct penile curvature. The model is inexpensive and received high marks from both trainees and expert

surgeons for usability and realism. It may improve PIG training and surgeon skill, thereby improving patient safety and outcomes. The model could be a valuable addition to training programs and may also be used to develop new surgical techniques and tools to correct penile deformity.

**Corresponding Author:** Alexandre Miranda, MD, PhD, FECSM, Department of Urology, Ipanema Federal Hospital. Rua Antônio Parreiras 67, Sala 308. Ipanema, Rio de Janeiro, RJ, Brazil. Tel: +55 21 99926-0236; E-mail: [contato@alexandremiranda.com.br](mailto:contato@alexandremiranda.com.br)

*Conflicts of Interest:* The authors report no conflicts of interest.

*Funding:* This research did not receive any specific grant from funding agencies in the public, commercial, or not-for-profit sectors.

## STATEMENT OF AUTHORSHIP

Alexandre Miranda: Writing - Original Draft, Formal Analysis, Conceptualization, Methodology, Investigation, Resources, Writing - Review & Editing, Funding Acquisition, Project Administration.

## REFERENCES

1. Chung E, Ralph D, Kagioglu A, et al. Evidence-based Management guidelines on Peyronie’s disease. *J Sex Med* 2016; **13**:905-923.
2. Barrett-Harlow B, Clavell-Hernandez J, Wang R. New developments in surgical treatment for penile size Preservation in Peyronie’s disease. *Sex Med Rev* 2019; **7**:156-166.
3. Chung E, Wang R, Ralph D, et al. A Worldwide survey on Peyronie’s disease surgical practice patterns among surgeons. *J Sex Med* 2018; **15**:568-575.
4. Sullivan J, Moskovic D, Nelson C, et al. Peyronie’s disease: urologist’s knowledge base and practice patterns. *Andrology* 2015; **3**:260-264.
5. Renterghem V, Ghazi A. 3D pelvic cadaver model: a novel approach to surgical training for penile implant surgery. *Int J Impot Res* 2020; **32**:261-263.

6. Witthaus MW, Saba P, Melnyk R, et al. The Future of penile Prosthetic surgical training is Here: design of a Hydrogel model for inflatable penile Prosthetic Placement using modern Education theory. *J Sex Med* 2021;17:2299-2306.
7. Miranda AF, Sampaio FJ. Practical Computerized Solution for incision and grafting in Peyronie's disease. *Sex Med* 2016; 4:e73-e82.
8. Miranda AF. Practical Computerized Solution for incision and grafting in Peyronie's disease - uniplanar case, video Journal of Prosthetic urology; Available at <https://www.vjpu-issm.info/videos/peer-reviewed/1-penile-prosthesis-malleable-inflatable-penile-prosthesis-ipp/1-b-peyronie-s-disease-without-implant/itemlist/filter?ftitle=Practical+Computerized+Solution&category=25&moduleId=170&Itemid=210>. Accessed October 16, 2020.
9. Hatzimouratidis K, Eardley I, Giuliano F, et al. EAU guidelines on penile curvature. *Eur Urol* 2012;62:543-552.
10. Nehra A, Alterowitz R, Culkin DJ, et al. Peyronie's disease: AUA Guideline. *J Urol* 2015;194:745-753.
11. Mulhall JP, Creech SD, Boorjian SA, et al. Subjective and objective analysis of the prevalence of Peyronie's disease in a population of men presenting for prostate cancer screening. *J Urol* 2004;171:2350-2353.
12. Walsh TJ, Hotaling JM, Lue TF, et al. How curved is too curved? The severity of penile deformity may predict sexual disability among men with Peyronie's disease. *Int J Impot Res* 2013;25:109-112.

## SUPPLEMENTARY DATA

Supplementary data related to this article can be found at <https://doi.org/10.1016/j.esxm.2020.100318>.