



Review

The art of prevention: It's too tight—Loosen up and let your hair down

Tiffany T. Mayo, MD^{a,*}, Valerie D. Callender, MD^{b,c}^a The University of Alabama at Birmingham, Birmingham, AL, United States^b Department of Dermatology, Howard University College of Medicine, Washington, District of Columbia, United States^c Callender Dermatology & Cosmetic Center, Glenn Dale, MD, United States

ARTICLE INFO

Article history:

Received 6 November 2020

Received in revised form 20 January 2021

Accepted 20 January 2021

Keywords:

Traction alopecia

Traction folliculitis

Black hair

Black hairstyles

Hair type classification

Hair care recommendations

ABSTRACT

Traction alopecia is prevalent in patients of color. Its significance in clinical practice may be underemphasized due to the transient nature of the condition; however, it has the potential to become permanent and cause significant psychosocial distress. Understanding of afro-textured hair and cultural practices, as well as early recognition and treatment, provides an opportunity to prevent permanent traction alopecia and long-term sequelae.

© 2021 The Authors. Published by Elsevier Inc. on behalf of Women's Dermatologic Society. This is an open access article under the CC BY-NC-ND license (<http://creativecommons.org/licenses/by-nc-nd/4.0/>).

Contents

Introduction	174
Traction alopecia	174
Practical intervention	178
Conflicts of interest	179
Funding	179
Study approval	179
References	179

Introduction

Hair in patients of color may present a unique challenge for dermatologists and other health care providers unfamiliar with different curl patterns and traditional practices in this patient population. Compared with white patients, alopecia, particularly traction alopecia (TA), is especially pervasive among black patients (Alexis et al., 2007). Differences in the physical properties of afro-textured hair relative to other hair types has been well described, and mechanical fragility has been shown to increase with tighter curl patterns (Khumalo et al., 2000; Porter et al., 2005). Hair is con-

ventionally classified into three simplified subgroups (African, Asian, and Caucasian), but more recently curl pattern classification systems have expanded our ability to understand different hair types (Table 1; Aguh and Okoye, 2017; Loussouarn et al., 2007; Taylor, 2020; Wikipedia, 2020). Knowledge of afro-textured hair, hair terminology, and traditional haircare practices in patients of color may improve our ability to prevent TA by providing an early diagnosis and practical recommendations.

Traction alopecia

TA is one of the most prevalent alopecias in patients of color, affecting up to one-third of adult women of African descent and up to one-fourth of adolescents and teenagers of African descent

* Corresponding author.





E-mail address: tmayo@uabmc.edu (T.T. Mayo).

(Khumalo et al., 2007a, 2007b). TA is caused by hairstyling techniques that pull the hair tightly, producing prolonged tension and damage to the hair shaft and follicle.

TA affecting black patients may be categorized into three main subtypes: anterior hairline, ophiasis pattern, and patchy. Diagnosis

is based on clinical findings of alopecia in areas of tension. Anterior, or marginal, hairline TA is the most commonly reported type and presents with symmetric alopecia along the frontotemporal hairline. Alopecia with retained hairs along the periphery of the marginal hairline (i.e., fringe sign) may be present (Samrao et al., 2011).

Table 1
Curl pattern terminology commonly used by patients with natural hair.

Hair type	Example	Description	Common concerns
1		Straight hair (Asian and Caucasian hair types)	Oily
2A–C		S-shaped waves (Asian and Caucasian hair types)	Frizzy
3A–3C		Curly (Asian, Caucasian, and African hair types)	Combination of frizzy and dryness
4A–4C		Coily or kinky (African hair types)	Dryness and brittleness; increased susceptibility to breakage

Another finding recently described is the flambeau sign, or linear white tracks on dermoscopy resembling a lit torch in the direction of the hair pull (Fig. 1; Agrawal et al., 2020; Barbosa et al., 2015).

Ophiasis pattern TA presents similarly to anterior hairline TA but is located along the posterior and parietal scalp. Retained peripheral hairs, analogous to the fringe sign, are commonly

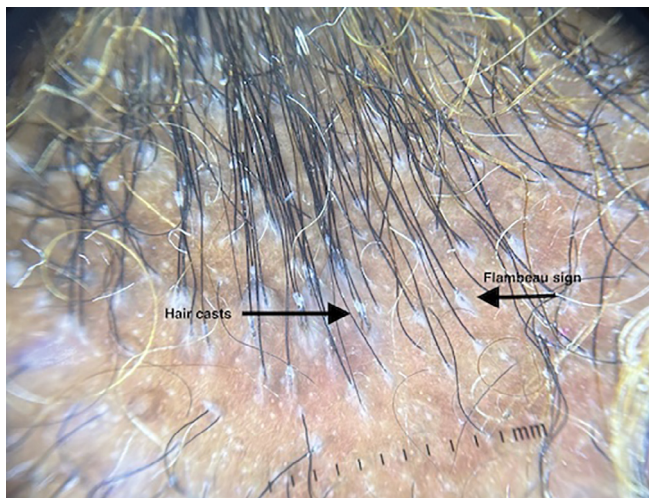


Fig. 1. Dermoscopy image showing flambeau sign (white tracks resembling a torch in the direction of hair pull) and hair casts (cylindrical casts encircling the proximal hair shaft), related to early traction alopecia.

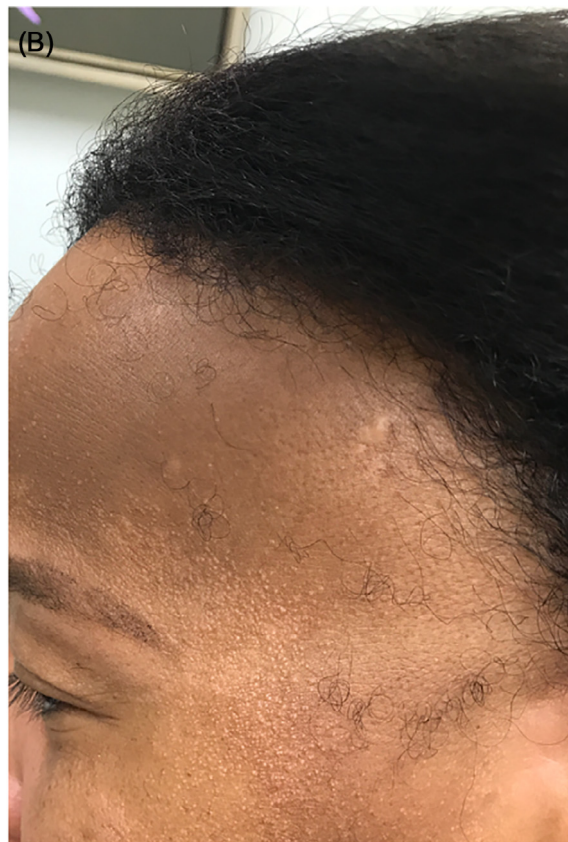

Fig. 2 (continued)

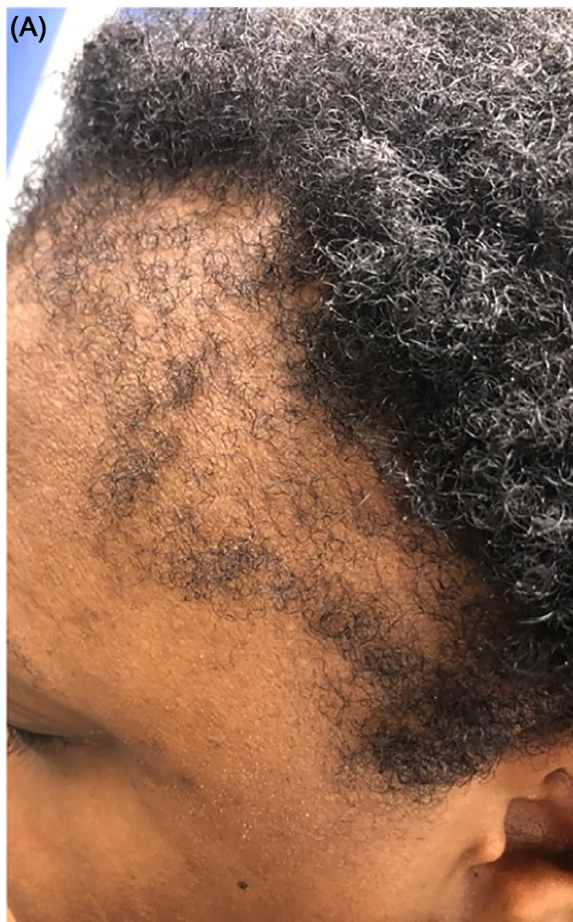

Fig. 2. (A) Traction alopecia demonstrating the fringe sign. (B) Frontal fibrosing alopecia showing classic findings, including lack of fringe sign, absence of vellus hairs, presence of single terminal hairs, facial papules, and loss of brows.

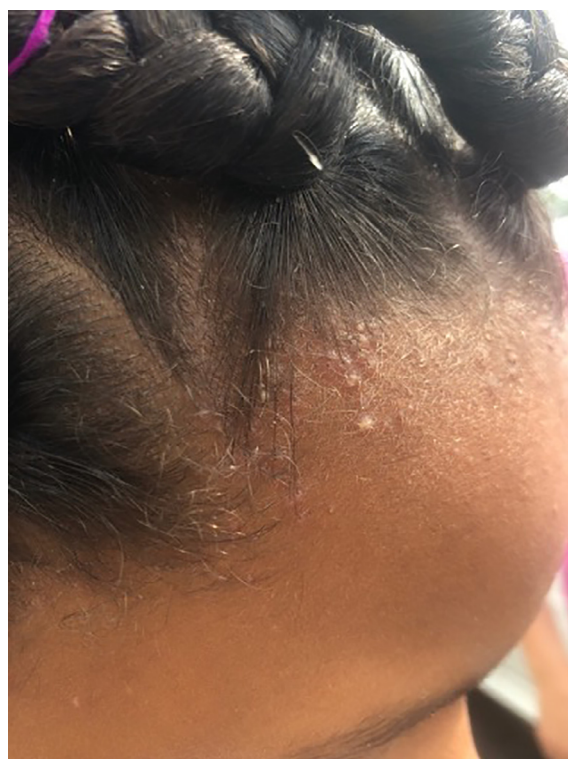

Fig. 3. Traction folliculitis.

present. Patients may reveal a history of up-do hairstyles, including ponytails, buns, and braids (Akingbola and Vyas, 2017; Haskin and Aguh, 2016).

Patchy TA presents with ill-defined areas of decreased density throughout the scalp (Barbosa et al., 2015; Billero and Miteva, 2018) and is due to recurrent tension in a particular pattern or direction. This type of TA is seen with hairstyles such as locks and recurrent tight braids. It may also be seen with recurrent use of hair rollers, hair clips, and other hair accessories (Billero and Miteva, 2018).

The differential for TA may include frontal fibrosing alopecia, alopecia areata, triangular temporal alopecia, and patchy central centrifugal cicatricial alopecia. Frontal fibrosing alopecia can be distinguished by a lack of the fringe sign, absence of vellus hair, presence of single lonely terminal hairs, peripilar scale, facial papules, and alopecia in other areas (e.g., brows; Fig. 2; Miteva et al., 2012). Alopecia areata, including the ophiasis pattern, may be distinguished by exclamation-point hairs on dermoscopy, a history of sudden onset or recurrent and remitting nature, and nail pitting (Akingbola and Vyas, 2017; Heath and Taylor, 2012; Strazzulla et al., 2018). Temporal triangular alopecia is usually unilateral and most commonly seen in children age 3 to 6 years (Fernández-Crehuet et al., 2016). Finally, patchy central centrifugal cicatricial alopecia and other scarring disorders can be distinguished from TA by loss of follicular ostia and inflammation

(Miteva and Tosti, 2015). Hairstyle history and duration of alopecia may assist with the diagnosis. It is important to note that TA may occur concomitantly with other types of alopecia, necessitating biopsy in some cases (Dlova et al., 2013).

Early symptoms of TA precede hair loss and may be subtle, such as pain, erythema, folliculitis (braid bumps), or serum crust (Fig. 3; Khumalo et al., 2007a). Many patients are asymptomatic. Hair casts (i.e., cylindrical casts seen on dermoscopy that encircle the proximal hair shaft) may also be seen and represent the inner or outer root sheath of the hair follicle (Fig. 1; Tosti et al., 2010). Alopecia caused by traction is initially reversible, but it becomes irreversible with prolonged repeated damage. Table 2 summarizes the symptoms and clinical findings of early and late TA.

Haskin and Aguh (2016) describe black hairstyling practices and their risk of TA. Common hairstyles and terminology are described in Table 3. Hairstyles with the highest likelihood of causing TA are tight buns/ponytails/pigtails, weaves/extensions, tight braids/cornrows, dreadlocks/sisterlocks, and curlers (Haskin and Aguh, 2016; Mirmirani and Khumalo, 2014; Rucker Wright et al., 2011). TA is also more common when these hairstyles are combined with chemically relaxed hair (Khumalo et al., 2008; Rucker Wright et al., 2011). Natural hair, loose hairstyles, and wigs are associated with the least risk of traction (Haskin and Aguh, 2016).

Management recommendations for traction folliculitis include mupirocin ointment or topical clindamycin gel. Treatment for early TA may include intralesional corticosteroids, antibiotics, and topical minoxidil (Khumalo and Ngwanya, 2007; Uwakwe et al., 2020). Hair transplantation has been shown to be effective for late TA with permanent alopecia (Earles, 1986; Okereke et al., 2019).

The treatment and management of hair in patients of color requires a nuanced understanding of terminology, cultural practices, and early signs and symptoms of disease. TA is prevalent and deserves the attention of dermatologists and other health care providers. Early diagnosis and intervention may prevent long-term permanent hair loss seen in late TA. Natural, loose, and low-hanging hairstyles are less likely to cause TA. These and other sty-

Table 2
Symptoms and clinical findings in early and late traction alopecia.

Traction alopecia preceding symptoms	Pain, erythema, folliculitis, serum crust, hair casts; often asymptomatic
Early traction alopecia	Decreased hair density, broken hairs, empty follicles, miniaturized hairs, fringe sign, flambeau sign
Late traction alopecia	Absence of follicular openings, fringe sign

Table 3
Terminology of common hairstyles and practices in black patients.

Big chop	Process of cutting off chemically relaxed hair ends
Blow-out	Brushing hair in the presence of moderate-to-high heat to straighten hair
Braid	Interlocking of ≥3 pieces of hair; not affixed to the scalp; may be combined with hair extensions for increased thickness and length
Co-wash	Process of washing hair with a conditioner instead of a shampoo; typically done on natural hair to maintain moisture
Cornrows	Braids affixed to the scalp with hair parted in straight or intricate rows
Dreadlocks, locks, sisterlocks	Intertwined sections of hair formed from uncombed hair tangling into clusters; hair may be rolled between the palms (palm rolling) to initiate and maintain process; hair is eventually permanently locked into sections; different from braids, which have a precise pattern and may be unbraided; sisterlocks are a much thinner variant of locks
Flat-ironing	Thermal straightening process where hair is pulled between two heated metal plates
Flat twists	Twists affixed to the scalp similar to cornrows but twisted instead of braided
Greasing scalp	Process of applying a pomade or oil to the scalp after washing hair and throughout the week; often done to cover scale from seborrheic dermatitis misinterpreted as dry scalp
Natural hair	Hair that has not been chemically processed
New growth	New unprocessed hair that has grown during a long-term style or chemical relaxer
Pomade	Ointment applied to hair to improve manageability; often applied to scalp (see greasing scalp)
Plaits, single braids, microbraids	Individually braided sections that vary in size; not affixed to the scalp; may be manipulated to form different styles
Pigtails	Hairstyle often worn by children in which hair is parted into sections, gathered using a rubber band or hair tie; loose ends are twisted or plaited
Pressing	Thermal hair straightening, also known as hot-combing; heated metal comb and hair oil are used to straighten hair
Relaxer	Chemical process to straighten hair permanently; frequently described as a perm by patients; however, perm is the permanent waving of straight hair, whereas relaxer is the permanent straightening of curly hair
Sew-in	Weave that is sewn onto hair braided into cornrows
Transitioning	Process of transitioning from relaxed to natural hair; also referred to as going natural or growing out hair
Twist-out	Twists or flat twists that have been untwisted and worn loose
Twists	Twisting two pieces of hair around each other; also known as two-strand twists
Weave, extensions, tracks	Synthetic or natural hair that can be sewn, braided, or glued to hair
Wig; lace front	Scalp covering made of synthetic or human hair; lace front is a type of wig with a frontal thin mesh or lace that camouflages in the frontal hairline



Fig. 4. Cultural relevance of hairstyling as a mother–daughter bonding experience.

ling modifications can provide safer yet acceptable hairstyle alternatives for patients.

Practical intervention

Early intervention is the most effective treatment for TA. Hair-styling practices and routines begin in toddlerhood. A study evaluating hair care practices and scalp disorders in African-American girls found that the risk of TA almost tripled with the use of cornrows, which is a common hairstyle in this age range (Rucker Wright et al., 2011). Pediatric hairstyles frequently display signs and symptoms of early TA (Table 2). The aforementioned study found less reported TA in surveys performed in dermatology clinics, presumably because dermatologists were more likely to discuss the risk of TA with parents (Rucker Wright et al., 2011). Educating mothers may be the most effective strategy to prevent TA given the influence mothers have on young girls' hair care practices during this common bonding experience (Fig. 4). Because early detection and education is critical, providers are encouraged to educate mothers and to identify signs of traction even when evaluating pediatric and adult patients for concerns unrelated to TA.

Although avoidance of tight hairstyles is the primary treatment for TA, recommending the discontinuation of specific hairstyles is often unrealistic, impractical, and may be perceived as a lack of understanding of ethnic or cultural practices and/or afro-textured hair. Also, hair loss is a sensitive subject for many patients and should be addressed with care and avoidance of hair shaming. Providing patients with education regarding early symptoms of TA and hairstyling modification recommendations may improve compliance and patient outcomes (Haskin and Aguh, 2016; Mirmirani and Khumalo, 2014). Table 4 identifies

Table 4
Practical recommendations to decrease risk of TA in adult and pediatric patients of African descent.

Adult hairstyles/practices that increase risk of TA	Modification/recommendation to patient
Weaves	Avoid using bonding glue, choose sew-in weave option (Haskin and Aguh, 2016)
Tight/heavy/long braids	Leave edges out when getting hair braided (may use edge control balm to style edges); avoid up-dos when styling braids; if up-dos preferred, gently loosen proximal ends of frontal hairline braids to decrease tension after hair tie in place; ask stylist to loosen braid if pain or stinging is experienced at time of braid placement, decrease volume and length of weave added to hair to decrease tension on hair follicle, leave styles in place no longer than 2–3 months; consider twists instead of braids
Chemically relaxed hair	Chemically relaxed hair combined with other hairstyles has highest prevalence of TA. Avoid weaves, braids, and extensions; if avoidance is not possible, decrease volume, length, and longevity of hairstyle; consider transitioning to natural hair and styling with temporary blow-out or thermal method when straight hair is desired
Wigs that rub frontal hair line	Satin wig cap or velvet wig band should be used to protect the hair and hairline; avoid cotton and nylon because these can cause friction and absorb moisture (Haskin and Aguh, 2016)
Ponytails, buns, and up-dos	Replace rubber bands with covered elastic ties or other types of hair ties without metal. If sleek appearance desired, instead of pulling hair tightly, use alcohol-free gels and hairstyling cream; use satin scarf to help set hair and control frizz
Dreadlocks and sisterlocks	Avoid length because this can increase weight and damage to hair follicle; avoid combining locks along the frontal hairline; when styling locks, loosen locks at frontal hairline once styled
Prolonged or repetitive styles	Give hair a break to recover between styles; consider wearing a wig with satin cap or other loose protective hairstyles
Pediatric hairstyles/practices that increase risk of TA	Modification/recommendation to parent
Tight cornrows	Avoid excessive pulling of hair during braiding of a cornrow; loosen tension of hair at the hairline before braiding loose end of cornrow; satin pillowcase or bonnet can help maintain style; consider flat twist instead of cornrows
Hair bound with rubber bands	Use covered elastic bands/ties or other hair bands without metal to decrease pulling and breakage caused by traditional rubber bands
Tight pigtails and ponytails	Frizz or unkempt appearance is a common reason for tight styles. Hairstyling balms, pomades, creams, and alcohol-free gels used with styling can help control frizz. Satin bonnets, satin scarves, or satin pillowcases can reduce frizz
Braids styled in updo or pulled back	Allow braid in frontal hairline to hang freely or once hair tie is in place, gently pull proximal ends of frontal hairline braids to decrease tension; avoid pulling loose braided end of cornrow perpendicular to director of the style (particularly cornrows braided along the frontal hairline); consider twists instead of braids
Prolonged braided or repeated braided styles	Prolonged tension from tight hairstyles can lead to TA; avoid leaving hairstyles in place longer than 2–4 weeks (up to 2 months for older children); moisturize hair along frontal hairline to decrease breakage; take breaks between braids/cornrows and avoid repetitive patterns of tension

TA, traction alopecia.

practical hairstyle recommendations that may decrease the risk of TA in adults and children.

Many patients with TA are asymptomatic, but pain after hair-styling is one of the earliest symptoms of TA. Patients may be accustomed to and actually expect pain and irritation of the scalp after certain hairstyles. Counseling patients to recognize scalp pain as a symptom of alopecia may help them identify when styling modifications are needed. This symptom provides patients with an opportunity to ask the stylist to loosen or adjust the style immediately. Counseling patients regarding other early symptoms of TA, such as erythema, traction folliculitis, and serum crust, may also be helpful in identifying early TA (Khumalo et al., 2007a). Other style-related modifications may include choosing sew-in weaves instead of using bonding glues, taking breaks between weaves/braided styles, decreasing use of thermal straightening on relaxed hair, and/or using natural hairstyles/wigs/scarves (Haskin and Aguh, 2016). For pediatric patients, mothers should be counseled to avoid rubber bands that pull hair and increase tension along the hairline. Hair ties or covered elastic bands may be used instead. Also, satin scarves/pillowcases and hair products can be used to keep the hair neat and increase the longevity of hairstyles/braids in lieu of tight styles. Finally, styles that pull the hair up or back should be avoided or adjusted to decrease the risk of TA (Table 4).

Cultural competence is imperative for effective communication regarding alopecia in patients of color. A key aspect of cultural competence is understanding common hair care practices and terminology. Effective communication also involves written resources. Patient handouts accessible through societies, such as the Skin of Color Society, may enhance treatment compliance. In addition to providing handouts, providers should consider writing a letter to the hairstylist notifying them of the diagnosis, treatment plan, and recommendations to encourage a team-based management approach. For pediatric patients, a similar letter to the child's parent and pediatrician may be helpful as well. Knowledge of terminology will improve communication with the patient/patient's parent and hairstylist, and it will increase patient confidence in management recommendations. Finally, supporting societies dedicated to alopecia education and research, such as the American Hair Research Society, Cicatricial Alopecia Research Foundation, and Skin of Color Society, may further our understanding, educational resources, and ability to manage TA.

Conflicts of interest

None.

Funding

None.

Study approval

The author(s) confirm that any aspect of the work covered in this manuscript that has involved human patients has been conducted with the ethical approval of all relevant bodies.

References

- Andre Walker hair typing system [Internet]. 2020 [cited 2020 December 18]. Available from: https://en.wikipedia.org/wiki/Andre_Walker_Hair_Typing_System.
- Agrawal S, Daruwalla SB, Dhurat RS. The flambeau sign - A new dermoscopy finding in a case of marginal traction alopecia. *Australas J Dermatol* 2020;61(1):49–50.
- Aguh C, Okoye G. The fundamentals of ethnic hair. Cham, Switzerland: Springer International Publishing; 2017.
- Akingbola CO, Vyas J. Traction alopecia: A neglected entity in 2017. *Indian J Dermatol Venereol Leprol* 2017;83(6):644–9.
- Alexis AF, Sergay AB, Taylor SC. Common dermatologic disorders in skin of color: A comparative practice survey. *Cutis* 2007;80(5):387–94.
- Barbosa AB, Donati A, Valente NS, Romiti R. Patchy traction alopecia mimicking areata. *Int J Trichol* 2015;7(4):184–6.
- Billero V, Miteva M. Traction alopecia: The root of the problem. *Clin Cosmet Invest Dermatol* 2018;11:149–59.
- Dlova NC, Jordaan HF, Skenjane A, Khoza N, Tosti A. Frontal fibrosing alopecia: A clinical review of 20 black patients from South Africa. *Br J Dermatol* 2013;169(4):939–41.
- Earles RM. Surgical correction of traumatic alopecia marginalis or traction alopecia in black women. *J Dermatol Surg Oncol* 1986;12(1):78–82.
- Fernández-Crehuet P, Vaño-Galván S, Martorell-Calatayud A, Arias-Santiago S, Grimalt R, Camacho-Martínez FM. Clinical and trichoscopic characteristics of temporal triangular alopecia: A multicenter study. *J Am Acad Dermatol* 2016;75(3):634–7.
- Haskin A, Aguh C. All hairstyles are not created equal: What the dermatologist needs to know about black hairstyling practices and the risk of traction alopecia (TA). *J Am Acad Dermatol* 2016;75(3):606–11.
- Heath CR, Taylor SC. Alopecia in an ophiasis pattern: Traction alopecia versus alopecia areata. *Cutis* 2012;89(5):213–6.
- Khumalo NP, Doe PT, Dawber RP, Ferguson DJ. What is normal black African hair? A light and scanning electron-microscopic study. *J Am Acad Dermatol* 2000;43(5 Pt 1):814–20.
- Khumalo NP, Jessop S, Gumedze F, Ehrlich R. Determinants of marginal traction alopecia in African girls and women. *J Am Acad Dermatol* 2008;59(3):432–8.
- Khumalo NP, Jessop S, Gumedze F, Ehrlich R. Hairdressing and the prevalence of scalp disease in African adults. *Br J Dermatol* 2007a;157(5):981–8.
- Khumalo NP, Jessop S, Gumedze F, Ehrlich R. Hairdressing is associated with scalp disease in African schoolchildren. *Br J Dermatol* 2007b;157(1):106–10.
- Khumalo NP, Ngwanya RM. Traction alopecia: 2% topical minoxidil shows promise. Report of two cases. *J Eur Acad Dermatol Venereol* 2007c;21(3):433–4.
- Loussouarn G, Garcel AL, Lozano I, Collaudin C, Porter C, Panhard S, et al. Worldwide diversity of hair curliness: A new method of assessment. *Int J Dermatol* 2007;46(Suppl 1):2–6.
- Mirmirani P, Khumalo NP. Traction alopecia: How to translate study data for public education—Closing the KAP gap? *Dermatol Clin* 2014;32(2):153–61.
- Miteva M, Tosti A. Central centrifugal cicatricial alopecia presenting with irregular patchy alopecia on the lateral and posterior scalp. *Skin Appendage Disord* 2015;1(1):1–5.
- Miteva M, Whiting D, Harries M, Bernardes A, Tosti A. Frontal fibrosing alopecia in black patients. *Br J Dermatol* 2012;167(1):208–10.
- Okereke UR, Simmons A, Callender VD. Current and emerging treatment strategies for hair loss in women of color. *Int J Womens Dermatol* 2019;5(1):37–45.
- Porter CE, Diridollou S, Holloway Barbosa V. The influence of African-American hair's curl pattern on its mechanical properties. *Int J Dermatol* 2005;44(Suppl 1):4–5.
- Rucker Wright D, Gathers R, Kapke A, Johnson D, Joseph CL. Hair care practices and their association with scalp and hair disorders in African American girls. *J Am Acad Dermatol* 2011;64(2):253–62.
- Samrao A, Price VH, Zedek D, Mirmirani P. The, “fringe sign” - A useful clinical finding in traction alopecia of the marginal hair line. *Dermatol Online J* 2011;17(11):1.
- Strazzulla LC, Wang EHC, Avila L, Sicco KL, Brinster N, Christiano AM, et al. Alopecia areata: Disease characteristics, clinical evaluation, and new perspectives on pathogenesis. *J Am Acad Dermatol* 2018;78(1):1–12.
- Taylor E. Here's how to figure out your specific hair type [Internet]. 2020 [cited 2020 December 18]. Available from: <https://www.newbeauty.com/how-to-figure-out-your-hair-type/1>.
- Tosti A, Miteva M, Torres F, Vincenzi C, Romanelli P. Hair casts are a dermoscopic clue for the diagnosis of traction alopecia. *Br J Dermatol* 2010;163(6):1353–5.
- Uwakwe LN, De Souza B, Tovar-Garza A, McMichael AJ. Intralesional triamcinolone acetonide in the treatment of traction alopecia. *J Drugs Dermatol* 2020;19(2):128–30.