

# CLIPPERS With Exclusive Extra Pontine Involvement

Helder Picarelli, MD, Vitor Nagai Yamaki, MD, Yuri Reis Casal, MD, Marcelo Houat de Brito, MD, Luiz Guilherme Cernaglia Aureliano de Lima, MD, Aline Sgnolf Ayres, MD, and Marcos Castello Barbosa de Oliveira, MD

**Correspondence**  
Dr. Picarelli  
hpicarelli@gmail.com

*Neurol Neuroimmunol Neuroinflamm* 2021;8:e989. doi:10.1212/NXI.0000000000000989

## Case Report

A 39-year-old female patient, without medical history, presented symptoms of holocranial headache and vomiting for 2 months before a single tonic-clonic seizure. In the postictal period, she presented with left hemiparesis that completely resolved over a couple of weeks without medical therapy other than phenytoin. The neurologic examination was unremarkable after that.

Brain MRI revealed subcortical and periventricular white matter lesions in the right frontoparietal and insular lobes, with a perivascular punctate and curvilinear enhancement, with no restricted diffusion, associated with edema without significant mass effect (figure 1). MRI angiography, including vessel wall sequences, did not show vascular stenosis or signs of vasculitis. CSF analysis showed slightly elevated protein levels (49 mg/dL) and cytology with 5 white blood cells; there were no oligoclonal bands, and protein electrophoresis was normal. Infectious screening of CSF was negative for herpes simplex virus I/II, *Cytomegalovirus*, *Adenovirus*, *Mycobacterium tuberculosis*, Varicella zoster virus, human herpesvirus 6/7, and *Enterovirus*. In addition, neoplastic cells were not detected in CSF. The investigation was also negative for *Treponema pallidum*, HIV, and hepatitis B and C. The screening for systemic autoimmunity and neoplastic diseases, including FDG PET-CT, was unremarkable.

The patient underwent neuronavigation-guided open biopsy of a contrast-enhancing region in the inferior frontal gyrus. Samples were sent for neuropathologic analysis and flow cytometry. Immunophenotyping was negative for abnormal hematologic cells. The neuropathologic study revealed leptomeningeal and perivascular inflammation with parenchymal infiltration consisting of CD4 reactive T lymphocytes and occasional CD8-, C20-, and CD86-positive lymphocytes (figures e-1 and e-2, [links.lww.com/NXI/A463](https://links.lww.com/NXI/A463) and [links.lww.com/NXI/A464](https://links.lww.com/NXI/A464), respectively). There were no lesions on vessel walls and no granulomas, malignant cells, or myelin loss. The patient was treated with oral prednisone (60 mg/d) for 6 weeks, followed by a taper. She remained asymptomatic during treatment. Posttreatment MRI revealed resolution of the gadolinium-enhancing lesions (figure e-3, [links.lww.com/NXI/A465](https://links.lww.com/NXI/A465)).

## Discussion

The original description of CLIPPERS emphasizes the involvement of the pons,<sup>1</sup> and the most recent set of criteria<sup>2</sup> require pontocerebellar involvement. However, more than half of patients with CLIPPERS have supratentorial involvement with imaging patterns similar to those seen in the

---

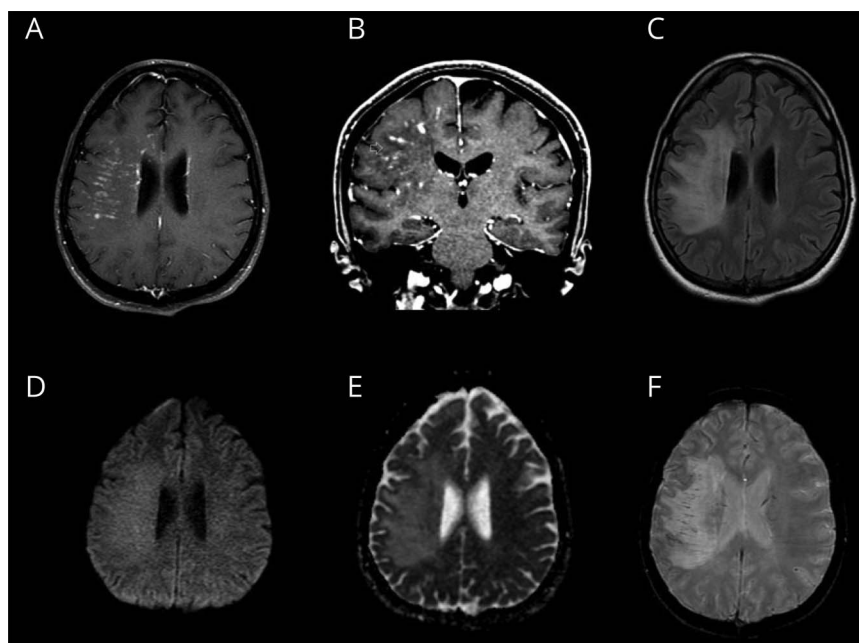
From the Department of Surgery (H.P.), Department of Surgery (V.N.Y.), Division of Anatomical Pathology (Y.R.C.), Neurology Unit (M.H.d.B.), Instituto do Câncer do Estado de São Paulo (ICESP), Faculdade de Medicina da Universidade de São Paulo (FMUSP), Brazil; Division of Anatomical Pathology (L.G.C.A.L.), Instituto do Câncer do Estado de São Paulo (ICESP), Faculdade de Medicina da Universidade de São Paulo (FMUSP), Brazil; Department of Diagnostic Imaging (A.S.A.), Instituto do Câncer do Estado de São Paulo (ICESP), Faculdade de Medicina da Universidade de São Paulo (FMUSP), Brazil; Neurology Unit (M.C.B.O.), Instituto do Câncer do Estado de São Paulo (ICESP), Faculdade de Medicina da Universidade de São Paulo (FMUSP), Brazil.

Go to [Neurology.org/NN](https://Neurology.org/NN) for full disclosures. Funding information is provided at the end of the article.

All authors have contributed equally to this work.

The Article Processing Charge was funded by the authors.

This is an open access article distributed under the terms of the Creative Commons Attribution-NonCommercial-NoDerivatives License 4.0 (CC BY-NC-ND), which permits downloading and sharing the work provided it is properly cited. The work cannot be changed in any way or used commercially without permission from the journal.



Perivascular enhancement, occasionally assuming a nodular configuration, in periventricular and subcortical right frontoparietal white matter (A and B). Extension to the insula and edema are also seen (C). No restricted diffusion is demonstrated (D and E). Mild enlarged vascular structures are seen in correspondence to enhancement zones in susceptibility imaging (F).

brainstem, as shown by the largest cohort to date.<sup>3</sup> In addition, in another study where autopsy and high-field 7T MRI were performed in patients with CLIPPERS, the authors suggest that there may be a more widespread perivascular inflammation, with a demonstration of supratentorial involvement that was not detected on 3T MRI.<sup>4</sup> Although 3 similar cases have previously been reported presenting as an exclusively supratentorial inflammatory disorder with curvilinear enhancement on MRI responsiveness to steroids, and perivascular T lymphocyte infiltrate on biopsy; they were published in abstract form with no images available on the brain MRI or neuropathology.<sup>5,6</sup> The disorder described was remarkably similar to CLIPPERS, with the exception that there was no pontocerebellar involvement. The authors suggested that these cases were a CLIPPERS variant and proposed to name it “supratentorial lymphocytic inflammation with parenchymal perivascular enhancement responsive to steroids (SLIPPERS).”

Our patient, similarly to the SLIPPERS cases reported, had a chronic perivascular lymphocytic inflammatory disorder that was remarkably responsive to steroids but lacked the pontocerebellar involvement to fulfill the CLIPPERS criteria. Histopathology ruled out lymphoproliferative disorders and vasculitis, which are commonly described as CLIPPERS mimics.<sup>3</sup> Although not tested for antigial fibrillary acidic protein (GFAP) antibodies, the clinical presentation, CSF profile, histopathology in our case was not typical of the recently described autoimmune GFAP astrocytopathy.<sup>7</sup>

CLIPPERS is currently regarded as a syndrome, and evidence is not robust enough to consider it a distinctive disease. Hypotheses that have been contemplated include that (1) it is prestage or

unusual presentation of well-determined diseases such as autoimmune gliopathies or vasculitis; (2) it is a prelymphoma state that could progress to lymphoma (i.e., primary CNS lymphoma); or (3) it is a manifestation of a disease still not fully understood.<sup>3</sup> In keeping with this rationale, it is conceivable that SLIPPERS may have pathophysiologic mechanisms akin to that of CLIPPERS and may represent another end of a spectrum of disorders with perivascular enhancement and responsiveness to steroids.

The pathogenesis of CLIPPERS and its predisposition for the pontine region remain unknown. Our description of the hemispheric pattern of involvement of a CLIPPERS-like disease suggests an autoimmune etiology. Long-term follow-up is necessary to exclude malignant transformation and to reach consistent conclusions. Despite that, we strongly believe that this description, and those previously named as SLIPPERS, supports the idea that all of them are a CLIPPERS-variant presentation with isolated supratentorial involvement. Therefore, we suggest the acronym extra pontine CLIPPERS, to stress the similarities between them, until more comprehensive understanding of this disorder is reached.

### Study Funding

No targeted funding reported.

### Disclosure

The authors report no competing interests. Go to [Neurology.org/NN](http://Neurology.org/NN) for full disclosures.

### Publication History

Received by *Neurology: Neuroimmunology & Neuroinflammation* December 22, 2020. Accepted in final form January 20, 2021.

## Appendix Authors

Name	Location	Contribution
<b>Helder Picarelli, MD</b>	Instituto do Câncer do Estado de São Paulo, Faculdade de Medicina da Universidade de São Paulo (FMUSP), São Paulo SP, Brazil	Drafting/revision of the manuscript for content, including medical writing for content; major role in the acquisition of data; study concept or design; and analysis or interpretation of data
<b>Vitor Nagai Yamaki, MD</b>	Universidade de São Paulo, Faculdade de Medicina, Hospital das Clínicas	Drafting/revision of the manuscript for content, including medical writing for content, and study concept or design
<b>Yuri Reis Casal, MD</b>	Universidade de São Paulo, Faculdade de Medicina, Hospital das Clínicas	Drafting/revision of the manuscript for content, including medical writing for content; major role in the acquisition of data; and analysis or interpretation of data
<b>Marcelo Houat de Brito, MD</b>	Instituto do Câncer do Estado de São Paulo, Faculdade de Medicina da Universidade de São Paulo (FMUSP), São Paulo SP, Brazil	Drafting/revision of the manuscript for content, including medical writing for content; study concept or design; and analysis or interpretation of data
<b>Luiz Guilherme Cernaglia Aureliano de Lima, MD</b>	Instituto do Câncer do Estado de São Paulo, Faculdade de Medicina da Universidade de São Paulo (FMUSP), São Paulo SP, Brazil	Drafting/revision of the manuscript for content, including medical writing for content; major role in the acquisition of data; and analysis or interpretation of data

## Appendix (continued)

Name	Location	Contribution
<b>Aline Sgnolf Ayres, MD</b>	Instituto do Câncer do Estado de São Paulo, Faculdade de Medicina da Universidade de São Paulo (FMUSP), São Paulo SP, Brazil	Drafting/revision of the manuscript for content, including medical writing for content; major role in the acquisition of data; and analysis or interpretation of data
<b>Marcos Castello Barbosa de Oliveira, MD</b>	Instituto do Câncer do Estado de São Paulo, Faculdade de Medicina da Universidade de São Paulo (FMUSP), São Paulo SP, Brazil	Drafting/revision of the manuscript for content, including medical writing for content; major role in the acquisition of data; study concept or design; and analysis or interpretation of data

## References

1. Pittock SJ, Debruyne J, Krecke KN, et al. Chronic lymphocytic inflammation with pontine perivascular enhancement responsive to steroids (CLIPPERS). *Brain* 2010;133:2626–2634.
2. Tobin WO, Guo Y, Krecke KN, et al. Diagnostic criteria for chronic lymphocytic inflammation with pontine perivascular enhancement responsive to steroids (CLIPPERS). *Brain* 2017;140:2415–2425.
3. Taieb G, Mulero P, Psimaras D, et al. CLIPPERS and its mimics: evaluation of new criteria for the diagnosis of CLIPPERS. *J Neurol Neurosurg Psychiatry* 2019;90:1027–1038.
4. Blaabjerg M, Ruprecht K, Sinnecker T, et al. Widespread inflammation in CLIPPERS syndrome indicated by autopsy and ultra-high-field 7T MRI. *Neurol Neuroimmunol Neuroinflammation* 2016;3:1–9.
5. Armand C, Graber J, Lado F, LaSala P, Weidenheim K. SLIPPERS: supratentorial lymphocytic inflammation with parenchymal perivascular enhancement responsive to steroids: a case report (P5.118). *Neurology* 2015;84:P5.118.
6. Horng S, Crary J, Fabian M. A case of SLIPPERS (supratentorial lymphocytic inflammation with parenchymal perivascular enhancement responsive to steroids) presenting with isolated cognitive dysfunction. (P1.336). *Neurology* 2017;88:336.
7. Kunchok A, Zekeridou A, McKeon A. Autoimmune glial fibrillary acidic protein astrocytopathy. *Curr Opin Neurol* 2019;32:452–458.