

Management of ankle injuries in professional basketball players: Prevalence and rehabilitation

M. Lane Moore,¹ Jack M. Haglin,¹
Jeffrey D. Hassebrock,²
Matthew B. Anastasi,² Anikar Chhabra²

¹Mayo Clinic Alix School of Medicine,
Mayo Clinic, Scottsdale, AZ;

²Department of Orthopedic Surgery,
Mayo Clinic, Phoenix, AZ, USA

Abstract

Basketball is a popular internationally played sport. With the physical requirements the game has on athletes, players are at risk of injury. Ankle injuries are the most common injury type suffered by basketball players. In this comprehensive review, we present an analysis and overview of the most common ankle injuries among basketball players, including sprains, fractures, impingement, and Achilles tendon pathology. The review includes treatment modalities for such injuries. More research is warranted regarding prevention strategies.

Introduction

With basketball's requirement for repetitive jumping, abrupt changes in motion, and need for explosiveness comes an increased risk for musculoskeletal injury. Basketball has the greatest risk of injury among all non-contact sports, with some research suggesting that the injury risk is greater than many full-contact sports as well.^{1,2} The most common injuries among basketball players are lower extremity injuries, mostly involving the ankles, knees, and injuries of the lower back.³⁻⁵ With the popularity of the National Basketball Association (NBA) and basketball as a sport growing in both the U.S. and worldwide, healthcare professionals should expect a continuous rise in basketball related injuries well into the future.^{6,7}

In terms of incidence, basketball-related ankle injury has been reported to fall anywhere from 3.8 to 5.2 injuries per 1,000 athlete exposures.^{8,9} Ankle injury is the most common lower extremity injury accounting for approximately 21.9% of all basketball-related injuries.¹⁰ In the NBA specifically, ankles are the most commonly injured joint with over 1,800 game-related ankle injuries compromising 14.7% of all injuries in an

average year.³ The most common activity at the time of ankle injury is rebounding (34.4% of all ankle injuries) followed by general play, defending, and shooting.

Ankle injuries are not only the most common injury sustained while playing basketball, but are also among the most severe and difficult to recover from.^{9,11} Despite basketball-related ankle injuries accounting for less than a quarter of all injuries, an Australian basketball study found that over half (53.7%) of the playing time missed due to injury was caused by an ankle injury.^{10,11} Additionally, ankle injuries are often associated with residual chronic symptoms and pathology (ankle instability, chronic pain, weakness, stiffness, and crepitus) that may impact an athlete's ability to return to play and perform at a high level of competition.¹² In this article, we discuss the important aspects of acute and chronic management of ankle injuries among professional basketball players along with the proper steps and protocols for rehabilitation. The prevalence of the most common types of ankle injury are also discussed.

Methods of article retrieval

An initial, comprehensive search of the MEDLINE database was performed for clinical publications that focused on ankle injury among athletes. Related clinical studies written in English were reviewed for relevancy and included. Articles written before 1990 were excluded to assure modern perspective. For the clinical study review, all published clinical reports that were eligible on the basis of our Preferred Reporting Items for Systematic Reviews and Meta-Analyses (PRISMA)-established search criteria were included to provide a comprehensive summary of the current body of published evidence (Figure 1). Search terms included "Ankle Injury Athlete", "Ankle Sprain Athlete", "Basketball Injury", "Ankle Injury Basketball" "Return to Play Basketball Injury".

Ankle sprain

Lateral low ankle sprain

Among all ankle sprains, lateral ankle ligament sprains are reported to be the most common, compromising 80.2% of all ankle sprains among professional basketball players.¹³ Lateral ankle sprains are also much more likely to be produced by a contact mechanism such as stepping on another player's foot or general contact with another

Correspondence: Jack M. Haglin, Mayo Clinic Alix School of Medicine, 13400 E Shea Blvd, Scottsdale, AZ 85259, USA.

E-mail: haglin.jack@mayo.edu

Key words: Ankle, Sports, Basketball, Rehabilitation.

Contributions: MLM: Project oversight, literature review, primary writing; LMH: Project oversight, literature review, primary writing, editing. JDH, MBA: Project oversight, literature review, primary and secondary writing, editing, clinical insight. AC: Project oversight, literature review, primary and secondary writing, editing, clinical insight, project conceptualization.

Conflict of interest: The authors declare no potential conflict of interest.

Funding: None.

Availability of data and materials: Data and materials are available by the authors.

Received for publication: 16 February 2021.
Accepted for publication: 27 March 2021.

This work is licensed under a Creative Commons Attribution NonCommercial 4.0 License (CC BY-NC 4.0).

©Copyright: the Author(s), 2021
Licensee PAGEPress, Italy
Orthopedic Reviews 2021;13:9108
doi:10.4081/or.2021.9108

player (71.2%).¹³ Additionally, professional basketball players younger than 26 years old experience a higher incidence of lateral ankle sprains when compared to players 26 years old or older.¹³ Interestingly, the prevalence of lateral ankle sprains has declined over the past three decades while the prevalence of high ankle sprains has risen.^{13,14}

Lateral ankle sprains are caused by excess inversion of the ankle joint which creates stress on the anterior talofibular ligament, calcaneofibular ligament, and the posterior talofibular ligament. The severity of the sprain may be rated based upon how much damage these ankle ligaments sustain. The majority of lateral ankle sprains do not require surgical intervention and can be treated nonoperatively. The first step in lateral ankle sprain management is to acutely minimize the degree of swelling and inflammation in the ankle. This is most effectively achieved by employing the RICE protocol (rest, ice, compression, and elevation), particularly for the first 24-48 hours.^{15,16} For more severe sprains, such as Grade 2 or 3, immobilization with a wrap or bracing device may also be employed for

the first few days to weeks to minimize pain and further injury. The athlete may implement the use of crutches initially and transition to a walking boot as soon as weight-bearing can be safely tolerated.

Rehabilitation begins with the implementation of proprioceptive training and muscle strengthening at 1-2 weeks post sprain. Closed chain lower extremity exercises can also be done bilaterally at this time. In weeks 2-3 post injury, unilateral closed chain exercises should be implemented along with straight line jogging and running. Braced, sport specific activities can usually be incorporated in weeks 3-4 depending on the severity of the initial injury. Full rehabilitation for moderate to severe sprains is usually accomplished by 6-8 weeks, at which time the athlete can safely return to competition.¹⁷ However, a history of previous sprains in an athlete should be considered as this may increase the likelihood of a subsequent.¹⁸

Medial low ankle sprain

Medial ankle sprains are much less common than lateral sprains, only compromising 7.8% of all ankle sprains in professional basketball players.¹³ Like lateral ankle sprains, medial sprains are also more likely to be caused by a contact mechanism (63.0%). However, medial ankle sprains were the most likely ankle sprain type to be caused by a noncontact mechanism (37.0%).¹³

The medial ankle is primarily supported by the deltoid ligament. Sprains of this ligament are typically caused by excessive eversion and dorsiflexion of the ankle joint. Due to the large biomechanical forces that must be present to cause damage to the deltoid ligament, fibular or medial malleolus fractures may also be present which may lead to a more severe injury that is difficult to recover from.¹⁹ Like lateral ankle sprains, medial sprains are also typically treated nonoperatively. However, if the ankle is chronically unstable, deltoid ligament reconstruction may be required, but this is uncommon. Acutely, the RICE protocol should be used to reduce the amount of swelling, pain, and inflammation in the ankle. An x-ray of the ankle may also be performed to check for coexisting fractures which may need surgical reduction. If no fractures are present, the ankle is usually immobilized with a cast or boot and no weightbearing for the first 1-2 weeks.²⁰

In weeks 2-3, low intensity, low impact exercise may be started (e.g. exercise bike) along with isolated proprioceptive training and light muscular strengthening. Gradually, the use of an elliptical machine may also be incorporated as the athlete progresses and begins to get more range of

motion and stability in the ankle. Straight light running is then begun and usually becomes asymptomatic in the first 3-4 weeks. However, sport specific movements such as cutting, planting, and jumping may be painful for months post-injury. Moreover, the use of an ankle stabilizing brace or wrap is also particularly important in an athlete's return to play. An athlete's rehabilitation can vary widely with a medial ankle sprain and may take upwards of 3-6+ months.²⁰

High ankle sprain

High ankle sprains are the least common classification of ankle sprain among professional basketball players making up only 4.1% of all sprains. However, they are among the most severe ankle injuries and often result in more missed games and increased time to return when compared to medial or lateral ankle sprains.¹³ The prevalence of high ankle sprains among NBA players has also risen over the past several decades.

High ankle sprains, also known as syndesmotic sprains, involve the disruption of the complex of connective tissue that bridges the tibia and fibula. This syndesmosis provides stability to the mortise of the talocrural (ankle) joint. The mechanism of injury almost universally involves forceful external rotation of the foot and ankle while the leg is in a planted position (e.g. rapid internal pivoting of an externally planted foot). This creates strain on the syndesmosis when the talus generates a separating pressure in the lower tibia and fibula. Unlike medial and lateral ankle sprains, surgical repair of high ankle sprains is more com-

mon and may be indicated if a fracture is present or if the syndesmosis is significantly disrupted.²¹ The stability of the syndesmosis should be evaluated on lateral stress radiographs to evaluate for widening of the tibiofibular clear space indicating instability.²¹ Surgical repair of the syndesmosis via either screw fixation or suture button have been shown to have high success rates and may lead to less long term, chronic pain and instability.²²

Whether treated surgically or non-surgically, the rehabilitation process for high ankle sprains is similar. Acutely, the ankle is treated with the RICE protocol and immobilization in a walking boot, cast, or wrap. In immobilization, it is important to stabilize the syndesmosis by limiting external rotation. This period is also accompanied by non-weightbearing or limited weightbearing for 1-2 weeks. Full weightbearing is recommended when the athlete can tolerate ambulation with minimal discomfort. Proprioceptive training and muscle strengthening is also indicated in the acute and subacute phase to facilitate recovery and preserve functional ability. When the athlete can comfortably jog in a straight line and hop with minimal discomfort, sport specific training and drills can be performed with substantial modification in intensity.²² Full recovery can vary substantially among athletes with previous research suggesting 6-8+ weeks until a return to play can be recommended. Chronic pain and instability is particularly common among athletes with previous high ankle sprains which further emphasizes the need for proper management and rehabilitation of these complex injuries.²²

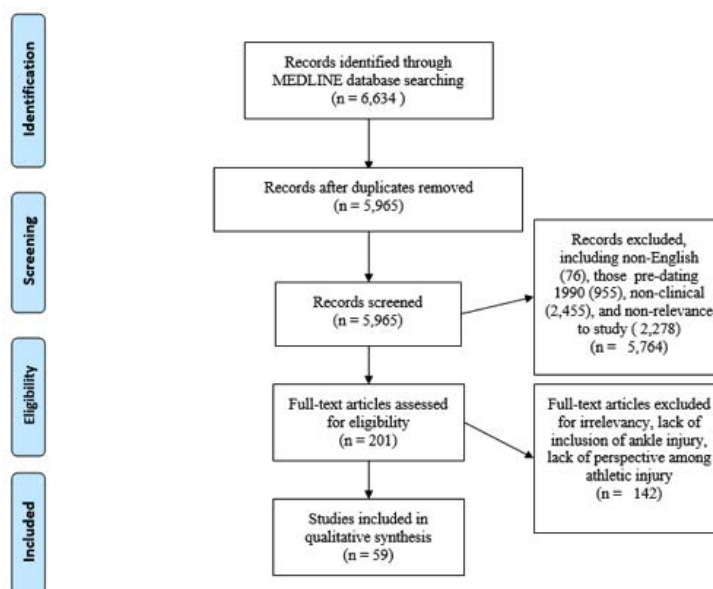


Figure 1. PRISMA flow diagram for article selection methodology.

Ankle fracture

Stress fracture

Overuse injuries such as stress fractures are frequently encountered due to the repetitive stresses that basketball requires. In a study conducted on NBA players between 2005 and 2015, 76 lower extremity bony stress injuries were identified with 55.0% involving the foot and 21.1% involving the ankle or fibula.²³ In this study, a stress fracture resulted in a mean of 25.1 games missed and approximately 30% of athletes were unable to return to their previous level of play post-injury.²³ While stress fractures

in the ankle and foot are less common than other musculoskeletal injuries, they can be debilitating injuries and linger for weeks to months if not properly managed and rehabilitated.

Stress fractures are most often caused by overuse of the foot and ankle by engaging in frequent, repetitive motions such as running, jumping, cutting, or pivoting that cause inflammation and microscopic trauma that progresses to a small fracture over time. The most common bones to experience a stress fracture in the ankle are the navicular bone, talus, and the lower tibia and fibula.²⁴ An x-ray is used to diagnose a stress fracture, but these fractures may be

difficult to detect. If an x-ray does not show evidence of a stress fracture, but clinical suspicion is strong, MRI or CT scan may need to be performed. In professional basketball players, stress fractures are routinely treated surgically. Conservative management often leads to an increased risk of refracture and surgical treatment typically offers athletes a quicker return to competition.²³ When a stress fracture is identified, it should be treated acutely with the RICE protocol. Crutches may also be employed in the first 1-2 weeks post-injury. Non-operatively, a stiff soled shoe, walking boot, or orthotic ankle brace should be used to stabilize the ankle and allow the nondisplaced

Table 1. Summary of common ankle injuries among basketball players and recommendations.

Injury	Mechanism	Treatment	Return to Play
Lateral low ankle sprain	Excess inversion of the ankle joint which creates stress on the anterior talofibular ligament, calcaneofibular ligament, and the posterior talofibular ligament.	RICE protocol (rest, ice, compression, and elevation), particularly for the first 24-48 hours and non-operative management. For more severe sprains, such as Grade 2 or 3, immobilization with a wrap or bracing device may also be employed.	Proprioceptive training, muscle strengthening in first 1-2 weeks post sprain. At 2-3 weeks can introduce straight line jogging and running as tolerated. Braced, sport specific activities incorporated in weeks 3-4. Full return to play expected at 6-8 weeks
Medial ankle sprain	Excessive eversion and dorsiflexion of the ankle joint which creates stress on the deltoid ligament.	ICE protocol with 1-2 weeks of immobilization via cast or walking boot with no weightbearing and non-operative management. If fractures are present or the joint is chronically unstable, fixation and deltoid ligament reconstruction may be necessary.	Low intensity and low impact exercise with concurrent proprioceptive training and light muscular strengthening in weeks 2-3. Introduce straight line running in weeks 3-4. Sport specific movements may be painful for months post-injury and use of ankle stabilizing braces are recommended. Full return to play expected at 3-6+ months.
High ankle sprain	Forceful external rotation of the foot and ankle while the leg is in a planted position, creating a strain on the syndesmosis when the talus generates a separating pressure in the lower tibia and fibula.	RICE protocol, immobilization via cast or walking boot, and non-weightbearing or limited weightbearing for 1-2 weeks. Be sure to stabilize syndesmosis by limiting external rotation. If a severe syndesmotoc disruption or a fracture is present, surgical screw fixation or suture button is recommended. Otherwise, manage non-operatively.	Rehabilitation timelines may vary substantially. Begin proprioceptive and muscle strengthening exercises early in the acute and subacute phases. Begin full weightbearing and straight-line jogging/running as the athlete can tolerate it. When the athlete can hop on one foot and run in a straight-line with no pain, begin modified intensity sport specific training. Full return to play expected in 6-8+ weeks.
Stress fracture	Overuse of the foot and ankle by engaging in frequent, repetitive motions that cause inflammation and microscopic trauma that progresses to a small fracture over time.	RICE protocol and non-weightbearing on crutches for 1-2 weeks. Non-operatively, a stiff soled shoe, walking boot, or orthotic brace is used to stabilize the foot/ankle and allow for good alignment and healing. Operative management for elite athletes includes screw fixation with possible bone graft.	Bone stimulating devices such as electromagnetic or ultrasound stimulation may be used to promote bone healing. Once the ankle pain is resolved, begin strengthening exercises like banded resistance training, proprioceptive training, and straight-line jogging. Slowly introduce this increased activity over a 4-6 week timespan. Average return to play is expected in 3.8 months with operative management or 5.6 months with non-operative management.
Jones fracture	Significant adduction of the foot with a simultaneously lifted heel.	RICE protocol and if the fifth metatarsal fracture is nondisplaced, a conservative approach can be taken with 6-8 weeks of non-weightbearing in a short leg cast. Surgical intervention in elite athletes may include the use of intermedullary screw fixation, low profile plating, or tension band constructs.	One-week post-surgery, modified weightbearing activities may begin along with general lower extremity body weight exercises like leg lifts. In weeks 2-6, full weightbearing, stretching, and resistance band exercises can be started when the athlete no longer experiences discomfort or pain. In weeks 6-8, light activity and functional weightbearing activities are started, but high impact activity should be avoided. By week 8, sport-specific training can likely begin, but the progression to full activity should be gradual. Full return to play expected in 8-10+ weeks.
Weber Type A fracture	Excessive adductive force upon a supinated foot.	RICE protocol and utilization of a walking cast until the fibula has healed if managed non-operatively. If displaced fractures are present, ORIF is recommended.	Full return to play is expected in 8 weeks.
Weber Type B fracture	Forced external rotation on a supinated foot.	RICE protocol and operative vs. nonoperative management is determined by the degree of fracture displacement or ankle instability. However, both options may offer similar outcomes.	Full return to play is expected in 8 weeks.
Weber Type C fracture	Excessive external rotation on a pronated foot.	RICE protocol and likely operative management with ORIF.	Full return to play is expected in 8 weeks.
Achilles tendon rupture	Forced dorsiflexion of the ankle with simultaneous contraction of the gastrocnemius-soleus complex.	RICE protocol and operative management in all athletes.	Splint or cast for 1-2 weeks post-surgery. Begin functional rehabilitation program with modified weightbearing soon after. Light stretching, muscle strengthening exercises, and full weightbearing started at 6 weeks as tolerated. At three months, more intense muscle strengthening and proprioceptive training can be initiated (isokinetic exercises, balance board, stair climbing, and isotonic plantar and dorsiflexion exercises). Full return to play is expected in 6 to 9 months.

fracture to heal properly and in good position. Further, an orthotic shoe modification may be utilized so that excess stress can be unloaded from the lateral foot and ankle.²⁵ This modification will place the fracture in an optimal biomechanical position to heal and lower the likelihood of a nonunion or further damage. Surgical intervention is typically reserved for failure of conservative management, or among elite athletes such as NBA players, particularly with navicular stress fractures.²⁶ Navicular stress fractures account for 25% of all stress fractures and have a predilection for young, male athletes.²⁶ Studies have shown that navicular stress fractures were slower to heal, had higher nonunion rates, and resulted in a slower return to activity when managed conservatively.^{27,28} Surgical treatment in these cases, especially among athletes, is recommended and typically involves screw fixation with a possible bone graft.²⁹ The average return to play after surgical intervention is 3.8 months versus 5.6 months with conservative treatment.³⁰

Bone stimulating devices that employ electromagnetic or ultrasound stimulation may also be incorporated in the healing process either to complement conservative management or post-operatively.³¹ These devices create microscopic mechanical stresses that accelerate bone formation and healing, but evidence is limited on the long term effectiveness.³² Once the ankle pain is completely resolved, strengthening exercises and light activity may be resumed. This includes banded resistance training, low impact exercise, proprioceptive training, and straight-line jogging. However, the gradual reintroduction of activity should span the course of 4-6 weeks. A return to activity too soon may reinjure the ankle and cause the bone to re-fracture.²⁴

It is also worth noting that vitamin D supplementation plays an important role in stress fracture management and prevention. Adequate levels of vitamin D, either through sunlight exposure or exogenous intake in food or supplements, has been shown to decrease the incidence of stress fractures in active individuals.³³⁻³⁵ A serum 25(OH)D level should be obtained in athletes, especially those with an increased risk of developing a stress fracture. If a deficiency exists, vitamin D supplementation should be given to avoid future injury and promote a quicker recovery if a stress fracture is already present.³⁶

Jones fracture

There are relatively high rates of Jones fractures among professional basketball players, and they are widely dreaded as they

may have profound impacts on an athlete's ability to return to play. In a study conducted between 1994 and 2013, 37 players were identified who had a confirmed Jones fracture diagnosis, and nearly 15% of them did not return to an NBA game after the season in which the injury was sustained.³⁷

A Jones fracture is defined as a transverse diaphyseal fracture of the proximal fifth metatarsal. This area of the ankle and foot has a limited blood supply which makes recovery complicated and difficult in some situations. Up to 15 to 30% of fractures have a nonunion. Jones fractures are caused when the foot is significantly adducted with a lifted heel. This type of movement usually accompanies abrupt changes in direction.³⁸ X-ray imaging is used to evaluate these fractures and may help the physician determine whether operative or non-operative treatment is required. Follow up with advanced imaging such as CT or MRI may be indicated if bony bridging cannot be adequately appreciated on traditional radiographs.²³ If the fifth metatarsal fracture is nondisplaced, a conservative approach can be taken with 6-8 weeks of non-weightbearing in a short leg cast. However, in displaced fractures or in high level athletes such as professional basketball players, surgical intervention may be the most appropriate treatment in order to accelerate the athletes return to play and to avoid bony nonunion risks or chronic injury.³⁸

Surgical intervention may include the use of intermedullary screw fixation, low profile plating, or tension band constructs.³⁸ In the first week post-surgery, modified weightbearing activities may begin along with general lower extremity body weight exercises like leg lifts. In weeks 2-6, full weightbearing can be started when the athlete no longer experiences discomfort or pain. Follow up x-rays are also important to ensure that the bone is healing properly. During this period, foot and ankle stretching and resistance band training is recommended. In weeks 6-8, light activity and functional weightbearing activities are started, but high impact activity should be avoided. By week 8, sport-specific training can likely begin, but the progression to full activity should be gradual and may vary from athlete to athlete.³⁹

Ankle fractures (Weber type A, B, and C)

Acute ankle fractures are relatively uncommon injuries in basketball players, accounting for roughly 0.5% of injuries

among professional basketball players.³ These injuries are debilitating and often result in extended periods of missed play among athletes. Given the heterogeneity of fracture types and associated outcomes, the typical timing of return to play is not well established for these injuries.⁴⁰ Treatment is often determined with an athlete-specific and injury-specific decision process. In general, these fractures can often be classified under the Danis-Weber classification system. The classification scheme, under which fractures are described as Weber A, B, or C, has been demonstrated to guide severity of injury and associated course of treatment with high interobserver reproducibility.⁴¹

Weber type A fractures

Weber type A fractures are lateral fibular fractures that occur *below* an intact syndesmosis below the talar dome. Such fractures most often occur as a result of an abduction force upon the supinated foot.⁴² This injury mechanism creates excess tension on the lateral collateral ligaments, resulting in rupture of the lateral collateral ligaments or an avulsion pull-off fracture of the lateral malleolus below the syndesmosis. These injuries are typically stable, with an intact tibiofibular syndesmosis and intact deltoid ligament. As such, these fractures rarely require surgical intervention. However, the force transferred across the ankle may also result in oblique, push off fractures of the medial malleolus and it is important to assess the lateral malleolus via radiographic imaging and deep palpation.

Regarding treatment, any stable Weber type A ankle fracture with non-displaced or minimally displaced avulsion fracture of the distal fibula and no medial lesion upon examination or radiographic evaluation should be treated with a walking cast until the fibula has healed. Athletes with such injuries can usually return to play by 8 weeks. Indications for surgical treatment via Operative Fixation and Internal Fixation (ORIF) of such injuries includes the presence of fracture displacement or significant instability at the lateral malleolus.

Weber type B fractures

Weber type B fractures are lateral fibular fractures that occur *at the level* of the syndesmosis.⁴² As a result, these injuries result in a partial, or occasionally complete, rupture of the syndesmosis. Such fractures most often occur as a result of forced external rotation on the supinated foot. This injury mechanism is often accompanied by rupture of the anterior syndesmosis, oblique or spiral fracture of the fibula, rupture of the posterior malleolus, and potential avulsion fracture of the medial malleolus.

Additionally, the deltoid ligament may be torn. These injuries result in variable stability of the syndesmosis, and adequate workup and assessment of stability is vital to determine treatment.

As the presence of instability may be an indication for operative treatment of such fractures, stress radiographs and manual stress testing should be performed in all cases in which such an injury is suspected. Widening of the distal tibiofibular joint indicates syndesmotic injury and instability, and ORIF is most often performed in such cases. Although the literature is not entirely conclusive regarding optimal treatment for these fractures, it is widely accepted that conservative, non-operative treatment with a walking cast can be pursued in isolated, stable Weber type B fractures if there is less than 3mm of fibular displacement without medial injury.⁴³ Indications for operative treatment include syndesmotic instability as indicated on radiographic or manual stress test, fibular displacement over 3mm, displacement of medial fracture, or deltoid ligament injury often indicated by over 5mm of medial clear space on static radiographs.⁴³ For unstable but otherwise nondisplaced and isolated lateral malleolar Weber B fractures, recent literature has demonstrated that equivalent outcomes can be achieved with either non-operative or operative management.⁴⁴ In these cases, treatment must be tailored to the individual characteristics and goals of the athlete.

Weber type C fractures

Weber type C fractures are lateral fibular fractures that occur *above* the syndesmosis, and nearly always are accompanied by a complete rupture of the syndesmosis with resulting instability of the ankle.⁴² Such fractures typically are the result of excessive external rotation on the pronated foot. In addition to the fibula fracture above the syndesmosis, this injury mechanism often causes avulsion of the medial malleolus, rupture of the anterior syndesmosis, and avulsion of the posterior malleolus. These injuries are typically unstable, and nearly always require surgical intervention with ORIF. The literature demonstrates equivalent outcomes may be achieved with or without the additional use of a syndesmotic screw when treating such fractures, and the decision to stabilize the syndesmosis can be made on an individual basis.⁴⁵ It is important to set realistic expectations with athletes requiring surgical repair of these injuries, as recent study indicates that as few as 25% of athletes return to the same level of play after one year following ORIF of unstable ankle fractures.⁴⁶

Achilles tendon rupture

The Achilles tendon (AT) is a less commonly injured structure in the ankle, but consequences of injury can be catastrophic for professional basketball players. The prevalence of AT ruptures among all sports is highest in basketball, and basketball play is actually the cause of 42.6% of all AT ruptures among individuals under age 60 in the United States.⁴⁷

The mechanism of injury for AT ruptures involves forced dorsiflexion of the ankle with simultaneous contraction of the gastrocnemius-soleus complex.⁴⁸ AT ruptures and partial ruptures are almost exclusively treated with surgical repair. This is especially true in high level athletes who desire to return to competition due to the ability of surgery to better restore dorsiflexion and plantarflexion peak torque in comparison to nonoperative treatment.⁴⁹

Post-operatively, an athlete may be placed in a splint or cast for the first 1-2 weeks to immobilize the AT. Shortly thereafter, a functional rehabilitation process that involves early modified weightbearing will begin.⁴⁸ At approximately 6 weeks post-surgery, light stretching and muscle strengthening exercises can be initiated. Full weightbearing in a walking boot may also begin at this time if tolerated. At three months, more intense muscle strengthening and proprioceptive training can be initiated. This will include isokinetic exercises, balance board, stair climbing, as well as isotonic plantar and dorsiflexion exercises. Full recovery can be variable between athletes, but a timeline of 6 to 9 months may be permitted.⁵⁰

Prevention

Along with the increase in recent epidemiologic studies regarding basketball injuries as presented in this review, there has also been more attention paid to prevention of these injuries. The three primary modalities for preventing ankle injury in basketball players discussed in the literature include preventative balance exercises, proprioception training programs, and the use of preventative external supports such as ankle tape, bracing, or orthosis. These modalities have all been proven to reduce the incidence of ankle fracture in basketball players to varying degrees.

External supports such as taping and bracing are the most common preventative method among basketball players, with several randomized controlled trials demon-

strating their effectiveness at reducing injury risk to the ankle.⁵¹⁻⁵⁴ The effectiveness of such measures comes from both providing mechanical support to the soft tissue of the ankle, as well as providing improvements in proprioceptive function and awareness at the joint to increase control and decrease excessive motion.⁵⁵ Despite their success at injury prevention, studies have demonstrated bracing and taping can cause skin irritation, as well as be uncomfortable for players and potentially impact their ability.^{55,56}

A promising area of current research includes preventative proprioceptive and kinematic training programs. Such programs utilize devices such as tilt boards or balance beams to simulate multiple planes of ankle motion on a weight bearing foot.⁵⁷ These programs are being increasingly studied, especially at the high school level. Initial reports have demonstrated similar effectiveness to taping and bracing at preventing ankle injury among such programs.^{58,59} Given the high incidence of ankle injury among basketball players discussed in this article, along with relative inconsistency of preventative recommendations, increased study and adoption of preventative strategies is needed moving forward.

Conclusions

Basketball is among the world's most popular sports and is continuing to see growth in the U.S. and worldwide. With this growth and an increasingly explosive and fast-paced playstyle comes an increased rate of injury. The most common injuries seen in professional basketball athletes are ankle injuries. The ankle is a complex joint with many associated orthopedic pathologies and opportunities for injury. This review provides sports medicine practitioners with a concise and educational resource that can be used in the effective management and rehabilitation of the most common ankle injuries in professional basketball.

References

1. Conn JM, Annest JL, Gilchrist J. Sports and recreation related injury episodes in the US population, 1997-99. *Inj Prev* 2003;9:117-23.
2. Finch C, Valuri G, Ozanne-Smith J. Sport and active recreation injuries in Australia: evidence from emergency department presentations. *Br J Sports Med* 1998;32:220-5.

3. Drakos MC, Domb B, Starkey C, Callahan L, Allen AA. Injury in the national basketball association: a 17-year overview. *Sports Health* 2010;2:284-90.
4. Soto PCM de, Guillén JFA, León AÁR, Zurita MJB, Quintanilla IM. Epidemiology of injury in a non professional basketball club during a regular season: a prospective study. 2018.
5. Weiss KJ, McGuigan MR, Besier TF, Whatman CS. Application of a Simple Surveillance Method for Detecting the Prevalence and Impact of Overuse Injuries in Professional Men's Basketball. *J Strength Cond Res* 2017;31:2734-9.
6. Sprung S. Inside The NBA's Push To Make Basketball The World's Most Popular Sport. *Forbes*. Accessed August 29, 2020. <https://www.forbes.com/sites/shlomosprung/2019/03/04/nba-china-ceo-derek-chang-takes-us-inside-nbas-push-to-make-basketball-worlds-most-popular-sport/>
7. The NBA's Growing Popularity Scores Wins for Sponsors. Accessed August 29, 2020. <https://www.nielsen.com/us/en/insights/article/2018/the-nbas-growing-popularity-scores-wins-for-sponsors>
8. Fong DT-P, Hong Y, Chan L-K, et al. A systematic review on ankle injury and ankle sprain in sports. *Sports Med Auckl NZ* 2007;37:73-94.
9. McKay GD, Goldie PA, Payne WR, Oakes BW. Ankle injuries in basketball: injury rate and risk factors. *Br J Sports Med* 2001;35:103-8.
10. Andreoli CV, Chiaramonti BC, Biruel E, et al. Epidemiology of sports injuries in basketball: integrative systematic review. *BMJ Open Sport Exerc Med* 2018;4:e000468.
11. McKay GD, Payne WR, Goldie PA, et al. A comparison of the injuries sustained by female basketball and netball players. *Aust J Sci Med Sport* 1996;28:12-7.
12. Yeung MS, Chan KM, So CH, Yuan WY. An epidemiological survey on ankle sprain. *Br J Sports Med* 1994;28:112-6.
13. Herzog MM, Mack CD, Dreyer NA, et al. Ankle Sprains in the National Basketball Association, 2013-2014 Through 2016-2017: *Am J Sports Med*. Published online August 7, 2019. doi:10.1177/0363546519864678
14. Starkey C. Injuries and Illnesses in the National Basketball Association: A 10-Year Perspective. *J Athl Train* 2000;35:161-7.
15. Publishing HH. Recovering from an ankle sprain. *Harvard Health*. Accessed September 5, 2020. https://www.health.harvard.edu/pain/recovering_from_an_ankle_sprain
16. Wolfe MW, Uhl TL, Mattacola CG, McCluskey LC. Management of Ankle Sprains. *Am Fam Physician* 2001;63:93.
17. Al-Mohrej OA, Al-Kenani NS. Acute ankle sprain: conservative or surgical approach? *EFORT Open Rev* 2016;1:34-44.
18. D'Hooghe P, Cruz F, Alkhelaifi K. Return to Play After a Lateral Ligament Ankle Sprain. *Curr Rev Musculoskelet Med* 2020;13:281-8.
19. Wade FE, Mok K-M, Fong DT-P. Kinematic analysis of a televised medial ankle sprain. *Asia-Pac J Sports Med Arthrosc Rehabil Technol* 2018;12:12-6.
20. Essential Insights In Treating Medial Ankle Sprains. *Podiatry Today*. Accessed September 5, 2020. <https://www.podiatrytoday.com/essential-insights-treating-medial-ankle-sprains>
21. van den Bekerom MP. Diagnosing syndesmotic instability in ankle fractures. *World J Orthop* 2011;2:51-6.
22. Williams GN, Allen EJ. Rehabilitation of Syndesmotic (High) Ankle Sprains. *Sports Health* 2010;2:460-70.
23. Khan M, Madden K, Burrus MT, et al. Epidemiology and Impact on Performance of Lower Extremity Stress Injuries in Professional Basketball Players. *Sports Health* 2017;10:169-74.
24. Foot & Ankle Stress Fractures: Causes, Symptoms, Treatments. *Hospital for Special Surgery*. Accessed September 6, 2020. https://www.hss.edu/conditions_stress-fractures-foot-ankle.asp
25. Darabos N, Obrovac K, Knez N, et al. Combined surgical therapy and orthotic management of stress and tuberosity avulsion fracture of the fifth metatarsal bone: a case report. *J Am Podiatr Med Assoc* 2009;99:529-35.
26. Shakked RJ, Walters EE, O'Malley MJ. Tarsal navicular stress fractures. *Curr Rev Musculoskelet Med* 2017;10:122.
27. Fitch K, Blackwell J, Gilmour W. Operation for non-union of stress fracture of the tarsal navicular. *J Bone Joint Surg Br* 1989;71-B:105-10.
28. Mallee WH, Weel H, Dijk CN van, et al. Surgical versus conservative treatment for high-risk stress fractures of the lower leg (anterior tibial cortex, navicular and fifth metatarsal base): a systematic review. *Br J Sports Med* 2015;49:370-6.
29. Coris EE, Lombardo JA. Tarsal Navicular Stress Fractures. *Am Fam Physician* 2003;67:85-90.
30. Khan KM, Brukner PD, Kearney C, et al. Tarsal Navicular Stress Fracture in Athletes. *Sports Med* 1994;17:65-76.
31. Haglin JM, Jain S, Ertorai AEM, Daniels AH. Bone Growth Stimulation: A Critical Analysis Review. *JBJS Rev* 2017;5:e8.
32. Mayer SW, Joyner PW, Almekinders LC, Parekh SG. Stress Fractures of the Foot and Ankle in Athletes. *Sports Health* 2014;6:481-91.
33. Miller JR, Dunn KW, Ciliberti LJ, et al. Association of Vitamin D With Stress Fractures: A Retrospective Cohort Study. *J Foot Ankle Surg* 2016;55:117-20.
34. Lappe J, Cullen D, Haynatzki G, et al. Calcium and Vitamin D Supplementation Decreases Incidence of Stress Fractures in Female Navy Recruits. *J Bone Miner Res* 2008;23:741-9.
35. Ogan D, Pritchett K. Vitamin D and the Athlete: Risks, Recommendations, and Benefits. *Nutrients* 2013;5:1856-68.
36. McCabe MP, Smyth MP, Richardson DR. Current concept review: vitamin D and stress fractures. *Foot Ankle Int* 2012;33:526-33.
37. Begly JP, Guss M, Ramme AJ, et al. Return to Play and Performance After Jones Fracture in National Basketball Association Athletes. *Sports Health* 2016;8:342-6.
38. Smidt KP, Massey P. 5th Metatarsal Fracture (Jones Fracture, Dancers Fracture). In: *StatPearls*. StatPearls Publishing; 2020. Accessed September 6, 2020. <http://www.ncbi.nlm.nih.gov/books/NBK544369/>
39. Fifth metatarsal fracture (Jones fracture) rehab protocol. Published August 25, 2018. Accessed September 6, 2020. <https://www.stoneclinic.com/fifth-metatarsal-fracture-rehab-protocol>
40. Del Buono A, Smith R, Coco M, et al. Return to sports after ankle fractures: a systematic review. *Br Med Bull* 2013;106:179-91.
41. Fonseca LL da, Nunes IG, Nogueira RR, et al. Reproducibility of the Lauge-Hansen, Danis-Weber, and AO classifications for ankle fractures. *Rev Bras Ortop Engl Ed* 2018;53:101-6.
42. Kennedy JG, Johnson SM, Collins AL, et al. An evaluation of the Weber classification of ankle fractures. *Injury* 1998;29:577-80.
43. Van Schie-Van der Weert EM, Van Lieshout EMM, et al. Determinants of outcome in operatively and non-operatively treated Weber-B ankle fractures.

- Arch Orthop Trauma Surg 2012;132:257-63.
44. Sanders DW, Tieszer C, Corbett B, Canadian Orthopedic Trauma Society. Operative versus nonoperative treatment of unstable lateral malleolar fractures: a randomized multicenter trial. *J Orthop Trauma* 2012;26:129-34.
 45. Kennedy JG, Soffe KE, Dalla Vedova P, et al. Evaluation of the syndesmotic screw in low Weber C ankle fractures. *J Orthop Trauma* 2000;14:359-66.
 46. Colvin AC, Walsh M, Koval KJ, et al. Return to sports following operatively treated ankle fractures. *Foot Ankle Int* 2009;30:292-6.
 47. Lemme NJ, Li NY, DeFroda SF, et al. Epidemiology of Achilles Tendon Ruptures in the United States: Athletic and Nonathletic Injuries From 2012 to 2016. *Orthop J Sports Med* 2018;6(11).
 48. Pedowitz D, Kirwan G. Achilles tendon ruptures. *Curr Rev Musculoskelet Med* 2013;6:285-93.
 49. Keating JF, Will EM. Operative versus non-operative treatment of acute rupture of tendo Achillis: a prospective randomized evaluation of functional outcome. *J Bone Joint Surg Br* 2011;93:1071-8.
 50. Torn Achilles Tendon. Sports Injuries, treatment and performance information. Published January 8, 2015. Accessed September 6, 2020. <https://www.sportsmd.com/torn-achilles-tendon/>
 51. Barrett JR, Tanji JL, Drake C, et al. High- versus low-top shoes for the prevention of ankle sprains in basketball players. A prospective randomized study. *Am J Sports Med* 1993;21:582-5.
 52. Garrick JG, Requa RK. Role of external support in the prevention of ankle sprains. *Med Sci Sports* 1973;5:200-3.
 53. Sitler M, Ryan J, Wheeler B, et al. The Efficacy of a Semirigid Ankle Stabilizer to Reduce Acute Ankle Injuries in Basketball: A Randomized Clinical Study at West Point. *Am J Sports Med*. Published online April 23, 2016. doi:10.1177/036354659402200404
 54. Tropp H, Askling C, Gillquist J. Prevention of ankle sprains. *Am J Sports Med* 1985;13:259-62.
 55. Surve I, Schweltnus MP, Noakes T, Lombard C. A fivefold reduction in the incidence of recurrent ankle sprains in soccer players using the Sport-Stirrup orthosis. *Am J Sports Med* 1994;22:601-6.
 56. Verhagen EA, van Mechelen W, de Vente W. The effect of preventive measures on the incidence of ankle sprains. *Clin J Sport Med Off J Can Acad Sport Med* 2000;10:291-6.
 57. Sheth P, Yu B, Laskowski ER, An KN. Ankle disk training influences reaction times of selected muscles in a simulated ankle sprain. *Am J Sports Med* 1997;25:538-43.
 58. Verhagen E, van der Beek A, Twisk J, et al. The effect of a proprioceptive balance board training program for the prevention of ankle sprains: a prospective controlled trial. *Am J Sports Med* 2004;32:1385-93.
 59. McGuine TA, Keene JS. The effect of a balance training program on the risk of ankle sprains in high school athletes. *Am J Sports Med* 2006;34:1103-11.