
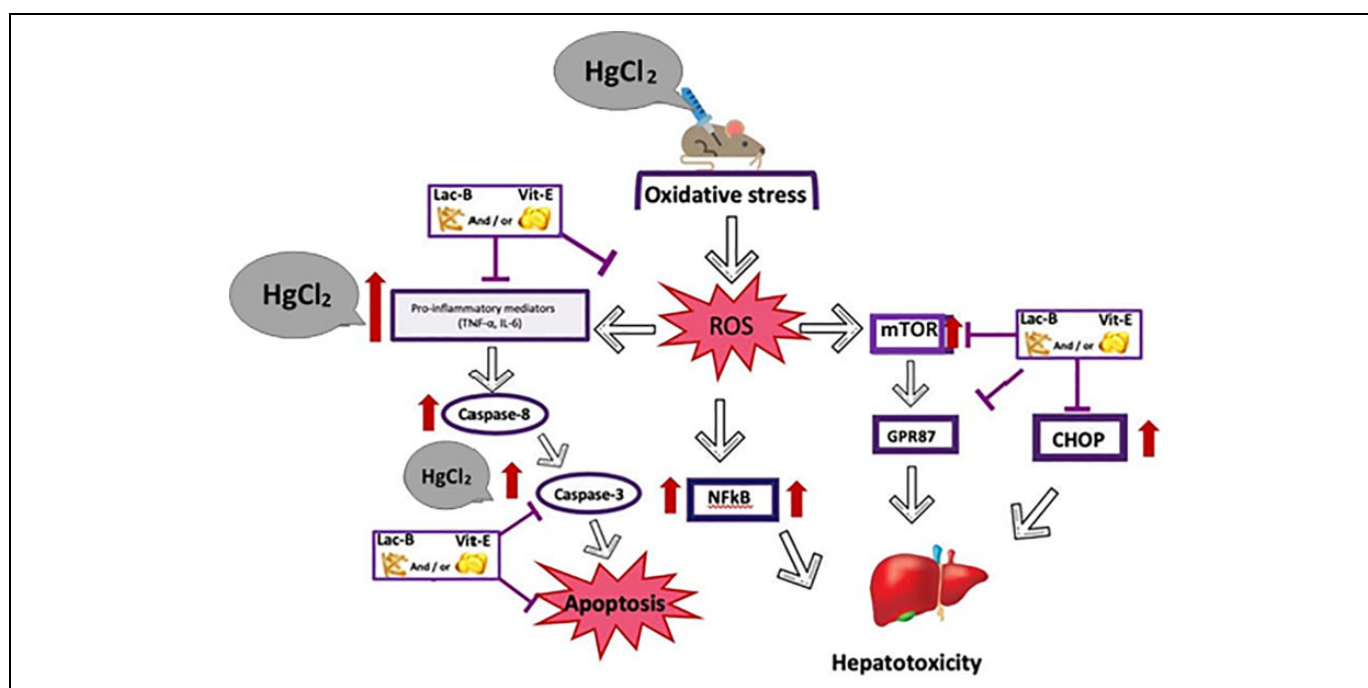


Vitamin E and *Lactobacillus* Provide Protective Effects Against Liver Injury Induced by HgCl₂: Role of CHOP, GPR87, and mTOR Proteins

Ahlam Alhusaini¹ , Shahad Alghilani², Waad Alhuqbani², and Iman H. Hasan¹

Abstract

Background and Objective: Mercury is one of the most harmful heavy metals and its toxicity causes severe multi-organ dysfunction. This study was designed to explore novel molecular pathways involved in the hepatoprotective effect of vitamin E (Vit-E) and *Lactobacillus plantarum* (Lac-B) against mercury toxicity.



¹ Pharmacology and Toxicology Department, Faculty of Pharmacy, King Saud University, Riyadh, Saudi Arabia

² Faculty of Pharmacy, King Saud University, Riyadh, Saudi Arabia

Received 11 March 2021; received revised 30 March 2021; accepted 31 March 2021

Corresponding Author:

Ahlam Alhusaini, Pharmacology and Toxicology Department, Pharmacy College, Faculty of Pharmacy, King Saud University, Riyadh, Saudi Arabia.
Email: aelhusaini@ksu.edu.sa



Creative Commons Non Commercial CC BY-NC: This article is distributed under the terms of the Creative Commons Attribution-NonCommercial 4.0 License (<https://creativecommons.org/licenses/by-nc/4.0/>) which permits non-commercial use, reproduction and distribution of the work without further permission provided the original work is attributed as specified on the SAGE and Open Access pages (<https://us.sagepub.com/en-us/nam/open-access-at-sage>).

Method: Acute hepatotoxicity was induced by administration of high dose of mercuric chloride (HgCl_2) in male rats, Vit-E or/and Lac-B were given along with HgCl_2 for 2 weeks. The effects of those antioxidants were studied focusing on their anti-apoptotic, anti-oxidative stress and anti-inflammatory efficacies. Histopathological examinations were also conducted.

Results: The administration of HgCl_2 induced liver injury which manifested by elevation in serum ALT and AST. Liver MDA, caspase-3 and TNF- α levels were markedly increased; whereas, GSH level and SOD activity were declined. HgCl_2 significantly elevated the expressions of hepatic CHOP, GPR87, NF- κ B and mTOR. Histopathological examination revealed massive hepatocyte degeneration following HgCl_2 administration. Treatment with Vit-E or/and Lac-B restored the normal levels of the previously mentioned parameters, as well as improved hepatic architecture.

Conclusion: Vit-E and Lac-B provided protective effect against HgCl_2 -induced hepatotoxicity via reduction of oxidative stress and inflammation, and downregulation of CHOP, GPR87, NF- κ B and mTOR proteins' expressions.

Keywords

mercury, hepatotoxicity, lactobacillus plantarum, vitamin E, CHOP, mTOR

Introduction

Mercury is extensively spread in the environment, which leads to a continuous human exposure to even low levels of this heavy metal.¹ People can be exposed to mercury by consumption of specific types of fish, dental amalgam or even at work.² The main source of mercury is the natural degassing of the earth's crust, including oceans and rivers. It has been documented that low level of mercury exposure caused immune system alterations and reduced mice resistance to viral infections.³ Mercury toxicity is attributed to its capability to diminish free sulfhydryl groups of GSH and other antioxidants enzymes.

Numerous studies illustrated that oxidative stress evokes various intracellular events, such as proliferation, cell-cycle arrest, and apoptosis.^{4,5} In addition, exposure to inorganic mercury can exert a dose-dependent cytotoxicity by producing high levels of H_2O_2 , which is normally quenched by pyruvate and catalase.⁶ Mercuric chloride (HgCl_2) may damage the function of many organelles such as lysosomes that keep proton gradient through the membrane and decline renal glutathione peroxidase activity with upregulation of heme oxidase function. Several studies have found increased risk of pulmonary, renal, and CNS systems among dental workers.⁷ Mercury induces disruption of the cytochrome *c* oxidase system/ATP energy function,^{8,9} and inhibits enzymes needed to change porphyrins to ATP causing progressive porphyrinuria, leading to low energy and digestive injuries.¹⁰

Many studies indicated that oxidative stress represents a dangerous event correlated to the neurotoxic effects of HgCl_2 .¹¹ The levels of various reactive species are dramatically increased upon HgCl_2 exposure.¹² Although it is broadly sulfhydryl reactive, yet signaling cascade implicated in mediating HgCl_2 -induced liver injury is not fully investigated.

This initiates our interest to study a new mechanistic role of HgCl_2 hepatotoxicity at molecular level and to find a way to protect against this toxicity using a combination of vitamin E (Vit-E) and *Lactobacillus plantarum* (Lac-B). Vit-E is considered as a major lipid soluble element in the defense system inside the cell, and it can be obtained from diet. It has a

powerful protection action against complications of various diseases due to its antioxidant role.¹³ Lac-B, a lactic acid bacterium, is used for dairy and meat fermentation, also it can be used as a probiotic with favorable actions on gut and metabolic illnesses.¹⁴

Materials and Methods

Chemicals

Vit-E and HgCl_2 were obtained from Sigma Chemical Co. (Sigma, St. Louis, MO, USA). Lac-B was obtained from local pharmacy. The primary antibodies of CHOP, GPR87, mTOR and NF- κ B were obtained from Santa Cruz (Santa Cruz Biotechnology, CA, USA).

Experimental Animals

Thirty Wistar adult male albino rats weighing 150-200 g were obtained from the Animal House, Faculty of Pharmacy, King Saud University. Animals were kept at temperature of 20-22°C; they were fed with standard rat pellet chow with free access to tap water ad libitum. The Experimental protocol was approved by the Research Ethics Committee, King Saud University (KSU-SE-19-38).

Experimental Design

After 1-week acclimation, rats were allocated into 5 groups each contains 6 rats; they were treated as follows: the first group was served as the normal control group and administered distilled water; in the second group, rats were intoxicated subcutaneously with 5 mg/kg HgCl_2 ¹⁵ once daily; the rats in the third group were treated with Vit-E at a dose of 100 mg/kg/day, orally¹⁶; the fourth group was orally treated with 6×10^{10} CFU of Lac-B 1.8701/kg in 1 mL normal saline¹⁷; and the fifth group was treated with the combination of Vit-E and Lac-B. All treatments were given daily along with HgCl_2 for 2 weeks.

After completion of all treatments, rats were subjected to a gradual concentration of CO_2 , then sacrificed by decapitation.

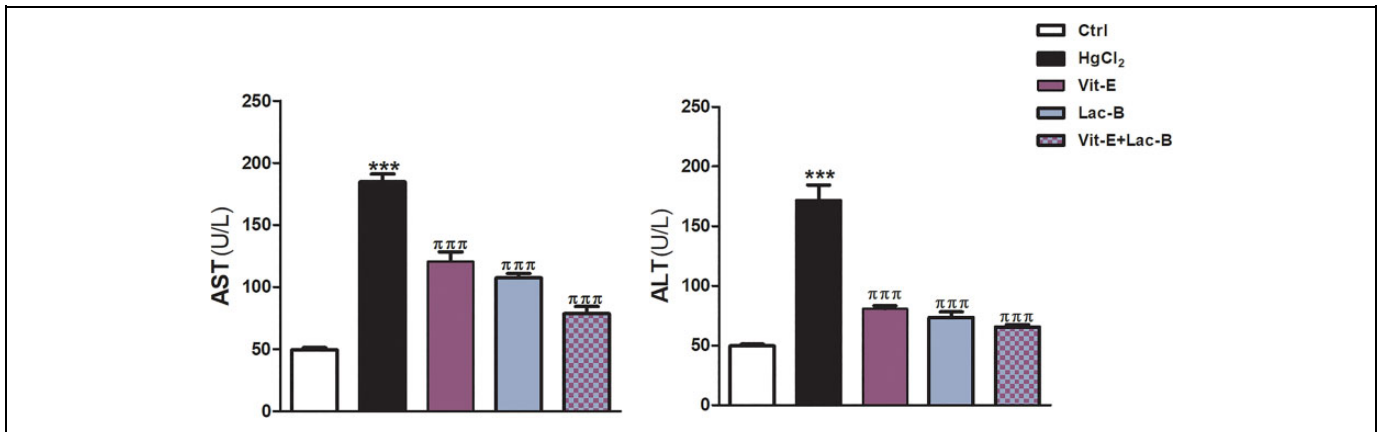


Figure 1. Vit-E, Lac-B and their combination prevents HgCl₂-induced liver injury in rats. Vit-E, Lac-B reduced serum AST and ALT in HgCl₂-intoxicated rats. The data are presented as the mean + SEM (n = 5). *** $P \leq .001$ versus control, and $\pi\pi\pi\pi P \leq .001$ versus HgCl₂-treated groups.

Blood samples were collected, and sera were separated by centrifugation at 3000 rpm for 20 min. The livers were also collected; parts of livers were homogenized in phosphate buffer to yield 20% homogenates. Then the homogenates were centrifuged for 20 min at 3000 rpm at 4°C, and the supernatants were kept at -80°C. Other parts of livers were rapidly frozen under liquid nitrogen and stored at -80°C for Western blotting. Parts of livers from each group were kept in 10% formalin for histopathological examination.

Biochemical Analysis

Examination of the liver enzymes. The activity of liver enzymes, aspartate aminotransferase (AST) and alanine aminotransferase (ALT) was measured in the serum using kits obtained from Randox (Crumlin, UK).

Determination of oxidative stress biomarkers. Malondialdehyde (MDA) was estimated in the liver tissue following the method of Mihara and Uchiyama.¹⁸ Reduced glutathione (GSH) was determined using the method of Ellman.¹⁹ Superoxide dismutase (SOD) activity was evaluated following the procedure of Marklund and Marklund.²⁰

Determination of liver inflammatory and apoptotic biomarkers. Liver tumor necrosis factor alpha (TNF- α), cysteine-aspartic acid protease 3 (caspase-3) and interleukin 6 (IL-6) levels were measured using a highly sensitive ELISA kit (Immuno-Biological Laboratories Co., Ltd. Takasaki-Shi, Gunma, Japan).

Western blot analysis. Western blots were performed to determine the proteins expressions of CHOP, GPR87, mTOR, and NF- κ B. Protein bands were visualized using the ECL-Plus detection system (Amersham Life Sciences, Little Chalfont, Buckinghamshire, UK) according to the manufacturer's instructions. Positive immunoreactive bands were quantified densitometrically and compared with control.

Histological analysis. Liver samples were fixed in 10% formaldehyde, and thinly sliced sections were used for histopathological examination using hematoxylin and eosin (H&E) stain.

Statistical Analysis

Data were expressed as mean \pm SEM for quantitative measures. The statistical comparisons were performed using 1-way analysis of variance (ANOVA), followed by Tukey-Kramer multiple comparisons test. The level of significance was set at $P < 0.05$, $P < 0.01$, and $P < 0.001$. Statistical tests were conducted using GraphPad Prism 5.00 (GraphPad Prism, San Diego, California, USA).

Results

Lac-B and/or Vit-E Retained Liver Functions in HgCl₂-Induced Hepatotoxicity

The current work showed marked elevation of the activity levels of serum ALT and AST enzymes in rat exposed to HgCl₂ compared to control rats. While the administration Lac-B and Vit-E concurrently with HgCl₂ significantly lowered the activity of liver enzymes (Figure 1).

Lac-B and/or Vit-E Attenuated Oxidative Stress, Inflammation, and Apoptosis Induced by HgCl₂

Further assessment of the hepatic protective effects of Lac-B and/or Vit-E was conducted by measuring the levels of oxidative, inflammatory, and apoptotic markers. Figure 2 shows the significant increase of MDA level and decrease of GSH and SOD following HgCl₂ intoxication; accordingly, indicated high oxidative damage. In the same figure, the administration of Lac-B and/or Vit-E markedly ameliorated the toxic effects of HgCl₂ on the previous parameters (Figure 2).

The expressions of the inflammatory biomarkers, IL-6 and TNF- α , were upregulated post HgCl₂ administration; but they reduced in Lac-B and/or Vit-E treated groups (Figure 3).

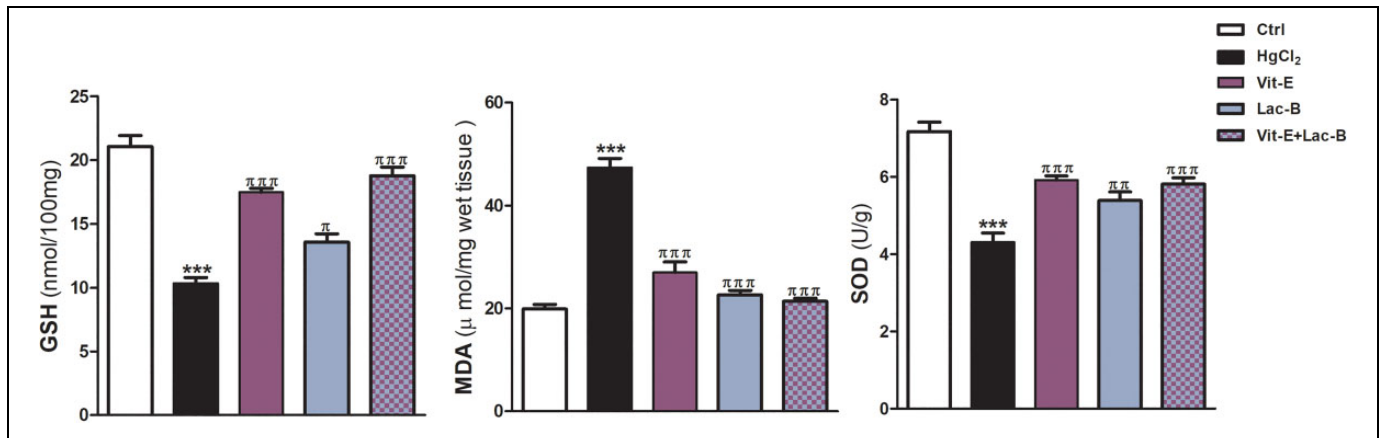


Figure 2. Vit-E, Lac-B and their combination modulate hepatic GSH, MAD and SOD against HgCl₂-induced liver injury in rats. The data are presented as the mean + SEM (n = 5). *** $P \leq .001$ versus control, and $\pi\pi\pi P \leq .001$ versus HgCl₂-treated groups.

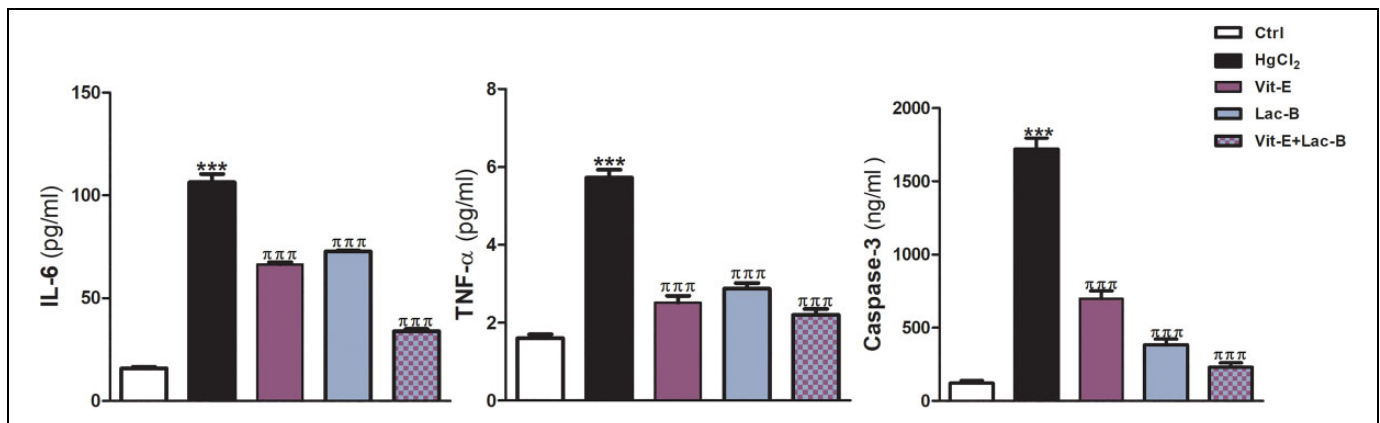


Figure 3. Vit-E, Lac-B and their combination downregulate hepatic inflammatory markers (IL-6 and TNF- α) and apoptotic marker (Caspase-3) in HgCl₂-induced liver injury in rats. The data are presented as the mean + SEM (n = 5). *** $P \leq .001$ versus control, and $\pi\pi\pi P \leq .001$ versus HgCl₂-treated groups.

Moreover, HgCl₂ intoxicated rats exhibited a significant elevation of the hepatic NF- κ B ($P \leq 0.001$) relative to control rats. On the other hand, rats received the antioxidants in question concurrently with HgCl₂ showed a significant reduction in the expression of NF- κ B (Figure 4).

In addition, HgCl₂ toxicity provoked apoptosis by causing a significant increase in capsase-3 expression in the liver of intoxicated rats ($P < 0.001$). However, the use of Lac-B and/or Vit-E produced remarkable reduction in apoptosis by down-regulating capsase-3 expression (Figure 3).

Lac-B and/or Vit-E Modulated the Expression of CHOP, GPR87, and mTOR

The CHOP, GPR87, and mTOR were significantly overexpressed following HgCl₂ intoxication compared to control group (Figure 4). Interestingly, the administration of Lac-B or Vit-E either alone or in combination downregulated the expressions of those proteins in comparison to HgCl₂ intoxicated group (Figure 4).

Lac-B and/or Vit-E Improved the Histopathological Changes Induced by HgCl₂ Overdose

The hepatoprotective effects of Lac-B and/or Vit-E were confirmed by the histological examination of liver sections stained with H&E. The liver sections from the rats of the negative control group demonstrate normal hepatocytes and normal blood sinusoids (Figure 5A). The liver section from a rat administered HgCl₂ shows moderate hepatocyte with ballooning and binucleated hepatocytes, central vein congestion (Figure 5B). The liver section from a rat administered Vit-E with HgCl₂ shows a hepatic tissue with normal structure and architecture with dilated congested sinusoids, central vein congestion (Figure 5C). The liver section from a rat administered Lac-B concurrently with HgCl₂ shows moderate healing of the necrosis and a slight decrease of the dilated sinusoids (Figure 5D). Lastly, the liver section from a rat administered a combined therapy of Vit-E and Lac-B with HgCl₂ shows a marked improvement in hepatocyte degeneration with normal sinusoids (Figure 5E).

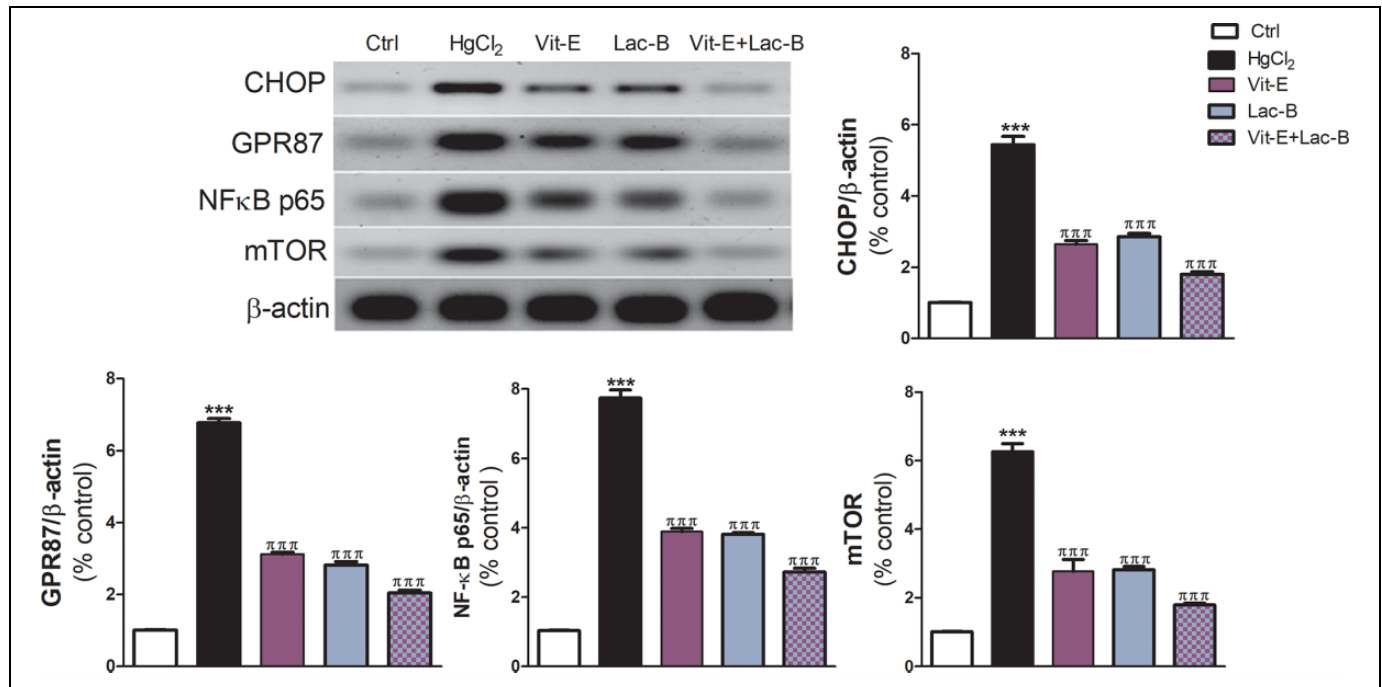


Figure 4. Representative blots of the expression of CHOP, GPR87, NF- κ B and mTOR proteins, Vit-E, Lac-B, and their combination significantly downregulated their expressions in hepatic tissues. The data are presented as the mean + SEM (n = 5). *** $p \leq .001$ versus control, and $^{***}p \leq .001$ versus HgCl₂-treated groups.

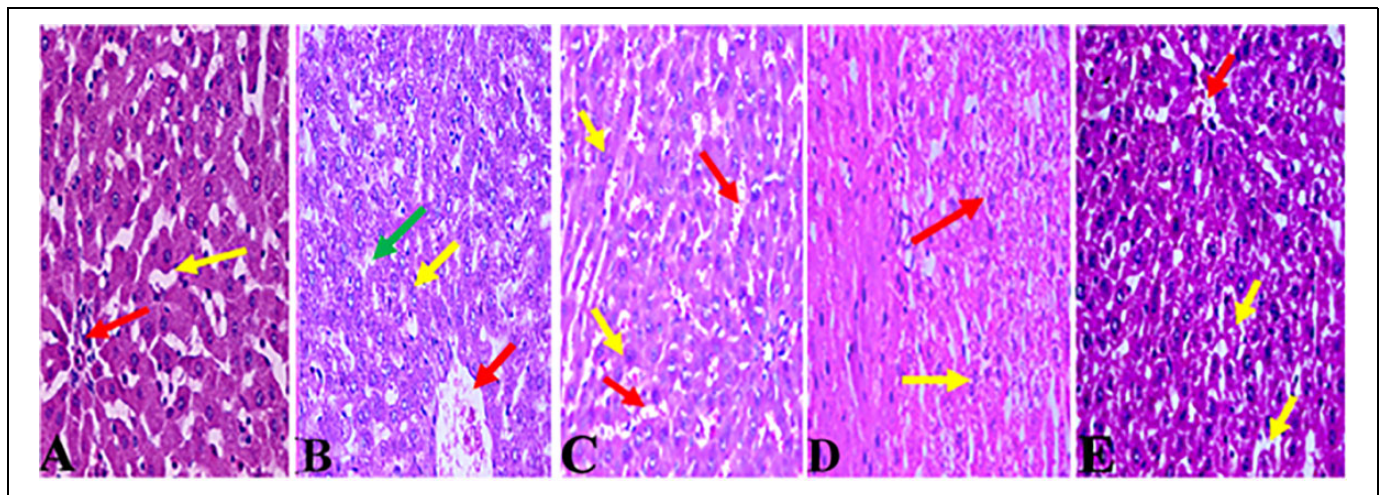


Figure 5. Light photomicrographs of liver sections stained with H&E. (A) The liver section from a negative control-treated rat shows normal hepatocytes (red arrow) with normal blood sinusoids (yellow arrow). (B) The liver section from a rat administered HgCl₂ shows moderate hepatocyte with ballooning (red arrow) and binucleated hepatocytes (yellow arrow), central vein congestion (green arrow). (C) The liver section from a rat administered Vit-E with HgCl₂ shows a hepatic tissue with normal structure and architecture with dilated congested sinusoids (red arrow), central vein congestion (yellow arrow). (D) The liver section from a rat administered Lac-B with HgCl₂ shows moderate healing of the necrosis (red arrow) and a slight decrease of the dilated sinusoids (yellow arrow). (E) The liver section from a rat administered Vit-E and Lac-B with HgCl₂ shows a marked improvement in hepatocyte degeneration (red arrow), with normal sinusoids (yellow arrow).

Discussion

Human may be exposed to HgCl₂ poisoning by multiple routes including oral, inhalation or skin exposures, since it is extensively distributed in the environment. The environmental levels of mercury are rising because of the discharge from

hydroelectric, mining and paper industries. It can be found in some skin lightening products and the filling of dental amalgam.²¹ Therefore, the aims of the current study are to examine the potential hepatoprotective effects of Vit-E and/or Lac-B against HgCl₂-induced liver damage in rats, and to further investigate the mechanisms underlying those effects.

In this study, we examined the effect of HgCl₂ intoxication on the activity of liver enzymes, and we found that HgCl₂ cause significant elevation of serum ALT and AST activities. These enzymes are considered as critical and initial markers in the diagnosis of liver injury, as these enzymes could be released into the circulating blood directly due to hepatic cell damage.²² Our results were parallel to the outcomes of previous studies which revealed the increasing of the liver enzymes activities post excessive exposure of HgCl₂.^{22,23}

Our study revealed the administration of HgCl₂ caused significant increase in the levels of oxidative stress (MDA), inflammatory (IL-6, TNF- α , and NF- κ B), and apoptotic (caspase-3) markers, while GSH level and SOD activity were lowered post HgCl₂ injection. It has been approved that when HgCl₂ is accumulated within the hepatic cells, this provokes oxidative stress and subsequent liver injury, and it is believed that the principal mechanism of hepatotoxic effect of HgCl₂ is the liberation of free radical and production of reactive oxygen species (ROS).²⁴ In addition, the inflammation is usually associated with the production of ROS,²⁵ and the inflammatory cytokines such as IL-6, TNF- α and NF- κ B are important transcription factors known to be sensitive to oxidative stress,^{26,27} see graphical abstract figure.

Additionally, our study revealed the upregulation of the protein's expressions of CHOP, GPR87, and mTOR in the liver tissues from HgCl₂ intoxicated rats. It is documented that in normal healthy conditions, CHOP is expressed at very low levels²⁸; while in diseased states the expression of CHOP is markedly increase and the apoptosis is triggered.^{28,29} Furthermore, Arfelt and colleagues documented the great relationship between the activation of NF- κ B and GPR87-mediated cancer progression.³⁰ Because mTOR is involved in the liver metabolism process of a drug,³¹ the balanced level of mTOR expression is vital for retaining hepatic cell homeostasis and prevention of liver damage and inflammation. Thus, the dysregulation of mTOR activity may result in liver injury, inflammation and even carcinogenesis.³²

The administration of Vit-E and/or Lac-B could reduce the HgCl₂-oxidative stress and prevent the overexpression of apoptotic and inflammatory biomarkers in liver tissue; moreover, using of those antioxidants improved the liver morphology. It has been demonstrated that Vit-E and Lac-B alleviated HgCl₂-induced testicular atrophy by reducing the testicular MDA, and serum inflammatory cytokines.⁵ It has been shown that Lac-B decreased the inflammation of rat's paw edema induced by carrageenan (a food additive which can initiates inflammation), diminished the expression of inflammatory cytokines, and improved its morphological architecture.³³ Moreover, in clinical studies, Lac-B exhibited antioxidant and anti-inflammatory activities in healthy individuals and diabetic patients.^{34,35} Likewise, Vit-E has shown the antioxidant properties against HgCl₂-induced reproductive toxicity.³⁶ Additionally, Vit-E possessed a protective action in human lung cell exposed to HgCl₂, through inhibition of oxidative stress and apoptosis.³⁷

To sum up, this study suggested that administration of Vit-E and/or Lac-B has the potential to protect the liver from the toxicity induced by HgCl₂ and also has the ability to attenuate and reverse HgCl₂-induced oxidative stress, apoptosis, and inflammation in liver tissue. Additionally, the modulation of CHOP, GPR87, and mTOR may explain further mechanisms of liver injury and protection.

Author's Note

AA and IH conceived of the study, participated in its design and coordination; IH, SA and WA carried out the animal experimentation and biochemical analyses; AA and IH conducted the gene and protein analyses, IHH analyzed the data; AA drafted the manuscript and all authors read and approved the final manuscript.

Acknowledgment

The authors extend their appreciation to the Deanship of Scientific Research at King Saud University for funding this work through the Undergraduate Student's Research Support Program, Project no. (URSP-5-20-19).


Declaration of Conflicting Interests

The author(s) declared no potential conflicts of interest with respect to the research, authorship, and/or publication of this article.

Funding

The author(s) disclosed receipt of the following financial support for the research, authorship, and/or publication of this article: The authors extend their appreciation to the Deanship of Scientific Research at King Saud University for funding this work through the Undergraduate Student's Research Support Program, Project no. (URSP-5-20-19).

ORCID iD

Ahlam Alhusaini  <https://orcid.org/0000-0003-2905-8882>

References

1. Eagles-Smith CA, Silbergeld EK, Basu N, et al. Modulators of mercury risk to wildlife and humans in the context of rapid global change. *Ambio*. 2018;47(2):170-197.
2. Bernhoft RA. Mercury toxicity and treatment: a review of the literature. *J Environ Public Health*. 2012;2012.
3. Nyland JF, Fairweather D, Shirley DL, Davis SE, Rose NR, Silbergeld EK. Low-dose inorganic mercury increases severity and frequency of chronic coxsackievirus-induced autoimmune myocarditis in mice. *Toxicol Sci*. 2012;125(1):134-143.
4. Nakamura H, Nakamura K, Yodoi J. Redox regulation of cellular activation. *Annu Rev Immunol*. 1997;15(1):351-369.
5. Fadda LM, Alhusaini AM, Al-Qahtani QH, Ali HM, Hasan IH. Role of α -tocopherol and *Lactobacillus plantarum* in the alleviation of mercuric chloride-induced testicular atrophy in rat's model: implication of molecular mechanisms. *J Biochem Mol Toxicol*. 2020;34(6):e22481.
6. Vimy MJ, Lorscheider FL, Sandborgh-Englund G, Ekstrand J, Elinder C-G. Renal function and amalgam mercury. *Am J Physiol Regul Integr Comp Physiol*. 1997;42(3):R1199-R1200.

7. Ahlbom A, Norell S, Rodvall Y, Nylander M. Dentists, dental nurses, and brain tumours. *Br Med J (Clin Res Ed)*. 1986; 292(6521):662.
8. Riedl J, Linseisen J, Hoffmann J, Wolfram G. Some dietary fibers reduce the absorption of carotenoids in women. *J Nutr*. 1999; 129(12):2170-2176.
9. Riedl CR, Plas E, Hübner WA, Zimmerl H, Ulrich W, Pflüger H. Bacterial colonization of ureteral stents. *Eur Urol*. 1999;36(1): 53-59.
10. Cianciola ME, Echeverria D, Martin MD, Vasken Aposian H, Woods JS. Epidemiologic assessment of measures used to indicate low-level exposure to mercury vapor (Hg). *J Toxicol Environ Health*. 1997;52(1):19-33.
11. Lohren H, Blagojevic L, Fitkau R, et al. Toxicity of organic and inorganic mercury species in differentiated human neurons and human astrocytes. *J Trace Elem Med Biol*. 2015;32:200-208.
12. Gökçe HS, Öztürk BC, Çam NF, Andiç-Çakır Ö. Gamma-ray attenuation coefficients and transmission thickness of high consistency heavyweight concrete containing mineral admixture. *Cem Concr Compos*. 2018;92:56-69.
13. Böhm V. Vitamin E. *Antioxidants (Basel)*. 2018;7(3):44. doi:10.3390/antiox7030044
14. Liu Y-W, Liong M-T, Tsai Y-C. New perspectives of *Lactobacillus plantarum* as a probiotic: the gut-heart-brain axis. *J Microbiol*. 2018;56(9):601-613.
15. Peixoto NC, Roza T, Flores ÉMM, Pereira ME. Effects of zinc and cadmium on HgCl₂-δ-ALA-D inhibition and Hg levels in tissues of suckling rats. *Toxicol Lett*. 2003;146(1):17-25.
16. Ibrahim MA, Bakhaat GA, Tammam HG, Mohamed RM, El-Naggar SA. Cardioprotective effect of green tea extract and vitamin E on Cisplatin-induced cardiotoxicity in mice: toxicological, histological and immunohistochemical studies. *Biomed Pharmacother*. 2019;113:108731.
17. Liu Q, Ni X, Wang Q, et al. *Lactobacillus plantarum* BSGP201683 isolated from giant panda feces attenuated inflammation and improved gut microflora in mice challenged with Enterotoxigenic *Escherichia coli*. *Front Microbiol*. 2017;8:1885.
18. Mihara M, Uchiyama M. Determination of malonaldehyde precursor in tissues by thiobarbituric acid test. *Anal Biochem*. 1978; 86(1):271-278.
19. Ellman GL. Tissue sulfhydryl groups. *Arch Biochem Biophys*. 1959;82(1):70-77.
20. Marklund S, Marklund G. Involvement of the superoxide anion radical in the autoxidation of pyrogallol and a convenient assay for superoxide dismutase. *Eur J Biochem*. 1974;47(3):469-474. doi:10.1111/j.1432-1033.1974.tb03714.x
21. Park J-D, Zheng W. Human exposure and health effects of inorganic and elemental mercury. *J Prev Med public Heal*. 2012;45(6):344.
22. Joshi D, Mittal DK, Shukla S, Srivastav AK, Srivastav SK. N-acetyl cysteine and selenium protects mercuric chloride-induced oxidative stress and antioxidant defense system in liver and kidney of rats: a histopathological approach. *J Trace Elem Med Biol*. 2014;28(2):218-226.
23. Caglayan C, Kandemir FM, Darendelioğlu E, Yıldırım S, Kucukler S, Dortbudak MB. Rutin ameliorates mercuric chloride-induced hepatotoxicity in rats via interfering with oxidative stress, inflammation and apoptosis. *J Trace Elem Med Biol*. 2019;56:60-68.
24. Yang D, Tan X, Lv Z, et al. Regulation of Sirt1/Nrf2/TNF-α signaling pathway by luteolin is critical to attenuate acute mercuric chloride exposure induced hepatotoxicity. *Sci Rep*. 2016; 6(1):1-12.
25. Zhang H, Tan X, Yang D, et al. Dietary luteolin attenuates chronic liver injury induced by mercuric chloride via the Nrf2/NF-κB/P53 signaling pathway in rats. *Oncotarget*. 2017;8(25):40982.
26. Benzer F, Kandemir FM, Kucukler S, Comaklı S, Caglayan C. Chemoprotective effects of curcumin on doxorubicin-induced nephrotoxicity in Wistar rats: by modulating inflammatory cytokines, apoptosis, oxidative stress and oxidative DNA damage. *Arch Physiol Biochem*. 2018;124(5):448-457.
27. Caglayan C, Kandemir FM, Yıldırım S, Kucukler S, Kılınc MA, Sağlam YS. Zingerone ameliorates cisplatin-induced ovarian and uterine toxicity via suppression of sex hormone imbalances, oxidative stress, inflammation and apoptosis in female Wistar rats. *Biomed Pharmacother*. 2018;102:517-530.
28. Ron D, Habener JF. CHOP, a novel developmentally regulated nuclear protein that dimerizes with transcription factors C/EBP and LAP and functions as a dominant-negative inhibitor of gene transcription. *Genes Dev*. 1992;6(3):439-453.
29. Yao Y, Lu Q, Hu Z, Yu Y, Chen Q, Wang QK. A non-canonical pathway regulates ER stress signaling and blocks ER stress-induced apoptosis and heart failure. *Nat Commun*. 2017;8(1): 1-15.
30. Arfelt KN, Fares S, Sparre-Ulrich AH, et al. Signaling via G proteins mediates tumorigenic effects of GPR87. *Cell Signal*. 2017;30:9-18.
31. Domitrović R, Potočnjak I. A comprehensive overview of hepatoprotective natural compounds: mechanism of action and clinical perspectives. *Arch Toxicol*. 2016;90(1):39-79.
32. Cho C-S, Kowalsky AH, Lee JH. Pathological consequences of hepatic mTORC1 dysregulation. *Genes (Basel)*. 2020;11(8):896.
33. Ayyanna R, Ankaiah D, Arul V. Anti-inflammatory and antioxidant properties of probiotic bacterium *Lactobacillus mucosae* AN1 and *Lactobacillus fermentum* SNR1 in Wistar albino rats. *Front Microbiol*. 2018;9:3063.
34. Kullisaar T, Songisepp E, Mikelsaar M, Zilmer K, Vihalemm T, Zilmer M. Antioxidative probiotic fermented goats' milk decreases oxidative stress-mediated atherogenicity in human subjects. *Br J Nutr*. 2003;90(2):449-456.
35. Ejtahed HS, Mohtadi-Nia J, Homayouni-Rad A, Niafar M, Asghari-Jafarabadi M, Mofid V. Probiotic yogurt improves antioxidant status in type 2 diabetic patients. *Nutrition*. 2012;28(5): 539-543.
36. Muthu K, Krishnamoorthy P. Effect of vitamin C and vitamin E on mercuric chloride-induced reproductive toxicity in male rats. *Biochem Pharmacol*. 2012;1(102):501-2167.
37. Ali HM. Mitigative role of garlic and vitamin E against cytotoxic, genotoxic, and apoptotic effects of lead acetate and mercury chloride on WI-38 cells. *Pharmacol Reports*. 2018;70(4): 804-811.