

Arthroscopic Rotator Cuff Repair in Supine Position

Victor Housset, M.D., Charles Payan, M.D., and Geoffroy Nourissat, M.D., Ph.D.



Abstract: Considering shoulder arthroscopy, lateral decubitus and beach chair are the 2 main employed positionings of the patient. Each include advantages and disadvantages. In our center, we perform all shoulder arthroscopy with the patient in supine position. The aim of this work is to present a stepwise approach of the accomplishment of a rotator cuff repair in supine position. Some specific technical notes are given to provide as much information as possible to help orthopaedic surgeons wishing to perform shoulder cuff repair in this position.

Patient positioning in shoulder arthroscopy is still debated and remains a critical step in the surgical preparation. According to the literature, the lateral decubitus and beach chair are the 2 most commonly used positions.^{1,2} However, they both present advantages and disadvantages, which explains why no superiority of one position versus another has been shown until now.

The lateral decubitus position was first introduced with the use of a static traction device to apply a flexion and abduction of the shoulder.^{2,3} This position gives a good exposure from the anterior to the posterior capsule labral complex. The disadvantages are represented by the vascular and neurologic complications, such as plexus brachial injuries, and the difficulty of conversion to an open procedure, and for the patient to maintain this position in case of isolated regional anesthesia.³⁻⁶

The beach chair position offers the possibility to move the arm of the patient more easily and in more directions and gives a better orientation to the surgeon because of the upright position of the patient.^{2,7,8} Conversion is easier in this position compared with the lateral decubitus position. The disadvantages are the head positioning, which can bother the surgeon using a

posterior portal, and is difficult for the anesthesiologist to reach. Rare but dramatic complications have been reported related to the risk of hypotensive conditions with cases described of ophthalmoplegia,^{9,10} severe brain damage as a result of cerebral ischemia, and even death.¹¹⁻¹³

The choice is most often dependent on the surgeon's experience and training but is also dependent of the surgical procedure performed. For example, it is common to see a surgeon practicing a rotator cuff repair with the patient in a beach chair position, whereas an anterior stabilization surgery for a Bankart lesion repair may be performed with the patient in the decubitus lateral position. The main objective remains to ensure the most adequate access to all parts of the joint where the surgeon needs to work while minimizing complications.

The use of the supine position in shoulder arthroscopy has already been described by Iamsurang and Chernchujit¹⁴ in 2016. The authors concluded that most of the arthroscopic surgical procedures such as cuff repair, biceps tenodesis or tenotomy, subacromial decompression, or even capsulolabral repair can be performed. Unfortunately, their article does not explain and show a whole step-by-step procedure.

The objective of the current article is to present a stepwise approach on how an arthroscopic rotator cuff repair can be performed in supine position. Some specific technical notes are given to provide as much information as possible to help orthopaedic surgeons wishing to perform shoulder cuff repair in this position.

Surgical Technique (With Video Illustration)

The patient received an ultrasound-guided interscalene brachial plexus block combined with general anesthesia with a laryngeal mask airway. The procedure is performed on a patient in supine position with a

*From the Clinique Maussins-Nollet, Sorbonne Université, Paris, France
The authors report no conflicts of interest in the authorship and publication of this article. Full ICMJE author disclosure forms are available for this article online, as [supplementary material](#).*

Received October 21, 2020; accepted January 9, 2021.

Address correspondence to Victor Housset, M.D., Clinique Maussins-Nollet, Sorbonne Université, Paris, France. E-mail: victor.housset@hotmail.fr

© 2021 THE AUTHORS. Published by Elsevier Inc. on behalf of the Arthroscopy Association of North America. This is an open access article under the CC BY-NC-ND license (<http://creativecommons.org/licenses/by-nc-nd/4.0/>).

2212-6287/201745

<https://doi.org/10.1016/j.eats.2021.01.004>

slight forward flexion of the upper body section of the orthopaedic table of 10° to 15° (this flexion of the table may be more important when a Bankart procedure is performed to facilitate the posterior arthroscopic portal).

To access the posterior portal, the operated shoulder has to be free to allow the maximum amplitude while using the instruments. The medial edge of the scapula is resting on the table to stabilize the operating site. The head of the patient is positioned in neutral position with a regular head fixation device. The research of potential compression points in the head fixation device as on the rest of the body is done to prevent these complications (Fig 1).

A Spider 2 Limb Positioner (Smith & Nephew) is used during the whole surgery allowing control of traction, abduction, rotation, and forward flexion. This system has the advantage of maintaining the arm in the desired position during the whole surgery (Fig 1).

For an arthroscopic rotator cuff repair, we start the surgery after applying an inferior traction of the glenohumeral space with the arm positioned as in Figure 2 to achieve good access of subacromial space. The bony surface anatomy can be marked before the incision to help the surgeon throughout the intervention (Fig 2).

For an anterior and superior rotator cuff tear of the supraspinatus as for a massive rotator cuff tear, the

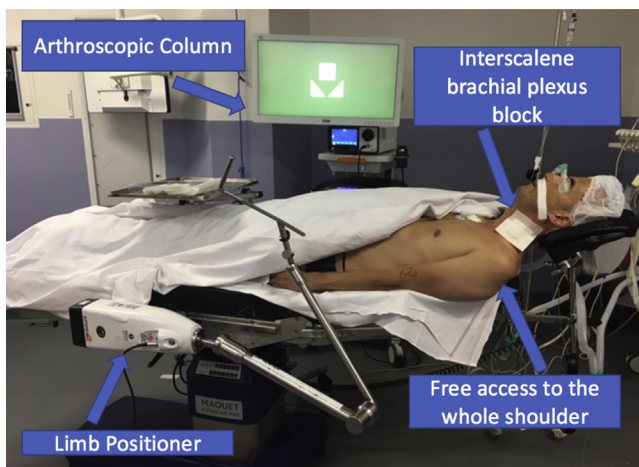


Fig 1. Patient in supine position for the arthroscopic rotator cuff repair. An ultrasound-guided interscalene brachial plexus block is combined with the general anesthesia. A limb positioner device is used at the same side as the operated shoulder to maintain the arm of the patient in the desired position. The head of the patient is positioned with a regular head fixation device in neutral position. The whole shoulder must be free of access to allow the realization of all the portals needed. The arthroscopic column is positioned in front of the operator on the contralateral side of the operated shoulder. A little forward flexion of the upper part of the orthopaedic table is sometimes needed when a posterior arthroscopic portal is needed.

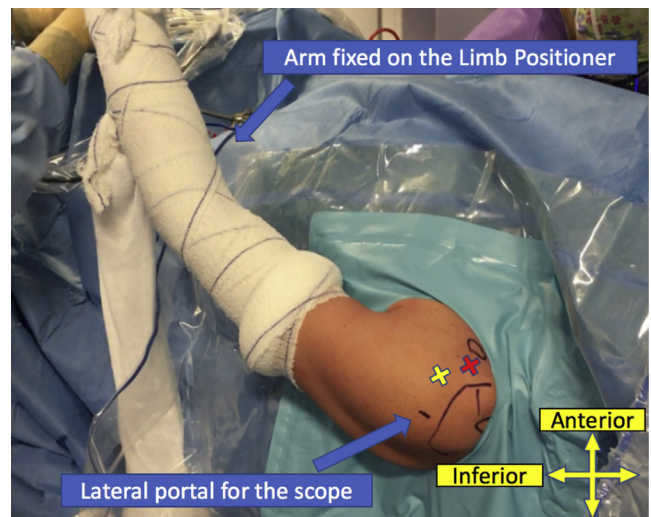


Fig 2. To perform an arthroscopic rotator cuff repair in supine position the arm can be fixed on a limb positioner to allow control of traction, forward elevation, abduction and rotation during the whole surgery. Bony landmarks can be marked on the skin the help the surgeon during the procedure. The surgery starts with the arthroscope introduced in the lateral portal to provide a direct view of the tear. An anterior and lateral portal (yellow cross) can be used to pass the suture for the anchor positioning and to tie the knots. An anterior portal (red cross) can be used as a waiting portal to prevent the entangling of the threads. The anterior and inferior aspect of the patient's body is given.

surgery is initiated with a posterior-lateral portal, lateral to the classic “soft point” incision commonly used. With this portal, the 30° arthroscope is positioned in the subacromial space more laterally and anteriorly and provides a direct view of the tears. The arthroscope must be maintained with a rotation of 90° relative to the ground to obtain a classical view during the arthroscopy. The glenoid rim and the proximal insertion of the long head of the biceps can be assessed through the tear. The arthroscope is not introduced through the infraspinatus but directly in the subacromial space, on the top of the cuff tear.

An instrumental anterior and lateral portal is established if necessary using a guided needle. After a classical bursectomy and an electro-surgical release of the supraspinatus tendon and of coracoacromial ligament, a tenotomy of the long head of the biceps is performed through the tear (Fig 3). A tenodesis can also be performed if required. After visualizing the size and the type of retraction of the tear and because of the traumatic context of this cuff tear, it can be decided to proceed with a transosseous equivalent double row suture technique.

A waiting anterior instrumental portal is established at the place where the acromioclavicular ligament is released. A canula is placed in the anterior lateral portal

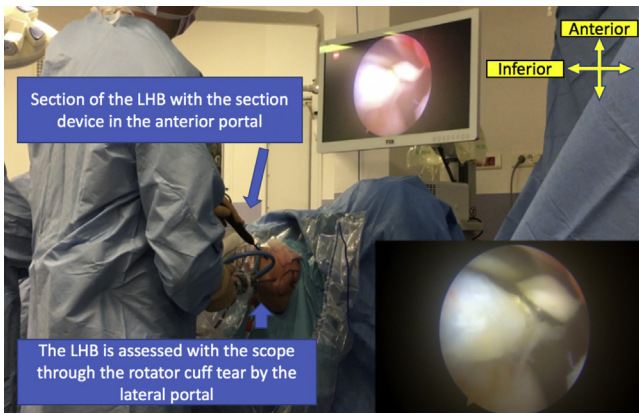


Fig 3. Realization of the long head of the biceps (LHB) tenotomy with a patient in supine position. The anterior and inferior aspect of the patient’s body is given. The section is performed through the rotator cuff tear using an anterior portal when it is possible with the arthroscope positioned in the lateral portal. A tenodesis of the LHB can also be performed using the same procedure. The management of the LHB tendon is not more difficult for the surgeon on a patient in supine position than with a patient in the beach chair or the lateral decubitus position. The arms of the surgeon remain low, which leads to less fatigability during the procedure. View with the arthroscope through the lateral portal.

to help in passing the suture through the tendon and to prevent the risk of entangling the threads.

A motorized shaving of the humeral footprint of the rotator cuff tendon is performed, and a superior portal is performed allowing the good positioning of the anchors (Fig 4). Anterior and posterior all-suture double-loaded anchors are impacted at the footprint level (Suturefix Ultra, 1.9-mm, Smith & Nephew) to perform

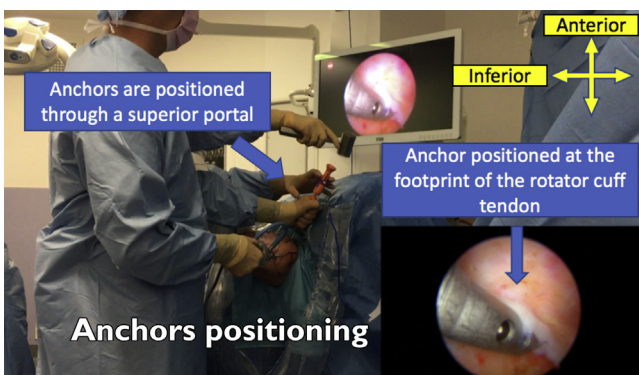


Fig 4. Anchors positioning during a rotator cuff repair with a patient in supine position. The anterior and inferior aspect of the patient’s body is given. The anchors have to be placed at the repaired tendon footprint for a single row repair as with the medial row of a double row repair. The optimal positioning of the anchors is easily obtained with a patient in supine position without difficulty for the surgeon. View with the arthroscope through the lateral portal.

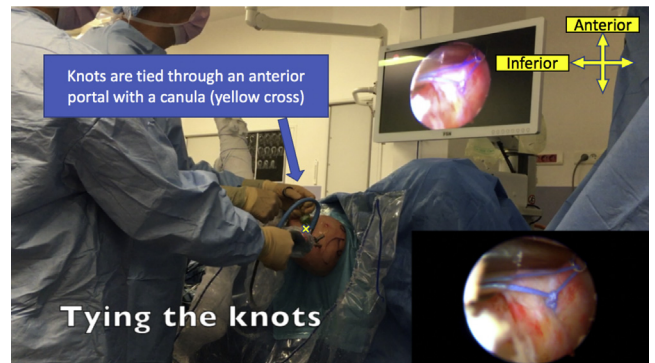


Fig 5. With a patient in supine position, there is no added difficulty to tie the knots for a single row repair or the medial row of a double row repair for a rotator cuff tear. The anterior and inferior aspect of the patient’s body is given. A canula (yellow cross) is placed in an anterior and lateral portal both to help passing the suture and to prevent the risk of entangling the threads. View with the arthroscope through the lateral portal.

the medial row of a double row repair or a single row repair.

After passing all the suture, 4 mattress knots are performed for a double row repair (Fig 5). The lateral anchor is then inserted under visual control of the potential final aspect of the repair to realize the lateral row (Multifix S Ultra Knotless Suture Anchor, Smith & Nephew). An acromioplasty is performed with the Shaver device (Smith & Nephew). At the end of the surgery, the good positioning of the rotator cuff tendon after its repair and the perfect recovering of its footprint is controlled (Fig 6).

The surgical procedure of an arthroscopic rotator cuff repair in supine position is shown in Video 1.

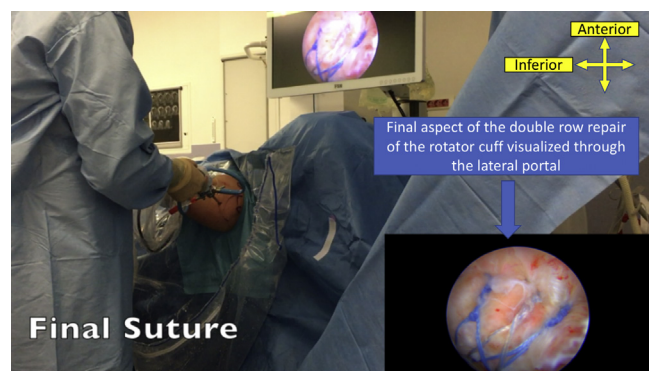


Fig 6. The final aspect of a double row repair for a rotator cuff tear for a patient in supine position is visualized through the lateral portal. The anterior and inferior aspect of the patient’s body is given. To learn how to operate and to well visualize during an arthroscopic rotator cuff repair in supine position, it is necessary to maintain a rotation of 90° relative to the ground to obtain a classical view during the procedure. View with the arthroscope through the lateral portal.

Table 1. Main Advantages and Disadvantages of the Supine Positioning

Advantages	Disadvantages
<ul style="list-style-type: none"> - Easy and quick set up - More comfortable for the patient - No risk of cerebral or hypoplegia complications - Access to all the compartments of the shoulder (anterior+) - Less fatigability for the operator - Easy access to the patient airways for the anesthesiologist - Easy conversion to an open procedure - Head and arm of the patient do not disturb the operator 	<ul style="list-style-type: none"> - Need for a traction system with risk of peripheral nerve and brachial plexus injury - Need for initial adaptation for the orientation of the arthroscope - Use caution for aseptic mistake when the hand of the operator is at the level of the thigh - Risk of bleeding owing to the absence of orthostatic hypotension

The arthroscopic repair of a rotator cuff tear is possible for any type of tear and does not necessitate any specific patient evaluation or preoperative imaging. Rehabilitation usually includes that patients use a shoulder immobilizer for 3 weeks with an abduction pillow, which is removed at 6 weeks. It must include gradually introduced pendular exercises with a passive and active rehabilitation. The patients are monitored with clinical follow-up at 3 and 6 weeks. The healing of the tendon and its thickness is evaluated at 12 weeks using ultrasound.

Discussion

When the question of patient positioning arises, no conclusive evidence of superiority of the beach chair or the lateral decubitus positions can be observed. They are both safe and effective methods in shoulder arthroscopic procedures. They are known for their respective advantages with regard to the good visualization allowed in each compartment of the shoulder.

In our department, all shoulder arthroscopies are performed in the supine position. Both subacromial space and glenohumeral joint can be properly assessed but as in the described technique, we always try to work only in the subacromial space during a rotator cuff repair when it is possible to minimize the traumatic aspect of the surgery and the risk of complications, such as infraspinatus damage. Moreover, the supine position is perfectly adequate if an open procedure conversion is needed.

Table 2. Main Tips in the Proceeding of an Arthroscopic Rotator Cuff Repair in Supine Position

Tips for Rotator Cuff Repair in Supine Position
<ul style="list-style-type: none"> - Using a good traction device (or a trained fellow) - Put a small tilt of approximately 10° to 15° (more may be required for a glenohumeral joint procedure, such as Bankart repair). - Control the compression point (the patient may not have legs crossed) - The whole posterior surface of the shoulder should be free to access (by removing piece from the orthopaedic table, if necessary) - Control the head positioning at the beginning of the procedure. - Use caution for aseptic mistake when the hands of the operator are positioned low.

The main advantages of this technique relates to ease of positioning the patient, which leads to a shorter time that has to be considered for surgeons practicing mainly shoulder arthroscopy. From an anesthetic point of view, it presents the same advantages as the decubitus lateral position by decreasing the incidence of cerebral desaturation events and the risk of bradycardic and hypotensive episodes. In the rare cases when general anesthesia is not possible, this position is also more comfortable for the patient and the access to the patient's airway for an eventual laryngeal intubation is also easier for the anesthesiologist. As seen in the video, in the supine position the arms of the operator and the assistant are low, which leads to less fatigability during the procedure. According to the operator, the main step in the learning curve of this technique is to learn how to operate with a different camera orientation. Eventually, all the compartments of the shoulder can be assessed without difficulty, and the view of the surgeon is not disturbed by arthroscopic bubbles, which do not stay in the subacromial space (Table 1). The main tips to proceed with this procedure in this position are given in Table 2.

Although we have not observed any complications relative to the supine position because we use this technique, there are many theoretical complications. The use of traction exposes the patient to neurologic risks such as postoperative neurapraxias or lesion of the brachial plexus. The preparation of the arm and how it is attached involves specific attention to avoid the risk of compression, especially of the ulnar nerve. We must admit that the use of the Spider 2 device (Smith & Nephew) is a great help for arm positioning when performing these kind of surgeries. However, the use of a classical traction device holding the arm in a slightly abducted and flexed position seems just as suitable.

Concerning the surgical procedure presented, the resection of the coracoacromial ligament is always performed first. Acromioplasty is performed before cuff repair if room is needed for suture visualization; if not, we prefer performing it after to limit bleeding during cuff repair. This bleeding should enhance healing of the tendon.¹⁵

All sutured anchors (ASA) have shown similar biomechanical capacity compared with conventional suture anchors in the double row rotator cuff repair.^{16,17} We proceed to a more vertical insertion angle of the ASA than the classical 45° based on the biomechanical evidence from the study by Oh et al.¹⁸ Moreover, the use of ASA is our preference because of the smaller starting defect in the proximal humerus, which allows us to proceed with the repair in many different settings.¹⁹

We use double row suture for patients with acute rotator cuff tear with good quality of the tissue.²⁰ Single row technique is preferred for degenerative chronic rotator cuff tears. Simple row repair can be done in the same position without any specific adaptation to the earlier described technique.

The main limitation we found with this positioning was that when the patient is in supine position there is no hypotension inside the joint and thus sometimes it is necessary to increase the pressure inside the joint to obtain a good view and to prevent bleeding.

Conclusions

Despite the initial need for an adaptation time for the operator to orientate himself in space, the rotator cuff repair in supine position can be easily assessed and performed by orthopaedic surgeons specialized in shoulder surgery. All compartments can be assessed and there is no risk of catastrophic complications described in beach chair position.

References

1. Rojas J, Familiari F, Bitzer A, Srikumaran U, Papalia R, McFarland EG. Patient positioning in shoulder arthroscopy: Which is best? *Joints* 2019;7:46-55.
2. Peruto CM, Ciccotti MG, Cohen SB. Shoulder arthroscopy positioning: Lateral decubitus versus beach chair. *Arthroscopy* 2009;25:891-896.
3. Gross RM, Fitzgibbons TC. Shoulder arthroscopy: A modified approach. *Arthroscopy* 1985;1:156-159.
4. Pitman MI, Nainzadeh N, Ergas E, Springer S. The use of somatosensory evoked potentials for detection of neuropraxia during shoulder arthroscopy. *Arthroscopy* 1988;4:250-255.
5. Polzhofer GK, Petersen W, Hassenpflug J. Thromboembolic complication after arthroscopic shoulder surgery. *Arthroscopy* 2003;19:E129-E132.
6. Kuremsky MA, Cain EL Jr, Fleischli JE. Thromboembolic phenomena after arthroscopic shoulder surgery. *Arthroscopy* 2011;27:1614-1619.
7. Skyhar MJ, Altchek DW, Warren RF, Wickiewicz TL, O'Brien SJ. Shoulder arthroscopy with the patient in the beach-chair position. *Arthroscopy* 1988;4:256-259.
8. Hoenecke HR, Fronek J, Hardwick M. The modified beachchair position for arthroscopic shoulder surgery: The La Jolla beachchair. *Arthroscopy* 2004;20 (Suppl 2):113-115.
9. Kim JY, Rhee YG. Ocular surface injury after shoulder surgery in the beach-chair position. *Int Orthop* 2018;42: 2891-2895.
10. Bhatti MT, Enneking FK. Visual loss and ophthalmoplegia after shoulder surgery. *Anesth Analg* 2003;96:899-902.
11. Murphy GS, Greenberg SB, Szokol JW. Safety of beach chair position shoulder surgery: A review of the current literature. *Anesth Analg* 2019;129:101-118.
12. Salazar D, Sears BW, Aghdasi B, et al. Cerebral desaturation events during shoulder arthroscopy in the beach chair position: Patient risk factors and neurocognitive effects. *J Shoulder Elbow Surg* 2013;22:1228-1235.
13. Dippmann C, Winge S, Nielsen HB. Severe cerebral desaturation during shoulder arthroscopy in the beach-chair position. *Arthroscopy* 2010;26(9 Suppl):S148-S150.
14. Iamsung C, Chernchujit B. The supine position for shoulder arthroscopy. *Arthrosc Tech* 2016;5:e1117-e1120.
15. Gerber C, Catanzaro S, Betz M, Ernstbrunner L. Arthroscopic correction of the critical shoulder angle through lateral acromioplasty: A safe adjunct to rotator cuff repair. *Arthroscopy* 2018;34:771-780.
16. Bernardoni ED, Frank RM, Veera SS, et al. Biomechanical analysis of medial-row all-suture suture anchor fixation for rotator cuff repair in a pair-matched cadaveric model. *Arthroscopy* 2019;35:1370-1376.
17. Ntalos D, Sellenschloh K, Huber G, et al. Conventional rotator cuff versus all-suture anchors—A biomechanical study focusing on the insertion angle in an unlimited cyclic model. *PLoS One* 2019;14:e0225648.
18. Oh JH, Jeong HJ, Yang SH, et al. Pullout strength of all-suture anchors: Effect of the insertion and traction angle—A biomechanical study. *Arthroscopy* 2018;34:2784-2795.
19. Burks RT. Editorial commentary: All-suture anchor for medial-row fixation in rotator cuff repair—ready for prime time? *Arthroscopy* 2019;35:1377-1378.
20. Sugaya H, Maeda K, Matsuki K, Moriishi J. Repair integrity and functional outcome after arthroscopic double-row rotator cuff repair. A prospective outcome study. *J Bone Joint Surg Am* 2007;89:953-960.