

Galectin-3 as an Immunohistochemical Tool to Distinguish Pilocytic Astrocytomas from Diffuse Astrocytomas, and Glioblastomas from Anaplastic Oligodendrogliomas

Luciano Neder¹; Suely K Nagahashi Marie²; Carlos Gilberto Carlotti Jr³; Alberto Alain Gabbai⁴; Sérgio Rosemberg⁵; Suzana MF Malheiros⁴; Rodrigo Proto Siqueira⁶; Sueli Miekko Oba-Shinjo²; Miyuki Uno²; Paulo Henrique Aguiar²; Flavio Miura²; Roger Chammas⁷; Benedicto Oscar Colli³; Wilson Araujo Silva Jr⁶; Marco A. Zago⁶

Departments of ¹Pathology, ³Neurosurgery, ⁶Clinical Medicine, and ⁸Genetics, Faculty of Medicine of Ribeirão Preto, University of São Paulo, Brazil.

Departments of ²Neurology, ⁵Pathology, and ⁷Radiology, School of Medicine, University of São Paulo, Brazil.

⁴Department of Neurology, Federal University of São Paulo, Brazil.

Corresponding author:

Suely Kazue Nagahashi Marie, MD, PhD, Department of Neurology, School of Medicine, University of São Paulo, Av Dr Arnaldo, 455, 4th floor, room 4110, São Paulo, SP 01246-903, Brazil (E-mail: sknmarie@usp.br)

The distinction of astrocytomas and oligodendrogliomas, mainly pilocytic astrocytomas (PILOs) from infiltrating astrocytomas and oligodendrogliomas (ODs), and high-grade oligodendrogliomas from glioblastomas (GBMs), poses a serious clinical problem. There is no useful immunohistochemical (IHC) marker to differentiate these gliomas, and sometimes the differential diagnosis between them is arbitrary. We identified galectin-3 (Gal-3) as a possible tool to differentiate them based on gene expression profiles of GBMs. We confirmed the differential expression in 45 surgical samples (thirteen GBMs; seven PILOs; 5 grade II ODs; 5 anaplastic oligodendrogliomas [AODs], including 2 Oligo-astrocytomas; 8 diffuse astrocytomas [ASTs], and 7 non-neoplastic samples) by quantification of Gal-3 gene expression by real-time quantitative PCR (rt-PCR). Higher expression of Gal-3 was observed in GBMs and PILOs than in OD, AODs and ASTs. The IHC expression of Gal-3 was evaluated in 90 specimens (fifteen PILOs, fourteen ASTs, 10 anaplastic astrocytomas, fifteen GBMs, eleven ODs, fifteen AODs, and 10 dysembryoplastic neuroepithelial tumors). The mean labeling score for Gal-3 determined according to the percentage of labeled cells in the tumor bulk was significantly different in GBMs versus AODs and in PILOs versus ASTs. Hence, Gal-3 is differentially expressed in central nervous system tumors, making IHC detection of Gal-3 a useful tool in distinguishing between these gliomas.

Brain Pathol 2004;14:399-405.

INTRODUCTION

The distinction of pilocytic astrocytomas (PILOs) from infiltrating astrocytomas, oligodendrogliomas (ODs), and other low grade lesions, including dysembryoplastic neuroepithelial tumors (DNTs), can sometimes be difficult. Similarly, the discrimination of high-grade oligodendroglioma from glioblastoma (GBM) poses a serious clinical problem, since anaplastic oligodendroglioma (AOD) may respond to chemotherapy with a relatively long survival time, in contrast to GBM with its poor prognosis (39). Although several studies have focused on the search for biological markers for oligodendroglial neoplasm (13, 14, 19, 28, 29, 31, 33, 36, 43, 51), there is no immunohistochemical marker that distinguishes between these entities.

The comparison of the gene expression profile of GBM with non-neoplastic brain tissue by Serial Analysis of Gene Expression (SAGE) (NCBI web site: <http://www.ncbi.nlm.nih.gov/SAGE>) reveals the overexpression of galectin-3 (Gal-3), a 31 kDa β -galactoside-binding lectin (18). Gal-3 has been observed in macrophage, endothelial cell, lymphocyte and different tumors, including central nervous system (CNS) tumors (8, 32, 42), and plays a role in cell growth, adhesion, migration and cell death (2, 12, 21, 22, 39, 50). The CNS contains large amounts of glycoconjugates, and glioma cells produce and secrete extracellular matrix (ECM) components involved in cell adhesion and migration (44). These specific characteristics, associated with the fact that Gal-3 mediates cell-cell and cell-matrix interactions, have

lead to several studies of Gal-3 expression in glial tumors of the CNS. However, the role of this lectin in these tumors has not been fully addressed, while some of the previous data are conflicting (4, 5, 10, 16, 24, 47). Additionally, there is no systematic study using molecular and immunohistochemical (IHC) approaches to compare Gal-3 expression in astrocytic and oligodendroglial neoplasms of different grades of malignancy.

Thus, in the present study we report the distinct gene expression of Gal-3 in surgical specimens of astrocytomas and oligodendrogliomas, on the basis of quantitative real-time polymerase chain reaction (rt-PCR), and propose that IHC expression of Gal-3 is a useful tool to differentiate GBM from AOD, and grade I and II astrocytomas, even in small samples obtained by stereotactic biopsies.

MATERIAL AND METHODS

Tissue samples. Tumor samples were obtained from 90 patients with astrocytomas, oligodendrogliomas of different grades of malignancy, and DNTs. All tumor specimens were examined microscopically and graded according to the latest WHO classification of CNS tumors (23) by 2 independent neuropathologists with full diagnostic agreement. The tumors were graded as: PILOs (n = 15), diffuse astrocytoma, grade II (ASTs) (n = 14), anaplastic astrocytoma, grade III (AAs) (n = 10), GBMs, grade IV (n = 15), ODs, grade II (n = 11, including one oligoastrocytoma), AODs, grade III (n = 15, including one anaplastic oligoas-

Case	Gender	Age (years)	Location	Gal-3 MLS Tumor Bulk		Endothelium
				Nuclei	Cytoplasm	
<i>Pilocytic astrocytomas</i>						
1	F	18	Cerebellum	4	4	-
2	F	13	Cerebellum	3	3	-
3	F	56	Thalamus	2	3	-
4	F	17	Diencephalon	1	4	-
5	F	18	Diencephalon	1	2	-
6	F	35	Medulla	1	2	-
7	F	4	Cerebellum	4	4	-
8	F	3	Cerebellum	3	3	-/+
9	M	13	Cerebellum	3	3	-
10	F	14	Temporal	2	3	-
11	M	12	Cerebellum	2	2	-
12	M	7	Optic Nerve	2	4	-
13	M	18	Cerebellum	2	3	-
14	F	8	Optic Nerve	4	4	-/+
15	M	32	Cerebellum	2	4	-
<i>Astrocytomas</i>						
16	M	20	Frontal	0	0	+
17	F	7	Thalamus	0	0	-
18	M	39	Temporal	0	0	+
19	F	37	Frontal	0	0	+
20	M	9	Spinal	0	0	-
21	F	46	Parietal	0	0	+
22	F	44	Frontal	0	0	+/-
23	F	24	Frontal	0	0	-
24	F	31	Fronto-parietal	0	0	+
25	F	25	Temporal	0	0	+
26	M	44	Frontal	0	0	+
27	M	29	Temporal	0	0	-
28	F	38	Parietal	0	0	-
29	M	42	Frontal	0	0	+/-
<i>Anaplastic astrocytomas</i>						
30	M	24	Thalamus	0	0	+/-
31	F	14	Thalamus	0	0	+
32	M	28	Frontal	0	0	+
33	M	31	Frontal	0	0	+
34	M	33	Temporal	0	0	-/+
35	M	9	Fronto-parietal	0	0	+
36	M	33	Temporal	0	0	-/+
37	F	35	Frontal	0	0	-/+
38	M	30	Temporal	0	0	+
39	M	30	Frontal	0	0	+

Table 1. Gender, age at the time of surgery, tumor location, and immunohistochemical data of Gal-3 labeling in the tumor bulk and the endothelium of astrocytomas and oligodendrogliomas of different malignancy grades and dysembryoplastic neuroepithelial tumors..

trocytoma), and ten DNTs. The age ranges of the patients with these 7 tumor groups were, respectively: 3 to 56 (median: 14 years), 7 to 46 (median: 34 years), 9 to 35 (median: 30 years), 36 to 81 (median: 61 years), 21 to 60 (median: 48 years), 20 to 73 (median: 46 years), and 18 to 50 (median: 31 years) (Table 1). RNA was extracted from 38 tissue samples for molecular analysis: ten ODs and AODs (including 2 cases of oligoastrocytomas, one of grade II and another of grade III), seven PILOs, eight ASTs, and thirteen GBMs. Additionally, non-neoplastic brain tissues were obtained from 7 individuals submitted to temporal lobe resection of epilepsy surgery.

Immunohistochemical detection of Gal-3. Sections were deparaffinized and subjected to heat-induced epitope retrieval by steaming for 40 minutes at 98°C in a ci-

trate buffer (0.001M, pH 6.0). After blocking of nonspecific binding sites using 2% normal horse serum in PBS (pH 7.4) for 60 minutes, primary antibody (anti-Gal-3, monoclonal, 1:200, Novocastra®) was applied overnight at room temperature. Labeling was detected by adding biotinylated secondary antibody for 30 minutes (anti-human universal antibody, 1:200, Novocastra®) with avidin-biotin complex, and 3, 3'-diaminobenzidine. Sections were then quickly counterstained with Harris hematoxylin. Negative controls were performed by omitting the primary antibody from the immunohistochemical reagents.

Microscopic evaluation. The descriptive analysis was supplemented by a quantitative evaluation of Gal-3 label. The percentage of labeled cells (considering nuclei and cytoplasm, and excluding endothelia) in

the tumor bulk was assessed using labeling scores determined simultaneously by 2 observers as follows: 0 = negative, 1 = up to 10% of labeled cells; 2 = 11% to 25% of labeled cells; 3 = 26% to 75% of labeled cells; and 4 = more than 75% of labeled cells. The mean labeling score (MLS) for Gal-3 was determined for each tumor group (Table 1).

Surgical material preparation for gene expression studies. During surgery, tissue samples from tumors were collected, frozen in liquid nitrogen and stored at -70°C in appropriate vials. Guided by the microscopic examination of cryostatic sections, the samples were microdissected by apposition, in order to remove areas of necrosis, cellular debris and any non-neoplastic tissue. A diagnostic confirmation was performed during this procedure. The tumor areas of interest were collected in microvials, kept under dry ice throughout all the manipulation and stored at -70°C until final usage.

RNA isolation and cDNA synthesis. RNA was isolated using the classic Trizol method (Invitrogen®, Paisley, United Kingdom) and preliminary evaluation of RNA integrity was done by RNA Gel Electrophoresis. cDNA was synthesized from 2 µg of total RNA by extension with random hexamer primers (Invitrogen®, Paisley, United Kingdom), and 200U of Superscript II reverse transcriptase (Invitrogen®, Paisley, United Kingdom).

Real-Time TaqMan Assay. rt-PCR for Gal-3 was performed using Assay-by-Design (Applied Biosystems®, United Kingdom) TaqMan primers and probe, following the technique described previously in detail (17). Primers used were gal3F 5'-GCCAC TGGCC CCTAT GG-3', gal3R 5'-AGGCA CAATC AGTGG C-3' MGBNFQ. Primers were positioned in different exons and the TaqMan probe binds to both exons to avoid false-positive results caused by DNA contamination of the RNA preparation. All PCR reactions were performed in duplicate with the GeneAmp 5700 Sequence Detection System® using 100 ng of cDNA. Quantitative data was normalized with the TaqMan PDAR endogenous control (Applied Biosystem®, United Kingdom) for the housekeeping glyceraldehyde-3-phosphate dehydrogenase

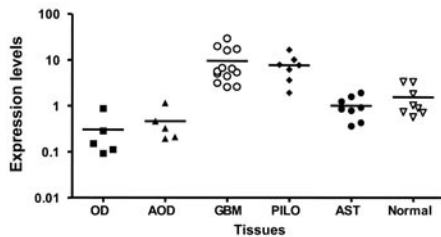


Figure 1. Gal-3 mRNA levels in tumoral and normal central nervous system tissues. Two micrograms of total RNA from oligodendrogliomas (OD), anaplastic oligodendrogliomas (AOD), glioblastomas (GBM), pilocytic astrocytomas (PILO), astrocytomas (AST) and normal central nervous system samples were reverse transcribed and 100 ng of cDNA were analyzed by rt-PCR. Expression levels ($\log_{10} 2^{-\Delta\Delta Ct}$) were calculated based on GAPDH expression levels of each sample. The horizontal bar shows the median of each group. The level of Gal-3 was -1.52-fold lower in ASTs, -3.3-fold lower in AODs, and -5.06-fold lower in OD than normal samples. Gal-3 transcript levels are different in PILOs ($p=0.0036$) and GBMs ($p=0.0145$), but not in AODs ($p=0.074$) and ASTs ($p=0.258$) when compared with normal CNS tissues. A significant difference was found when Gal-3 transcript levels were compared between PILOs and ASTs ($p=0.0016$) and between AODs and GBMs ($p=0.029$).

(GAPDH). Standard curves were established following serial sample dilutions to ensure amplification efficiency within each cycle close to factor 2 (data not shown). The equation $2^{-\Delta\Delta Ct}$ was applied to calculate the relative expression of Gal-3 in tumor samples compared with a pool of three normal nervous tissues. $\Delta Ct = Ct \text{ Gal-3} - Ct \text{ GAPD}$, and $\Delta\Delta Ct = \Delta Ct \text{ tumor} - \Delta Ct \text{ pool of normal tissue}$ (27).

Statistical analysis. Student's *t*-test or a normal reference distribution was used to construct 95% confidence intervals for the differences in the different grade astrocytomas and normal CNS samples. Differences were considered to be statistically significant at $p < 0.05$.

RESULTS

Molecular expression of Galectin-3. The mRNA levels for Gal-3 measured by rt-PCR in PILOs and GBMs were similar, being 5.02- and 6.2-fold higher than in non-neoplastic samples respectively (Figure 1, in $\log_{10} 2^{-\Delta\Delta Ct}$ scale): $p=0.0036$ for PILOs compared with normal samples, and $p=0.0145$ for GBMs compared with normal samples. In addition, the Gal-3 transcript levels did not differ in AODs ($p=0.074$) and ASTs ($p=0.258$) when

Case	Gender	Age (years)	Location	Gal-3 MLS Tumor Bulk		Endothelium
				Nuclei	Cytoplasm	
<i>Glioblastomas</i>						
40	F	81	Parietal	2	4	-
41	M	40	Parietal	3	4	-
42	F	40	Cerebellum	2	3	-
43	M	36	Cerebellum	2	4	-
44	F	65	Occipital	1	2	-
45	F	66	Temporal	3	4	-
46	M	63	Frontal	2	3	-
47	M	53	Frontal	3	3	-
48	M	61	Frontal	3	2	-
49	M	64	Temporal	2	3	-
50	F	44	Frontal	4	4	-
51	F	46	Temporal	3	4	-
52	F	78	Frontal	4	4	-
53	M	37	Parieto-occipital	4	4	-
54	F	67	Temporal	2	4	-
<i>Oligodendrogliomas</i>						
55	F	55	Temporal	0	0	+
56	M	21	Frontal	0	0	+
57	M	49	Frontal	0	0	+
58	M	57	Frontal	0	0	+
59	M	48	Parieto-temporal	0	0	+
60	F	47	Frontal	0	0	+
61	M	29	Frontal	0	0	-/+
62	M	60	Frontal	0	0	+
63	M	27	Frontal	0	0	+
64	M	28	Frontal	0	0	-/+
65*	F	48	Frontal	0	0/2*	-
<i>Anaplastic oligodendrogliomas</i>						
66	F	69	Frontal	0	0	+/-
67	M	73	Frontal	0	0	-/+
68	F	48	Cyngulum	0	0	+
69	M	48	Occipital	0	1	-
70	M	34	Temporal	0	1	-
71	M	52	Frontal	0	0	-
72	F	70	Frontal	0	0	-
73	M	57	Frontal	0	0	-/+
74	F	37	Frontal	0	0	-
75	M	46	Temporal	0	0	-/+
76	M	38	Frontal	0	0	-/+
77	M	46	Parieto-temporal	0	0	-/+
78	M	44	Frontal	1	0	-/+
79	F	20	Frontal	0	0	-/+
80*	F	36	Frontal	0	0	-
<i>Dysembryoplastic Neuroepithelial Tumors</i>						
81	F	35	Temporo-parietal	1	1	+
82	F	38	Parietal	0	0	+/-
83	F	25	Temporal	0	0	+
84	F	18	Temporal mesial	1	1	+
85	F	26	Temporal	0	0	+
86	F	36	Parieto-occipital	0	0	-/+
87	M	25	Frontal	1	1	+
88	M	50	Temporal	0	0	+
89	M	27	Occipital	1	1	+
90	M	33	Frontal	0	0	+/-

Table 1. Continued. MLS: Mean Labeling Score (0: negative, 1: up to 10% cells labeled; 2: 11% to 25% cells labeled; 3: 26% to 75% cells labeled; 4: more than 75% cells labeled). *: score 2 in the astrocytoma component. +: positive; -: negative; +/-: positive IHC in majority of cells; -/+ : negative IHC in majority of cells. #: mixed oligoastrocytoma

compared with normal CNS tissues. ODs presented underexpression of Gal-3 compared with normal samples ($p=0.042$). A significant difference was found when Gal-3 transcript levels were compared between PILOs and ASTs ($p=0.0016$). Similarly, a significant difference was observed between AODs and GBMs ($p=0.029$) (Figure 1).

Immunohistochemical expression of Galectin-3. The results of IHC staining for Gal-3 in astrocytomas, oligodendrogliomas of different malignancy grades and DNTs are presented in Table 1. A distinct Gal-3 expression was observed in PILOs (Figure 2C, D) compared to ASTs (Figure 2E), AAs, and DNTs (Figure 2F). PILOs presented a diffuse Gal-3 expression (Figure 2C) in tumor cells, both in the nuclei and

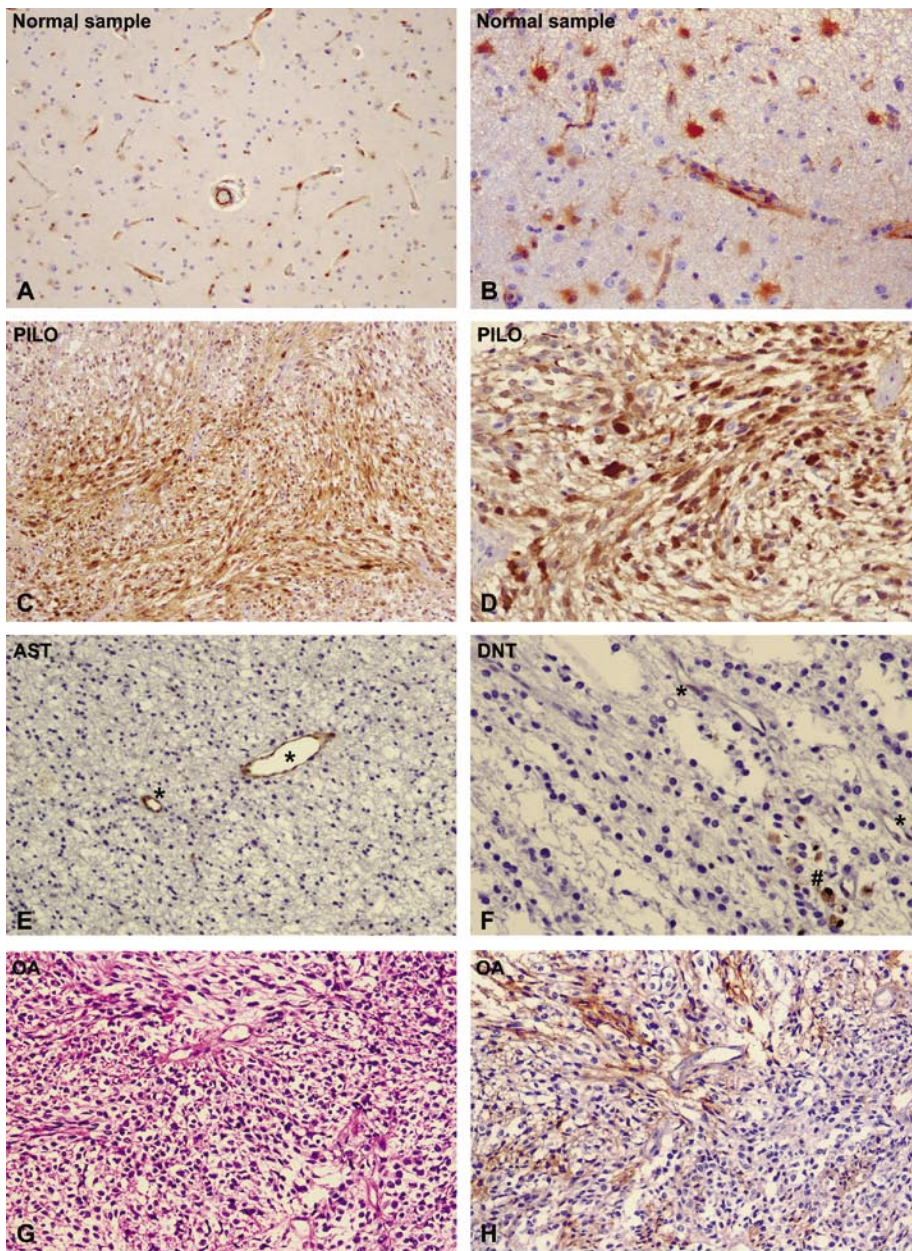


Figure 2. Gal-3 immunostaining of normal brain samples showing its expression in endothelial cells (A, $\times 100$), and in reactive astrocytes (B, $\times 400$). Pilocytic astrocytoma (PILO) presented diffuse expression of Gal-3 (C, $\times 100$), both in the nuclei and the cytoplasm of tumor cells (D, $\times 400$), whereas diffuse astrocytoma (AST) (E, $\times 200$), and dysembryoplastic neuroepithelial tumor (DNT) (F, $\times 400$) showed no expression in tumor cells. Gal-3 expression in endothelial cells was variable, being positive in AST (E, *), and faintly positive in DNT (F, *). Histiocytes expressed Gal-3 (F, #). Oligoastrocytoma, grade II (AO) in H&E section (G, $\times 200$), and respective Gal-3 immunohistochemical preparation (H, $\times 200$) showed positive expression in the astrocytic component of the tumor.

the cytoplasm (Figure 2D), whereas in ASTs (Figures 2E) and AAs, no tumor cells expressed Gal-3, and few DNTs presented score 1 Gal-3 reactivity, both in the nuclei and the cytoplasm of tumor cells (Table 1). The endothelium in PILOs did not stain for Gal-3 (Figure 2D), in contrast to non-tumoral adjacent brain parenchyma, which exhibited strong immunoreactivity for Gal-3 in vessels (Figure A), and reactive astrocytes (Figure 2B). The majority of the

endothelium of tumor vessels in ASTs was positive for Gal-3 (Figure 2E, asterisk), but the expression was variable in AAs and DNTs (Figure 2F, asterisk). A weak Gal-3 expression in the tumor cells of the astrocytic component in a case of grade II Oligoastrocytoma was detected. However, there was no reactivity in the oligodendroglial counterpart of the tumor (Figures 2G, H).

GBMs showed a heterogeneous, but intense immunostaining for Gal-3, particularly in the pseudopalisading of tumor cells around serpiginous areas of necrosis (Figure 3A, B), and, both in the nuclei and the cytoplasm of tumor cells (Figure 3D), including the multinucleated giant tumor cells (Figure 3D, insert). In contrast, tumor cells were negative in AODs, even in those cells along the pseudopalisading (Figure 3E). Whereas only macrophages, sparse entrapped reactive astrocytes, and some monolayered endothelial cells stained positively (Figure 3E, F). Interestingly, there was no immunostaining of endothelial and muscle cells/pericytes for Gal-3 in the microvascular proliferation of high-grade gliomas, particularly in GBMs (Figure 3C, D). In general, we found more Gal-3 positive endothelial cells in low-grade than in high-grade gliomas.

Diffuse extracellular immunopositivity was observed in all cases of PILOs and GBMs, being less intense than the immunostaining detected in the nuclei and the cytoplasm. GBMs presented less extracellular positivity than PILOs.

In contrast to the positive immunostaining of PILOs and GBMs at tumor cores, the non-neoplastic areas presented Gal-3 expression only in vessels and any arising reactive astrocytes (Figure 2A, B), where no expression was observed extracellularly.

The mean labeling scores (MLS) obtained in the tumor bulk were significantly different in PILOs (3.2 ± 0.2 SD) and GBMs (3.5 ± 0.2 SD) in comparison with all other gliomas analyzed, which were uniformly negative, except for a case of oligodendroglioma that was labeled with a 2 score in the astrocytoma component, and few cases of AOD with a 1 score either in the nuclei or the cytoplasm of tumor cells.

DISCUSSION

The present study demonstrates the distinct gene expression of Gal-3 in CNS tumors, with significantly higher mRNA levels in GBMs and PILOs, in contrast with the low or absent expression in diffuse astrocytomas, oligodendrogliomas, and DNTs. The mean levels for the PILO and GBM groups were respectively 5.02- and 6.2-fold higher than the levels observed for normal samples. In addition, the Gal-3 transcript levels in anaplastic oligodendrogliomas and grade II astrocytomas did not

differ from the non-neoplastic CNS tissues. Accordingly, the immunohistochemical staining with a monoclonal antibody reflected these results at the protein level and forms the basis for a simple laboratory approach to help toward distinguishing these tumors.

The pattern of IHC expression was heterogeneous in GBMs, present mainly in the tumor cells forming pseudopalisades around areas of necrosis and in bizarre tumor cells. In contrast, PILOs showed diffuse staining of Gal-3, present in the majority of cells in the tumor bulk. In oligodendrogliomas, regardless of the malignancy grade, the IHC expression of Gal-3 was not observed in tumor cells, even in pseudopalisades, and only infiltrating macrophages, occasional reactive astrocytes entrapped in the tumor bulk, and endothelial cells stained positively. As two-thirds of oligodendrogliomas respond to chemotherapy, patients with these tumors have longer survival time in comparison with ordinary GBMs (11, 38, 40). Differential diagnosis between tumors is therefore important, mostly in cases where the setting of classical morphological characteristics is not presented.

By the same token, PILOs exhibit diffuse staining of Gal-3 whereas ASTs, and DNTs do not. The IHC detection of Gal-3 is of diagnostic interest, as it can sometimes be difficult to discriminate from infiltrating astrocytomas, oligodendrogliomas and other low grade lesions such as DNTs, which present diverse biological behavior, prognosis and treatment.

Perhaps the high expression of Gal-3 in 2 tumors with such distinct PILO and GBM could be a coincidence, or may depend on common causes and mechanisms. The exact meaning of the high Gal-3 expression remains an open question. Galectins are a large family of structurally related beta-galactoside-binding proteins, recognized by their affinity for poly-N-acetyl-lactosamine-enriched glycoconjugates and sequence similarities in the carbohydrate recognition domain, that participate in the control of cell differentiation, proliferation, activation and cell death in different tissues (2, 6, 26, 41). Gal-3, one of the fourteen-member family, is found in both the extracellular (cell surface and medium) and in the intracellular (nucleus and cytoplasm) compartments (20), where it exists in a nonphosphorylated (concentrated in

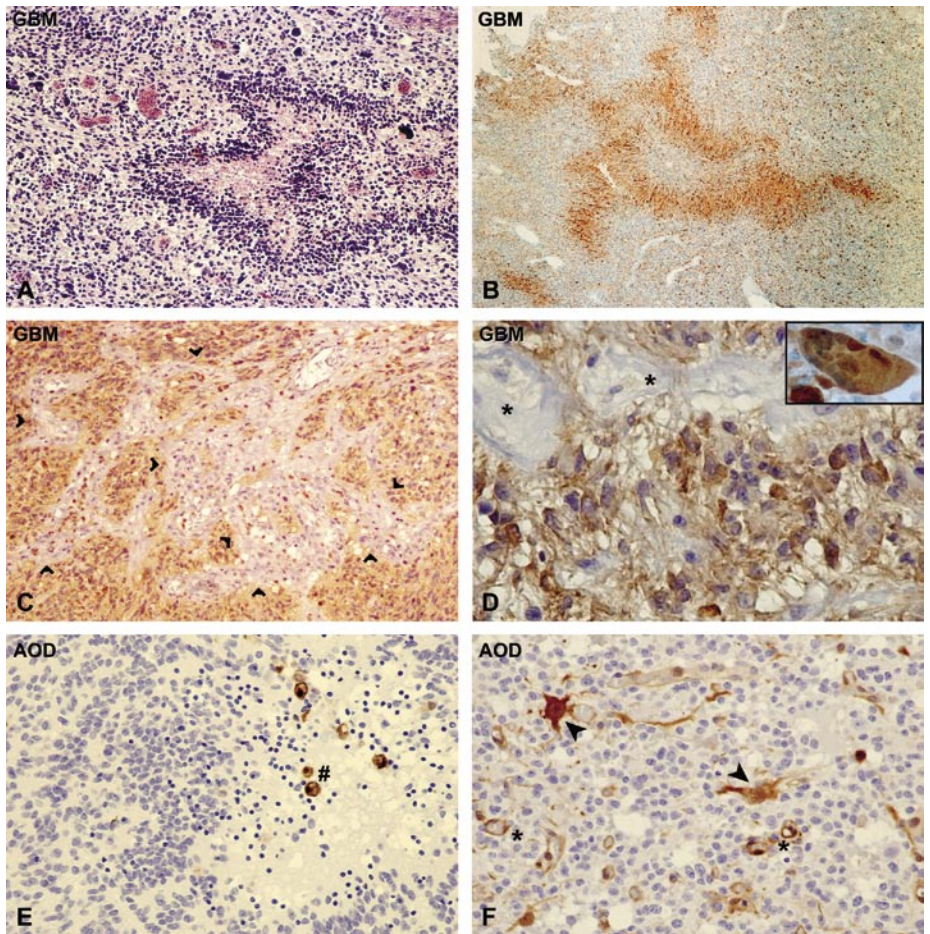


Figure 3. H&E stained section showing a glioblastoma (GBM) (A, $\times 200$) and respective Gal-3 expression along the pseudopalisading (B, $\times 100$). Microvascular proliferation showed lack of Gal-3 reactivity (C, $\times 200$), whereas the nuclei and the cytoplasm of tumor cells showed conspicuous Gal-3 expression (D, $\times 400$), including the multinucleated giant cell (D, insert $\times 400$). Anaplastic oligodendroglioma (AOD) presented absence of Gal-3 expression in tumor cells, even in the pseudopalisading (E, $\times 200$; F, $\times 400$). Only histiocytes (E, #), reactive astrocytes (F, arrow heads) and vessels (F, *) exhibited immunoreactivity for Gal-3.

the nucleus) and phosphorylated form (nucleus and cytoplasm) (7). The intracellular localization of Gal-3 is consistent with several interacting ligands: Bcl-2, CBP70, Chrp, Gemin4 and cytokeatin (15, 30, 35, 46, 49).

Although GBMs and PILOs express Gal-3 with similar labeling pattern, ie, both in the nuclei and the cytoplasm of tumor cells, expression in GBMs were found mainly in the pseudopalisading of tumor cells around serpiginous areas of necrosis and in multinucleated giant tumor cells, whereas the staining was diffuse in PILOs, with no “hot spots” as seen in GBMs. Pseudopalisading glioma cells are the boundaries of the hypoxic tissue microenvironment. Expression of Gal-3 in these cells may have a protective role, since Gal-3 has been reported as an anti-apoptotic molecule (50). On the other hand, it has recently been reported

that glial tumor cells in these pseudopalisading areas are migrating away from hypoxic regions. The strong staining here may be therefore also related to cell motility (3). In fact Gal-3 mediates cell-cell and cell-matrix interaction, particularly adhesion to laminin, fibronectin (45), integrins (34), and binds specifically to the neuronal adhesive glycoproteins L1, N-CAM and myelin-associated glycoprotein MAG (39). Further studies detailing the interaction of Gal-3 with the above pathways would clarify whether this lectin is also involved in cell motility.

Our present data conflict with some earlier reports describing decreasing Gal-3 immunopositivity from PILO to GBM (5, 16). However, our immunohistochemical results were substantiated by mRNA expression profiles. Interestingly OD and AOD, in contrast to WHO grade I and

IV astrocytomas, showed no Gal-3 immunostaining, whereas Deininger et al (10) described fewer Gal-3 positive cells in WHO grade II than in grade III primary oligodendrogliomas. At least part of these contradictory results may be due to the use of different techniques, such as distinct antigen retrieval procedures, and the variable amounts of Gal-3 expressed by distinct tumor clones (16). The difficulties in establishing the diagnosis based on morphological characteristics may also explain these distinct results, mainly in those tumors primarily classified as OD/AOD and subsequently as GBM on relapses.

Another interesting finding was the lack of Gal-3 immunoreactivity in endothelial cells in PILOs and GBMs, in contrast to other astrocytomas and oligodendrogliomas. For GBMs, a constant finding was the complete absence of Gal-3 staining in vessels exhibiting microvascular proliferation, whereas in PILOs the single endothelium layer did not express this lectin. Our results of the expression of Gal-3 in the endothelium in astrocytomas are similar to those reported in the literature (4, 14). In ODs, the Gal-3 expression in the endothelial vessels was variable, however we found lesser staining in high-grade tumors, akin to that reported by Deininger et al (10). Moreover, it is intriguing that contrast-enhancing tumors on neuroimaging, namely PILOs and GBMs, did not express Gal-3 in endothelial cells. We speculate that this finding could be related to some alteration of the blood brain barrier by the pathological vasculature. Extracellular Gal-3 induces endothelial cell differentiation and mediates adhesion of monocytes (25) and macrophages (1), and our findings seem to support Strik et al (47) who postulate that a reduced Gal-3 level may be correlated with the endothelial cell proliferation and formation of pathological vasculature seen in GBMs.

On the basis of our immunohistochemical and molecular data in conjunction with previously published data, we conclude that Gal-3 is differentially expressed in glioblastomas and anaplastic oligodendrogliomas, and in pilocytic astrocytomas and diffuse astrocytomas. Hence, we propose that the IHC detection of Gal-3 is helpful in distinguishing between these gliomas. The meaning of high expression of Gal-3 in pilocytic astrocytomas, a WHO grade I

tumor, remains an open question, although the immunohistochemical staining is different from that observed in glioblastomas. Additionally, the lack of expression of this lectin in endothelial cells in contrast-enhancing tumors could be related to some alteration of the blood brain barrier by the pathological vasculature.

ACKNOWLEDGMENTS

This work is part of the Clinical Genomics Project supported by Fundação de Amparo a Pesquisa do Estado de São Paulo (FAPESP, Brazil), and the Ludwig Institute for Cancer Reseach. The authors are grateful to Ana Maria Anselmi, Amelia Goes de Araujo, Marli H. Tavela, Maria Paula M. Scandar, Monica de Souza Rusticci, Keila Cardoso Barbosa and Eliene Dutra Campos for the excellent technical assistance.

REFERENCES

- Almkvist J, Karlsson A (2004) Galectins as inflammatory mediators. *Glycoconj J* 19:575-581.
- Barondes SH, Castronovo V, Cooper DN, Cummings RD, Drickamer K, Feizi T, Gitt MA, Hirabayashi J, Hughes C, Kasai K, Leffler H, Lui F, Lotan R, Mercurio AM, Monsigny M, Pillai S, Poirer F, Raz A, Rigby PW, Rini JM, Wang JL (1994b) Galectins: a family of animal β -galactoside-binding lectins. *Cell* 76:597-598.
- Brat DJ, Castellano-Sanchez AA, Hunter SB, Pecot M, Cohen C, Hammond EH, Devi SN, Kaur B, Meir EGV (2004) Pseudopalisades in glioblastoma are hypoxic, express extracellular matrix proteases, and are formed by an actively migrating cell population. *Cancer Res* 64:920-927.
- Bresalier RS, Yan PS, Byrd JC, Lotan R, Raz A (1997) Expression of the endogenous galactose-binding protein galectin-3 correlates with the malignant potential of tumors in the central nervous system. *Cancer* 80:776-787.
- Camby I, Belot N, Rorive S, Lefranc F, Mauraug CA, Lahm H, Kaltner H, Hadari Y, Ruchoux MM, Brotqui J, Zick Y, Salmon I, Gabius HJ, Kiss R (2001) Galectins are differentially expressed in supratentorial pilocytic astrocytomas, astrocytomas, anaplastic astrocytomas and glioblastomas, and modulate tumor astrocyte migration. *Brain Pathol* 11:12-26.
- Cooper DN, Barondes SH (1999) God must love galectins; he made so many of them. *Glycobiology* 9:919-984.
- Cowles EA, Agrwal N, Anderson RL, Wang JL (1990) Carbohydrate-binding protein 35. Isoelectric points of the polypeptide and a phosphorylated derivative. *J Biol Chem* 265:17706-17712.
- Danguy A, Camby I, Kiss R (2002) Galectins and cancer. *Biochem Biophys Acta* 1572:285-293.
- Daumas-Duport C, Beuvon F, Varlet P, Fallet-Bianco C (2000) Gliomas: WHO and Sainte-Anne Hospital classifications. *Ann Pathol* 20:413-428.

- Deininger MH, Trautmann K, Meyerermann R, Schluesener HJ (2002) Galectin-3 labeling correlates positively in tumor cells and negatively in endothelial cells with malignancy and poor prognosis in oligodendroglioma patients. *Anticancer Res* 22:1585-1592.
- Engelhard HH, Stelea A, Cochran EJ (2002) Oligodendroglioma: pathology and molecular biology. *Surg Neurol* 58:111-117.
- Fukumori T, Takenaka Y, Yoshii T, Kim HR, Horgan V, Inohara H, Kagawa S, Raz A (2003) CD29 and CD7 mediate galectin-3-induced type II T-cell apoptosis. *Cancer Res* 63:8302-8311.
- Gallo V, Armstrong RC (1995) Developmental and growth factor-induced regulation of nestin in oligodendrocyte lineage cells. *J Neurosci* 15:394-406.
- Geiger KD, Stoldt P, Schlote W, Derouiche A (2000) Ezrin immunoreactivity is associated with increasing malignancy of astrocytic tumors but is absent in oligodendrogliomas. *Am J Pathol* 157:1785-1793.
- Goletz S, Hanisch FG, Karsten U (1997) Novel alphaGalNAc containing glycans on cytokeratins are recognized in vitro by galectins with type II carbohydrate recognition domains. *J Cell Sci* 110:1585-1596.
- Gordower L, Decaestecker C, Kacem Y, Lemmers A, Gusman J, Burchert M, Danguy A, Gabius HJ, Salmon I, Kiss R, Camby I (1999) Galectin and galectin-3 binding site expression in human adult astrocytic tumours and related angiogenesis. *Neuropathol Applied Neurobiol* 25:319-330.
- Heid CA, Stevens J, Livak KJ, Williams PM (1996) Real time quantitative PCR. *Genome Res* 6:986-994.
- Hirabayashi J, Kasai K (1993) The family of metazoan metal-independent (-galactoside-binding lectins: structure, function and molecular evolution. *Glycobiology* 3:297-304.
- Hoang-Xuan K, Aguirre-Cruz L, Mokhtari K, Marie Y, Sanson M (2002) OLIG-1 and 2 gene expression and oligodendroglial tumours. *Neuropathol Appl Neurobiol* 28:89-94.
- Hughes RC (1997) The galectin family of mammalian carbohydrate-binding molecules. *Biochem Soc Trans* 25:1194-1198.
- Hughes RC (2001) Galectins as modulator of cell adhesion. *Biochimie* 83:667-676.
- Inohara H, Akahani S, Raz A (1998) Galectin-3 stimulates cell proliferation. *Exp Cell Res* 245:294-302.
- Kleihues P, Louis DN, Scheithauer BW, Rorke LB, Reifenberger G, Burger PC, Cavenee WK (2002) The WHO classification of tumors of the nervous system. *J Neuropathol Exp Neurol* 61:215-225.
- Kuklinski S, Pesheva P, Heimann C, Urschel S, Gloor S, Graeber S, Herzog V, Pietsch T, Wiestler OD, Probstmeier R (2000) Expression pattern of galectin-3 in neural tumor cell lines. *J Neurosci Res* 60:45-57.
- Lotan R, Belloni PN, Tressler RJ, Lotan D, Xu XC, Nicolson GL (1994) Expression of galectins on mi-

- crovessel endothelial cells and their involvement in tumour cell adhesion. *Glycoconj J* 11:462-468.
26. Liu FT, Patterson RJ, Wang JL (2002) Intracellular functions of galectins. *Biochem Biophys Acta* 1572:263-273.
27. Livak KJ, Schmittgen TD (2001) Analysis of relative gene expression data using real-time quantitative PCR and the 2^{-ΔΔC_T} method. *Methods* 25:402-408.
28. Lu QR, Park JK, Noll E, Chan JA, Alberta J, Yuk D, Alzamora MG, Louis DN, Stiles CD, Rowitch DH, Black PM (2001) Oligodendrocyte lineage genes (OLIG) as molecular markers for human glial brain tumors. *Proc Natl Acad Sci U S A* 98:10851-10856.
29. Marie Y, Sanson M, Mokhtari K, Leuraud P, Kujas M, Delattre JY, Poirier J, Zalc B, Hoang-Xuan K (2001) OLIG2 as a specific marker of oligodendroglial tumour cells. *Lancet* 358:298-300.
30. Menon RP, Strom M, Hughes RC (2000) Interaction of a novel cysteine and histidine-rich cytoplasmic protein with galectin-3 in a carbohydrate-independent manner. *FEBS Lett* 470:227-231.
31. Nakagawa Y, Perentes E, Rubinstein LJ (1986) Immunohistochemical characterization of oligodendrogliomas: an analysis of multiple markers. *Acta Neuropathol (Berl)* 72:15-22.
32. Nangia-Makker P, Honjo Y, Sarvis R, Akahani S, Hogan V, Pienta KJ, Raz A (2000) Galectin-3 induces endothelial cell morphogenesis and angiogenesis. *Am J Pathol* 156:899-909.
33. Ohnishi A, Sawa H, Tsuda M, Sawamura Y, Itoh T, Iwasaki Y, Nagashima K (2003) Expression of the oligodendroglial lineage-associated markers Olig1 and Olig2 in different types of human gliomas. *J Neuropathol Exp Neurol* 62:1052-1059.
34. Ochieng, J, Leite-Browning ML, Warfield P (1998) Regulation of cellular adhesion to extracellular matrix proteins by galectin-3. *Biochem Biophys Res Comm* 246:788-791.
35. Park JW, Voss PG, Grabski S, Wang JL, Patterson RJ (2001) Association of galectin-1 and galectin-3 with Gemin4 in complexes containing the SMN protein. *Nucleic Acids Res* 29:3595-3602.
36. Perentes E, Rubinstein LJ (1986) Immunohistochemical recognition of human neuroepithelial tumors by anti-Leu 7 (HNK-1) monoclonal antibody. *Acta Neuropathol (Berl)* 69:227-233.
37. Perillo NL, Marcus ME, Baum LG (1998) Galectins: versatile modulators of cell adhesion, cell proliferation, and cell death. *J Mol Med* 76:402-412.
38. Pohl U, Cairncross JG, Louis DN (1999) Homozygous deletions of the CDKN2C/p18INK4C gene on the short arm of chromosome 1 in anaplastic oligodendrogliomas. *Brain Pathol* 9:639-643.
39. Probstemeier R, Montag D, Schachner M (1995) Galectin-3, a beta-galactoside-binding animal lectin, binds to neural recognition molecules. *J Neurochem* 64:2465-2472.
40. Pudukkoti VK, Hashmi M, McAllister LD, Levin VA, Hess KR, Prados M, Jaeckle KA, Yung WK, Buys SS, Bruner JM, Townsend JJ, Davis R, Sawaya R, Kyritsis AP (2003) Anaplastic oligodendrogliomas: prognostic factors for tumor recurrence and survival. *Oncology* 65:259-266.
41. Rabinovich GA (1999) Galectins: an evolutionarily conserved family of animal lectins with multifunctional properties; a trip from the gene to clinical therapy. *Cell Death Differ* 6:711-721.
42. Rabinovich GA, Baum LG, Tinari N, Paganelli R, Natoli C, Liu FT, Iacobelli S (2002) Galectins and their ligands: amplifiers, silencers or tuners of the inflammatory response? *Trends Immunol* 23:313-320.
43. Riemenschneider MJ, Koy TH, Reifenberger G (2004) Expression of oligodendrocyte lineage genes in oligodendroglial and astrocytic gliomas. *Acta Neuropathol (Berl)* 107:277-282.
44. Rutka JT, Apodaca G, Stern R, Rosenblum M (1998) The extracellular matrix of the central and peripheral nervous systems: structure and function. *J Neurosurg* 69:155-170.
45. Sato S, Hughes RC (1992) Binding specificity of a baby hamster kidney lectin for H type I and II chains, polylectosamine glycans, and appropriately glycosylated forms of laminin and fibronectin. *J Biol Chem* 267:6983-6990.
46. Seve AP, Felin M, Doyennette-Moyne MA, Sahraoui T, Aubery M, Hubert J (1993) Evidence for a lactose-mediated association between two nuclear carbohydrate-binding proteins. *Glycobiology* 3:23-30.
47. Strik HM, Deininger MH, Frank B, Schluesener HJ, Meyermann R (2001) Galectin-3: cellular distribution and correlation with WHO-grade in human gliomas. *J Neurooncol* 53:13-20.
48. van den Bent MJ, Chinot O, Boogerd W, Bravo Marques J, Taphoorn MJ, Kros JM, van der Rijt CC, Vecht CJ, De Beule N, Baron B (2003) Second-line chemotherapy with temozolomide in recurrent oligodendroglioma after PCV (procarbazine, lomustine and vincristine) chemotherapy: EORTC Brain Tumor Group phase II study 26972. *Ann Oncol* 14:599-602.
49. Yang RY, Hsu DK, Liu FT (1996) Expression of galectin-3 modulates T-cell growth and apoptosis. *Proc Natl Acad Sci U S A* 93:6737-6742.
50. Yang RY, Liu FT (2003) Galectins in cell growth and apoptosis. *Cell Mol Life Sci* 60:267-276.
51. Yates AJ, Comas T, Scheithauer BW, Burger PC, Pearl DK (1999) Glycolipid markers of astrocytomas and oligodendrogliomas. *J Neuropathol Exp Neurol* 58:1250-1262.