



HHS Public Access

Author manuscript

Pediatr Res. Author manuscript; available in PMC 2021 September 25.

Published in final edited form as:

Pediatr Res. 2021 August ; 90(2): 397–402. doi:10.1038/s41390-020-01265-w.

Prenatal opioid exposure is associated with smaller brain volumes in multiple regions

Stephanie L. Merhar^{1,2}, Julia E. Kline¹, Adebayo Braimah³, Beth M. Kline-Fath⁴, Jean A. Tkach⁴, Mekibib Altaye^{2,5}, Lili He^{1,2}, Nehal A. Parikh^{1,2}

¹Perinatal Institute, Division of Neonatology, Cincinnati Children's Hospital,

²University of Cincinnati Department of Pediatrics

³Imaging Research Center, Cincinnati Children's Hospital,

⁴Department of Radiology, Cincinnati Children's Hospital,

⁵Division of Biostatistics and Epidemiology, Cincinnati Children's Hospital

Abstract

Background: The impact of prenatal opioid exposure on brain development remains poorly understood.

Methods: We conducted a prospective study of term-born infants with and without prenatal opioid exposure. Structural brain MRI was performed between 40–48 weeks postmenstrual age. T2-weighted images were processed using the Developing Human Connectome Project structural pipeline. We compared 63 relative regional brain volumes between groups.

Results: Twenty-nine infants with prenatal opioid exposure and 42 unexposed controls were included. The groups had similar demographics, except exposed infants had lower birth weights, more maternal smoking and maternal Hepatitis C, fewer mothers with a college degree, and were more likely non-Hispanic White. After controlling for sex, postmenstrual age at scan, birth weight, and maternal education, exposed infants had significantly smaller relative volumes of the deep gray matter, bilateral thalamic ventrolateral nuclei, bilateral insular white matter,

Users may view, print, copy, and download text and data-mine the content in such documents, for the purposes of academic research, subject always to the full Conditions of use:http://www.nature.com/authors/editorial_policies/license.html#terms

Address correspondence to: Stephanie Merhar MD MS Perinatal Institute, Cincinnati Children's Hospital, 3333 Burnet Ave ML 7009, Cincinnati OH 45229, stephanie.merhar@cchmc.org, phone 513-803-5180, fax 513-636-5454.

Author contributions:

Dr Merhar conceptualized and designed the study, drafted the initial manuscript, and revised the manuscript for important intellectual content.

Dr. Kline supervised data analysis, developed the figures, and revised the manuscript for important intellectual content.

Mr. Braimah performed data analysis and revised the manuscript for important intellectual content.

Dr. Kline-Fath supervised data acquisition and revised the manuscript for important intellectual content.

Dr. Tkach implemented the MRI protocol, supervised data acquisition and revised the manuscript for important intellectual content.

Dr. Altaye performed statistical analysis and revised the manuscript for important intellectual content.

Dr. He collected data and revised the manuscript for important intellectual content.

Dr. Parikh supervised data collection and analysis, interpreted the data, and revised the manuscript for important intellectual content. All authors approved the final manuscript as submitted and agree to be accountable for all aspects of the work.

Disclosure statement: The authors have no conflicts of interest relevant to this article to disclose.

Category of study: Clinical Research

Consent statement: Consent was required from a parent/legal guardian for this study

bilateral subthalamic nuclei, brainstem, and cerebrospinal fluid. Exposed infants had larger relative volumes of the right cingulate gyrus white matter and left occipital lobe white matter.

Conclusion: Infants with prenatal opioid exposure had smaller brain volumes in multiple regions compared to controls, with two regions larger in the opioid-exposed group. Further research should focus on the relative contributions of maternal opioids and other exposures.

Introduction

The United States is in the midst of an opioid epidemic, with one infant born exposed to opioids every 15 minutes(1). Opioids cross the placenta and the blood brain barrier(2, 3), but the effects of prenatal opioid exposure on the brain remain poorly characterized. Prenatal opioid exposure has been associated with adverse behavioral and developmental outcomes(4, 5), but it is unclear whether the association is due to direct effects of opioids on the brain and/or to other confounding factors such as polysubstance use, maternal stress, or parenting.

Animal studies have consistently shown negative effects of prenatal opioids on the brain. In experimental models, prenatal exposure to buprenorphine or methadone affects neurotransmitter biosynthesis(6), neurogenesis(7), and myelination(8, 9). *In vitro* studies in human cells have shown that morphine increases apoptosis in human fetal microglia and neurons(10), suggesting that these animal studies may be applicable to humans. In adult humans, adverse changes in regional brain volumes are seen after even short-term opioid exposure(11, 12). Volumetric studies in older children and adolescents have also shown smaller brain volumes in multiple regions in opioid(13) and polysubstance(14) exposed children. Studies in older children may be confounded by the multiple experiences opioid-exposed children have during infancy and childhood, including adverse home environments and other stressors. Only one previous study has evaluated brain volumes in infants(15). This pilot study found significantly smaller whole brain and basal ganglia volumes and larger lateral ventricular volumes in opioid-exposed infants compared to population means, but no control group was used.

Given the paucity of literature on this topic, additional studies evaluating the effects of prenatal opioid exposure on early brain development are warranted. The objective of our current study was to compare regional brain volumes in term-born infants <8 weeks of age with prenatal opioid exposure and age-matched unexposed controls.

Methods

Subjects

Infants born at >37 weeks gestation with prenatal opioid exposure and no other medical problems were recruited from Cincinnati-area birth hospitals or from the Opioid Exposed Clinic or Neonatal Abstinence Syndrome Clinic at Cincinnati Children's Hospital. Infants were screened for inclusion/exclusion criteria by trained research coordinators and eligible infants were approached for participation. Healthy control infants born at >37 weeks gestation were recruited from the same birth hospitals, from the Pediatric Primary Care clinic at Cincinnati Children's using a study flyer in their newborn care packet, or through

our Office of Clinical and Translational Research using flyers posted around the hospital and on the website. Infants were recruited between April 2018 and October 2019. Infants with known chromosomal or congenital anomalies, Apgar score at 5 minutes of <7, any requirement for positive pressure ventilation after birth, and any head trauma were excluded from both groups. Opioid exposure was determined by maternal urine toxicology screen at the time of delivery and confirmed with neonatal toxicology screen (meconium or umbilical cord). Lack of opioid or other drug exposure in controls was confirmed by maternal urine toxicology screen at the time of delivery, which is standard clinical practice in our region. Additional information about drug exposure was collected by review of infant medical records and by maternal questionnaire at the time of MRI. Neonatal abstinence syndrome (NAS) was defined as clinically prescribed treatment with opioid replacement medication after birth. Pregnancy and birth history were collected by review of infant medical records. Information about maternal socioeconomic status (education, employment, income) and race was collected by maternal questionnaire at the time of MRI. This study was approved by the Institutional Review Boards at Cincinnati Children's Hospital, University of Cincinnati Medical Center, Good Samaritan Hospital, and St. Elizabeth Hospital. Written informed consent was obtained from a parent or guardian prior to any study procedures.

Imaging methods

Infants were scanned between 40 and 48 weeks postmenstrual age during sleep with no sedation. Infants were fed, swaddled, fitted with ear protection, placed in the Med-Vac vacuum bag, and moved into the scanner bore. All infants were scanned on the same Philips 3T Ingenia scanner in the Imaging Research Center at Cincinnati Children's Hospital using a 32 channel receive head coil. Structural MR imaging included a sagittal magnetization prepared inversion recovery 3D T1-weighted gradient echo sequence (shot interval = 2300 milliseconds, repetition time = 7.6 milliseconds, echo time = 3.6 milliseconds, inversion time = 1100 milliseconds, flip angle = 11°, voxel size 1mm × 1mm × 1mm, acceleration (SENSE) = 1 in plane and 2.0 through plane (slice) phase encode, scan time 3 minutes 6 seconds) and an axial 2D T2-weighted fast spin echo sequence (repetition time = 19100–19500 milliseconds, echo time = 166 milliseconds, voxel size 1mm × 1.11mm × 1mm, acceleration (SENSE) = 1.5/in plane phase encode, scan time 3 minutes 50 seconds).

MRI processing

T2-weighted images were processed using the developing Human Connectome Project (dHCP) pipeline(16, 17). The dHCP pipeline automatically performs cortical and sub-cortical volume segmentation, resulting in 87 segmentations and 5 combined regions. All tissue segmentations were visually inspected for accuracy. A representative segmentation is shown in Figure 1. The “deep gray matter” segmentation includes the thalamus, subthalamic nucleus, caudate, lentiform, and intracranial background (Antonios Makropoulos, personal communication, March 2020).

Statistical analysis

All statistical analysis was performed in STATA 16.0 (Stata Corp., College Station, TX). For the purposes of this analyses, we excluded the subsegmentations (e.g., the anterior/posterior parts of structures) and instead included only the “merged regions”. We also excluded the

“gyri parahippocampalis et ambiens”, which is a very small brain region that in our prior work has likely shown spurious associations(18). We thus analyzed volume differences in 58 regions of the brain and 5 combined regions (supplementary Table 1). Relative regional volumes were used for all analyses (i.e., the volume of the region divided by the total volume of brain tissue).

Descriptive statistics for the two groups (opioid-exposed and controls) were computed. Groups were compared using two-sided t-tests for continuous variables and Fisher’s exact test for categorical variables. We compared regional brain volumes between the two groups by performing a multivariable linear regression which allowed us to control for the potential confounding effects of infant sex, postmenstrual age (PMA) at scan, birth weight, and maternal education for each of the 63 regions. Since birth weight and maternal education were found to be significantly different between the opioid and unexposed groups, these were also included in the regression model as covariates. We performed a sensitivity analysis removing birth weight from the model, and results were unchanged. Sex and PMA at scan were not significantly different between groups; however, since even small group differences in these variables can affect brain development and volumes, we opted to control for them in the model. We did not include maternal Hepatitis C and maternal smoking in the model due to no Hepatitis C and very little smoking in the control group. We also performed a sensitivity analysis including only infants who were exposed only to opioids and not other substances. Correction for multiple comparisons was not performed given the preliminary nature of this study(19). All significance is reported at $p < 0.05$.

Results

Twenty-nine infants with prenatal opioid exposure and 42 controls with no opioid or other drug exposure were recruited for the study. All scans were successfully processed with the dHCP pipeline and included in the analysis. As shown in Table 1, infants with prenatal opioid exposure and unexposed controls had comparable baseline characteristics, except opioid-exposed infants had smaller birth weights, increased rates of maternal smoking and maternal Hepatitis C, fewer mothers with a college degree, and were more likely non-Hispanic White. None of the infants in either group had known alcohol exposure during pregnancy, although one mother in each group endorsed drinking alcohol in the first trimester before the pregnancy was known. In the opioid-exposed group, 4/29 infants had additional exposures: 2 infants to THC only, one infant to THC and cocaine, and one infant to cocaine and methamphetamines.

Infants with prenatal opioid exposure had decreased relative volumes of the deep gray matter, bilateral ventrolateral nuclei of thalamus, bilateral subthalamic nuclei, bilateral insular white matter, brainstem, and cerebrospinal fluid (CSF), after adjustment for sex, PMA at MRI, birth weight, and maternal education (Table 2, Figure 2). Infants with prenatal opioid exposure had increased relative brain volumes of the white matter of the right cingulate gyrus and white matter of the left occipital lobe. Sensitivity analysis removing the 4 infants with additional exposures besides opioids resulted in 4 regions (overall deep gray, L insular white matter, and bilateral subthalamic nuclei) no longer being significantly different, with p values of 0.09, 0.09, 0.09, and 0.06, respectively. Although all analysis were

conducted using relative volumes, for ease of interpretation we presented volumes in mm³. This was accomplished by multiplying the least squares means and corresponding values obtained from the relative volume analysis by the average brain volume of the groups.

Discussion

We found that infants with prenatal opioid exposure had smaller overall deep gray matter, thalamus, subthalamic nucleus, insular white matter, brainstem, and CSF volumes compared to unexposed infants, but larger volumes of white matter in the right cingulate gyrus and left occipital lobe. This study builds on previous literature in opioid and polysubstance-exposed infants and children showing smaller regional brain volumes in exposed children compared with controls, with significant overlap in regions found in previous literature.

Opioids are known to cross the human placenta and the blood-brain barrier(2). Opioid exposure could potentially change brain volumes through direct neurotoxicity or indirect vascular or metabolic effects(20, 21). Smaller gray matter volumes could be explained by decreased neurogenesis, increased apoptosis, or decreased density. Opioids induce neuronal apoptosis in animal models(22, 23) and human fetal neurons(10). Opioids decrease neurogenesis(7, 24) and decrease dendritic spine density, both of which could explain smaller brain volumes(25, 26). Smaller white matter volumes could be explained by altered microglia(27) and decreased myelin production(9, 27) or Wallerian degeneration after damage to gray matter(28). However, larger white matter volumes could also be pathologic, reflecting inappropriate pruning or increased connections in pathways related to stress(29, 30).

Few volumetric studies have been performed on children exposed to opioids *in utero*. A small study of 16 newborns with prenatal opioid exposure showed smaller whole brain and basal ganglia volumes compared to population norms, but no control group was used(15). Another study in 16 opioid-exposed children aged 10–14 years showed smaller volumes of basal ganglia, thalamus, and cerebellar white matter when compared to matched controls(13). A third small study in 14 children with prenatal substance exposure (10 exposed to opioids) and 14 controls found reduced regional volumes of multiple areas, including the cortex, amygdala, accumbens, putamen, pallidum, brainstem, and cerebellum in the substance-exposed group(14). Other studies in infants and children with prenatal opioid exposure have found differences in white matter microstructure(31, 32) and reductions in head circumference(33–35). We did not find differences in head circumference or overall brain volume in infants in our study.

We found that the ventrolateral thalami, subthalamic nuclei, and overall deep gray matter were smaller in infants exposed to opioids. The thalamus is an important structure in drug addiction(36). The ventrolateral thalami are integral structures in the dopaminergic reward circuit(37). Smaller thalamic gray matter volumes have been found for subjects using various substances, including alcohol, cocaine, nicotine, methamphetamine, opioids, and cannabinoids(36). The thalamus had lower glucose metabolism on PET scanning in adult subjects with opioid dependence than healthy controls(38). However, a meta-analysis of imaging gray matter abnormalities in opioid-dependent adults did not find significant

decreases in thalamic volumes(39). The subthalamic nucleus is part of the dopamine-rich basal ganglia, which play a role in addiction(40). The basal ganglia are smaller in children with prenatal substance exposure in multiple studies(13–15).

Brainstem volumes were also smaller in opioid-exposed infants. The brainstem is rich in opioid receptors, particularly in the ventral tegmental area of the midbrain(41). One small study of children exposed to opioids and other substances *in utero* also found the brainstem to be smaller compared with controls(14).

We found smaller insular white matter bilaterally in infants exposed to opioids. The insula is thought to be essential in drug addiction(42) as it acts as a hub for many regions relevant to substance use(39). In both animal studies(43) and studies of adult tobacco users(44), lesions of the insula appear to eliminate addiction to smoking. Decreased gray matter has been found in the insula of adult opioid users(12, 45, 46), including adults with chronic back pain randomized to 1 month of oral morphine as compared to those randomized to placebo(12).

Cerebrospinal fluid volumes were smaller in opioid-exposed infants. Overall brain volumes did not differ between groups, nor did ventricular volumes. This decreased CSF volume in the opioid-exposed group with similar brain and ventricle volumes suggests that the regional volumetric decreases we found in the opioid-exposed group are not due to atrophy but rather maldevelopment of specific structures.

We found larger volumes of the right cingulate gyrus white matter in infants exposed to opioids prenatally. The anterior cingulate gyrus is highly connected to limbic structures in the brain and is a frontocortical area strongly associated with drug addiction(47). In the study discussed above, in which adults with back pain were randomized to 1 month of oral morphine or placebo, morphine administration was associated with increased gray matter in the cingulate cortex.(12) A similar study in adults with back pain administered morphine also showed dosage-correlated volumetric increase in the right ventral posterior cingulate(11). Chronic stress increases white matter connectivity in the cingulum in mice(29) and humans(30).

Opioid-exposed infants also had larger volumes of the left occipital lobe white matter. Multiple white matter tracts in the occipital lobe connect the visual cortex to other areas of the brain(48). Several case series have shown that children exposed to opioids *in utero* have altered visual development(49–51), but the mechanism by which larger white matter volumes could explain these visual changes is unclear.

Strengths of our study include high-resolution imaging at 3T with regional volumes determined by an automated pipeline, decreasing human error. We had rigorous information on drug exposure, with maternal urine toxicology at the time of delivery for opioid-exposed infants and controls, and biological samples (cord or meconium) for all opioid-exposed infants. We imaged infants before 8 weeks of age, which allowed for the minimization of the effects of caregiving and the home environment compared with imaging in older children. Limitations include the small sample size, although our study is larger than brain volume studies previously published in this population. We were unable to control for maternal smoking and Hepatitis C. Maternal smoking may be particularly relevant to brain

development(52) and neurodevelopmental outcomes(53, 54) and future studies must be designed with the ability to control for this important variable. Although we had maternal report on alcohol use during pregnancy, we did not have any biomarkers of alcohol use, and a previous paper has suggested that opioid use and alcohol use disorder often coexist(55). Other potential confounders that we were unable to account for included maternal stress and maternal psychiatric disorders.

Conclusions

In this prospective imaging study of opioid-exposed infants and unexposed controls imaged between 40–48 weeks postmenstrual age, we found multiple differences in regional brain volumes between groups. More research is needed to understand how the type, timing, and duration of opioid exposure, as well as other confounding factors such as maternal smoking during pregnancy, affect the developing brain and subsequent neurodevelopment.

Supplementary Material

Refer to Web version on PubMed Central for supplementary material.

Funding source:

KL2 TR001426 (SM), R01 NS094200 (NP), R01 NS096037 (NP)

Statement of financial support: The authors have no financial relationships relevant to this article to disclose.

References

1. Honein MA, Boyle C, Redfield RR. Public Health Surveillance of Prenatal Opioid Exposure in Mothers and Infants. *Pediatrics* 143 (2019).
2. Concheiro Met al. Maternal buprenorphine dose, placenta buprenorphine, and metabolite concentrations and neonatal outcomes. *Ther Drug Monit* 32:206–215 (2010). [PubMed: 20216119]
3. Chaves C, Remiao F, Cisternino S, Declèves X. Opioids and the Blood-Brain Barrier: A Dynamic Interaction with Consequences on Drug Disposition in Brain. *Curr Neuropharmacol* 15:1156–1173 (2017). [PubMed: 28474563]
4. Yeoh S Let al. Cognitive and Motor Outcomes of Children With Prenatal Opioid Exposure: A Systematic Review and Meta-analysis. *JAMA Netw Open* 2:e197025 (2019). [PubMed: 31298718]
5. Larson J Jet al. Cognitive and Behavioral Impact on Children Exposed to Opioids During Pregnancy. *Pediatrics* 144 (2019).
6. Wu VW, Mo Q, Yabe T, Schwartz JP, Robinson SE. Perinatal opioids reduce striatal nerve growth factor content in rat striatum. *Eur J Pharmacol* 414:211–214 (2001). [PubMed: 11239921]
7. Wu CC et al. Prenatal buprenorphine exposure decreases neurogenesis in rats. *Toxicol Lett* 225:92–101 (2014). [PubMed: 24321744]
8. Vestal-Laborde AA, Eschenroeder AC, Bigbee JW, Robinson SE, Sato-Bigbee C. The opioid system and brain development: effects of methadone on the oligodendrocyte lineage and the early stages of myelination. *Dev Neurosci* 36:409–421 (2014). [PubMed: 25138998]
9. Sanchez ES, Bigbee JW, Fobbs W, Robinson SE, Sato-Bigbee C. Opioid addiction and pregnancy: perinatal exposure to buprenorphine affects myelination in the developing brain. *Glia* 56:1017–1027 (2008). [PubMed: 18381654]
10. Hu S, Sheng WS, Lokensgard JR, Peterson PK. Morphine induces apoptosis of human microglia and neurons. *Neuropharmacology* 42:829–836 (2002). [PubMed: 12015209]

11. Younger JW et al. Prescription opioid analgesics rapidly change the human brain. *Pain* 152:1803–1810 (2011). [PubMed: 21531077]
12. Lin JC et al. One Month of Oral Morphine Decreases Gray Matter Volume in the Right Amygdala of Individuals with Low Back Pain: Confirmation of Previously Reported Magnetic Resonance Imaging Results. *Pain Med* 17:1497–1504 (2016). [PubMed: 26814280]
13. Sirnes E et al. Brain morphology in school-aged children with prenatal opioid exposure: A structural MRI study. *Early Hum Dev* 106–107:33–39 (2017).
14. Walhovd KB et al. Volumetric cerebral characteristics of children exposed to opiates and other substances in utero. *Neuroimage* 36:1331–1344 (2007). [PubMed: 17513131]
15. Yuan Q et al. Do maternal opioids reduce neonatal regional brain volumes? A pilot study. *J Perinatol* 34:909–913 (2014). [PubMed: 24945162]
16. Makropoulos A et al. The developing human connectome project: A minimal processing pipeline for neonatal cortical surface reconstruction. *Neuroimage* 173:88–112 (2018). [PubMed: 29409960]
17. Makropoulos A et al. Automatic whole brain MRI segmentation of the developing neonatal brain. *IEEE Trans Med Imaging* 33:1818–1831 (2014). [PubMed: 24816548]
18. Kline JE, Illapani VSP, He L, Altaye M, Parikh NA. Retinopathy of Prematurity and Bronchopulmonary Dysplasia are Independent Antecedents of Cortical Maturational Abnormalities in Very Preterm Infants. *Sci Rep* 9:19679 (2019). [PubMed: 31873183]
19. Rothman KJ. No adjustments are needed for multiple comparisons. *Epidemiology* 1:43–46 (1990). [PubMed: 2081237]
20. Cunha-Oliveira T, Rego AC, Oliveira CR. Cellular and molecular mechanisms involved in the neurotoxicity of opioid and psychostimulant drugs. *Brain Res Rev* 58:192–208 (2008). [PubMed: 18440072]
21. Brown GG, Jacobus J, McKenna B. Structural imaging for addiction medicine: From neurostructure to neuroplasticity. *Prog Brain Res* 224:105–127 (2016). [PubMed: 26822356]
22. Tramullas M, Martínez-Cué C, Hurlé M. Chronic administration of heroin to mice produces up-regulation of brain apoptosis-related proteins and impairs spatial learning and memory. *Neuropharmacology* 54:640–652 (2008). [PubMed: 18201731]
23. Wang Y, Han TZ. Prenatal exposure to heroin in mice elicits memory deficits that can be attributed to neuronal apoptosis. *Neuroscience* 160:330–338 (2009). [PubMed: 19272431]
24. Eisch AJ, Barrot M, Schad CA, Self DW, Nestler EJ. Opiates inhibit neurogenesis in the adult rat hippocampus. *Proc Natl Acad Sci U S A* 97:7579–7584 (2000). [PubMed: 10840056]
25. Liao D, Lin H, Law PY, Loh HH. Mu-opioid receptors modulate the stability of dendritic spines. *Proc Natl Acad Sci U S A* 102:1725–1730 (2005). [PubMed: 15659552]
26. Liao D et al. Distinct effects of individual opioids on the morphology of spines depend upon the internalization of mu opioid receptors. *Mol Cell Neurosci* 35:456–469 (2007). [PubMed: 17513124]
27. Jantzie LL et al. Prenatal opioid exposure: The next neonatal neuroinflammatory disease. *Brain Behav Immun* 84:45–58 (2020). [PubMed: 31765790]
28. Wollman SC et al. White matter abnormalities in long-term heroin users: a preliminary neuroimaging meta-analysis. *Am J Drug Alcohol Abuse* 41:133–138 (2015). [PubMed: 25664621]
29. Grandjean J et al. Chronic psychosocial stress in mice leads to changes in brain functional connectivity and metabolite levels comparable to human depression. *Neuroimage* 142:544–552 (2016). [PubMed: 27520750]
30. Bierer LM et al. White matter abnormalities in Gulf War veterans with posttraumatic stress disorder: A pilot study. *Psychoneuroendocrinology* 51:567–576 (2015). [PubMed: 25465169]
31. Monnelly VJ, et al. Prenatal methadone exposure is associated with altered neonatal brain development. *Neuroimage Clin* 18:9–14 (2018). [PubMed: 29326869]
32. Walhovd KB, Watts R, Amlien I, Woodward LJ. Neural tract development of infants born to methadone-maintained mothers. *Pediatr Neurol* 47:1–6 (2012). [PubMed: 22704008]
33. Towers CV et al. Neonatal Head Circumference in Newborns With Neonatal Abstinence Syndrome. *Pediatrics* 143 (2019).

34. Hytinen Tet al. Neonatal outcome of 58 infants exposed to maternal buprenorphine in utero. *Acta Paediatr*97:1040–1044 (2008). [PubMed: 18474065]
35. Garrison Let al. Fetal Growth Outcomes in a Cohort of Polydrug- and Opioid-Dependent Patients. *J Reprod Med*61:311–319 (2016). [PubMed: 29075045]
36. Huang AS, Mitchell JA, Haber SN, Alia-Klein N, Goldstein RZ The thalamus in drug addiction: from rodents to humans. *Philos Trans R Soc Lond B Biol Sci*373 (2018).
37. Haber S, McFarland NR The place of the thalamus in frontal cortical-basal ganglia circuits. *Neuroscientist*7:315–324 (2001). [PubMed: 11488397]
38. Prosser J, London ED, Galynker II Sustained attention in patients receiving and abstinent following methadone maintenance treatment for opiate dependence: performance and neuroimaging results. *Drug Alcohol Depend*104:228–240 (2009). [PubMed: 19608356]
39. Wollman SC et al. Gray matter abnormalities in opioid-dependent patients: A neuroimaging meta-analysis. *Am J Drug Alcohol Abuse*43:505–517 (2017). [PubMed: 27808568]
40. Koob GF, Volkow ND Neurobiology of addiction: a neurocircuitry analysis. *Lancet Psychiatry*3:760–773 (2016). [PubMed: 27475769]
41. Ting-A-Kee R, van der Kooy D The neurobiology of opiate motivation. *Cold Spring Harb Perspect Med*2 (2012).
42. Droutman V, Read SJ, Bechara A Revisiting the role of the insula in addiction. *Trends Cogn Sci*19:414–420 (2015). [PubMed: 26066588]
43. Scott D, Hiroi ND Deconstructing craving: dissociable cortical control of cue reactivity in nicotine addiction. *Biol Psychiatry*69:1052–1059 (2011). [PubMed: 21429478]
44. Naqvi NH, Rudrauf D, Damasio H, Bechara A Damage to the insula disrupts addiction to cigarette smoking. *Science*315:531–534 (2007). [PubMed: 17255515]
45. Lyoo IK et al. Prefrontal and temporal gray matter density decreases in opiate dependence. *Psychopharmacology (Berl)*184:139–144 (2006). [PubMed: 16369836]
46. Gardini S, Venneri A Reduced grey matter in the posterior insula as a structural vulnerability or diathesis to addiction. *Brain Res Bull*87:205–211 (2012). [PubMed: 22178355]
47. Goldstein RZ, Volkow ND Dysfunction of the prefrontal cortex in addiction: neuroimaging findings and clinical implications. *Nat Rev Neurosci*12:652–669 (2011). [PubMed: 22011681]
48. Takemura H et al. Occipital White Matter Tracts in Human and Macaque. *Cereb Cortex*27:3346–3359 (2017). [PubMed: 28369290]
49. Hamilton R et al. Ophthalmic, clinical and visual electrophysiological findings in children born to mothers prescribed substitute methadone in pregnancy. *Br J Ophthalmol*94:696–700 (2010). [PubMed: 20410537]
50. McGlone L et al. Visual outcome in infants born to drug-misusing mothers prescribed methadone in pregnancy. *Br J Ophthalmol*98:238–245 (2014). [PubMed: 24246372]
51. Spiteri Cornish K, Hrabovsky M, Scott NW, Myerscough E, Reddy AR The short- and long-term effects on the visual system of children following exposure to maternal substance misuse in pregnancy. *Am J Ophthalmol*156:190–194 (2013). [PubMed: 23628351]
52. El Marroun H et al. Prenatal tobacco exposure and brain morphology: a prospective study in young children. *Neuropsychopharmacology*39:792–800 (2014). [PubMed: 24096296]
53. Nelson L F et al. Cognitive Outcomes of Young Children After Prenatal Exposure to Medications for Opioid Use Disorder: A Systematic Review and Meta-analysis. *JAMA Netw Open*3:e2011195 (2020). [PubMed: 32186745]
54. Holz N E et al. Effect of prenatal exposure to tobacco smoke on inhibitory control: neuroimaging results from a 25-year prospective study. *JAMA Psychiatry*71:786–796 (2014). [PubMed: 24828276]
55. Bakhireva L N et al. Prevalence of alcohol use in pregnant women with substance use disorder. *Drug Alcohol Depend*187:305–310 (2018). [PubMed: 29704852]

Impact statement:

- Prenatal opioid exposure is associated with developmental and behavioral consequences, but the direct effects of opioids on the developing human brain are poorly understood
- Prior small studies using MRI have shown smaller regional brain volumes in opioid-exposed infants and children
- After controlling for covariates, infants with prenatal opioid exposure scanned at 40–48 weeks postmenstrual age had smaller brain volumes in multiple regions compared to controls, with two regions larger in the opioid-exposed group
- This adds to the literature showing potential impact of prenatal opioid exposure on the developing brain

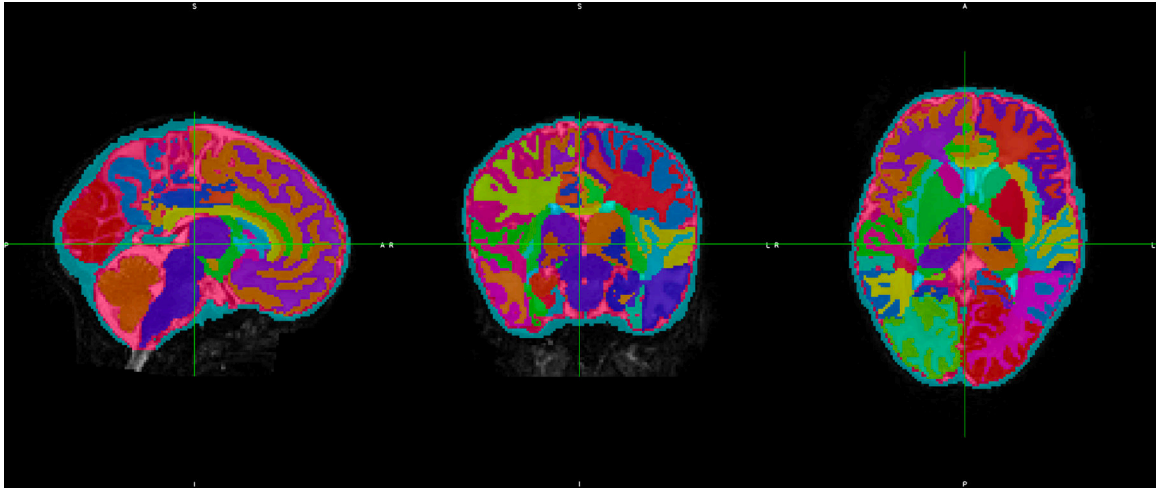


Figure 1.
Representative segmentation of a neonatal brain showing different brain regions automatically segmented using the dHCP pipeline

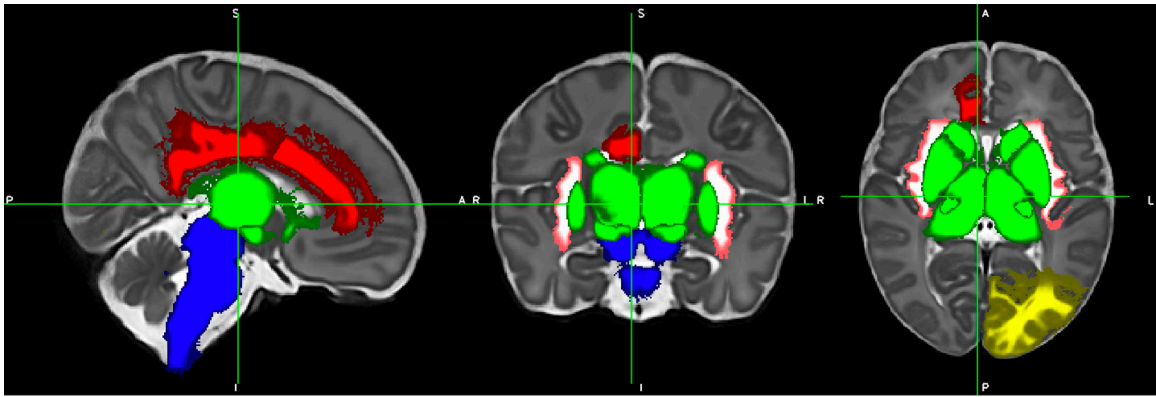


Figure 2.

Differences in regional volumes between opioid-exposed and control infants. Blue = brainstem (smaller in exposed infants). White/pink = bilateral insular white matter (smaller in exposed infants). Green = deep gray matter including ventrolateral nuclei and subthalamic nuclei (smaller in exposed infants). Red = right cingulate gyrus white matter (larger in exposed infants). Yellow = left occipital lobe white matter (larger in exposed infants). Cerebrospinal fluid volume (not pictured) was also smaller in opioid-exposed infants.

Table 1

Demographics of study population

	Opioid-exposed (n=29)	Controls (n=42)	p value
Male, n (%)	10 (34%)	20 (48%)	0.27
Gestational age at birth (weeks), mean (SD)	38.9 (1.1)	39.0 (0.72)	0.55
Birth weight (g), mean (SD)	3048 (299)	3274 (432)	0.02
Head circumference at birth (cm), mean (SD)	34.1 (1.3)	34.0 (1.4)	0.89
Postmenstrual age at scan (weeks), mean (SD)	44.7 (1.2)	44.0 (2.0)	0.07
Race/ethnicity			0.004
Non-Hispanic White	24	20	
Non-Hispanic Black	4	20	
Non-Hispanic Asian	0	1	
Hispanic White	1	1	
Maternal smoking, n (%)	25 (86%)	3 (7%)	<0.001
Reported maternal alcohol use during pregnancy	1 (3%)	1 (2%)	1.0
Maternal Hepatitis C, n (%)	19 (66%)	0 (0%)	<0.001
Maternal college degree, n (%)	5 (17%)	24 (57%)	0.001
Maternal methadone, n (%)	12 (41%)	n/a	n/a
Maternal buprenorphine, n (%)	15 (52%)	n/a	n/a
Maternal heroin and/or fentanyl, n (%)	12 (41%)	n/a	n/a
Neonatal abstinence syndrome requiring opioid treatment, n (%)	13 (45%)	n/a	n/a

Two-sided t-test was used to compare continuous variables and Fisher's exact test was used to compare categorical variables.

Table 2
Least squares means and standard error of brain volumes and percent differences in exposed and control groups

	Exposed (n=29)		Control (n=42)		LS Mean difference	95% confidence interval (lower bound)	95% confidence interval (upper bound)	P value	% difference
	LS Mean volume (mm ³)	SE	LS Mean volume (mm ³)	SE					
Deep gray matter	30657.8	307.3	31507.5	229.3	-849.6	-1644.1	-55.0	0.037	-2.70
R thalamus ventrolateral nucleus	752.1	28.6	864.2	21.4	-112.1	-186.0	-38.0	0.004	-13.0
L thalamus ventrolateral nucleus	719.1	31.6	824.1	23.6	-105.1	-186.8	-23.5	0.012	-12.8
R insula white matter	2659.1	44.0	2871.6	32.8	-212.5	-326.1	-99.0	0.000	-7.4
L insula white matter	2582.6	47.1	2745.1	35.2	-162.5	-284.3	-40.7	0.010	-5.9
R subthalamic nucleus	270.6	6.3	287.6	4.7	-17.0	-33.2	-0.8	0.040	-5.9
L subthalamic nucleus	239.2	6.3	256.9	4.7	-17.8	-34.0	-1.6	0.032	-6.9
Brainstem	6870.3	117.3	7258.8	87.6	-388.5	-691.7	-85.1	0.013	-5.4
Cerebrospinal fluid	95493.6	3397.3	106689.9	2535.5	-11196.3	-19980.1	-2412.6	0.013	-10.5
R cingulate gyrus white matter	3271.1	60.7	3086.7	45.3	184.4	27.5	341.5	0.022	6.0
L occipital lobe white matter	7623.2	160.9	7197.0	120.1	426.2	10.2	842.3	0.045	5.9

Percent differences were calculated using the relative volumes adjusted for covariates. For ease of interpretation, we have reported the least square means and standard errors, derived by multiplying the least square means from the original regression analysis by the average brain volume of all subjects.