

# Cryptococcosis complicating diabetes mellitus: a scoping review

Lauryn Nsenga, Jonathan Kajjimu, Ronald Olum, Sandra Ninsiima, Andrew Peter Kyazze, Phillip Ssekamatte, Davis Kibirige, Joseph Baruch Baluku, Irene Andia-Biraro and Felix Bongomin 

*Ther Adv Infectious Dis*

2021, Vol. 8: 1–10

DOI: 10.1177/  
20499361211014769

© The Author(s), 2021.  
Article reuse guidelines:  
sagepub.com/journals-  
permissions

## Abstract

**Background:** A better understanding of the epidemiology of cryptococcal infection in HIV-negative individuals is an international research interest. Immune dysfunction in diabetes mellitus (DM) significantly increases the risk of acquiring and reactivation of infection due to *Cryptococcus neoformans*. Risk factors and outcomes of cryptococcosis in DM are not well documented.

**Objective:** The objective of this study was to determine the clinical characteristics and outcomes of cryptococcal infections in persons living with DM.

**Methods:** MEDLINE (via PubMed), EMBASE, and the Cochrane Library databases were searched in November 2020. The searches covered the period between 1980 and 2020. We included studies that reported confirmed cryptococcosis in patients with DM. Reference lists of included articles were also searched, and additional studies were included if appropriate. No language restriction was applied. Single case reports, case series and original articles were included whereas review articles were excluded.

**Results:** A total of 28 studies (24 single case reports, 4 retrospectives) were included involving 47 unique patients from Asia (17 cases), North America (six cases), South America (three cases) and Africa (two cases). Men constituted 75% ( $n = 18$ ) of the cases. Median age was 60.5 (range: 27–79) years. The majority of the patients had cryptococcal meningitis (68.1%,  $n = 32$ ) followed by disseminated cryptococcosis (6.4%,  $n = 7$ ), and others (isolated cutaneous disease one, peritonitis one, pleural one, thyroid one, adrenal one). Diagnosis was achieved through either culture and microscopy (38/47), cryptococcal antigen tests (9/47) or histopathology (9/47) singly or in a combination. All-cause mortality was 38.3% ( $n = 18$ ). Among those with meningitis mortality was 36.2%.

**Conclusion:** A wide spectrum of cryptococcal infections with varying severity occurs in DM. Mortality remains unacceptably high. There is a need for more studies to characterize better cryptococcal disease in DM.

**Keywords:** clinical characteristics, cryptococcosis, diabetes mellitus, mortality

Received: 19 December 2020; revised manuscript accepted: 13 April 2021.

## Introduction

Cryptococcosis is an opportunistic, multi-systemic fungal infection with a predilection for the central nervous system (CNS). It is acquired through inhalation of airborne yeast cells (basidiospores) and subsequent pulmonary infection of mainly two etiological agents, *Cryptococcus neoformans* and *Cryptococcus gattii*.<sup>1</sup> Soil containing pigeon

droppings are the main reservoir for *C. neoformans*, whereas eucalyptus trees and decaying hollows in living trees are the major environmental source for *C. gattii*.<sup>2–4</sup> *C. neoformans* is the most predominant cause of cryptococcosis and accounts for 80% of cases globally. Immune suppressive states such as HIV/AIDS, immunosuppressive drugs, and solid organ transplant recipients are

Correspondence to:

**Felix Bongomin**  
Department of Medical  
Microbiology and  
Immunology, Faculty of  
Medicine, Gulu University,  
P.O. Box, 166, Gulu,  
Uganda  
[drbongomin@gmail.com](mailto:drbongomin@gmail.com)

**Lauryn Nsenga**  
School of Medicine, Kabale  
University, Kabale, Uganda

**Jonathan Kajjimu**  
Faculty of Medicine,  
Mbarara University of  
Science and Technology,  
Mbarara, Uganda

**Ronald Olum**  
**Sandra Ninsiima**  
**Andrew Peter Kyazze**  
Department of Medicine,  
College of Health  
Sciences, Makerere  
University, Kampala,  
Uganda

**Phillip Ssekamatte**  
Department of  
Immunology and  
Molecular Biology,  
School of Biomedical  
Sciences, Makerere  
University College of  
Health Sciences, Kampala,  
Uganda

**Davis Kibirige**  
Department of Medicine,  
Uganda Martyrs Lubaga  
Hospital, Kampala, Uganda  
Medical Research Council/  
Uganda Virus Research  
Institute and London  
School of Hygiene and  
Tropical Medicine, Uganda  
Research Unit, Entebbe,  
Uganda

**Joseph Baruch Baluku**  
Division of Pulmonology,  
Kiruddu National Referral  
Hospital, Kampala, Uganda  
Department of Programs,  
Mildmay Uganda, Wakiso,  
Uganda

**Irene Andia-Biraro**  
Department of  
Medicine, College  
of Health Sciences,  
Makerere University,  
Kampala, Uganda  
Medical Research  
Council/Uganda Virus  
Research Institute  
and London School of  
Hygiene and Tropical  
Medicine, Uganda  
Research Unit,  
Entebbe, Uganda

key risk factors for acquisition and reactivation of the infection. Conversely, *C. gattii* is less frequent (20%), and a growing number of cases occur mainly in immunocompetent individuals.<sup>5–7</sup>

There is growing data on the epidemiology of cryptococcosis among HIV-negative populations.<sup>8</sup> In a recent prospective study conducted among HIV-negative people in the United States, CNS cryptococcosis was found to be present in 50% of 145 study subjects with underlying immunosuppression, and was associated with recurrent neurological morbidities and pressure-related complications.<sup>9</sup> In a recent review of isolated pulmonary cryptococcosis among HIV-negative patients, men were found to be more prone than women, and isolated pulmonary cryptococcosis was associated with underlying diseases and immune dysfunction.<sup>10</sup> The key risk factors of cryptococcosis in HIV-negative individuals are systemic lupus erythematosus and other autoimmune rheumatic diseases, smoking, corticosteroid use, and chronic obstructive pulmonary disease,<sup>7</sup> cirrhosis,<sup>11</sup> pregnancy and diabetes mellitus (DM).<sup>12</sup>

DM is one of the most common predisposing underlying diseases for cryptococcosis in HIV-negative individuals, accounting for 10–20% of cryptococcosis patients with underlying diseases.<sup>10,13–15</sup> Cryptococcal meningitis in patients with DM is associated with poor clinical outcomes.<sup>16,17</sup> Hyperglycemia seen in DM patients causes defects in the host's immune system which predisposes DM patients to opportunistic infections such as cryptococcosis.<sup>18</sup> In mainland China, a retrospective study among Chinese individuals with type 2 DM found a hospital-based cryptococcal prevalence of 0.21%, with 62% having DM before infection.<sup>19</sup> In a study in Taiwan, in addition to DM being associated with the occurrence of cryptococcosis in HIV-negative patients, it was also found to be associated with a 1-year and overall mortality from cryptococcosis and cryptococcal meningitis.<sup>20</sup>

There have been few data available to understand cryptococcosis clinical manifestations, management, and outcomes of cryptococcosis in people without HIV.<sup>21</sup> In addition, the role of the different types of DM in the development of cryptococcosis in DM patients is unclear. We undertook this study to describe the epidemiology, clinical

manifestations and treatment outcomes of cryptococcosis in patients with DM through a scoping review of case reports, case series and studies of the epidemiology and clinical characteristics of DM patients with cryptococcosis.

## Methods

We systematically explored international medical databases: MEDLINE (via PubMed), Embase, and the Cochrane Library in November 2020. The searches covered the period between 1980 and 2020. The search terms used were 'disseminated cryptococcosis', 'cryptococcal meningitis', 'cryptococcal pneumonia', 'diabetic mellitus', 'organ transplant'. Boolean operators AND, OR and NOT were used appropriately. No language restrictions were applied.

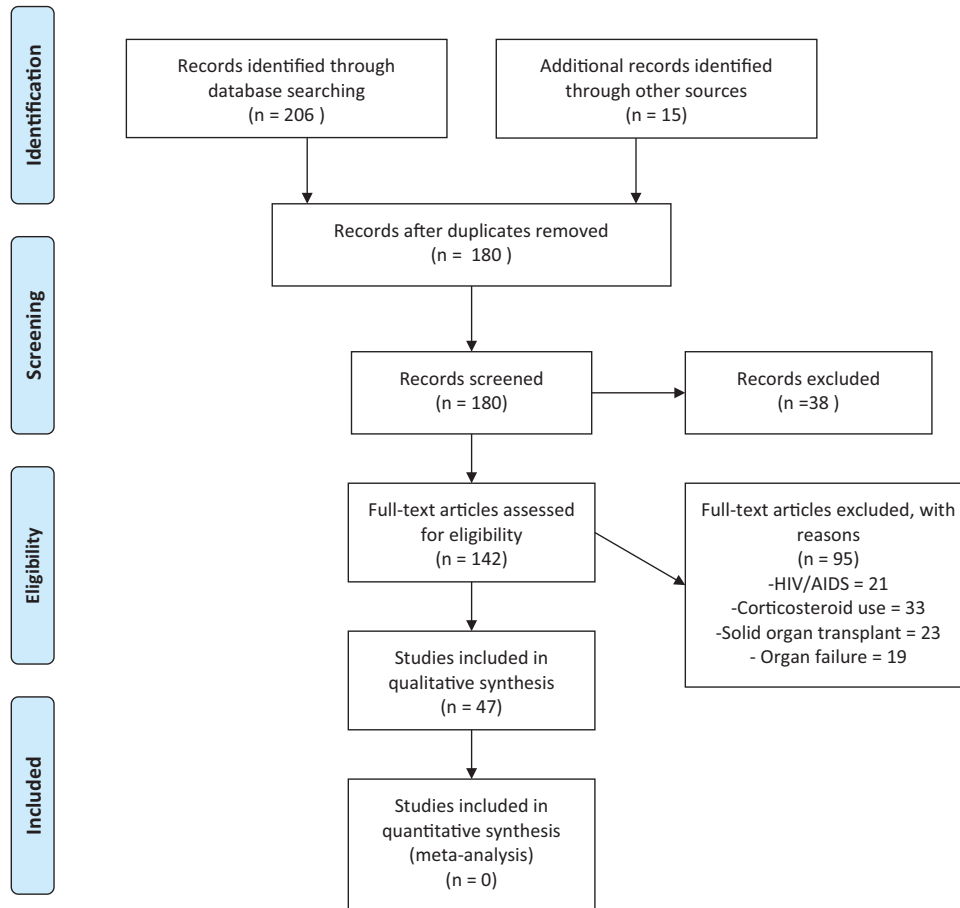
Reference lists of included articles were also searched, and additional studies were included if appropriate. We included single case reports, case series and original articles and excluded review articles and studies including DM and other known risk factors for cryptococcosis such as HIV/AIDS and solid organ transplant (Figure 1). We included studies that reported confirmed cryptococcosis in DM patients. The confirmation of cryptococcosis was based on culture and microscopy, positive Indian ink staining, histopathological examination and/or cryptococcal antigen screening (CrAg). The diagnosis of DM should have been made prior to cryptococcosis diagnosis. We collected the following data: publication data, age, gender, study type, clinical characteristics, other underlying conditions, diagnostic modalities, and disease outcomes.

Data were analyzed using Microsoft Excel 2016 and descriptive statistics (mean or median for numerical data; frequency and percentages for categorical variables) were employed. This study did not require approval by the institutional review board.

## Results

### *Epidemiology of cryptococcosis among patients with DM*

We identified 28 studies, including 47 patients from across four different continents: Asia (60.7%,  $n = 17$ ), North America (21.4%,  $n = 6$ ),



**Figure 1.** PRISMA flow diagram.

South America (10.7%,  $n=3$ ), and Africa (7.1%  $n=2$ ). Most of the studies were single case reports (85.7%,  $n=24$ ) and retrospective (14.3%,  $n=4$ ) studies. Male patients (75%,  $n=18$ ) were recorded more than female patients (25%,  $n=6$ ). The median age was 60.5 years (27–79) (Table 1).

#### *Clinical manifestations of cryptococcosis among patients with DM*

The majority of the patients had cryptococcal meningitis (68.1%,  $n=32$ ), followed by disseminated cryptococcosis (6.4%,  $n=3$ ), isolated pulmonary disease (14.9%,  $n=7$ ), and others (10.6%,  $n=5$ ) (Table 1). The most reported presenting complaints among cryptococcal meningitis were headache (57.1%,  $n=8$ ), fever (57.1%,  $n=8$ ), altered mental status (35.7%,  $n=5$ ), and nausea and vomiting (28.6%,  $n=4$ ). Isolated pulmonary cryptococcosis common symptoms included fever (42.9%,  $n=3$ ), shortness of breath (42.9%,  $n=3$ ), and cough (100%,  $n=7$ ).

Although patients with disseminated disease presented with varying symptoms, fever was the most common among the cases.

#### *Diagnosis of cryptococcosis among patients with DM*

The diagnosis of cryptococcal meningitis was made by culture and microscopy of cerebrospinal fluid (CSF) 81.3% ( $n=26$ ), India ink 21.9% ( $n=7$ ), and CSF cryptococcal antigen 12.5% ( $n=4$ ), whereas the diagnosis of isolated pulmonary disease was made by culture 42.9% ( $n=3$ ) and histopathology 71.4% ( $n=5$ ). Disseminated disease was diagnosed by culture and microscopy culture 66.7% ( $n=2$ ), and other tests listed (Table 2).

#### *Treatment outcomes of cryptococcosis among patients with DM*

Of the 47 patients, 38.3% ( $n=18$ ) patients died on therapy. Mortality in patients with meningeal

**Table 1.** Study characteristics.

Study	Year of publication	Country of origin of cases	Study type	Total number of patients	Age	Sex	Diabetes	HbA1C	CrAg status and how diagnosis was made	Manifestation	Outcome
Anto <i>et al.</i> <sup>22</sup>	2020	India (Asia)	Case report	1	64	F	yes		Blood and urine cultures were positive and nucleotide sequencing confirmed as <i>C. neoformans</i> var. <i>grubii</i>	Meningitis	Dead
Kalyango <i>et al.</i> <sup>23</sup>	2020	Uganda (Africa)	Case report	1	59	M	Yes	9.3%	Sputum culture	Pulmonary	Alive
Acharya <i>et al.</i> <sup>24</sup>	2020	USA (North America)	Case report	1	61	F	Yes	9 mmol/mol	Lumbar puncture	Meningitis	Alive
Zitun <i>et al.</i> <sup>25</sup>	2020	USA (North America)	Case report	1	66	M	Yes		Positive serum CrAg	Pleural	Alive
Wan <i>et al.</i> <sup>26</sup>	2020	China (Asia)	Retrospective (2013–2017)	15			Yes 3/15		Positive CSF CrAg, culture	Meningitis	alive
Owuor <sup>27</sup>	2019	Kenya (Africa)	Case report	1	27	F	yes		India ink on 2 CSF samples	Meningitis	Alive
Badami <i>et al.</i> <sup>28</sup>	2019	USA (North America)	Case report	1	68	M	Yes	6.0%	Positive CSF CrAg, transbronchial biopsy	Disseminated	Alive
Jha <i>et al.</i> <sup>29</sup>	2019	India (Asia)	Case report	1	56	M	Yes	6.4%	CSF gram staining, India ink and culture	Meningitis	Dead
Ikumi <i>et al.</i> <sup>30</sup>	2016	Japan (Asia)	Case report	1	72	F	Yes		Blood and CSF culture	Meningitis	Alive
De Oliveira Nunes <i>et al.</i> <sup>31</sup>	2016	Brazil (South America)	Case report	1	69	M	Yes		Blood culture and BAL culture	Pulmonary	Alive
Sung <i>et al.</i> <sup>32</sup>	2015	South Korea (Asia)	Case report	1	32	M	Yes	10.9%	Percutaneous supraclavicular lymph node core needle biopsy.	Pulmonary	Alive
Chen <i>et al.</i> <sup>33</sup>	2015	China (Asia)	Case report	1	71	M	Yes		blood culture	Disseminated	Alive
Ho <i>et al.</i> <sup>34</sup>	2015	China (Asia)	Case report	1	73	M	Yes		Operative debridement	Cutaneous	Alive
Koike <i>et al.</i> <sup>35</sup>	2014	Japan (Asia)	Case report	1	79	M	Yes		CSF culture	Meningitis	Alive
Messina <i>et al.</i> <sup>16</sup>	2014	Argentina (South America)	Retrospective (2008–2011)	182			Yes 14/182		CSF culture	Meningitis	12/14 dead
Poojary <i>et al.</i> <sup>18</sup>	2014	India (Asia)	Case report	1	48	M	Yes		Culture of tissue on Sabouraud dextrose agar	Disseminated	Alive

(continued)

Table 1. (continued)

Study	Year of publication	Country of origin of cases	Study type	Total number of patients	Age	Sex	Diabetes	HbA1C	CrAg status and how diagnosis was made	Manifestation	Outcome
Sugita <i>et al.</i> <sup>36</sup>	2014	Japan (Asia)	Case report	1	71	M	Yes		Fibre optic bronchoscopy, and biopsy	Pulmonary	Alive
Raheja <i>et al.</i> <sup>37</sup>	2012	USA (North America)	Case report	1	54	M	yes		Positive CSF CrAg	Meningitis	Alive
Shoji <i>et al.</i> <sup>38</sup>	2012	Japan (Asia)	Case report	1	68	M	Yes		India ink staining of CSF	Meningitis	Alive
Araujo <i>et al.</i> <sup>39</sup>	2012	Brazil (South America)	Case report	1	51	M	Yes		Positive serum CrAg, incision, biopsy and culture of biopsy	Peritonitis	Alive
Kurahara <i>et al.</i> <sup>40</sup>	2011	Japan (Asia)	Case report	1	57	M	yes		Positive CrAg, transbronchial lung biopsy	Pulmonary	Alive
Juhi <i>et al.</i> <sup>41</sup>	2009	India (Asia)	Retrospective (2004–2007)	7			Yes 2/7		CSF India ink, gram stain, culture	Meningitis	½ dead
Huang <i>et al.</i> <sup>42</sup>	2005	China (Asia)	Case report	1	69	M	Yes		Transthoracic needle biopsy	Pulmonary	Alive
Tanigawa <i>et al.</i> <sup>43</sup>	2004	Japan (Asia)	Case report	1	65	M	yes		Transbronchial Lung biopsy	Pulmonary	Alive
Prasad <i>et al.</i> <sup>44</sup>	2003	India (Asia)	Retrospective (1996–2001)	45			Yes 4/45		CSF culture	Meningitis	¼ dead
Karpinsky <i>et al.</i> <sup>45</sup>	1998	USA (North America)	Case report	1	60	M	Yes		Lumbar puncture	Meningitis	Dead
Vaidya <i>et al.</i> <sup>46</sup>	1991	USA (North America)	Case report	1	54	F	Yes		Fine-needle aspirate and culture; blood culture	Thyroidal	Dead
Liu <i>et al.</i> <sup>47</sup>	1991	Taiwan (Asia)	Case report	1	62	F	Yes		Positive serum CrAg, biopsy	Adrenal	Alive

BAL, bronchoalveolar lavage; CrAg, cryptococcal antigen; CSF, cerebrospinal fluid; F, female; M, male; SDA, Sabouraud dextrose agar.

**Table 2.** Diagnostic yield stratified by sample type and clinical syndrome of cryptococcosis in patients with diabetes mellitus.

Diagnostic test	All cases N=47	Disseminated N=3	Pulmonary N=7	CNS N=32	Cutaneous N=1	Peritoneal N=1	Pleural N=1	Thyroid N=1	Adrenal N=1
Culture (any site)	38 (80.9)	2 (66.7)	4 (57.1)	29 (90.6)	1 (100)	1 (100)		1 (100)	
Blood culture	5 (10.6)	1 (33.3)	1 (14.3)	2 (6.3)				1 (100)	
CSF culture	26 (55.3)			26 (81.3)					
BAL culture	1 (2.1)		1 (14.3)						
Sputum culture	1 (2.1)		1 (14.3)						
Urine culture	1 (2.1)			1 (3.1)					
Skin and soft tissue culture	4 (8.5)	1 (33.3)	1 (14.3)		1 (100)	1 (100)			
CrAg (all)	9 (19.1)	1 (33.3)	1 (14.3)	4 (12.5)		1 (100)	1 (100)		1 (100)
Serum CrAg	4 (8.5)		1 (14.3)			1 (100)	1 (100)		1 (100)
CSF CrAg	5 (10.6)	1 (33.3)		4 (12.5)		1 (100)			
Histopathology	9 (19.1)	1 (33.3)	5 (71.4)	7 (21.9)				1 (100)	1 (100)

BAL, bronchoalveolar lavage; CrAg, cryptococcal antigen; CSF, cerebrospinal fluid.

disease was 36.2% ( $n=17$ ) and thyroid disease 0.21% ( $n=1$ ), whereas patients with pulmonary disease and disseminated disease reported recoveries (Table 1).

### Discussion

There is an emerging body of evidence, mainly from observational studies and case reports, to support DM as an important risk factor for cryptococcosis.<sup>39,48–50</sup> In the present study, we sought to describe the clinical characteristics and outcomes of cryptococcosis in people living with DM. We found that the median age was 60.5 years, which is consistent with previous studies that showed a prevalence of cryptococcosis and DM in the older population.<sup>51</sup>

According to a population-based study in Taiwan reported by Lin and colleagues, 30.6% of 4587 people who were found to have cryptococcosis had DM as the underlying condition.<sup>20</sup> In that study, it was argued that the higher prevalence of cryptococcosis in DM was attributed to the higher age of DM patients. However, after accounting for the effect of age through case–control matching, a relationship between DM and cryptococcosis was demonstrated.<sup>20</sup>

Our data showed a male predominance, which was similar to previous studies.<sup>52,53</sup> A proposed explanation for the male gender predominance could be a difference in the host's immune response between men and women. The immune modulating effect of testosterone makes men more susceptible to IRIS.<sup>54</sup> Furthermore, we found that cryptococcal meningitis was the most frequent form of cryptococcal disease in patients with DM. This is in line with a multicenter study performed in the USA with cryptococcosis in people living with HIV.<sup>55</sup> However, Baddley and colleagues found that in a study of 166 HIV-negative individuals, pulmonary cryptococcosis was the most prevalent form of cryptococcal disease, which is in contrast with our findings.<sup>56</sup>

The clinical manifestations of cryptococcal infection vary depending on the patient's immune status and site of infection, from asymptomatic to having cough, fever, pneumonia, meningoencephalopathy, spread to multiple body sites, severe life-threatening disease, or even death. However, due to the predilection of *C. neoformans* for the CNS, the most common clinical presentation of cryptococcosis is meningoencephalitis whose signs include meningismus, papilledema, cranial nerve palsies, focal neurological deficits,

and depressed level of consciousness.<sup>2</sup> The severity of cryptococcosis depends on the characteristic virulence factors of the *Cryptococcus* and host immune system responses. A predominant T helper (Th) immune response is associated with protection from cryptococcosis whereas Th-2 responses are associated with susceptibility to cryptococcal infection.<sup>7,57</sup> According to this study, common clinical manifestations of cryptococcal disease included: headache, fever, shortness of breath, altered mental status, nausea and vomiting in the respective sites of infection.

Furthermore, this study indicated an overall mortality of 21.3%, with the death rate in meningeal disease as high as 43.8%. No mortalities were reported among patients with disseminated or pulmonary disease. Cases have been reported of pulmonary cryptococcosis resolving without treatment in immunocompetent individuals.<sup>13</sup> Lin *et al.* was able to demonstrate a higher 1-year and overall mortality among HIV-uninfected individuals with DM than those without DM in cryptococcosis and cryptococcal meningitis.<sup>20</sup>

A study in the USA identified DM as a major risk factor for cryptococcal disease in solid organ transplant and immunocompetent patients.<sup>58</sup> Other predisposing conditions related to cryptococcosis include: recipients of immunosuppressive treatment, this was the most common in this study, HIV/AIDS, chronic renal failure, malignancy, and Cushing's syndrome.<sup>59</sup> Cell mediated immunity is the most important host response to cryptococcal disease, hence the high incidence of disease among immunosuppressed individuals. DM leads to decreased cell mediated immunity through neutrophilic chemotaxis impairment, abnormal phagocytosis, poor lymphocyte blast transformation, and defective opsonization. Hyperglycemia also influences the microbicidal function of macrophages. This allows for opportunistic infections and is hypothesized to be the relationship between cryptococcal infection and DM.<sup>60-62</sup>

Culture of appropriate respiratory samples is the gold standard for the diagnosis of cryptococcal infection hence it comes as no surprise that it was the most commonly favored diagnostic modality in this study. The use of CrAg detection for confirming the diagnosis was also widely favored because it is more convenient for all hospital settings and takes a shorter duration of time.<sup>63</sup> In a large validation study in Africa by Boulware

*et al.*,<sup>64</sup> CrAg lateral flow assay (LFA) reported a high sensitivity (99.3%) and a high specificity (99.1%) in HIV-positive individuals and a median sensitivity and specificity of 100% [95% confidence interval (CI) 95.6–100%] and 99.5% (95% CI 95.7–100%) whereas culture, although specific, has a low sensitivity (50–80%).<sup>65</sup>

The limitations of our study were an inability to have a complete picture on diabetic control and cryptococcal infection because hemoglobin A<sub>1</sub>C was not recorded for the majority of articles and there were few data on *Cryptococcus* species typing. Further studies should be done to confirm the relationship between cryptococcosis and other comorbidities and also to document the commonest species of *Cryptococcus* encountered in DM. Studies concerning diabetic control in cryptococcal infection would be insightful.

### Conclusion

There is significant evidence to support the relationship between cryptococcosis and DM. Therefore, health workers should have a higher index of suspicion when presented with elderly patients with DM complaining of headache, fever and shortness of breath. Diagnosis should be ascertained by culture and microscopy, cryptococcal antigen testing or histopathology. Healthcare providers should also give thought to the effect of hyperglycemia in the management of cryptococcal infection and DM. Additional studies on hyperglycemic control with cryptococcosis are recommended.

### Author contributions

Felix Bongomin conceptualized the study. Lauryn Nsenga, Jonathan Kajjimu, Ronald Olum, Sandra Ninsiima, Andrew Peter Kyazze, Phillip Ssekamate, Davis Kibirige, Joseph Baruch Baluku, Irene Andia-Biraro and Felix Bongomin contributed to the drafting of the manuscript. All authors reviewed and approved the final manuscript prior to submission.

### Conflict of interest statement

The authors declare that there is no conflict of interest.

### Funding

The authors received no financial support for the research, authorship, and/or publication of this article.

**Ethical statement**

Our study did not require ethical board approval because of its design of a literature review of published data. Our study did not require consent because no individual patient data were included.

**ORCID iD**

Felix Bongomin  <https://orcid.org/0000-0003-4515-8517>

**References**

1. Kwon-Chung KJ, Fraser JA, Doering TL, *et al.* *Cryptococcus neoformans* and *Cryptococcus gattii*, the etiologic agents of cryptococcosis. *Cold Spring Harb Perspect Med* 2014; 4: a019760.
2. Li SS and Mody CH. Cryptococcus. *Proc Am Thorac Soc* 2010; 7: 186–196.
3. Emmons CW. Saprophytic sources of *Cryptococcus neoformans* associated with the pigeon (*Columba livia*). *Am J Hyg* 1955; 62: 227–232.
4. Evans EE. The antigenic composition of *Cryptococcus neoformans*: I. A serologic classification by means of the capsular and agglutination reactions. *J Immunol* 1950; 64: 423–430.
5. Meyer W, Gilgado F, Ngamskulrunroj P, *et al.* Molecular typing of the *Cryptococcus neoformans/Cryptococcus gattii* species complex. In: Heitman J, Kozel TR, Kwon-Chung KJ, *et al.* (eds) *Cryptococcus: from human pathogen to model yeast*. Wiley Online Books, 2011, pp. 327–357.
6. Franco-Paredes C, Womack T, Bohlmeyer T, *et al.* Management of *Cryptococcus gattii* meningoencephalitis. *Lancet Infect Dis* 2015; 15: 348–355.
7. Pereira ABM and Rogerio AP. Chronic obstructive pulmonary disease (COPD) and asthma–chronic obstructive pulmonary disease overlap syndrome (ACOS) are risk factors for cryptococcosis. *Open Allergy J* 2020; 11: 1–4.
8. O’Halloran JA, Powderly WG and Spec A. Cryptococcosis today: it is not all about HIV infection. *Curr Clin Microbiol Rep* 2017; 4: 88–95.
9. Marr KA, Sun Y, Spec A, *et al.* A multicenter, longitudinal cohort study of cryptococcosis in human immunodeficiency virus-negative people in the United States. *Clin Infect Dis* 2020; 70: 252–261.
10. Wu H-H, Chen Y-X and Fang S-Y. Clinicopathological features of isolated pulmonary cryptococcosis in HIV-negative patients. *J Int Med Res* 2020; 48: 0300060520927877.
11. Singh N, Husain S, De Vera M, *et al.* *Cryptococcus neoformans* infection in patients with cirrhosis, including liver transplant candidates. *Medicine* 2004; 83: 188–192.
12. Nakamura S, Izumikawa K, Seki M, *et al.* Pulmonary cryptococcosis in late pregnancy and review of published literature. *Mycopathologia* 2008; 167: 125.
13. Kohno S, Kakeya H, Izumikawa K, *et al.* Clinical features of pulmonary cryptococcosis in non-HIV patients in Japan. *J Infect Chemother* 2015; 21: 23–30.
14. Tsai WC, Lien CY, Lee JJ, *et al.* The clinical characteristics and therapeutic outcomes of cryptococcal meningitis in elderly patients: a hospital-based study. *BMC Geriatr* 2019; 19: 1–6.
15. Kiertiburanakul S, Wirojtananugoon S, Prachartam R, *et al.* Cryptococcosis in human immunodeficiency virus-negative patients. *Int J Infect Dis* 2006; 10: 72–78.
16. Messina FA, Negroni R, Maiolo EI, *et al.* Criptococcosis meníngea en pacientes con diabetes y sida. *Enferm Infecc Microbiol Clin* 2014; 32: 643–646.
17. Lao M, Li C, Li J, *et al.* Opportunistic invasive fungal disease in patients with type 2 diabetes mellitus from Southern China: clinical features and associated factors. *J Diabetes Investig* 2020; 11: 731–744.
18. Poojary S and Khatu SP. Disseminated cryptococcosis in a diabetic patient. *Cutis* 2014; 94: 91–95.
19. Li Y, Fang W, Jiang W, *et al.* Cryptococcosis in patients with diabetes mellitus II in mainland China: 1993–2015. *Mycoses* 2017; 60: 706–713.
20. Lin KH, Chen CM, Chen TL, *et al.* Diabetes mellitus is associated with acquisition and increased mortality in HIV-uninfected patients with cryptococcosis: a population-based study. *J Infect* 2016; 72: 608–614.
21. Perfect JR, Dismukes WE, Dromer F, *et al.* Clinical practice guidelines for the management of cryptococcal disease: 2010 update by the infectious diseases society of America. *Clin Infect Dis* 2010; 10: 161–166.
22. Anto PV, Reddy NM, Krishnan V, *et al.* Abstracts from the International Science



- Symposium on HIV and Infectious Diseases (ISSHID 2019): infectious diseases: Chennai, India. 12–14 October 2019. *BMC Infect Dis* 2020; 20: 324.
23. Kalyango N, Kwizera R, Baluku JB, *et al.* Intracavitary pulmonary cryptococcoma in poorly controlled diabetes mellitus. *Med Mycol Case Rep* 2020; 28: 1–3.
  24. Acharya R, Khanal K, Upadhyaya P, *et al.* Diabetes mellitus as a risk factor for cryptococcal meningitis in immunocompetent. *IDCases* 2020; 22: e00988.
  25. Zitun M, Elmassy M, El Nawaa SE, *et al.* A rare case of cryptococcal empyema in an immunocompetent patient. *Chest* 2020; 158: A1257.
  26. Wan Y, Li X, Wang Y, *et al.* Clinical characteristic of 15 cases of cryptococcal meningitis treated with Ommaya reservoir. *Acta Neurol Belg* 2019; 1–7.
  27. Owuor OH and Chege P. Cryptococcal meningitis in a HIV negative newly diagnosed diabetic patient: a case report. *BMC Infect Dis* 2019; 19: 5.
  28. Badami V and Zulfikar R. Cryptococcosis in an immunocompetent well-controlled diabetic. D48 critical care case reports: infection and sepsis II. *Am Thorac Soc* 2019; 201: A6605.
  29. Jha MK, Mohanty A and Gupta P. *Cryptococcus gattii* meningitis in a diabetic adult in South India. *J Family Med Prim Care* 2019; 8: 1253–1256.
  30. Ikuma K, Yokoi K and Ando T. Cryptococcal meningoencephalitis presenting with treatable cognitive impairment and involuntary movement. *Clin Neurol* 2016; 56: 27–31.
  31. de Oliveira Nunes J, Pillon KRAP, Bizerra PL, *et al.* Erratum to: The simultaneous occurrence of histoplasmosis and cryptococcal fungemia: a case report and review of the literature. *Mycopathologia* 2016, 181: 899.
  32. Sung JH, Do Hoon Kim MJ, Lee KJ, *et al.* A case of pulmonary cryptococcosis in an immunocompetent male patient diagnosed by a percutaneous supraclavicular lymph node biopsy. *Tuberc Respir Dis* 2015; 78: 276–280.
  33. Chen CM and Yu WL. Complicated cryptococcal meningitis, spinal myelitis and probably tracheobronchitis: a rare case report. *J Microbiol Immunol Infect* 2015; 48: S167.
  34. Ho SW, Ang CL, Ding CS, *et al.* Necrotizing fasciitis caused by *Cryptococcus gattii*. *Am J Orthop* 2015; 44: E517–E522.
  35. Koike Y, Ishihara T, Ozawa T, *et al.* Cryptococcal meningitis successfully treated with voriconazole and low-dose amphotericin B. *Neurol Clin Neurosci* 2014; 2: 166–168.
  36. Sugita C, Tanaka S and Takahashi T. Endobronchial cryptococcosis in a non-HIV immunocompromised patient. *J Exp Clin Med* 2014; 6: 105–106.
  37. Raheja H, Sinha A, Irukulla PK, *et al.* Cryptococcal meningitis masquerading as normal pressure hydrocephalus in an immune-competent adult. *J Glob Infect Dis* 2017; 9: 157–159.
  38. Shoji H, Takuma T, Ohbayashi H, *et al.* Measurement of antifungal drug levels in cerebrospinal fluid for cryptococcal meningoencephalitis. *J Infect Chemother* 2012; 18: 775–779.
  39. Araújo BS, Bay M, Reichert R, *et al.* Intra-abdominal cryptococcosis by *Cryptococcus gattii*: case report and review. *Mycopathologia* 2012; 174: 81–85.
  40. Kurahara Y, Tachibana K, Katsura H, *et al.* A case of cryptococcal empyema successfully treated by debridement by medical thoracoscopy with local anesthesia. *Nihon Kokyuki Gakkai Zasshi* 2011; 49: 142–147.
  41. Juhi T, BibhaBati M, Aradhana B, *et al.* Cryptococcal meningitis in a tertiary care hospital. *Nihon Ishinkin Gakkai Zasshi* 2009; 50: 95–99.
  42. Huang CJ, Yang MC and Ueng SH. Large cryptococcoma mimicking lung cancer in an HIV-negative, type 2 diabetic patient. *J Thorac Imaging* 2005; 20: 115–117.
  43. Tanigawa M, Kimura M, Ichioka M, *et al.* A case of secondary pulmonary cryptococcosis complicating diabetes mellitus. *Nihon Kokyuki Gakkai Zasshi* 2004; 42: 272–276.
  44. Prasad KN, Agarwal J, Nag VL, *et al.* Cryptococcal infection in patients with clinically diagnosed meningitis in a tertiary care center. *Neurol India* 2003; 51: 364–366.
  45. Karpinsky NC and Powell H. Case of the month: July 1997 – Diabetic male with transient ischemic attacks. *Brain Pathol* 1998; 8: 235–236.
  46. Vaidya KP and Lomvardias S. Cryptococcal thyroiditis: report of a case diagnosed by fine-needle aspiration cytology. *Diagn Cytopathol* 1991; 7: 415–416.
  47. Liu YC, Cheng DL, Liu CY, *et al.* Isolated cryptococcosis of the adrenal gland. *J Intern Med* 1991; 230: 285–287.

48. Sah R, Jaiswal A, Singla S, *et al.* Pulmonary cryptococcosis: report of the first confirmed autochthonous case in Nepal. *Acta Trop* 2019; 105:205.
49. Indira P, Kumar PM, Shalini S, *et al.* Opportunistic infections among people living with HIV (PLHIV) with diabetes mellitus (DM) attending a tertiary care hospital in coastal city of South India. *PLoS One* 2015; 10: e0136280.
50. Chuang YM, Ho YC, Chang HT, *et al.* Disseminated cryptococcosis in HIV-uninfected patients. *Eur J Clin Microbiol Infect Dis* 2008; 27: 307–310.
51. Lee YC, Wang JT, Sun HY, *et al.* Comparisons of clinical features and mortality of cryptococcal meningitis between patients with and without human immunodeficiency virus infection. *J Microbiol Immunol Infect* 2011; 44: 338–345.
52. Tsai WC, Lien CY, Lee JJ, *et al.* The prognostic factors of HIV-negative adult cryptococcal meningitis with a focus on cranial MRI-based neuroimaging findings. *J Clin Neurosci* 2018; 55: 57–61.
53. Pappas PG, Perfect JR, Cloud GA, *et al.* Cryptococcosis in human immunodeficiency virus-negative patients in the era of effective azole therapy. *Clin Infect Dis* 2001; 33: 690–699.
54. Casadevall A and Perfect J. *Cryptococcus neoformans*. Washington, DC: American Society for Microbiology Press, 1998, pp. 351–369.
55. Pappas PG. Cryptococcal infections in non-HIV-infected patients. *Trans Am Clin Climatol Assoc* 2013; 124: 61–79.
56. Baddley JW, Perfect JR, Oster RA, *et al.* Pulmonary cryptococcosis in patients without HIV infection: factors associated with disseminated disease. *Eur J Clin Microbiol Infect Dis* 2008; 27: 937–943.
57. Wormley FL and Perfect JR. Immunology of infection caused by *Cryptococcus neoformans*. *Methods Mol Med* 2005; 118: 193–198.
58. George IA, Spec A, Powderly WG, *et al.* Comparative epidemiology and outcomes of human immunodeficiency virus (HIV), non-HIV non-transplant, and solid organ transplant associated cryptococcosis: a population-based study. *Clin Infect Dis* 2018; 66: 608–611.
59. Shih CC, Chen YC, Chang SC, *et al.* Cryptococcal meningitis in non-HIV-infected patients. *QJM* 2000; 93: 245–251.
60. May RC, Stone NR, Wiesner DL, *et al.* Cryptococcus: from environmental saprophyte to global pathogen. *Nat Rev Microbiol* 2016; 14: 106–117.
61. Huffnagle GB, Lipscomb MF, Lovchik JA, *et al.* The role of CD4+ and CD8+ T cells in the protective inflammatory response to a pulmonary cryptococcal infection. *J Leukoc Biol* 1994; 55: 35–42.
62. Kakeya H, Izumikawa K, Yamada K, *et al.* Concurrent subcutaneous candidal abscesses and pulmonary cryptococcosis in a patient with diabetes mellitus and a history of corticosteroid therapy. *Intern Med* 2014; 53: 1385–1390.
63. Meya D, Manabe Y, Castelnuovo B, *et al.* Cost-effectiveness of serum cryptococcal antigen screening to prevent deaths among HIV-infected persons with a CD4+ cell count  $\leq$ 100 cells/ $\mu$ l who start HIV therapy in resource-limited settings. *Clin Infect Dis* 2010; 51 :448–55.
64. Boulware DR, Rolfes MA, Rajasingham R, *et al.* Multisite validation of cryptococcal antigen lateral flow assay and quantification by laser thermal contrast. *Emerg Infect Dis* 2014; 20: 45–53.
65. Snow RM and Dismukes WE. Cryptococcal meningitis diagnostic value of cryptococcal antigen in cerebrospinal fluid. *Arch Intern Med* 1975; 135: 1155–1157.