

## Tissue response resulting from different force magnitudes combined with corticotomy in rats

Kriangkrai Kraiwattanapong<sup>a</sup>; Bancha Samruajbenjakun<sup>b</sup>

### ABSTRACT

**Objectives:** To evaluate the amount of hyalinization and root resorption after application of light and heavy forces during corticotomy-assisted tooth movement.

**Materials and Methods:** Forty-eight male Wistar rats were used. Eight animals were the control group (day 0). The other 40 animals were randomly divided into two groups using the split-mouth technique: (1) corticotomy combined light force (CLF) and (2) corticotomy combined heavy force (CHF). Nickel-titanium closed coil springs that generated 10 g (light force) and 50 g (heavy force) were used for maxillary first molar movement. three-dimensional root volume was evaluated at 0, 14, and 28 days. Percent hyalinization was analyzed at 0, 3, 7, 14, 21, and 28 days by histomorphometric analysis.

**Results:** The CHF group showed significantly lower cervical root volume than the CLF group at 28 days. Compared with day 0, the CHF group showed significantly less root volume in both distobuccal and distopalatal roots at 28 days. The hyalinization percentages in the CHF group were significantly higher than the CLF group at days 3 and 21.

**Conclusions:** Heavy force combined with corticotomy produced more periodontal ligament hyalinization and root resorption than the light force combined with corticotomy. (*Angle Orthod.* 2019;89:797–803.)

**KEY WORDS:** Corticotomy; Heavy force; Root resorption; Hyalinization

### INTRODUCTION

Since prolonged duration of orthodontic treatment has been associated with an increased risk of dental caries, periodontal problems, and root resorption,<sup>1</sup> numerous efforts have been made to reduce orthodontic treatment time to avoid unwanted side effects. Among the interventions, corticotomy is known to be an effective and often used clinical method to create rapid tooth movement.<sup>2</sup> This technique intentionally injures the cortical bone area of teeth with minimal damage to the cancellous bone. Consequently, bone anabolic and catabolic activities are accelerated to

restore the injured tissues leading to a temporary osteopenia state, which reduces alveolar bone density around the surgical site.<sup>3</sup> This phenomenon is termed the regional acceleratory phenomenon (RAP).<sup>4</sup> Previous studies showed that corticotomy accelerated tooth movement by rapidly eliminating hyalinization without an increased amount of root resorption.<sup>5</sup>

Force is one of many factors that create an adequate biological response for tooth movement. The effects of different force magnitudes on surrounding structures have been reported and showed that light forces produce less or no hyalinization and are assumed to be safe for the roots of teeth. In contrast, heavy forces cause an obstruction of blood flow followed by PDL necrosis and have been implicated in root resorption.<sup>6,7</sup>

Although the results of corticotomy on tooth movement and alveolar bone response have been investigated, the effects on the periodontal ligament (PDL) tissue and root during the application of different force magnitudes following corticotomy have not been thoroughly examined. A previous study<sup>8</sup> found a similar percent of root resorption between light and heavy force applications with corticotomy; however, they used two-dimensional histomorphometric evaluation

<sup>a</sup> Private Practice, Hat Yai, Songkhla, Thailand.

<sup>b</sup> Assistant Professor, Orthodontic Section, Department of Preventive Dentistry, Faculty of Dentistry, Prince of Songkla University, Hat Yai, Songkhla, Thailand.

Corresponding author: Bancha Samruajbenjakun, DDS, MSc, DScD, Department of Preventive Dentistry, Faculty of Dentistry, Prince of Songkla University, Hat Yai, Songkhla 90112, Thailand (e-mail: samruaj@hotmail.com)

Accepted: January 2019. Submitted: September 2018.

Published Online: March 21, 2019

© 2019 by The EH Angle Education and Research Foundation, Inc.

that might not provide the maximum accuracy of resorption area. Thus, this study aimed to compare the quantity of PDL hyalinization and three-dimensional root volume change after application of light and heavy forces during corticotomy assisted tooth movement.

## MATERIALS AND METHODS

This study was approved by The Animal Ethics Committee of the Prince of Songkla University (MOE 0521.11/602). Forty-eight male, 12-week-old Wistar rats (body weight: 250–300 g) from National Laboratory Animal Center, Prince of Songkla University, were selected for the experiment. The animals were acclimatized for 7 days. Eight animals were randomly chosen as the control group at day 0 (no intervention). The maxillary right and left sides of 40 animals were randomly divided using a split-mouth technique into two groups: (1) corticotomy combined with light force (CLF) and (2) corticotomy combined with heavy force (CHF). The amount of hyalinization was evaluated at 0, 3, 7, 14, 21, and 28 days. Root volume was analyzed at 0, 14, and 28 days (Figure 1).

### Clinical Procedure

The experimental procedures were done following a previous study.<sup>8</sup> The 48 rats were anesthetized by intraperitoneal injection using ketamine (90 mg/kg) and xylazine (10 mg/kg). The corticotomy procedure was begun by incision at the gingival sulcus of the maxillary first molar. Full-thickness flaps on both the buccal and palatal sides were carefully elevated. A slow-speed handpiece and a 0.5-mm round bur under sterile water irrigation were used for alveolar decortication with two dots on both the buccal and palatal sides. Each decortication was about 0.5 mm in diameter and 0.25 mm deep. Synthetic absorbable sterile material was used for flap suturing.

Nickel-titanium closed-coil springs generated 10 g force in the CLF group and 50 g force in the CHF group and were used for movement of the maxillary first molar. The forces were measured by a tension gauge. To prevent dislodging of the ligature wire in the incisor area, a shallow retention groove of 0.5 mm from the gingival margin on the distal surface of the incisor was prepared. Then, flowable light-cured composite resin was placed to cover the wires and the tooth (Figure 2).

### 3D Image Construction and Root Volume Measurement

After tooth movement, the animals were sacrificed at 3, 7, 14, 21, and 28 days by injection of thiopental. Afterward, the maxilla was removed within 10 minutes after euthanasia and placed in 10% formalin for at least

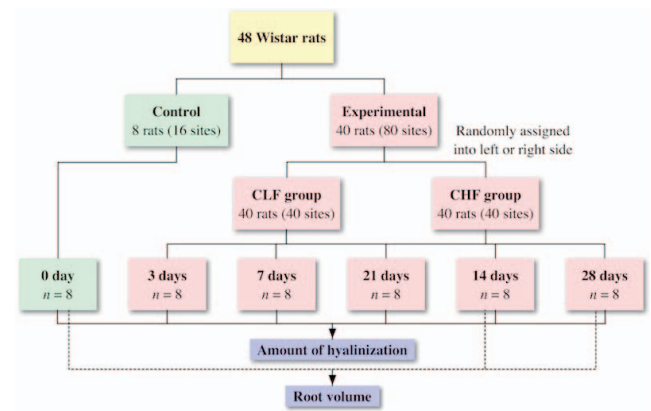


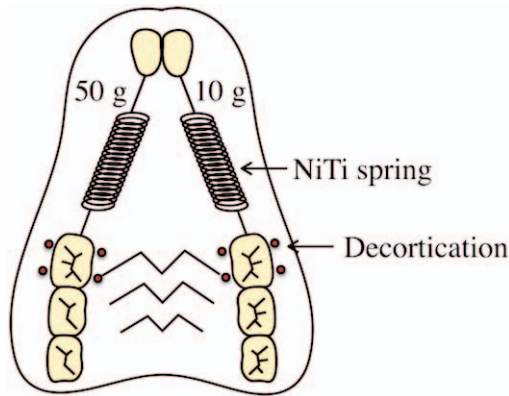
Figure 1. Schematic of study design and timeline.

7 days. Then, image layers of the maxilla were assembled using micro-computed tomography (CT) (Scanco  $\mu$ CT 35, Scanco Medical, Brüttisellen, Switzerland) with a 10  $\mu$ m voxel size. The maxilla was scanned parallel to the occlusal plane of the maxillary first molar. All maxillary first molar roots were contoured in serial horizontal sections (Figure 3) beginning from the point that all roots completely separated to the apex of each root. The contour components were exported as three-dimensional objects in stereolithography file format. Volumetric analysis of the distobuccal and distopalatal roots were selected and done by Blender software (Blender Foundation, Amsterdam, The Netherlands). Each root was divided into a cervical half and apical half to calculate the volume (Figure 4A, B). The root volumes were compared between the CLF and CHF groups at 14 and 28 days.

### Hyalinization Evaluation

After micro-CT scanning, demineralization was done with 10% ethylenediaminetetraacetic acid at room temperature in all maxillae for 4 weeks. Following decalcification, the samples were prepared into serial 3- $\mu$ m horizontal sections with 100- $\mu$ m intervals. The sections were stained with hematoxylin and eosin for hyalinized tissue examination.

Periodontal tissues of the distobuccal and distopalatal roots of the maxillary first molar were assessed with a bright field microscope for five serial sections beginning from the section beneath the bifurcation level. For hyalinization evaluation, the distobuccal and distopalatal roots were divided into a compression and a tension side using the buccopalatal axis of the root. PDL hyalinization was evaluated on the compression side of the root. The definition of PDL hyalinization was the localized homogeneous cell-free area due to PDL cell degeneration. The hyalinization area was divided by the PDL area on the compression side and then a percentage was calculated (Figure 5). The measure-



**Figure 2.** Split-mouth experimental tooth movement.

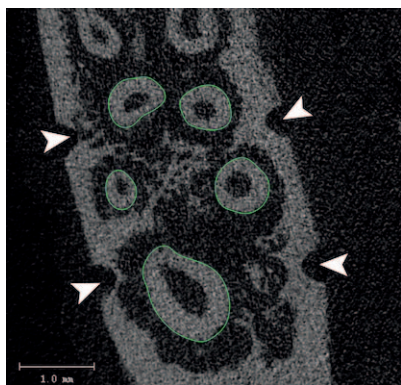
ments were evaluated on a picture transmitted from the microscope using NIS-Elements D software version 4.20 (Nikon Instruments, Inc., Melville, New York). The percentages from five sections were averaged for each sample and compared between the CLF and CHF groups at all observation periods.

**Statistical Analysis**

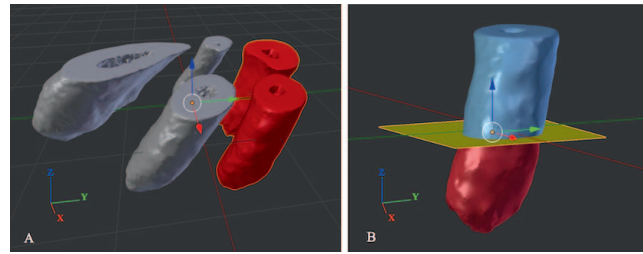
Four random samples from both groups in every period were remeasured after a 2-week interval for intrarater reliability assessment. SPSS version 17 (SPSS, Chicago, Illinois) was used for the data analysis. The Shapiro-Wilk test showed that the data were not normally distributed. The Wilcoxon signed-rank test was used to compare the data between the CLF and CHF groups. Kruskal-Wallis and Dunn-Bonferroni post-hoc tests were used to compare the differences between the time points in each group. A *P* value less than 0.05 was considered to be statistically significant.

**RESULTS**

The intraclass correlations that were used for the intrarater reliability evaluation were 0.96 for root



**Figure 3.** Maxillary first molar roots depicted in a micro-CT scan. Arrowheads indicate the alveolar decortication.

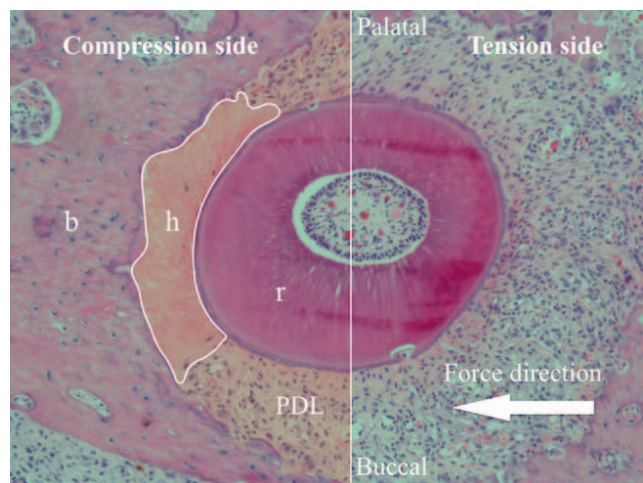


**Figure 4.** Volumetric analysis. (A) The 3D-image of the maxillary first molar roots shows the XYZ-axis. X-axis: buccolingual direction; Y-axis: mesiodistal direction; Z-axis: occluso-apical direction. (B) The distopalatal root was separately analyzed in the cervical and apical portions. The XY-axis was used as the reference plane at the midpoint of the root length in the Z-axis.

volumetric analysis and 0.78 for histomorphometric analysis. Thus, the measurement techniques were considered to have acceptable reliability.

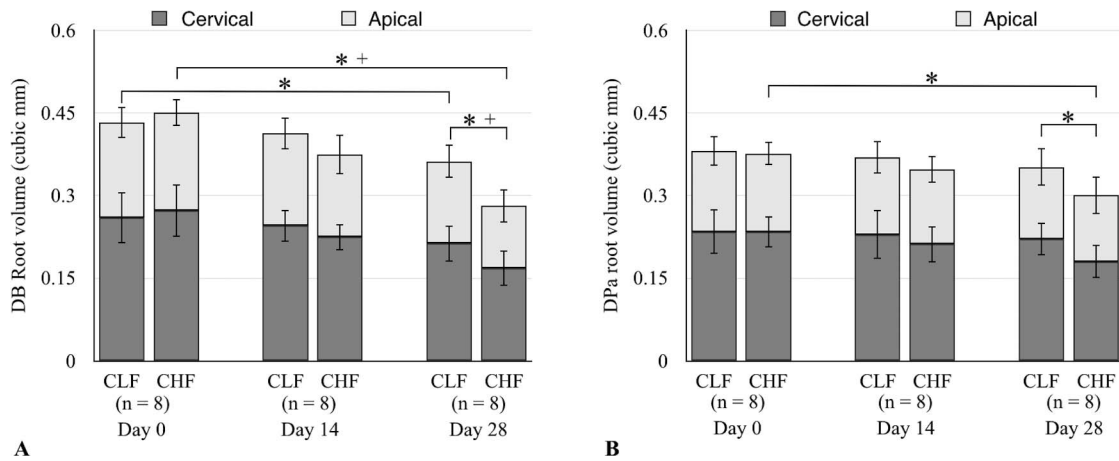
**Root Volume**

The cervical and apical root volumes of the distobuccal root in the CHF group were significantly lower than in the CLF group at 28 days (cervical:  $0.17 \pm 0.03 \text{ mm}^3$  vs  $0.21 \pm 0.02 \text{ mm}^3$ ; apical:  $0.11 \pm 0.03 \text{ mm}^3$  vs  $0.15 \pm 0.04 \text{ mm}^3$ ) (Figure 6A). The distopalatal root exhibited significantly lower cervical root volume in the CHF group than in the CLF group at 28 days ( $0.18 \pm 0.03 \text{ mm}^3$  vs  $0.22 \pm 0.03 \text{ mm}^3$ ) (Figure 6B). The intragroup comparison showed significantly decreasing distobuccal and distopalatal root volumes between 0 and 28 days in the cervical half of the distobuccal root in the CLF group ( $0.26 \pm 0.05 \text{ mm}^3$  vs  $0.21 \pm 0.02 \text{ mm}^3$ ), cervical and apical half of the distobuccal root in the CHF group (cervical:  $0.27 \pm 0.05 \text{ mm}^3$  vs  $0.17 \pm 0.03 \text{ mm}^3$ ; apical:  $0.18 \pm 0.03 \text{ mm}^3$  vs  $0.11 \pm 0.03$



**Figure 5.** Evaluation of the hyalinized area by histomorphometric analysis. r indicates root; b, alveolar bone; h, hyalinized area; and PDL, periodontal ligament tissue.





**Figure 6.** Comparison of root volume between the CLF and the CHF groups: (A) distobuccal root, (B) distopalatal root. \*, + indicates  $P < .05$  between the cervical half and the apical half, respectively.

mm<sup>3</sup>), and the cervical half of the distopalatal root in the CHF group ( $0.23 \pm 0.03$  mm<sup>3</sup> vs  $0.18 \pm 0.03$  mm<sup>3</sup>) (Figures 6A, B, and 7A–L).

The CLF group had significantly less root volume loss than the CHF group in the 0–28 day period. In addition, the volumetric reduction of the cervical half of the distobuccal root in the 14–28 day period in the CHF group was significantly greater than in the CLF group (Table 1).

**PDL Hyalinization**

Percent hyalinization in both the CLF and CHF groups showed a similar pattern. The highest hyalinization was at day 3, which then decreased continuously to the baseline from 7 to 28 days. The hyalinization percentages reduced quickly in the 3- to 14-day period in both groups. However, in the 14–21 day period, the percent hyalinization in the CHF group decreased slowly compared with the CLF group which decreased at an almost constant rate. The hyalinization percentages in the CHF group were higher than the CLF group at all time points but significant differences were found only at days 3 and 21 for the distobuccal root (day 3:  $18.07 \pm 4.35\%$  vs  $10.81 \pm 2.76\%$ ; day 21:  $2.64 \pm 1.20\%$  vs  $0.25 \pm 0.41\%$ ) and at

day 21 for the distopalatal root ( $1.51 \pm 1.26\%$  vs  $0.27 \pm 0.50\%$ ). The intragroup comparison exhibited significantly higher percent hyalinization at days 3 and 7 than at day 0 in the CLF distobuccal root (day 0: 0%, day 3:  $10.81 \pm 2.76\%$ ; day 7:  $7.31 \pm 6.12\%$ ) and distopalatal root (day 0: 0%; day 3:  $8.46 \pm 5.81\%$ ; day 7:  $5.73 \pm 3.25\%$ ) and in the CHF distobuccal root (day 0: 0%; day 3:  $18.07 \pm 4.35\%$ ; day 7:  $10.75 \pm 9.62\%$ ) and distopalatal root (day 0: 0%; day 3:  $12.20 \pm 5.83\%$ ; day 7:  $7.80 \pm 4.58\%$ ) (Figure 8A–L, 9).

**DISCUSSION**

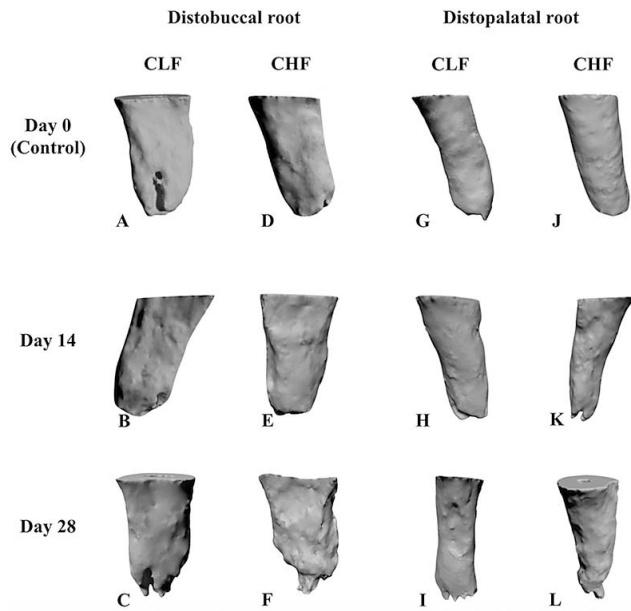
Root resorption is associated with multiple factors such as force magnitude, treatment time, age, emotional stress, and individual biological response.<sup>9,10</sup> The split-mouth experimental design can avoid confounding factors such as age, root morphology, and emotional stress, between two groups that might lead to misinterpretation of data.

Based on previous studies, direct application of light (10 g) or heavy (50–100 g) force induced root resorption. However, a heavier force magnitude created a large area of resorption and a significant reduction in root volume.<sup>6,7,10</sup> The results showed that root volume in the heavy force group was significantly

**Table 1.** Root Volume Loss in the CLF and CHF Groups

Period	Root Region	Distobuccal Root			Distopalatal Root		
		CLF (mm <sup>3</sup> ), Mean ± SD	CHF (mm <sup>3</sup> ), Mean ± SD	P Value	CLF (mm <sup>3</sup> ), Mean ± SD	CHF (mm <sup>3</sup> ), Mean ± SD	P Value
Days 0–14	Cervical	0.014 ± 0.027	0.037 ± 0.029	.05	0.005 ± 0.037	0.022 ± 0.045	.40
	Apical	0.005 ± 0.034	0.026 ± 0.029	.26	0.007 ± 0.025	0.007 ± 0.030	.78
Days 0–28	Cervical	0.047 ± 0.024	0.093 ± 0.033	.01*	0.014 ± 0.033	0.053 ± 0.030	.04*
	Apical	0.024 ± 0.036	0.063 ± 0.030	.01*	0.016 ± 0.025	0.022 ± 0.034	1.00
Days 14–28	Cervical	0.032 ± 0.024	0.056 ± 0.033	.04*	0.008 ± 0.033	0.031 ± 0.030	.16
	Apical	0.019 ± 0.036	0.037 ± 0.030	.07	0.009 ± 0.025	0.016 ± 0.034	1.00

\*  $P < .05$ .




**Figure 7.** Images of distobuccal (A–F) and distopalatal (G–L) roots in the CLF and CHF groups at different time points.

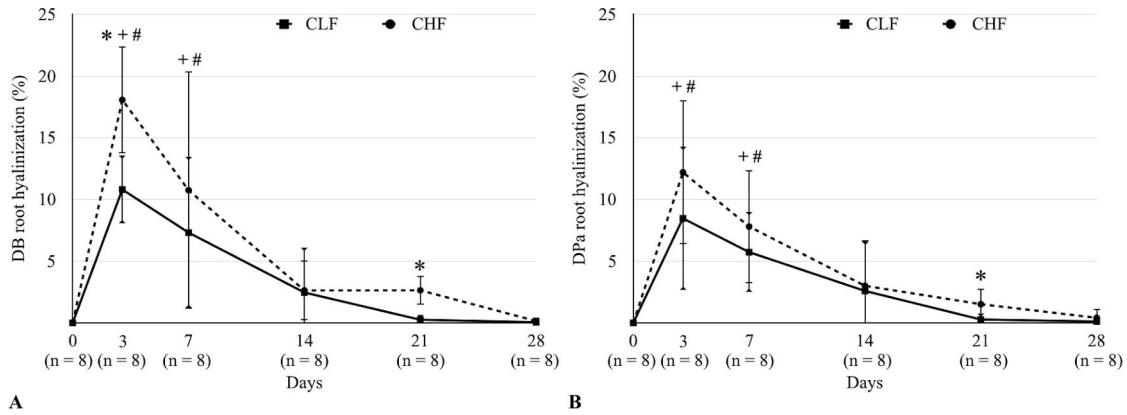
lower than in the light force group at 28 days even if corticotomy was applied. This finding was in contrast to previous studies. Murphy et al.<sup>11</sup> did not find a significant difference in resorption between corticision-assisted tooth movement with forces of 10 g (light force) and 100 g (heavy force) at 14 days. This contradictory result possibly came from the different experimental period. In the current study, 28 days of experimental tooth movement in the rat clearly identified differences in root resorption between the light and heavy forces more than in a 14-day experiment.<sup>6</sup> This finding also disagreed with a previous study<sup>8</sup> that used two-dimensional histological pictures to evaluate root resorption areas. Although high resolution is an advantage for histomorphometric analysis, root resorption happens in three dimensions. Therefore, two-dimensional measurement may not cover all resorption areas.

The results showed that the CHF group had more root volume loss than the CLF group in the 0- to 28- and 14- to 28-day periods but did not find a significant difference in the 0- to 14-day period. This might be explained by the temporary osteopenia that peaked at the first week after corticotomy and then gradually returned to normal.<sup>8,12</sup> A previous study showed that osteopenia can reduce strain from orthodontic force on the dental root, which leads to a decreased resorption crater.<sup>13</sup> Therefore, differences in root volume loss between the groups were not found in the 0- to 14-day period.

During the tipping tooth movement in this study, stresses occurred along the cervical and apical areas



**Figure 8.** Histological images of the distobuccal root in CLF (A–F), and CHF groups (G–L). (B, H) Osteoclasts from the bone marrow attacked the underside of the bone close to the hyalinization area. (C, D, I, J) Osteoclasts removing the hyalinized tissues. (K) Hyalinization in the other areas in the CHF group after 21 days (r indicates root; b, alveolar bone; h, hyalinized area; and PDL, periodontal ligament tissue. Arrows indicate the osteoclasts.



**Figure 9.** Time course of changes in the percent hyalinization between the CLF and CHF groups: (A) distobuccal root, (B) distopalatal root. \*  $P < .05$  between the CLF and CHF groups; +  $P < .01$  from day 0 in the CLF group; #  $P < .01$  from day 0 in the CHF group.

of the root. The study found reduction of root volume in both the cervical and apical regions. However, the volume loss in the cervical region was more noticeable than in the apical region in both the distobuccal and distopalatal roots. A finite-element method analysis also showed that major stress was found in the cervical region of the root during tooth movement.<sup>14</sup> In addition, the reduction in bone density shifted the center of rotation of the tooth more apically during the tipping movement.<sup>15</sup> Therefore, stresses mainly occurred in the cervical region and resulted in more resorption in the cervical region than in the apical half.

In conventional tooth movement, the use of light force has been advocated to reduce periodontal tissue damage. A comparison between light and heavy orthodontic forces showed greater hyalinization by heavy force than light force during the first 7 days.<sup>16</sup> Hyalinization in this study was in agreement with the previous report. The CHF group showed a significantly greater amount of hyalinized tissue than in the CLF group. However, rapid reduction of hyalinization was found, which began in the 3-to 7-day period. Previous studies showed that corticotomy could eliminate PDL hyalinization at an early stage of tooth movement by increased osteoclastic activity at an early time on the alveolar wall and in the bone marrow cavities, which began attacking the underside of the bone through the area of hyalinization.<sup>5,12</sup> Hyalinization, however, was found throughout the period observed in this study. A recent publication also revealed that hyalinization was found not only in the lag phase, but also in the acceleration and linear phases of tooth movement.<sup>17</sup> At day 21, hyalinization in the CHF group was significantly more than in the CLF group, which was almost absent in the PDL area. This finding possibly occurred from continuous heavy pressure at the PDL together with a diminished RAP and, consequently, the existence of hyalinization was prolonged.<sup>8</sup> However, the amount of hyalinization, which not only depends on the force

magnitude, probably resulted from local stress concentration on the buccal or palatal sides of the moving teeth that might vary due to irregularities in periodontal and bone morphology.<sup>18</sup>

The proximity of the injury is important for creating a sufficient osteopenia effect.<sup>19</sup> In this study, alveolar osteopenia was assumed surrounding all maxillary first molar roots. However, the four-dot decortications may have been closer to the mesial aspect and may not have provided the full benefit of osteopenia to the alveolar bone around the distal root. An increased quantity of decortication may be needed to eliminate this proximity problem and express an adequate RAP response.

Clinically, accelerated tooth movement is desired to shorten treatment time. Heavy force combined with corticotomy seemed effective in the initial stage after corticotomy.<sup>8</sup> However, the heavy force produced more PDL hyalinization, which may be related with pain. Additionally, anchorage loss and root resorption could be associated with heavier force magnitude.<sup>20</sup> Thus, the use of a heavy force in corticotomy-assisted orthodontic tooth movement should be cautiously considered.

## CONCLUSIONS

- A heavy force combined with corticotomy produced more PDL hyalinization than a light force combined with corticotomy in both the initial and late stages of tooth movement.
- During corticotomy-assisted tooth movement, root resorption volume was increased when a heavy force was used.

## REFERENCES

1. Pinto AS, Alves LS, Zenkner J, Zanatta FB, Maltz M. Gingival enlargement in orthodontic patients: Effect of



- treatment duration. *Am J Orthod Dentofacial Orthop.* 2017; 152(4):477–482.
2. Long H, Pyakurel U, Wang Y, Liao L, Zhou Y, Lai W. Interventions for accelerating orthodontic tooth movement: a systematic review. *Angle Orthod.* 2013;83(1):164–171.
  3. Wilcko MT, Wilcko WM, Pulver JJ, Bissada NF, Bouquot JE. Accelerated osteogenic orthodontics technique: a 1-stage surgically facilitated rapid orthodontic technique with alveolar augmentation. *J Oral Maxillofac Surg.* 2009;67(10):2149–2159.
  4. Frost HM. The regional acceleratory phenomenon. *Orthop Clin North Am.* 1981;12:725–726.
  5. Iino S, Sakoda S, Ito G, Nishimori T, Ikeda T, Miyawaki S. Acceleration of orthodontic tooth movement by alveolar corticotomy in the dog. *Am J Orthod Dentofacial Orthop.* 2007;131(4):448 e441–448.
  6. Gonzales C, Hotokezaka H, Yoshimatsu M, Yozgatian JH, Darendeliler MA, Yoshida N. Force magnitude and duration effects on amount of tooth movement and root resorption in the rat molar. *Angle Orthod.* 2008;78(3):502–509.
  7. Nakano T, Hotokezaka H, Hashimoto M, et al. Effects of different types of tooth movement and force magnitudes on the amount of tooth movement and root resorption in rats. *Angle Orthod.* 2014;84(6):1079–1085.
  8. Kraiwattanapong K, Samruajbenjakun B. Effects of different force magnitudes on corticotomy-assisted orthodontic tooth movement in rats. *Angle Orthod.* 2018;88(5):632–637.
  9. Vandevska-Radunovic V, Murison R. Emotional stress and orthodontic tooth movement: effects on apical root resorption, tooth movement, and dental tissue expression of interleukin-1 alpha and calcitonin gene-related peptide immunoreactive nerve fibres in rats. *Eur J Orthod.* 2010; 32(3):329–335.
  10. Harris DA, Jones AS, Darendeliler MA. Physical properties of root cementum: part 8. Volumetric analysis of root resorption craters after application of controlled intrusive light and heavy orthodontic forces: a microcomputed tomography scan study. *Am J Orthod Dentofacial Orthop.* 2006;130(5):639–647.
  11. Murphy C, Kalajzic Z, Chandhoke T, Utreja A, Nanda R, Uribe F. The effect of corticision on root resorption with heavy and light forces. *Angle Orthod.* 2016;86(1):17–23.
  12. Baloul SS, Gerstenfeld LC, Morgan EF, Carvalho RS, Van Dyke TE, Kantarci A. Mechanism of action and morphologic changes in the alveolar bone in response to selective alveolar decortication-facilitated tooth movement. *Am J Orthod Dentofacial Orthop.* 2011;139(4 Suppl):S83–101.
  13. Goldie RS, King GJ. Root resorption and tooth movement in orthodontically treated, calcium-deficient, and lactating rats. *Am J Orthod.* 1984;85(5):424–430.
  14. Gonzales C, Hotokezaka H, Arai Y, et al. An in vivo 3D micro-CT evaluation of tooth movement after the application of different force magnitudes in rat molar. *Angle Orthod.* 2009;79(4):703–714.
  15. Verna C, Cattaneo PM, Dalstra M. Corticotomy affects both the modus and magnitude of orthodontic tooth movement. *Eur J Orthod.* 2018;40(1):107–112.
  16. Tomizuka R, Shimizu Y, Kanetaka H, et al. Histological evaluation of the effects of initially light and gradually increasing force on orthodontic tooth movement. *Angle Orthod.* 2007;77(3):410–416.
  17. Von Bohl M, Maltha J, Von den Hoff H, Kuijpers-Jagtman AM. Changes in the periodontal ligament after experimental tooth movement using high and low continuous forces in beagle dogs. *Angle Orthod.* 2004;74(1):16–25.
  18. Böhl MV, Maltha JC, Von Den Hoff JW, Kuijpers-Jagtman AM. Focal hyalinization during experimental tooth movement in beagle dogs. *Am J Orthod Dentofacial Orthop.* 2004; 125(5):615–623.
  19. Sebaoun JD, Kantarci A, Turner JW, Carvalho RS, Van Dyke TE, Ferguson DJ. Modeling of trabecular bone and lamina dura following selective alveolar decortication in rats. *J Periodontol.* 2008;79(9):1679–1688.
  20. Yee JA, Türk T, Elekdağ-Türk S, Cheng LL, Darendeliler MA. Rate of tooth movement under heavy and light continuous orthodontic forces. *Am J Orthod Dentofacial Orthop.* 2009;136(2):150.e1–150.e9.