

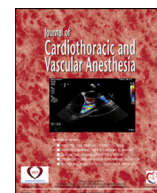


Since January 2020 Elsevier has created a COVID-19 resource centre with free information in English and Mandarin on the novel coronavirus COVID-19. The COVID-19 resource centre is hosted on Elsevier Connect, the company's public news and information website.

Elsevier hereby grants permission to make all its COVID-19-related research that is available on the COVID-19 resource centre - including this research content - immediately available in PubMed Central and other publicly funded repositories, such as the WHO COVID database with rights for unrestricted research re-use and analyses in any form or by any means with acknowledgement of the original source. These permissions are granted for free by Elsevier for as long as the COVID-19 resource centre remains active.

Contents lists available at [ScienceDirect](https://www.sciencedirect.com)

## Journal of Cardiothoracic and Vascular Anesthesia

journal homepage: [www.jcvaonline.com](http://www.jcvaonline.com)

## Letters to the Editor

### Right Ventricular Dysfunction in Patients with Coronavirus Disease 2019 Supported with Extracorporeal Membrane Oxygenation



To the Editor:

The development of right ventricular dysfunction (RVD) while on venovenous (VV) extracorporeal membrane oxygenation (ECMO) is not well-understood. Before the pandemic, single-center reports have described RVD in patients with acute respiratory distress syndrome (ARDS) on VV ECMO, while others identified improvement in RV function after ECMO initiation.<sup>1-3</sup> Although early reports of patients with coronavirus disease 2019 (COVID-19) ARDS identified echocardiography data in right ventricular (RV) dilation and RVD in 40% and 27%, respectively, the prevalence and severity of RVD in patients with COVID-19 requiring ECMO therapy are unknown.<sup>4</sup> Given this knowledge gap, we performed a pilot study evaluating RV function in patients with severe ARDS due to COVID-19 supported with conventionally cannulated, femoro femoral VV ECMO.

Following Institutional Review Board approval, we analyzed point-of-care echocardiographic data acquired from adult patients with COVID-19 on ECMO during clinical care in the cardiovascular intensive care unit between April 2020 and October 2020. A point-of-care examination was triggered by hemodynamic instability and/or refractory hypoxemia. Two-dimensional (2-D) examinations were performed in accordance with American Society of Echocardiography guidelines.<sup>5</sup> Tricuspid annular plane systolic excursion (TAPSE), tricuspid lateral annular systolic velocity (S'), and end-diastolic diameter (EDD) measurements were obtained. Images with frame rates >30 frames/s subsequently were exported for offline analysis of free-wall longitudinal strain (FWLS) and fractional area change (FAC) with TomTec 2-D CPA software (TomTec Imaging Systems, Unterschleissheim, Germany). Summary statistics are reported as frequency (percentage) for categorical variables and as mean (standard deviation [SD]) or median [interquartile range] for continuous variables.

A total of 11 consecutive patients treated between April and October 2020 were analyzed. [Table 1](#) presents demographic and clinical variables, and [Table 2](#) presents the echocardiographic findings. The mean (SD) time to initial evaluation

occurred at 9.17 (7.44) days of ECMO support, prompted by clinical deterioration. The majority of patients (seven, [63.6%]) had abnormal RV size, with mean (SD) EDD values of 4.47 (0.69) cm and 3.64 (0.83) cm at the base and mid chamber, respectively. TAPSE mean (SD) of 2.15 (0.65) cm and S' of 13.8 (4.69) cm/s were normal for the majority of examinations. However, FWLS and FAC measurements were abnormal in nine patients (81.8%) and ten patients (90.9%), with a mean (SD) of -16.37% (5.97%) and 22.61% (6.2%), respectively. RVD causing clinical instability requiring inotropic support was present in five patients (45.5%).

RVD is a well-described complication of ARDS, with incidence varying between 22% and 50%.<sup>6</sup> Current evidence suggests similar rates in COVID-19 ARDS.<sup>4</sup> Patients with ARDS requiring VV ECMO do not appear immune to this complication, with prepandemic studies reporting RVD in 18%-34% in this cohort.<sup>1,2</sup> Our data further showed that a substantial number of patients with severe ARDS due to COVID-19 may develop clinically significant RVD while being supported with femoro femoral VV ECMO. RV enlargement, abnormal myocardial free wall strain, and abnormal FAC were found in the majority of patients. Additionally, just under half of our patients experienced clinically significant RVD, defined as hemodynamic instability with echocardiographic stigmata of RVD and negative workup for other etiologies. While an improvement in RV function previously has been noted<sup>3</sup> following the initiation of VV ECMO, our findings suggested this effect may be short-lived. On average, RVD was found nine days into ECMO therapy.

Based on our results, RVD complicating ECMO support in patients with COVID-19 ARDS may be more ubiquitous than previously observed in other ARDS ECMO cohorts. Unique COVID-19 characteristics may be responsible for these findings. Pulmonary microthrombi, endothelial injury, lung consolidation, iatrogenic therapies, and patient-specific characteristics such as obesity are just some factors that may play a role in RVD development.<sup>7</sup>

Our findings have important implications for patient care. Some centers around the U.S. preemptively changed their ECMO cannulation practices during the pandemic to promote RV protection, and results have been encouraging.<sup>8,9</sup> Our results provide additional data potentially supporting the use of dual-staged cannulae in this population. Furthermore, our findings suggest that echocardiographic evaluation of RV

Table 1  
Demographic and Clinical Variables

Variables	Results (n = 11)
Age, y, mean (SD)	49.55 (8.96)
Sex, n (%)	
Male	6 (54.5%)
Female	5 (45.5%)
Race, n (%)	
White	4 (36.4%)
Black	2 (18.2%)
Asian	2 (18.2%)
Other	3 (27.3%)
Ethnicity, Hispanic, n (%)	3 (27.3%)
BMI, kg/m <sup>2</sup> , mean (SD)	35.1 (7.6)
Comorbidities, n (%)	
Obesity	9 (81.8%)
Type 2 Diabetes Mellitus	6 (54.5%)
Hypertension	4 (36.4%)
Chronic kidney disease	3 (27.3%)
Neurologic disorder	2 (18.2%)
COPD	1 (9.1%)
Asthma	1 (9.1%)
Connective tissue disease	1 (9.1%)
HFrEF	0 (0%)
Chronic liver disease	0 (0%)
Cancer	0 (0%)
Pulmonary fibrosis	0 (0%)
Length of stay, d, mean (SD)	31.8 (17.3)
Length of ICU stay, d, mean (SD)	18.5 (10.7)
ECMO length, d, mean (SD)	20.92 (9.90)
Average daily respiratory variables per patient from ECMO start to first exam, median [IQR]	
PaO <sub>2</sub> , mmHg	72.5 [61.7-77.0]
FiO <sub>2</sub> , %	60.0 [48.8-55.0]
PaO <sub>2</sub> /FiO <sub>2</sub> ratio, mmHg	131.1 [109.2-165.0]
Tidal volume, mL	365.3 [284.4-425.0]
Plateau pressure, cm H <sub>2</sub> O	33 [31.7-35.2]
PEEP, cm H <sub>2</sub> O	12.8 [12.0-17.1]
Variables on first exam day, median [IQR]	
Lowest pH, units	7.34 [7.3-7.4]
Lowest PaO <sub>2</sub> , mmHg	76.2 [56.6-117.4]
Highest PCO <sub>2</sub> , mEq/L	54.6 [48.0-59.5]
Highest bicarbonate, mmol/L	28.9 [24-31.2]
Lowest SaO <sub>2</sub> , %	85.9 [83.5-93.1]
Average variables from ECMO start to first exam date, median [IQR]	
ECMO highest flow, L/min, median [IQR]	4.66 [4.33-4.79]
ECMO highest SWEEP, L/min, median [IQR]	4.5 [3.64-5.50]
Length ECMO flow >5 L/min, h	14.88 [7.0-18.44]
SOFA, units	9.0 [5.56-9.67]
D-Dimer, µg/mL	5.13 [3.33-9.83]
Ferritin, ng/mL	754.62 [138.25-1468.7]
Highest peak inspiratory pressure	31.06 [28.67-41.3]
Lowest SaO <sub>2</sub> , %	91.2 [87.3-91.95]
Complications, n (%)	
Delirium/Agitation	11 (100%)
AKI	9 (81.8%)
Bleeding/thrombosis	8 (72.7%)
RV failure requiring inotropic support	5 (45.5%)
RRT requirement	4 (36.4%)
Septic Shock	4 (36.4%)
Liver function abnormality	3 (27.3%)
LV dysfunction	1 (9.1%)
Pulmonary embolism	0 (0%)

SD, standard deviation; BMI, body mass index; COPD, chronic obstructive pulmonary disease; HFrEF, heart failure with reduced ejection fraction; ECMO, extracorporeal membrane oxygenation; IQR, interquartile range; ICU, intensive care unit; SOFA, sequential organ failure assessment; AKI, acute kidney injury; RV, right ventricle; RRT, renal replacement therapy; LV, left ventricle.

Table 2  
Point-of-Care Echocardiographic Findings

Variables	N	Results
Number of patients	11	
Total number of echocardiographic exams	11	
Number of days to exam after ECMO start, mean (SD)		9.17 (7.44)
Echocardiographic exam results, mean (SD)		
FWLS (%)	11	-16.37 (5.97)
FAC (%)	11	22.61 (6.2)
EDD basal (cm)	11	4.47 (0.69)
EDD mid chamber (cm)	11	3.64 (0.83)
TAPSE (cm)	8	2.15 (0.65)
S' (cm/s)	8	13.8 (4.69)
Incidence of abnormal measurements during ECMO, n (%)		
FWLS > -20%	11	9 (81.8%)
FAC <35%	11	10 (90.9%)
EDD basal > 4.2 cm	11	6 (54.5%)
EDD mid cavity > 3.5 cm	11	7 (63.6%)
TAPSE < 1.7 cm	8	3 (37.5%)
S' < 9.5 cm/s	8	0 (0%)
Number of patients with abnormal results, n (%)		
FWLS	11	9 (81.81%)
FAC	11	9 (81.81%)
Size	11	7 (63.6%)
TAPSE	11	3 (27.27%)
S'	11	0 (0%)

ECMO, extracorporeal membrane oxygenation; SD, standard deviation; FAC, fractional area change; FWLS, free-wall longitudinal strain; EDD, end-diastolic diameter; TAPSE, tricuspid annular plane systolic excursion; S', tricuspid lateral annular systolic velocity; RV, right ventricle.

function in patients with COVID-19 ARDS on ECMO should include FAC and FWLS because TAPSE and S' may not be accurate.

Our study had significant limitations including retrospective nature and small sample size. In addition, the analytical utility of point-of-care echocardiography in FWLS acquisition remains uncertain, and the lack of echocardiograms before ECMO cannulation may have missed preexisting RVD in this population. Further longitudinal studies are needed to fully elucidate the effects of COVID-19 and ECMO on the right ventricle over time. Moreover, describing regional strain at the free wall base, mid-chamber, and apex would help pinpoint the pathophysiology of the dysfunction. Future studies also could compare different ECMO cannulation strategies in this at-risk population

In summary, RVD may develop in a significant number of patients with COVID-19 ARDS supported on ECMO. These findings have significant clinical implications and add to the body of evidence supporting alternative cannulation modalities and use of FWLS and FAC as descriptors of RV function in this patient population.

## Conflict of Interest

None

## References

- 1 Ortiz F, Brunsvold ME, Bartos JA. Right ventricular dysfunction and mortality after cannulation for venovenous extracorporeal membrane oxygenation. *Crit Care Explor* 2020;2:e0268.
- 2 Vogel DJ, Fabbri A, Falvo A, et al. Assessment of right ventricular function with CT and echocardiography in patients with severe acute respiratory distress syndrome on extracorporeal membrane oxygenation. *Crit Care Explor* 2021;3:e0345.
- 3 Miranda DR, van Thiel R, Brodie D, et al. Right ventricular unloading after initiation of venovenous extracorporeal membrane oxygenation. *Am J Respir Crit Care Med* 2015;191:346–8.
- 4 Szekely Y, Lichter Y, Taieb P, et al. Spectrum of cardiac manifestations in COVID-19: A systematic echocardiographic study. *Circulation* 2020;142:342–53.
- 5 Lang RM, Badano LP, Mor-Avi V, et al. Recommendations for cardiac chamber quantification by echocardiography in adults: An update from the American Society of Echocardiography and the European Association of Cardiovascular Imaging. *Eur Heart J Cardiovasc Imaging* 2015;16:233–71.
- 6 Zochios V, Parhar K, Tunnicliffe W, et al. The right ventricle in ARDS. *Chest* 2017;152:181–93.
- 7 Kopanczyk R, Al-Qudsi OH, Bhatt AM. Extracorporeal membrane oxygenation and coronavirus disease 2019. *JAMA Surg* 2021;156:410–2.
- 8 Cain MT, Smith NJ, Barash M, et al. Extracorporeal membrane oxygenation with right ventricular assist device for COVID-19 ARDS. *J Surg Res* 2021;264:81–9.
- 9 Mustafa AK, Alexander PJ, Joshi DJ, et al. Extracorporeal membrane oxygenation for patients with COVID-19 in severe respiratory failure. *JAMA Surg* 2020;155:990–2.

Rafal Kopanczyk, DO\*<sup>1</sup>

Omar H. Al-Qudsi, MD\*

Alberto Uribe, MD, MS, MPH<sup>c</sup>\*

Luis Priel, MD\*

Juan Fiorda-Diaz, MD\*

Mahmoud Abdel-Rasoul, MS, MPH<sup>†</sup>

Nicolas Kumar, BS<sup>‡</sup>

Amar M. Bhatt, MD\*

\*The Ohio State University Wexner Medical Center, Department of Anesthesiology, Columbus, OH

<sup>†</sup>Center for Biostatistics, Department of Biomedical Informatics, College of Medicine, The Ohio State University, Columbus, OH

<sup>‡</sup>The Ohio State University College of Medicine, Columbus, OH

<https://doi.org/10.1053/j.jvca.2021.05.019>

## Refractory Hypotension During ECMO: Words of Caution When Using Methylene Blue



To the Editor:

WE READ WITH GREAT INTEREST the retrospective observational study by Ortoleva et al. describing their experience using methylene blue (MB) to treat vasoplegia in patients requiring extracorporeal membrane oxygenation (ECMO).<sup>1</sup> We would like to bring attention to potential patient safety concerns with using MB in special pathophysiologic states and in the broader setting of ECMO.

Previously, a device-related adverse event was reported to the US Food and Drug Administration describing blue-tinged

water in the heat exchanger water bath of an ECMO circuit in a patient treated with MB for vasoplegia.<sup>2</sup> The manufacturer's response to the event stated this phenomenon is believed to be unidirectional and, therefore, there is no risk of substance transfer from heat exchanger to patient circulation.

Heat exchangers are crucial for the function of ECMO circuits to manage excessive heat dissipation from large blood surface area contact and provide a mechanism for thermal management. Water from the heat exchanger is pumped through thermoplastic polyurethane fibers in the oxygenator, with countercurrent flow allowing for heat exchange and tight regulation of circuit temperature. The Extracorporeal Life Support Organization recommends cleaning and disinfecting heat exchanger water baths "from time to time."<sup>3</sup> Although external surfaces are cleaned regularly and between cases, different manufacturers recommend varying schedules for heat exchanger water bath and fluid circuit cleaning, with some as infrequently as every three months.<sup>4</sup>

Interestingly, the phenomenon of MB transfer across the polyurethane heat exchanger fibers may occur bidirectionally. In an ex vivo experiment, very high quantities of MB (1,500 mg) were added to the water bath of a heat exchanger, which then was connected to a plasmalyte-primed closed-loop ECMO circuit.<sup>5</sup> Flow was circulated for six hours and then left idle. After 13 and 30 days, flow was recirculated, and samples were analyzed with spectrophotometry, revealing increased optical densities suggestive of MB transfer. Oxygenator fibers and plasmalyte in the ECMO circuit also were visibly blue. Indeed, polyurethanes have demonstrated adsorptive capacity for MB.<sup>6</sup> Chemical analysis to quantify transferred MB content in the circuit was not performed. Because MB is small in size ( $\leq 15$  angstroms) and has a low molecular weight ( $< 600$  Dalton), it will transport passively across membranes to maintain concentration equilibria.<sup>7,8</sup> Aside from concentration gradient and temperature, the most significant factor affecting MB passage through materials is relative molecular size to material pore size, as it is a primary determinant of the diffusivity of the material. In ECMO systems, drugs of similar or lower molecular weight compared with MB are likely to diffuse through polyurethane and lower-density oxygenator heat exchange fiber materials as MB is much smaller than the pore size of the microporous fiber materials used.<sup>9,10</sup> However, some newer oxygenators (eg, Medtronic Affinity) use polyethylene terephthalate heat exchanger fibers, designed for higher density to provide greater chemical resistance with lower permeability as compared with lower-density counterparts such as polyurethane.<sup>11</sup>

As MB is nearly completely protein-bound (94%) and has a high volume of distribution (255L),<sup>12</sup> it is unclear to what extent this transfer phenomenon may occur at physiologic dosages of MB and in the presence of complex pharmacokinetics that are not present in ex vivo experiments. Further complicating these interactions is adsorption of MB to ECMO cannulae and tubing, albeit to a lesser extent than oxygenator fibers due to higher density. With the assumption that most solid polymers are nanoporous (1–100 nm) and the tubing is a more crystalline form, and thereby denser, positively charged low-