

## OPEN

# Management of Condyloma Acuminata in Pregnancy: A Review

Shunya Sugai, MD, Koji Nishijima, MD, PhD, and Takayuki Enomoto, MD, PhD

**Abstract:** No clear guidelines are available for the management of pregnant women with condyloma acuminata, a human papillomavirus-associated benign neoplasm that develops in the genital tract. We performed a systematic review to gain a better understanding of the management of condyloma acuminata during pregnancy. In this review, we mainly focused on treatments. We searched PubMed, Google Scholar, and Web of Science to identify studies on the treatment of condyloma acuminata during pregnancy. Thirty articles met the inclusion criteria. The treatment methods described in the literature were laser therapy, cryotherapy, imiquimod, photodynamic therapy, trichloroacetic acid, and local hyperthermia. The most effective treatment remains unclear. Various factors must be considered when deciding how to treat. Based on our assessment of the literature, we recommend cryotherapy as the first-choice treatment and laser therapy as the second-choice treatment. Imiquimod can be considered in cases such as extensive condyloma acuminata that is not easily treated by cryotherapy or laser therapy. In such cases, sufficient informed consent must be obtained from the patient. Cryotherapy, laser therapy, and imiquimod have been administered during all 3 trimesters with no severe adverse effects, but we cautiously recommend reserving laser therapy until the third trimester because of the lower risk of recurrence before delivery. There are still many unclear points regarding the management of condyloma in pregnancy, and further research is needed.

Condyloma acuminata is a benign neoplasm that develops in the genital tract, and it is caused by infection with human papillomavirus (HPV) types 6 and 11.<sup>1</sup> The estimated prevalence of condyloma acuminata in the United States is 1%.<sup>2</sup> Because the onset is likely to occur at the age of 25 to 34 years, which is the age of childbearing, this condition can occur during pregnancy.<sup>3</sup> The main symptoms of condyloma acuminata are pain, itching, increased vaginal secretions, and bleeding, but many cases are

asymptomatic,<sup>4</sup> and the condition may be first discovered during pregnancy.

In the offspring of pregnant women with condyloma acuminata, juvenile-onset recurrent respiratory papillomatosis (JORRP) may develop by mother-to-child transmission. Juvenile-onset recurrent respiratory papillomatosis is a benign neoplasm in the larynx and trachea in children and is caused by HPV types 6 and 11.<sup>5</sup> The estimated prevalence is 1.7 to 4.3 per 100,000 children in the United States.<sup>5,6</sup> Surgical treatment is required; affected children require a mean of 5 surgeries annually and a median of 13 surgeries throughout their lifetime.<sup>6</sup>

A maternal history of condyloma acuminata in pregnancy is a strong risk factor for the development of JORRP.<sup>7,8</sup> Silverberg et al.<sup>8</sup> reported 1 case of JORRP per 144 births in pregnant women with condyloma acuminata and found that the risk of JORRP was 231 times higher in the presence than absence of maternal condyloma acuminata. Therefore, prevention of mother-to-child transmission in pregnant women with condyloma acuminata is an important management point. However, no clear guidelines are available. In this systematic review, we summarize data on the efficacy and adverse events related to treatment of condyloma acuminata in pregnancy.

## MATERIALS AND METHODS

### Search Strategy

We used 3 databases (PubMed, Google Scholar, and Web of Science) and references or related articles to conduct a review of the management of condyloma acuminata in pregnancy.

We first identified articles in PubMed using the following search string: (“condylomata acuminata/therapy”[MeSH]) AND (“pregnancy”[MeSH]). Given the search results in PubMed, we added the words “cryotherapy,” “laser,” “imiquimod,” “trichloroacetic acid,” “photodynamic therapy,” and “local hyperthermia” to cover all relevant articles. Next, articles in Google Scholar and Web of Science were identified using the following search string: (“condylomata acuminata” OR “condyloma acuminata” OR “genital wart” OR “genital warts”) AND “pregnancy” AND (“cryotherapy” OR “cryosurgery” OR “imiquimod” OR “laser” OR “trichloroacetic acid” OR “photodynamic therapy” OR “local hyperthermia”).

### Inclusion/Exclusion Criteria

All included articles were peer reviewed, were published in English from January 1, 1966, to December 31, 2019, and contained information on the treatment of condyloma acuminata in pregnancy. Some studies of treatment were limited to pregnant women, whereas others were not. For articles that were not limited to pregnant women, we extracted information on the pregnant women from the text. We excluded studies that did not include pregnant women or in which the treatment outcomes in pregnancy were unclear.

From the Department of Obstetrics and Gynecology, Niigata University Medical and Dental Hospital, Niigata, Japan

Acknowledgments: The authors thank Angela Morben, DVM, ELS, from Edanz Group (<https://en-author-services.edanzgroup.com/ac>), for editing a draft of this article.

Conflict of Interest and Sources of Funding: The authors declare no conflicts of interest. No funding was received for this study.

Correspondence: Shunya Sugai, MD, Department of Obstetrics and Gynecology, Niigata University Medical and Dental Hospital, 1-757 Asahimachidori, Chuo-ku, Niigata 951-8510, Japan. E-mail: sugoi3215@gmail.com. Received for publication May 31, 2020, and accepted October 18, 2020.

Supplemental digital content is available for this article. Direct URL citations appear in the printed text, and links to the digital files are provided in the HTML text of this article on the journal's Web site (<http://www.stdjournals.com>).

DOI: 10.1097/OLQ.0000000000001322

Copyright © 2020 The Author(s). Published by Wolters Kluwer Health, Inc. on behalf of the American Sexually Transmitted Diseases Association. This is an open-access article distributed under the terms of the Creative Commons Attribution-Non Commercial-No Derivatives License 4.0 (CCBY-NC-ND), where it is permissible to download and share the work provided it is properly cited. The work cannot be changed in any way or used commercially without permission from the journal.

## Data Extraction and Synthesis

One reviewer extracted the data. The extracted information included the type of treatment, number of patients treated, trimester of pregnancy at the time of the first treatment, recurrence until delivery, and severe adverse effects. The data were classified according to the type of treatment and summarized in a table.

## RESULTS

Our search of key terms resulted in 4876 unique articles, 4754 of which were excluded during title and abstract screening. Full-text reviews of the remaining 122 articles were performed, and 92 did not meet the inclusion criteria. Therefore, 30 articles were included in the present review (Fig. 1).

The most common treatment of condyloma acuminata during pregnancy among the 30 articles was laser therapy (n = 17),<sup>9-25</sup> followed by cryotherapy (n = 7),<sup>26-30,31s,32s</sup> imiquimod cream (n = 4),<sup>33s-36s</sup> photodynamic therapy (n = 2),<sup>32s,37s</sup> trichloroacetic acid (n = 1),<sup>20</sup> and local hyperthermia (n = 1).<sup>38s</sup> One of the articles on photodynamic therapy was a study comparing the outcomes of photodynamic therapy with those of cryotherapy. The article on trichloroacetic acid was a study investigating the combination of trichloroacetic acid with laser therapy. We found no reports describing treatment with trichloroacetic acid as a single agent in pregnant women.

Treatment is often classified into patient-applied treatment and provider-applied treatment. Table 1 summarizes reports on patient-applied treatment (imiquimod cream) and provider-applied treatment (laser therapy, cryotherapy, photodynamic therapy, trichloroacetic acid, and local hyperthermia). The primary author, year published, pregnancy trimester at the time of the first treatment, recurrence until delivery, severe adverse effects, and other notes are presented for each of the treatments.

### Patient-Applied Treatment

#### Imiquimod Cream

Imiquimod is an imidazoquinolinamine derivative that has no in vitro antiviral activity but induces macrophages to secrete

cytokines such as interleukin 2 and interferon  $\alpha$ . It is effective against condyloma acuminata as an immune response modifier.<sup>1,39s</sup>

Previous reports of treatment with imiquimod cream are summarized in Table 1. The pregnant women described in the reports were treated during all 3 trimesters, and the duration of therapy ranged from 3 to 10 weeks.<sup>33s-36s</sup> Ciavattini et al.<sup>36s</sup> reported that 2 (50%) of 4 patients had a complete response after 4 weeks of treatment, whereas the other 2 patients had a partial response and underwent surgical resection of the remnant lesions. In all reports, the recurrence rate until delivery was 0%.

The most commonly reported adverse effects of imiquimod are topical mild erythema (67%) and severe erythema (<6%).<sup>40s</sup> Ciavattini et al.<sup>36s</sup> reported that 3 (75%) of 4 patients had mild erythema. In other reports, the off-label use of imiquimod (using the same treatment as in nonpregnant women) resulted in no severe adverse maternal events at the site of application.<sup>33s-35s</sup> Audisio et al.<sup>35s</sup> reported that one patient had uterine contractions and therapy was discontinued. No adverse fetal outcomes or fetal and neonatal abnormalities were observed in any studies.

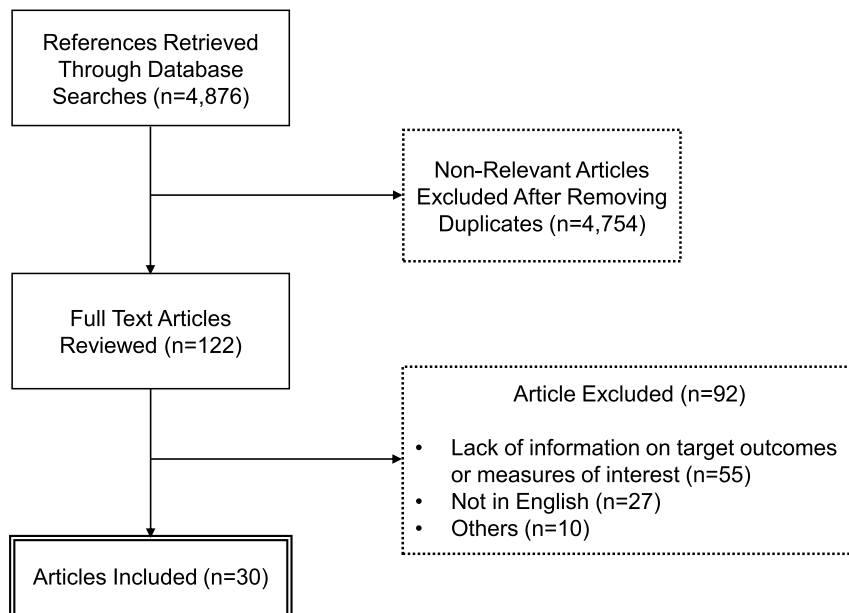
The advantages of imiquimod include the elimination of frequent outpatient visits and the ability to treat extensive condyloma acuminata that is not easily treated by cryotherapy or laser therapy.<sup>36s</sup>

### Provider-Applied Treatment

#### Laser Therapy

Laser therapy involves the collection and use of the energy of an infrared laser to evaporate the affected tissue.<sup>39s</sup> Some centers offer laser therapy as an outpatient procedure. However, because the patient must endure extreme heat, general anesthesia, or spinal anesthesia is required; therefore, an in-hospital procedure is usually better.<sup>1,39</sup>

Laser therapy is preferable in terms of patient comfort because it seals nerve endings, resulting in less pain than in conventional surgical treatment. In addition, bleeding can be minimized



**Figure 1.** Flowchart of article selection process. Our key term search resulted in 4876 unique articles, 4754 of which were excluded during title and abstract screening. After full-text review of the remaining 122 articles, 92 did not meet the inclusion criteria. Finally, we included 30 articles in this review.

TABLE 1. Literature Summary: Treatments for Condyloma Acuminata in Pregnancy

| Treatment                      | First Author                  | Year Published          | No. Pregnant Patients | Pregnancy Trimester | Recurrence Until Delivery | Severe Adverse Effects  | Notes  |   |
|--------------------------------|-------------------------------|-------------------------|-----------------------|---------------------|---------------------------|---|--|---|
| Patient-applied imiquimod      | Maw <sup>33s</sup>            | 2004                    | 1                     | 2                   | 0.0%                      | NR  | The duration of therapy was 4 wk.  |   |
|                                | Einarson <sup>34s</sup>       | 2006                    | 4                     | 2 and 3             | 0.0%                      | NR  | The duration of therapy was 3–10 wk.   |   |
|                                | Audisio <sup>35s</sup>        | 2008                    | 17                    | 2 and 3             | NR                        | One patient had uterine contractions, and therapy was discontinued. | The duration of therapy was 1–8 wk. Thirteen patients had a complete response, whereas 1 patient had a partial response.   |   |
| Provider-applied laser therapy | Ciavattini <sup>36s</sup>     | 2012                    | 4                     | 2 and 3             | 0.0%                      | NR  | The duration of therapy was 4 wk. Two patients had a complete response, whereas 2 patients had a partial response and underwent surgical excision of remnant lesions.                        |   |
|                                | Baggish <sup>9</sup>          | 1980                    | 15                    | NR                  | NR                        | NR  |  |   |
|                                | Hahn <sup>10</sup>            | 1981                    | 5                     | NR                  | NR                        | NR  |  |   |
|                                | Malfetano <sup>11</sup>       | 1981                    | 1                     | 3                   | 0.0%                      | NR  |  |   |
|                                | Calkins <sup>12</sup>         | 1982                    | 15                    | NR                  | NR                        | NR  |  |   |
|                                | Ferenzy <sup>13</sup>         | 1983                    | 3                     | NR                  | 0.0%                      | NR  |  |   |
|                                | Kryger-Baggesen <sup>14</sup> | 1984                    | 15                    | NR                  | NR                        | One patient had symptoms of preterm labor a few days after therapy. |  |   |
|                                | Grundsel <sup>15</sup>        | 1984                    | 6                     | 1, 2, and 3         | NR                        | NR  |  |   |
|                                | Ferenzy <sup>16</sup>         | 1984                    | 43                    | 1, 2, and 3         | 13.9% (6/43)              | NR  | The recurrence rate was 33.3% (3/9) and 18.8% (3/16) among the patients treated during the first and second trimester, respectively. Recurrence was not observed during the third trimester. |   |
|                                | cryotherapy                   | Scott <sup>17</sup>     | 1984                  | 2                   | NR                        | NR  | NR   |   |
|                                |                               | Rotteleur <sup>18</sup> | 1986                  | 18                  | NR                        | NR  | NR   |   |
|                                |                               | Caglar <sup>19</sup>    | 1987                  | 8                   | 1, 2, and 3               | NR  | NR   |   |
|                                |                               | Schwartz <sup>20</sup>  | 1988                  | 32                  | 1, 2, and 3               | 9.4% (3/32)   | One patient had PROMs 4 d after therapy. Another patient developed acute pyelonephritis within 24 h of therapy.  | This is a report of laser therapy combined with trichloroacetic acid. |
|                                |                               | Hankins <sup>21</sup>   | 1989                  | 9                   | 2 and 3                   | 22.2% (2/22)  | One patient at 36 wk developed clinical chorioamnionitis 8 h after therapy. Another patient had bleeding requiring both direct pressure and electrocautery.                                  |   |
|                                |                               | Adelson <sup>22</sup>   | 1990                  | 16                  | 2 and 3                   | 0.0%  | NR   |   |
| Chaisilwattana <sup>23</sup>   |                               | 1996                    | 13                    | NR                  | NR                        | NR  |  |   |
| Arena <sup>24</sup>            |                               | 2001                    | 115                   | 2 and 3             | 7.8% (9/115)              | NR  |  |   |
| Widschwendter <sup>25</sup>    |                               | 2019                    | 91                    | 1, 2, and 3         | 16.5% (15/91)             | NR  | Patients with recurrence were treated earlier than those without recurrence.   |   |
| Bergman <sup>26</sup>          |                               | 1984                    | 34                    | 2 and 3             | 0.0%                      | NR  | The number of therapy sessions was 3 or more in only one patient and 1 or 2 in the other patients.   |   |
| cryotherapy                    | Matsunaga <sup>27</sup>       | 1987                    | 51                    | 2 and 3             | 0.0%                      | NR  | The number of therapy sessions was 2 in 43 patients, 3 in 4 patients, and 4 in 4 patients.   |   |
|                                | Bergman <sup>28</sup>         | 1987                    | 28                    | 2 and 3             | 0.0%                      | NR  | The number of therapy sessions was 4 in only one patient and 1 or 2 in the other patients.   |   |
|                                | Matányi <sup>29</sup>         | 1988                    | 13                    | 1, 2, and 3         | NR                        | NR  |  |   |
|                                |                               |                         |                       |                     |                           |   |  |   |

Continued next page

TABLE 1. (Continued)

| Treatment            | First Author                               | Year Published | No. Pregnant Patients | Pregnancy Trimester | Recurrence Until Delivery | Severe Adverse Effects | Notes  |
|----------------------|--|----------------|-----------------------|---------------------|---------------------------|------------------------|--|
|                      | Odeibat <sup>30</sup>                      | 2007           | 53                    | 1, 2, and 3         | 0.0%                      | NR                     | The number of therapy sessions was 2 in 17 patients, 3 in 31 patients, and 6 in 6 patients. This is a report of cryotherapy combined with proanthocyanidins. One patient relapsed after 1 month, and five patients relapsed after 3 mo. Only 3 treatments were performed. The clearance rate was 72.7% (16/22). The recurrence rate was 36.4% (8/22) during a 3-mo follow-up period. |
| Photodynamic therapy | Yang <sup>37s</sup><br>Yang <sup>32s</sup> | 2012<br>2019   | 5<br>16               | 1, 2, and 3<br>NR   | 0.0%<br>NR                | NR<br>NR               | Only 3 treatments were performed. The clearance rate was 93.8% (15/16). The recurrence rate was 6.3% (1/16) during a 3-mo follow-up period.  |
| Local hyperthermia   | Huo <sup>38s</sup>                         | 2014           | 2                     | 1 and 2             | 0.0%                      | NR                     |  |

NR indicates none reported.

by sealing vessels up to 1 mm in diameter with heat, and scar formation is less severe because laser therapy is a superficial treatment.<sup>21,22,41s</sup>

Reports on laser therapy are summarized in Table 1. The pregnant women were treated during all 3 trimesters, and the recurrence rate from treatment to delivery ranged from 0% to 22%.<sup>11,13,16,20–22,24,25</sup>

Ferenczy<sup>16</sup> reported that the recurrence rate was high in the first trimester (33%) and decreased in the second trimester (17%); no recurrence was observed in the third trimester. Widschwendter et al.<sup>25</sup> reported a similar trend.

Severe adverse effects of laser therapy were identified in 2 reports. Schwartz et al.<sup>20</sup> reported a case of preterm premature rupture of membranes (PROMs) 4 days after laser therapy was performed at 35 weeks of gestation. Whether this was related to the laser therapy is unclear. The child was delivered at 36 weeks of gestation and had no further complications. The authors reported that 2 of 32 pregnant women developed PROM. However, this occurred at 7 and 10 weeks after laser therapy and was not considered directly related to the laser therapy. The overall rate of PROM in their study was not significantly different from that in the control group. In addition, only one patient developed acute pyelonephritis within 24 hours after laser therapy. The infection promptly responded to antibiotic therapy.

Hankins et al.<sup>21</sup> reported a case of clinical chorioamnionitis with fever and uterine tenderness 8 hours after laser therapy at 36 weeks of gestation. A 2600-g male infant with an Apgar score of 8/8 was delivered by cesarean delivery. The infant had respiratory distress that required intubation. He was treated with antibiotic therapy and extubated 6 days after delivery. All maternal and infant cultures were negative. In addition, only one patient developed severe bleeding requiring direct compression and electrocautery for hemostasis.

No other severe adverse events were reported. In all reports, there was no clear evidence of spontaneous abortion, fetal malformation, or preterm delivery caused by laser therapy in pregnancy. Another study showed that the performance of laser therapy in pregnancy does not have identifiable adverse effects on the fetus.<sup>42s</sup>

A major advantage of laser therapy is that all lesions can be treated in one session.<sup>25</sup> In addition, laser therapy is particularly useful when the lesions are extensive.<sup>1</sup>

### Cryotherapy

Cryotherapy involves the use of liquid nitrogen to freeze and kill tissue affected by condyloma acuminata. The tissue sloughs and inflammation ensues; the inflammation then subsides as healing occurs.<sup>1</sup> In patients with condyloma acuminata, cryotherapy is used to freeze the entire lesion, including its base and 1 to 2 mm of surrounding normal tissue, for a maximum of 2 minutes. This treatment is repeated every 2 weeks and continues until the lesions have completely disappeared.<sup>26,27</sup>

Previous reports describing the use of cryotherapy are summarized in Table 1. The pregnant women were treated during all 3 trimesters. In 4 reports,<sup>26–28,30</sup> the number of treatments required until lesion disappearance was 1 or 2 for 120 (72%) of 166 patients and ≥3 for 46 (28%) of 166 patients. No lesions relapsed from the time of disappearance to the time of delivery.

The adverse effects of cryotherapy in these previous reports included pain, erythema, swelling, and exudation; however, all patients were able to continue treatment.<sup>26–30,31s,32s</sup> In addition, the rates of premature deliveries after cryotherapy were 7.1% (2/28) in a study by Bergman et al.<sup>28</sup> and 9.8% (5/51) in a study by Matsunaga et al.<sup>27</sup> However, these authors reported that cryotherapy was safe to administer because the rate of preterm delivery obtained in their studies was not different from the rate normally seen

at those hospitals, and at least 2 weeks had passed between cryotherapy and premature birth. Thus, the treatment complications and preterm birth were unrelated.<sup>27,28</sup>

An important advantage of cryotherapy, unlike surgical treatments such as laser therapy, is that anesthesia is unnecessary and outpatient treatment is possible. In addition, there is no risk to the fetus and no bleeding, necrosis, or infection at the treatment site.<sup>26,27</sup>

### Photodynamic Therapy

Photodynamic therapy with 5-aminolevulinic acid is a new treatment of condyloma acuminata, and research has shown that it is effective in nonpregnant women.<sup>43s-45s</sup> Yang et al.<sup>32s</sup> reported that in pregnancy, photodynamic therapy provided better clearance and a lower recurrence rate than did cryotherapy and could be used safely without severe adverse effects. However, the evidence of the effectiveness and safety of photodynamic therapy in pregnant women is inadequate and must be further evaluated.

### Trichloroacetic Acid

Trichloroacetic acid is corrosive to the skin and mucous membranes and destroys condyloma acuminata by chemical coagulation of cellular proteins, resulting in tissue necrosis. Trichloroacetic acid is safe for pregnant women because it is not absorbed by the skin or mucous membranes. However, few studies have examined the effectiveness of trichloroacetic acid in any population.<sup>1,39s</sup>

One study described administration of trichloroacetic acid in combination with laser therapy in pregnant women.<sup>20</sup> Although 97% of the pregnant women showed clearance, severe adverse effects attributable to this treatment combination included PROM (35 weeks of gestation) at 4 days after treatment in 1 of 32 women and acute pyelonephritis within 24 hours of treatment in 1 woman. However, whether these adverse effects were caused by trichloroacetic acid is unclear.<sup>20</sup>

Although trichloroacetic acid is widely used in clinical practice, little research has been done. Therefore, it should be administered with caution.<sup>4</sup>

### Local Hyperthermia

Local hyperthermia is a treatment that involves hot water, lasers, and lamps. It is often used for other types of HPV infection such as plantar warts and common warts.<sup>46s</sup>

Huo et al.<sup>38s</sup> reported only 2 cases in which local hyperthermia was used to treat condyloma acuminata in pregnancy. The patients' warts disappeared at 5 and 7 weeks, respectively, and there were no signs of recurrence during the 6-month follow-up period. The authors also reported that local hyperthermia could be used safely without any major complications.

### Surgical Excision and Electrosurgery

Surgical excision using a scalpel or scissors allows for direct removal of lesions, and electrosurgery involves the use of electrical energy to destroy lesions.<sup>1,39s</sup> In the present review, we identified no new reports on surgical excision or electrosurgery.

Duus et al.<sup>44s</sup> reported that the results of these surgical and laser treatments were comparable in terms of clearance, recurrence, and postoperative adverse effects (pain, healing time, and scar formation). However, some experts suggest that laser therapy is more effective for bleeding, pain, and scar formation.<sup>9,11,16,20,21</sup>

Important advantages of surgical excision and electrosurgery are that all lesions can be treated in one session and pathological evaluation is possible.<sup>39s</sup> These procedures may be considered in facilities where laser therapy is not possible or when pathological evaluation is needed.

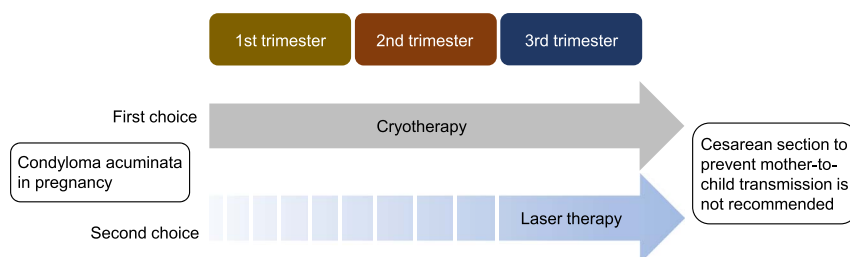
### Other Treatments

Interferon, 5-fluorouracil cream, and cidofovir have been used in the past for nonpregnant women, but these treatments are not currently recommended.<sup>1</sup> In addition, sinecatechin, podophyllin resin, and podophyllotoxin should not be used in pregnant women.<sup>4</sup>

## DISCUSSION

Many treatments for condyloma acuminata are currently available. However, there are no data to indicate which treatment is most effective.<sup>1,4</sup> Therefore, treatments are determined with consideration of the following factors: lesion size, lesion number (single or multiple), lesion extent (intensive or extensive), anatomical site (internal or external genitalia), patient preference, ease of treatment, adverse effects of drugs and surgery, and doctor's experience, among others.<sup>4,39s</sup> The number of gestational weeks at treatment is also important.<sup>47s</sup> In pregnant women with condyloma acuminata, the lesions generally tend to grow rapidly. This may be because of changes in hormone levels (e.g., elevated progesterone levels), increased vaginal discharge, a moist local environment, and reduced immune responsiveness.<sup>1,48s,49s</sup> In addition, clinicians must consider pregnancy complications such as preterm birth and PROM and their effects on the fetus.<sup>42s</sup> For these reasons, it is reasonable to consider the treatment for pregnant and nonpregnant women separately.

We reviewed reports describing treatment with laser therapy, cryotherapy, imiquimod, photodynamic therapy, trichloroacetic acid, and local hyperthermia. In our review, laser therapy, cryotherapy, and imiquimod had the most published data and were the treatments of interest. In particular, laser therapy and cryotherapy have been proven effective and safe. We believe that cryotherapy should be the first choice because of its simplicity and patient relief and that laser treatment should be the second choice.



**Figure 2.** Management of condyloma acuminata in pregnancy. We suggest that cryotherapy (first-choice treatment) and laser therapy (second-choice treatment) be considered before other treatments. In addition, we cautiously recommend reserving laser therapy until the third trimester. Performance of cesarean delivery to prevent mother-to-child transmission is not recommended.



Although the toxicity of imiquimod in pregnant women has not been fully evaluated, animal studies have shown no teratogenic or toxic effects.<sup>28</sup> The US Centers for Disease Control and Prevention does not recommend topical therapy with imiquimod in pregnancy.<sup>4</sup> However, its use in pregnancy is not prohibited, and the imiquimod cream package insert states that it should be used in pregnancy “only if clearly needed.” In fact, Suzuki et al.<sup>50s</sup> reported that approximately 35% of Japanese facilities use imiquimod cream for pregnant women with condyloma acuminata. We have only limited information on the use of imiquimod in pregnancy; therefore, it is not recommended for first-line treatment in pregnant women. However, the advantages of imiquimod include the elimination of frequent outpatient visits and the ability to treat extensive condyloma acuminata that is not easily treated by cryotherapy or laser therapy.<sup>36s</sup> Treatment with imiquimod can be considered after obtaining sufficient informed consent. Regarding photodynamic therapy, the number of reports is still small and the efficacy and safety are considered insufficient. The same is true for local hyperthermia. We found no reports describing the use of trichloroacetic acid as a single agent in pregnancy. However, many documents state that it can be safely used even in pregnancy because it is not absorbed by the systemic circulation.<sup>39s</sup> In addition, it is widely used in clinical practice. For this reason, despite the lack of published data, trichloroacetic acid may be considered depending on the experience of the clinician. We have summarized the management of condyloma acuminata in pregnancy in Figure 2.

No prospective studies to date have examined the gestational age at which treatment should be used to ensure therapeutic efficacy and safety. Therefore, there is no consensus on the optimal gestational age for treatment. Previous reports have suggested that the preservation of normal anatomy, hemostasis, and patient comfort be properly assessed to determine when to treat.<sup>21</sup> Ferenczy<sup>16</sup> and Widschwendter et al.<sup>25</sup> reported that an earlier gestational age at the time of laser therapy was associated with a higher recurrence rate in pregnancy. Therefore, Ferenczy<sup>16</sup> proposed reserving laser therapy until the third trimester to minimize recurrence. Exactly why the recurrence rate gradually decreases in parallel with the increase in gestational age is unknown. However, the recurrence in pregnancy is generally thought to be associated with a relative decrease in cell-mediated immunity and maternal immunocompetence. Immune dysfunction in pregnancy may be associated with this process. These cell systems are involved in the cytotoxic immune response and are thought to be related to changes in estrogen and chorionic gonadotropin. These hormones are elevated in the first and second trimesters and have been shown to decrease the activity of natural killer cells and suppressor T cells. Thus, patients may be prone to relapse because of immune dysfunction.<sup>16</sup>

The first trimester is important for organogenesis, and therapy in this period may increase the risk of spontaneous abortion. Therapy in the third trimester may also increase the risk of preterm delivery.<sup>42s,47s</sup> Laser therapy is recommended for the second or early third trimester to avoid spontaneous abortion or preterm delivery, and the European Society for Laser Dermatology has also limited laser therapy to the third trimester once the fetus is fully developed.<sup>42s,51s</sup> However, none of the reports showed an increase in the prevalence of maternal or neonatal adverse effects with any treatment in the first, second, or third trimester. In addition, it seems that treatment is performed in any trimester in clinical practice.

A notable problem with condyloma acuminata in pregnant women is that the mother-to-child transmission of HPV may cause JORRP in the offspring. Mother-to-child transmission of HPV was first reported in a patient with JORRP in 1956.<sup>52s</sup> Since then, various mother-to-child transmission modes have been described in several studies; however, the exact routes remain unknown.<sup>53s</sup>

The main routes that have been described to date are vertical transmission (periconceptual, prenatal, and perinatal transmission) and horizontal transmission.<sup>54s–56s</sup> These transmission routes can cause mother-to-child transmission in complex networks.<sup>57s</sup> Although there is no proof that treatment reduces the risk of mother-to-child transmission, experts agree that condyloma acuminata should be treated to reduce the HPV load in pregnant women.<sup>25,42s</sup>

The effectiveness of cesarean delivery in preventing the development of JORRP and mother-to-child transmission of HPV is uncertain. Human papillomavirus transmission also occurs in cesarean delivery, and prophylactic cesarean delivery has only a very limited cost-benefit ratio. Therefore, cesarean delivery is not recommended to prevent JORRP or mother-to-child transmission of HPV.<sup>1,54s,58s</sup> The Centers for Disease Control and Prevention also concluded that there is no clear consensus on cesarean delivery as a prevention of mother-to-child transmission. However, cesarean delivery should be considered if the pelvic outlet is obstructed or if vaginal delivery would result in excessive bleeding.<sup>4</sup>

Few reports have addressed the management of condyloma acuminata in pregnancy. Therefore, there are still many unclear points regarding the management of condyloma acuminata in pregnancy, and further research is needed. We hope that our review will help doctors to deal with condyloma acuminata in pregnancy.

## REFERENCES

1. Wiley DJ, Douglas J, Beutner K, et al. External genital warts: Diagnosis, treatment, and prevention. *Clin Infect Dis* 2002; 35:S210–S224.
2. Cates W Jr. Estimates of the incidence and prevalence of sexually transmitted diseases in the United States. American Social Health Association Panel. *Sex Transm Dis* 1999; 26(4 Suppl):S2–S7.
3. Dinh TH, Sternberg M, Dunne EF, et al. Genital warts among 18- to 59-year-olds in the United States, national health and nutrition examination survey, 1999–2004. *Sex Transm Dis* 2008; 35:357–360.
4. Workowski KA, Bolan GA, Centers for Disease Control and Prevention. Sexually transmitted diseases treatment guidelines, 2015. *MMWR Recomm Rep* 2015; 64(RR-03):1–137.
5. Derkay CS, Wiatrak B. Recurrent respiratory papillomatosis: A review. *Laryngoscope* 2008; 118:1236–1247.
6. Reeves WC, Ruparella SS, Swanson KI, et al. National registry for juvenile-onset recurrent respiratory papillomatosis. *Arch Otolaryngol Head Neck Surg* 2003; 129:976–982.
7. Shah KV, Stern WF, Shah FK, et al. Risk factors for juvenile onset recurrent respiratory papillomatosis. *Pediatr Infect Dis J* 1998; 17:372–376.
8. Silverberg MJ, Thorsen P, Lindeberg H, et al. Condyloma in pregnancy is strongly predictive of juvenile-onset recurrent respiratory papillomatosis. *Obstet Gynecol* 2003; 101:645–652.
9. Baggish MS. Carbon dioxide laser treatment for condylomata acuminata venereal infections. *Obstet Gynecol* 1980; 55:711–715.
10. Hahn GA. Carbon dioxide laser surgery in treatment of condyloma. *Am J Obstet Gynecol* 1981; 141:1000–1008.
11. Malfetano JH, Marin AC, Malfetano JH Jr. Laser treatment of condylomata acuminata in pregnancy. *J Reprod Med* 1981; 26:574–576.
12. Calkins JW, Masterson BJ, Magrina JF, et al. Management of condylomata acuminata with the carbon dioxide laser. *Obstet Gynecol* 1982; 59:105–108.
13. Ferenczy A. Using the laser to treat vulvar condylomata acuminata and intraepidermal neoplasia. *Can Med Assoc J* 1983; 128:135–137.
14. Kryger-Baggesen N, Falck Larsen J, Hjortkjaer Pedersen P. CO<sub>2</sub>-laser treatment of condylomata acuminata. *Acta Obstet Gynecol Scand* 1984; 63:341–343.
15. Grundsell H, Larsson G, Bekassy Z. Treatment of condylomata acuminata with the carbon dioxide laser. *Br J Obstet Gynaecol* 1984; 91:193–196.
16. Ferenczy A. Treating genital condyloma during pregnancy with the carbon dioxide laser. *Am J Obstet Gynecol* 1984; 148:9–12.
17. Scott RS, Castro DJ. Treatment of condyloma acuminata with carbon dioxide laser: A prospective study. *Lasers Surg Med* 1984; 4:157–162.

18. Rotteleur G, Riboulet JL, Vanlerberghe K, et al. Management of vulvar condylomata acuminata with argon laser. *Lasers Surg Med* 1986; 6: 119–122.
19. Caglar H, Erk M, Hreshchyshyn MM. Carbon dioxide laser surgery of female genital, perineal, and anal condyloma acuminata. *N Y State J Med* 1987; 87:365–366.
20. Schwartz DB, Greenberg MD, Daoud Y, et al. Genital condylomas in pregnancy: Use of trichloroacetic acid and laser therapy. *Am J Obstet Gynecol* 1988; 158:1407–1416.
21. Hankins GD, Hammond TL, Snyder RR, et al. Use of laser vaporization for management of extensive genital tract condyloma acuminata during pregnancy. *J Infect Dis* 1989; 159:1001–1002.
22. Adelson MD, Semo R, Baggish MS, et al. Laser vaporization of genital condylomata in pregnancy. *J Gynecol Surg* 1990; 6:257–262.
23. Chaisilwattana P, Bhiraueus P. Carbon dioxide laser vaporization for genital wart. *J Med Assoc Thai* 1996; 79:749–754.
24. Arena S, Marconi M, Frega A, et al. Pregnancy and condyloma. Evaluation about therapeutic effectiveness of laser CO<sub>2</sub> on 115 pregnant women. *Minerva Ginecol* 2001; 53:389–396.
25. Widschwendter A, Böttcher B, Riedl D, et al. Recurrence of genitals warts in pre-HPV vaccine era after laser treatment. *Arch Gynecol Obstet* 2019; 300:661–668.
26. Bergman A, Bhatia NN, Broen EM. Cryotherapy for treatment of genital condylomata during pregnancy. *J Reprod Med* 1984; 29:432–435.
27. Matsunaga J, Bergman A, Bhatia NN. Genital condylomata acuminata in pregnancy: Effectiveness, safety and pregnancy outcome following cryotherapy. *Br J Obstet Gynaecol* 1987; 94:168–172.
28. Bergman A, Matsunaga J, Bhatia NN. Cervical cryotherapy for condylomata acuminata during pregnancy. *Obstet Gynecol* 1987; 69:47–50.
29. Matányi S. Cryotherapy during pregnancy. *Acta Chir Hung* 1989; 30:325–331.
30. Odeibat H, Obaidat N, Awamleh A, et al. Cryotherapy for the management of genital warts in pregnancy: A five-year observational study. *JRMS* 2007; 14:26–30.

For further references, please see “Supplemental References,” <http://links.lww.com/OLQ/A573>.