

# Vedolizumab-Induced De Novo Extraintestinal Manifestations

Liege I. Diaz, MD, Tara Keihanian, MD, Ingrid Schwartz, MD, Su Bin Kim, MD, Fernando Calmet, MD, Maria Alejandra Quintero, MPH, and Maria T. Abreu, MD

Dr Diaz is an advanced gastroenterology fellow in the Department of Gastrointestinal Oncology at the Moffitt Cancer Center in Tampa, Florida. Dr Keihanian is a gastroenterology fellow in the Department of Internal Medicine in the Division of Gastroenterology at the University of Miami Miller School of Medicine in Miami, Florida. Dr Schwartz is an internal medicine resident in the Department of Internal Medicine at the University of Miami Miller School of Medicine. Dr Kim is a gastroenterology professor in the Department of Internal Medicine in the Division of Gastroenterology at the Cleveland Clinic in Weston, Florida. Dr Calmet is a gastroenterologist in the Department of Internal Medicine in the Division of Gastroenterology at Newton-Wellesley Hospital in Boston, Massachusetts. Ms Quintero is a research program manager at the Crohn's & Colitis Center in Miami, Florida. Dr Abreu is director of the Crohn's & Colitis Center and professor of medicine and of microbiology and immunology in the Department of Internal Medicine in the Division of Gastroenterology at the University of Miami Miller School of Medicine.

Address correspondence to:

Dr Maria T. Abreu

1475 NW 12th Avenue

Miami, FL 33136

Tel: 305-243-8644

Fax: 305-243-6125

E-mail: Mabreu1@med.miami.edu

## Keywords

Vedolizumab, extraintestinal manifestations, perianal disease, arthralgia, inflammatory bowel disease

**Abstract: Background:** Vedolizumab is an  $\alpha 4\beta 7$  integrin antagonist with gut-specific effects on lymphocyte and monocyte trafficking. Although the treatment is beneficial for inflammatory bowel disease (IBD), the effects of vedolizumab on extraintestinal manifestations (EIMs) have not been well described. The gut-specific effects of the medication may have diverse outcomes on EIMs. We hypothesize that EIMs may be unmasked by systemic availability of gut-homing effector cells. **Aim:** The goal of this study is to describe de novo EIMs of IBD patients who were started on vedolizumab. **Methods:** A retrospective chart review of 71 patients from January 2011 to October 2017, including clinical and medication history and colonoscopy results, was performed. **Results:** EIMs occurred in 26.7% of patients who were started on vedolizumab. The most common EIMs were arthralgias, perianal fistula, and pyoderma gangrenosum. There was a trend toward a greater occurrence of EIMs in patients with Crohn's disease compared to ulcerative colitis. **Conclusion:** Our retrospective study suggests that inhibition of gut-specific effector cells results in activated lymphocytes and/or monocytes that cause inflammation in other tissues. More studies are needed to confirm these observations and to develop biomarkers that predict patients at risk for EIMs and perianal fistulas while on vedolizumab.

Different classes of drugs have been developed to induce and maintain remission in inflammatory bowel disease (IBD), yet many patients continue to experience chronic symptoms and long-term structural damage of the bowel. The development of anti-tumor necrosis factor (TNF) antibodies to treat both ulcerative colitis and Crohn's disease was an advance in the field.

Anti-TNF drugs such as infliximab, adalimumab, and certolizumab pegol (Cimzia, UCB) have been used as monotherapy or combination therapy with immunomodulators to induce and maintain remission of ulcerative colitis and Crohn's disease.<sup>1</sup> However, studies report a 20% to 40% rate of primary nonresponse to anti-TNF therapy and a late loss of response in up to 40% of patients.<sup>2-4</sup> In addition to loss of response, there are concerns regarding the potential toxicity of anti-TNF therapy, particularly serious infections and an increased risk of non-Hodgkin lymphoma, especially when combined with thiopurines.<sup>1,5-8</sup>

Understanding the pathogenetic mechanisms underlying IBD can improve therapies. Identifying how immune cells flux to the intestine is the basis of a burgeoning area of biologics and small molecules. The first in this class of medications to be used for IBD was natalizumab (Tysabri, Biogen), an  $\alpha 4$  integrin antagonist antibody that targets both  $\alpha 4\beta 7$  and  $\alpha 4\beta 1$  subunits in a high percentage of peripheral blood T cells homing to the gut, secondary lymphoid organs such as the spleen and lymph nodes, and the central nervous system.<sup>9,10</sup> Natalizumab remains an effective treatment for multiple sclerosis and Crohn's disease, but it increases the risk of an often fatal brain infection with John Cunningham virus known as progressive multifocal leukoencephalopathy.<sup>11,12</sup> Therefore, its use in IBD is rare.

Vedolizumab (Entyvio, Takeda) is a more gut-selective monoclonal antibody that binds the  $\alpha 4\beta 7$  integrin found in T cells, B cells, and monocytes and inhibits the interaction with mucosal addressin-cell adhesion molecule (MAdCAM) 1 present in the vascular endothelium of the intestine, thereby preventing the recruitment of lymphocytes into the gut.<sup>10,13-15</sup> MAdCAM-1 expression is also present in the hepatic sinusoidal endothelium and portal vein in the setting of autoimmune-mediated inflammation.<sup>16</sup> Vedolizumab has been shown to be effective in moderately to severely active ulcerative colitis and Crohn's disease for both induction and maintenance of remission. An important appeal of vedolizumab is its safety profile. To date, no cases of progressive multifocal leukoencephalopathy in patients treated with vedolizumab have been reported. In general, the drug is viewed as a safe biologic with minimal increased risk of infections and no increased risk of malignancies.<sup>2,14,17,18</sup>

Extraintestinal manifestations (EIMs) are thought to affect approximately 50% of patients with IBD, although this percentage depends on the definition of EIM being used.<sup>19</sup> Proposed theories include antigen leak from the gastrointestinal tract, and shared epitopes between gut bacteria and other target tissues such as joints and skin. Most commonly, EIMs are musculoskeletal and dermatologic, although ocular, hepatobiliary, hematologic, and renal involvement are also recognized.<sup>20</sup> EIMs affecting the musculoskeletal system are further classified into type 1 (pauciarticular, involving large joints) and type 2 (polyarticular, symmetrically involving small joints). The skin is usually involved in the form of erythema nodosum and pyoderma gangrenosum. Ocular EIMs include episcleritis and anterior uveitis.<sup>19,21</sup> Luminal activity typically correlates with type 1 musculoskeletal disease, erythema nodosum, and episcleritis, whereas type 2 does not correlate with luminal inflammation. The relationship between luminal activity and pyoderma gangrenosum is controversial, and uveitis and primary

sclerosing cholangitis have varying association with disease activity.<sup>19-21</sup>

Although vedolizumab has been proven to be successful in treating moderate to severe IBD,<sup>17,18</sup> its effects on EIMs remain incompletely characterized. Several studies have suggested a risk of developing skin and articular manifestations after starting vedolizumab.<sup>22-26</sup> The goal of this retrospective review is to determine the incidence of de novo EIMs in patients who were started on vedolizumab.

## Methods

We designed a retrospective cross-sectional study of patients with IBD who were 18 years or older and who were followed at the Crohn's & Colitis Center of the University of Miami. The study was approved by the University of Miami Miller School of Medicine Institutional Review Board. Patients were included if their electronic medical record showed a diagnosis of Crohn's disease and/or ulcerative colitis according to the International Classification of Diseases, 9th Revision, Clinical Modification. Patients who were not on vedolizumab were excluded.

Data of patients whose index date of care in our health care system was between January 2011 and October 2017 were extracted from a database. Further collected data included clinical history, medication history, history of EIMs, colonoscopy results, pathology reports, and de novo EIMs (eg, pyoderma gangrenosum, peripheral arthralgia or arthritis, axial arthropathies, erythema nodosum, worsening primary sclerosing cholangitis, uveitis). From patients who developed de novo EIMs, we also collected data on the time since vedolizumab was started, prior treatment, inflammatory markers, whether or not medication was discontinued, and resolution of symptoms. A total of 71 patients on vedolizumab were identified. Table 1 lists patients' baseline characteristics.

Data analysis was performed with R, version 3.5.0. Nonnormal continuous data were compared with the Wilcoxon signed-rank test, whereas proportions were compared with the chi-squared test or Fisher test as indicated. Multivariate logistic regression was then performed to identify potential risk factors for the development of EIMs. Survival data were compared using log-rank testing and were plotted on Kaplan-Meier curves.

## Results

We identified 71 patients who initiated vedolizumab at our center; 31 had ulcerative colitis and 40 had Crohn's disease. Approximately 53% were women, and the median age was 43 years (interquartile range, 28.5-59.5).

**Table 1.** Baseline Characteristics

Characteristic	All, N=71	Crohn's Disease, n=40	Ulcerative Colitis, n=31	P value <sup>a</sup>
Age, years	43; IQR, 28.5-59.5	42; IQR, 29.8-56.3	45; IQR, 27.5-64.5	.2555
Female sex	38 (53.5%)	21 (52.5%)	17 (54.8%)	1.00
Developed new EIM(s)	19 (26.7%)	14 (35.0%)	5 (16.1%)	.131
Clinical remission	38 (53.5%)	17 (42.5%)	21 (67.7%)	.061
Endoscopic remission	22 (31.0%)	11 (27.5%)	11 (35.5%)	.644
Prior surgery	37 (52.1%)	34 (85.0%)	3 (9.7%)	<.0001
Prior EIM(s)	30 (42.3%)	21 (52.5%)	9 (29.0%)	.081
<i>Prior Therapies</i>				
5-ASA	29 (40.9%)	14 (35.0%)	15 (48.3%)	.3709
Corticosteroids	5 (7.0%)	4 (10.0%)	1 (3.2%)	.3779
Immunomodulators	43 (60.6%)	24 (60.0%)	19 (61.3%)	1.00
Cyclosporine	1 (1.4%)	1 (2.5%)	0 (0.0%)	1.00
Anti-TNF agents	63 (88.7%)	35 (87.5%)	28 (90.3%)	1.00
Ustekinumab	4 (5.6%)	4 (10.0%)	0 (0.0%)	.1264
Anti-integrins	3 (4.2%)	2 (5.0%)	1 (3.2%)	1.00

5-ASA, 5-aminosalicylic acid; EIM, extraintestinal manifestation; IQR, interquartile range; TNF, tumor necrosis factor.

<sup>a</sup>Wilcoxon signed-rank test used for comparison of nonnormal continuous data. The chi-squared or Fisher test was used for comparison of proportions.

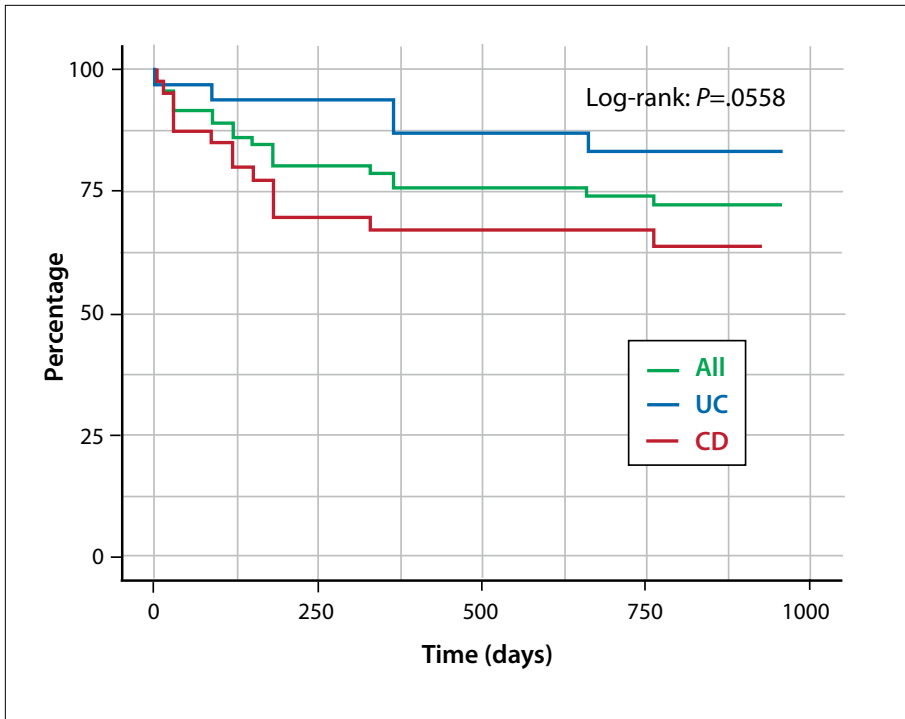
**Table 2.** Risk Factors for Developing New EIMs in Patients With Inflammatory Bowel Disease With No Prior EIMs

Characteristic	EIMs, n=8	No EIMs, n=33	P value
Age, years	32; IQR, 29.8-46.8	43; IQR, 28-64	.374
Female sex	5 (62.5%)	17 (51.5%)	.7033
Clinical remission	3 (37.5%)	22 (66.7%)	.2252
Endoscopic remission	1 (12.5%)	13 (39.4%)	.2267
Prior surgery	6 (75.0%)	11 (33.3%)	.0486
<i>Prior Therapies</i>			
5-ASA	4 (50.0%)	16 (48.5%)	1.0
Corticosteroids	1 (12.5%)	2 (6.1%)	.4882
Immunomodulators	3 (37.5%)	21 (63.6%)	.2412
Cyclosporine	0 (0.0%)	0 (0.0%)	N/A
Anti-TNF agents	7 (87.5%)	30 (90.9%)	1.0
Ustekinumab	1 (12.5%)	1 (3.0%)	.3561
Anti-integrins	0 (0.0%)	1 (3.0%)	1.0

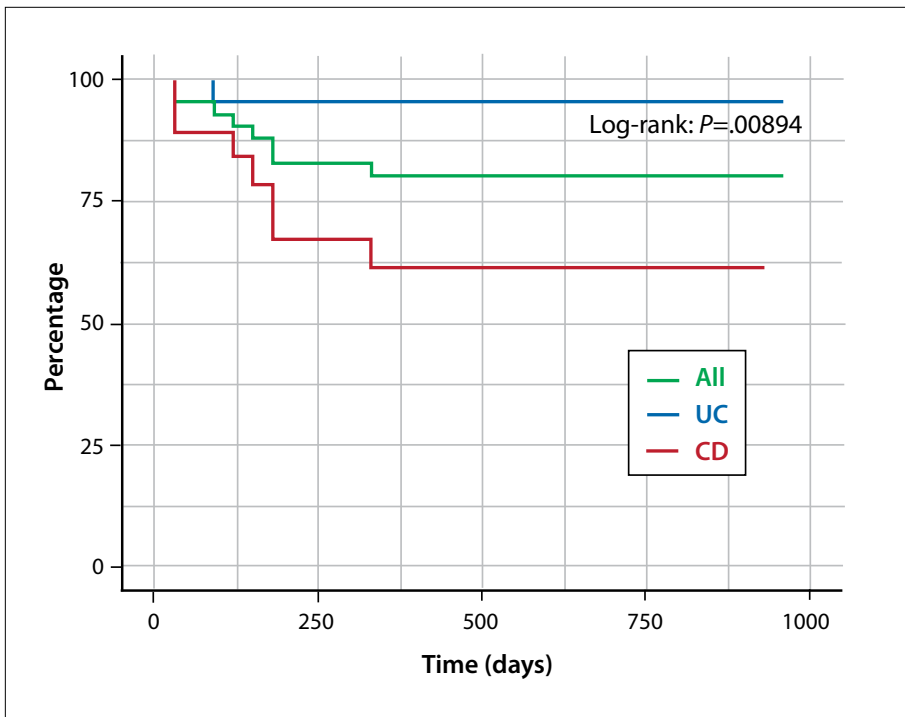
5-ASA, 5-aminosalicylic acid; EIM, extraintestinal manifestation; IQR, interquartile range; N/A, not applicable; TNF, tumor necrosis factor.

Approximately 53% (38/71) of patients had clinical remission. De novo EIMs occurred in 26.7% (19/71) of patients who were started on vedolizumab after a median of 3.75 months (interquartile range, 1.38-5.75). The most common EIMs were arthralgias (n=8), perianal

fistula (n=7), pyoderma gangrenosum (n=2), erythema nodosum (n=1), enterocutaneous fistula (n=1), rectovaginal fistula (n=1), spondylitis (n=1), and uveitis (n=1). In the subgroup of patients with no prior EIMs (Table 2), new EIMs developed in 19.5% (8/41).



**Figure 1.** EIM-free survival according to the type of inflammatory bowel disease. CD, Crohn’s disease; EIM, extraintestinal manifestation; UC, ulcerative colitis.



**Figure 2.** EIM-free survival according to the type of inflammatory bowel disease in the subgroup of patients with no prior EIMs. CD, Crohn’s disease; EIM, extraintestinal manifestation; UC, ulcerative colitis.

There was a trend toward a greater occurrence of EIMs in patients with Crohn’s disease compared to patients with ulcerative colitis (35.0% and 16.1%, respectively; log-rank  $P=.0558$ ; Figure 1). In patients

with Crohn’s disease, those who developed EIMs were younger than those without EIMs (median age, 29.5 vs 47.5 years, respectively;  $P=.0141$ ). Conversely, in patients with ulcerative colitis, there was no statistically significant

age difference among those with or without new EIMs after initiating therapy (median age, 44.0 vs 47.5 years, respectively;  $P=.609$ ). Development of new EIMs was not associated with a history of prior EIMs ( $P=.1798$ ), clinical remission ( $P=.7192$ ), or endoscopic remission ( $P=.387$ ). In the subgroup of patients with no prior EIMs, we found that patients with Crohn's disease were more likely to develop de novo EIMs when started on vedolizumab compared to patients with ulcerative colitis (36.8% vs 4.5%;  $P=.00894$ ; Figure 2). This finding remained significant on multivariate logistic regression analysis ( $P=.0264$ ). In this subgroup, there was also an association with prior surgeries, although this association disappeared when adjusting for type of IBD ( $P=.6499$ ).

Forty-six patients (64%) underwent colonoscopy after starting vedolizumab. Interestingly, there was a trend toward a greater development of EIMs in patients not achieving endoscopic remission, although this did not reach statistical significance (53% vs 20%;  $P=.0839$ ). This was driven by a decreased development of perianal fistulas in patients with Crohn's disease achieving mucosal healing (0% vs 38%;  $P=.0457$ ).

Regarding arthralgias, 8 patients with new-onset or worsening arthralgia while on vedolizumab were previously treated with adalimumab, azathioprine or 6-mercaptopurine, golimumab (Simponi, Janssen), infliximab, and mesalamines. One patient had an extensive rheumatologic evaluation and was deemed to have fibromyalgia as opposed to inflammatory arthritis. Two patients initially had new-onset arthralgia after the first few infusions; however, with treatment continuation, joint pain resolved and their symptoms appeared to be controlled on vedolizumab. In the 5 remaining patients, joint pain resolved with vedolizumab discontinuation and also with initiating other biologic therapies (tofacitinib [Xeljanz, Pfizer] and infliximab).

## Discussion

Vedolizumab is safe and effective for induction of remission, maintenance of response, and long-term mucosal healing in patients with moderately to severely active Crohn's disease and/or ulcerative colitis.<sup>26,27</sup> Vedolizumab is a humanized, monoclonal immunoglobulin G1 antibody that binds to and blocks the interaction of the  $\alpha 4\beta 7$  integrin with MAdCAM-1 and inhibits the migration of memory T lymphocytes across the endothelium into inflamed gastrointestinal parenchymal tissue. MAdCAM-1 is largely expressed on the endothelium of the gastrointestinal blood vessels, although some expression is also present in the kidneys. Its efficacy in the management of fistulizing Crohn's disease and in achieving faster fistula closure has also been reported in a post-hoc study

(vedolizumab vs placebo, 31% vs 11%; absolute risk reduction, 19.7%; 95% CI, -8.9 to 46.2).<sup>28</sup> It is thought that because of its unique gut-specific activity, vedolizumab has the potential to reduce systemic side effects.<sup>29</sup>

A wide range of EIMs can occur in patients with Crohn's disease and ulcerative colitis. The pathogenesis of an EIM in IBD is not completely clear. Although some EIMs correlate directly with luminal disease activity, others have an independent course, which makes treatment of IBD even more challenging. The reported prevalence of EIMs is 15% to 20% in ulcerative colitis and 20% to 40% in Crohn's disease, and is even higher in Crohn's colitis.<sup>25</sup> Systemic therapies such as corticosteroids and anti-TNF antibodies can be effective for many of the inflammatory EIMs. It may be expected that transitioning from an anti-TNF agent to an anti-integrin can reveal a previously treated EIM of immune-mediated disease. In this study, we have included perianal fistulas as an extraluminal complication of IBD. Seven of 71 patients (9.8%) without history of a fistula developed new fistulas while on vedolizumab.

## Literature Review

We performed a literature review of EIMs and the effect of vedolizumab in IBD patients. Although some studies showed vedolizumab to be effective in the treatment of EIMs, others reported the drug as the cause of such EIMs. Fleisher and colleagues reported that vedolizumab was effective for the treatment of pyoderma gangrenosum in ulcerative colitis and for the treatment of uveitis, erythema nodosum, polyarticular arthropathy, and ankylosing spondylitis or sacroiliitis in both ulcerative colitis and Crohn's disease.<sup>16</sup> Similar results were reported in a study by Feagan and colleagues.<sup>30</sup> In this study, patients with IBD who were treated with vedolizumab were 32% more likely to achieve sustained resolution of arthritis or arthralgia vs placebo, and 21% less likely to have a worsening or new occurrence of arthritis or arthralgia.<sup>30</sup> In another study, conducted by Orlando and colleagues, 36 patients were induced with vedolizumab and followed for a median of  $2.6 \pm 1.6$  months.<sup>31</sup> Vedolizumab did not cause new cases or flare existing arthritis and/or sacroiliitis. Fourteen cases of IBD patients with active sacroiliitis showed clinical improvement after treatment with vedolizumab.<sup>31</sup> The VICTORY Consortium, a cohort of 7 medical centers, retrospectively analyzed the safety of vedolizumab in 212 patients with Crohn's disease. Serious adverse events and serious infections occurred at a rate of 10 and 13 per 100 patient years (PYs) of follow-up, respectively. Arthralgia was seen in 5 patients, and 1 patient developed autoimmune hepatitis.<sup>32</sup>

In another study from the VICTORY Consortium, the safety of vedolizumab was analyzed in 321 patients

with ulcerative colitis.<sup>33</sup> At 12 months, serious adverse events and serious infections were reported in 6% and 4% of patients, respectively; however, no new or worsening EIMs were reported. Six patients had diffuse myalgias and influenza-like symptoms, and 4 of these patients required discontinuation of therapy.<sup>33</sup> Colombel and colleagues performed a safety data analysis of 6 trials of vedolizumab that included a total of 2830 patients from May 2007 to June 2013.<sup>21</sup> Adverse events were evaluated in patients who received at least 1 dose of vedolizumab or placebo and were reported as exposure-adjusted incidence rates as the number of patients experiencing the event per 100 PYs of exposure. The researchers found 11.2 vedolizumab-exposed patients experienced an arthralgia per 100 PYs of follow-up compared with 19.3 patients receiving placebo.<sup>21</sup>

In contrast, Meserve and colleagues performed a retrospective analysis of data from a multicenter consortium database from May 2014 through June 2017.<sup>34</sup> The analysis included 1087 patients, and the most common noninfectious adverse events reported were arthralgias (n=31, 2.9%; 3.60/100 PYs of exposure). Nearly all of these patients developed arthralgias during vedolizumab induction therapy and achieved resolution over time; however, 4 patients required discontinuation of therapy (0.36%; 0.47/100 PYs of exposure) and 1 patient developed arthralgias after escalation to every 4 weeks of vedolizumab maintenance.<sup>34</sup> In another study, vedolizumab was demonstrated to lead to a flare of arthritis and/or sacroiliitis in 5 patients with IBD.<sup>22</sup> Tadbiri and colleagues reported 49 vedolizumab-treated patients with arthralgia or arthritis and cutaneous lesions; complete remission of inflammatory arthralgia or arthritis was associated with a clinical remission of IBD (odds ratio, 1.89; 95% CI, 1.05-3.41;  $P=.03$ ).<sup>24</sup> However, 34 (13.8%) patients without any EIM at baseline had evidence of inflammatory arthralgia as peripheral arthralgia during the follow-up period.<sup>24</sup> Adverse skin manifestation was seen in 14 (4.8%) cases.<sup>24</sup> Dubinsky and colleagues studied the prevalence and incidence of EIMs in patients with IBD who were treated with vedolizumab vs anti-TNF agents.<sup>23</sup> Patients with Crohn's disease in the vedolizumab arm were 28% more likely to develop erythema nodosum, aphthous stomatitis, episcleritis or scleritis, arthropathy, primary sclerosing cholangitis, and uveitis or iritis (adjusted internal rate of return, 1.28; 95% CI, 1.02-1.62). Patients with ulcerative colitis receiving vedolizumab were more likely to develop aphthous stomatitis, pyoderma gangrenosum, and primary sclerosing cholangitis compared to patients who were treated with anti-TNF agents.<sup>23</sup>

Our study showed that vedolizumab induces de novo EIMs in patients with IBD. Among the 71 patients who were treated with vedolizumab and followed up for a

median of 3.75 months, the most common EIMs were arthralgias (n=8), perianal fistula (n=7), and pyoderma gangrenosum (n=2). There was 1 report each of erythema nodosum, enterocutaneous fistula, rectovaginal fistula, spondylitis, and uveitis. Not all patients with arthralgias or arthritis are sent for rheumatologic evaluation, as this is a common occurrence in patients with IBD. In our study, we distinguished patients who had complaints prior to starting biologic therapy from patients who developed de novo symptoms while on vedolizumab. It is important to note that due to vedolizumab's intestinal specificity, some patients with a predisposition to extraintestinal inflammation may have this susceptibility unmasked.

In terms of axial EIM, it was demonstrated that innate lymphoid cells were expanded in the gut, synovial fluid, and bone marrow of patients with ankylosing spondylitis with overexpression of the  $\alpha 4\beta 7$  integrin, which supports the hypothesis of a beneficial effect of an  $\alpha 4\beta 7$  blockade of vedolizumab in treating articular manifestations in IBD patients.<sup>35</sup> However, it is unclear by which pathophysiologic mechanism vedolizumab induces axial EIMs in IBD patients.

## Conclusion

The underlying mechanism by which vedolizumab helps or induces EIMs is not completely understood. Integrins and adhesion molecules may play a role in the interception of recirculating activated lymphocytes away from the gut. As a result, activated cells could use alternative homing receptors to enter other tissues, such as skin, eyes, and joints. The overall survival of cells is not affected. The gut-selective inflammatory control of vedolizumab may potentially limit its clinical effect on EIM prevention or may lead to inflammation in other sites. The findings of this study highlight the need for large randomized, controlled trials to collect data on EIMs, including their severity, in order to properly assess whether new drugs have a beneficial or exacerbating role in the management of EIMs. Attention should be paid when using vedolizumab for treatment of IBD patients with previous EIMs.

*Dr Abreu has received grant/research support from Prometheus Laboratories, Takeda, Eli Lilly Pharmaceuticals, and Pfizer. She has served as a consultant for AbbVie Laboratories, Prometheus Laboratories, Takeda, Janssen Pharmaceuticals, Focus Medical Communications, Celgene Corporation, Eli Lilly Pharmaceuticals, Pfizer, Shire Pharmaceuticals, Roche Pharmaceuticals, Boehringer Ingelheim Pharmaceuticals, Amgen, Gilead, and Allergan. She has also served on the speakers bureau for Takeda and Focus Medical Communications. The other authors have no relevant conflicts of interest to disclose.*

## References

- Dassopoulos T, Sultan S, Falck-Ytter YT, Inadomi JM, Hanauer SB. American Gastroenterological Association Institute technical review on the use of thiopurines, methotrexate, and anti-TNF- $\alpha$  biologic drugs for the induction and maintenance of remission in inflammatory Crohn's disease. *Gastroenterology*. 2013;145(6):1464-1478.e1-e5.
- Armuzzi A, Gionchetti P, Daperno M, et al; GIVI (Gruppo Italiano su Vedolizumab nelle IBD) Group. Corrigendum to "Expert consensus paper on the use of vedolizumab for the management of patients with moderate-to-severe inflammatory bowel disease." *Dig Liver Dis*. 2016;48(9):1103.
- Ford AC, Sandborn WJ, Khan KJ, Hanauer SB, Talley NJ, Moayyedi P. Efficacy of biological therapies in inflammatory bowel disease: systematic review and meta-analysis. *Am J Gastroenterol*. 2011;106(4):644-659.
- Ben-Horin S, Chowers Y. Review article: loss of response to anti-TNF treatments in Crohn's disease. *Aliment Pharmacol Ther*. 2011;33(9):987-995.
- Kirchgesner J, Lemaire M, Carrat F, Zureik M, Carbonnel F, Dray-Spira R. Risk of serious and opportunistic infections associated with treatment of inflammatory bowel diseases. *Gastroenterology*. 2018;155(2):337-346.e10.
- Bonovas S, Fiorino G, Allocca M, et al. Biologic therapies and risk of infection and malignancy in patients with inflammatory bowel disease: a systematic review and network meta-analysis. *Clin Gastroenterol Hepatol*. 2016;14(10):1385-1397.e10.
- Beaugerie L, Brousse N, Bouvier AM, et al; CESAME Study Group. Lymphoproliferative disorders in patients receiving thiopurines for inflammatory bowel disease: a prospective observational cohort study. *Lancet*. 2009;374(9701):1617-1625.
- Herrinton LJ, Liu L, Weng X, Lewis JD, Hutfless S, Allison JE. Role of thiopurine and anti-TNF therapy in lymphoma in inflammatory bowel disease. *Am J Gastroenterol*. 2011;106(12):2146-2153.
- Zundler S, Neurath MF. Novel insights into the mechanisms of gut homing and antiadhesion therapies in inflammatory bowel diseases. *Inflamm Bowel Dis*. 2017;23(4):617-627.
- Grant AJ, Lalor PF, Hübscher SG, Briskin M, Adams DH. MAdCAM-1 expressed in chronic inflammatory liver disease supports mucosal lymphocyte adhesion to hepatic endothelium (MAdCAM-1 in chronic inflammatory liver disease). *Hepatology*. 2001;33(5):1065-1072.
- Danese S, Panés J. Development of drugs to target interactions between leukocytes and endothelial cells and treatment algorithms for inflammatory bowel diseases. *Gastroenterology*. 2014;147(5):981-989.
- Lau MS, Tsai HH, Ryschkevitich C, et al. Review of vedolizumab for the treatment of ulcerative colitis. *World J Gastrointest Pharmacol Ther*. 2016;7(1):107-111.
- Cherry LN, Yunker NS, Lambert ER, Vaughan D, Lowe DK. Vedolizumab: an  $\alpha 4\beta 7$  integrin antagonist for ulcerative colitis and Crohn's disease. *Ther Adv Chronic Dis*. 2015;6(5):224-233.
- Feagan BG, Rutgeerts P, Sands BE, et al; GEMINI 1 Study Group. Vedolizumab as induction and maintenance therapy for ulcerative colitis. *N Engl J Med*. 2013;369(8):699-710.
- Uzzan M, Tokuyama M, Rosenstein AK, et al. Anti- $\alpha 4\beta 7$  therapy targets lymphoid aggregates in the gastrointestinal tract of HIV-1-infected individuals. *Sci Transl Med*. 2018;10(461):eaau4711.
- Fleisher M, Marsal J, Lee SD, et al. Effects of vedolizumab therapy on extraintestinal manifestations in inflammatory bowel disease. *Dig Dis Sci*. 2018;63(4):825-833.
- Amiot A, Grimaud JC, Peyrin-Biroulet L, et al; Observatory on Efficacy and of Vedolizumab in Patients With Inflammatory Bowel Disease Study Group; Groupe d'Etude Thérapeutique des Affections Inflammatoires du tube Digestif. Effectiveness and safety of vedolizumab induction therapy for patients with inflammatory bowel disease. *Clin Gastroenterol Hepatol*. 2016;14(11):1593-1601.e2.
- Kim SB, Solis N, Deshpande AR, et al. New perianal fistulas in patients switched from anti-TNFs to vedolizumab for the treatment of Crohn's disease (CD). *Am J Gastroenterol*. 2017;112(suppl 1):S1107.
- Levine JS, Burakoff R. Extraintestinal manifestations of inflammatory bowel disease. *Gastroenterol Hepatol (N Y)*. 2011;7(4):235-241.
- Harbord M, Annesse V, Vavricka SR, et al; European Crohn's and Colitis Organisation. The first European evidence-based consensus on extra-intestinal manifestations in inflammatory bowel disease. *J Crohns Colitis*. 2016;10(3):239-254.
- Colombel JF, Sands BE, Rutgeerts P, et al. The safety of vedolizumab for ulcerative colitis and Crohn's disease. *Gut*. 2017;66(5):839-851.
- Varkas G, Thevissen K, De Brabanter G, et al. An induction or flare of arthritis and/or sacroiliitis by vedolizumab in inflammatory bowel disease: a case series. *Ann Rheum Dis*. 2017;76(5):878-881.
- Rubinsky MC, Cross RK, Sandborn WJ, et al. Extraintestinal manifestations in vedolizumab and anti-TNF-treated patients with inflammatory bowel disease [published online April 13, 2018]. *Inflamm Bowel Dis*. doi:10.1093/ibd/izy065.
- Tadbiri S, Peyrin-Biroulet L, Serrero M, et al; GETAID OBSERV-IBD Study Group. Impact of vedolizumab therapy on extra-intestinal manifestations in patients with inflammatory bowel disease: a multicentre cohort study nested in the OBSERV-IBD cohort. *Aliment Pharmacol Ther*. 2018;47(4):485-493.
- Lakatos PL, Lakatos L, Kiss LS, Peyrin-Biroulet L, Schoepfer A, Vavricka S. Treatment of extraintestinal manifestations in inflammatory bowel disease. *Digestion*. 2012;86(suppl 1):28-35.
- Kopylov U, Avni-Biron I, Ron Y, et al. Effectiveness and safety of vedolizumab for maintenance treatment in inflammatory bowel disease—the Israeli real world experience. *Dig Liver Dis*. 2019;51(1):68-74.
- Plevris N, Chuah CS, Allen RM, et al. Real-world effectiveness and safety of vedolizumab for the treatment of inflammatory bowel disease: the Scottish vedolizumab cohort. *J Crohns Colitis*. 2019;13(9):1111-1120.
- Feagan BG, Schwartz D, Danese S, et al. Efficacy of vedolizumab in fistulising Crohn's disease: exploratory analyses of data from GEMINI 2. *J Crohns Colitis*. 2018;12(5):621-626.
- Pijls PA, Gilissen LP. Vedolizumab is an effective alternative in inflammatory bowel disease patients with anti-TNF-alpha therapy-induced dermatological side effects. *Dig Liver Dis*. 2016;48(11):1391-1393.
- Feagan BG, Sandborn WJ, Colombel JF, et al. DOP019 Effect of vedolizumab treatment on extraintestinal manifestations in patients with Crohn's disease: a GEMINI 2 post hoc analysis. *Gastroenterology*. 2017;152:S597.
- Orlando A, Orlando R, Ciccio F, et al. Clinical benefit of vedolizumab on articular manifestations in patients with active spondyloarthritis associated with inflammatory bowel disease. *Ann Rheum Dis*. 2017;76(9):e31.
- Dulai PS, Singh S, Jiang X, et al. The real-world effectiveness and safety of vedolizumab for moderate-severe Crohn's disease: results from the US VICTORY Consortium. *Am J Gastroenterol*. 2016;111(8):1147-1155.
- Narula N, Peerani F, Meserve J, et al. Correction: Vedolizumab for ulcerative colitis: treatment outcomes from the VICTORY Consortium. *Am J Gastroenterol*. 2018;113(12):696.
- Meserve J, Aniwan S, Kolianni-Pace JL, et al. Retrospective analysis of safety of vedolizumab in patients with inflammatory bowel diseases. *Clin Gastroenterol Hepatol*. 2019;17(8):1533-1540.e2.
- Ciccio F, Guggino G, Rizzo A, et al. Type 3 innate lymphoid cells producing IL-17 and IL-22 are expanded in the gut, in the peripheral blood, synovial fluid and bone marrow of patients with ankylosing spondylitis. *Ann Rheum Dis*. 2015;74(9):1739-1747.