

# A Case of Horner Syndrome with Intermittent Mydriasis in a Patient with Hypoplasia of the Internal Carotid Artery

## CASE REPORT

M. Ibrahim  
H.M. Branson  
J.R. Buncic  
M.M. Shroff

**SUMMARY:** We report a rare case of hypoplasia of the right internal carotid artery (ICA) with ipsilateral congenital Horner syndrome. The etiology and pathogenesis of hypoplasia of the ICA is not well understood. Multiple types of collateral flow have been reported to develop to maintain blood supply to the ipsilateral cerebral hemisphere. Although collateral flow may allow these patients to remain asymptomatic, we postulate that the enlarged posterior communicating artery (PcomA) in our patient caused mass effect on the cisternal segment of cranial nerve III causing intermittent mydriasis apart from Horner syndrome.

## Case Report

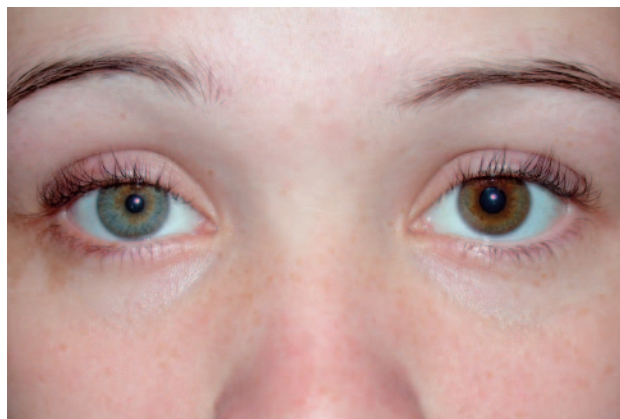A 15-year-old girl was referred to the ophthalmology clinic for assessment of right iris heterochromia and miosis, with intermittent episodes of asymmetric dilation of the right pupil. Since her birth, the parents had noticed the right pupil was smaller and the right iris lighter in color than the left eye (Fig 1).

Recently the patient complained of recurrent episodes of pupil dilation, which lasted approximately 10 minutes once a day for 2–3 months and then decreased to once a month. These episodes of pupil dilation were accompanied with tingling in the right cheek. In addition, the patient experienced intermittent blurring of the vision in the right eye with aching around her eyes, especially on the right. Examination of the patient demonstrated uncorrected visual acuity of 20/20 in both eyes. There was slight (1–2 mm) right-sided ptosis. The right pupil was smaller than the left, and the right iris was lightly pigmented compared with the left. The right iris was asymmetrically hypoplastic; the inferior sphincter cuff was hypoplastic, whereas the upper portion was normal. Failure of the right pupil to dilate after administration of 4% cocaine eye drops verified the diagnosis of unilateral right Horner syndrome. The rest of the ocular and visual examination was normal.

Time-of-flight MR angiography (MRA) of the circle of Willis showed absent flow in the right internal carotid artery (ICA) with collateral flow to the right cerebral hemisphere via an enlarged PcomA (Fig 2A, -B). Figure 3 demonstrates compression of the right cranial nerve III by the enlarged right PcomA. Time-of-flight MRA of the neck reveals absence of the right cervical ICA (Fig. 4). High-resolution CT through the skull base demonstrated an atretic right bony carotid canal, confirming presence of the hypoplastic ICA before skull base development (Fig 5).

## Discussion

Hypoplasia of the ICA is an uncommon congenital disease. Slightly more than 100 cases have been reported in the literature,<sup>1</sup> though only a few cases have been reported in association with congenital Horner syndrome.<sup>2</sup> To the best of our knowledge, the association of Horner syndrome with inter-



**Fig 1.** Clinical photograph demonstrating right Horner syndrome with ptosis, miosis, and iris heterochromia.

mittent mydriasis in the setting of hypoplasia of the ICA has not been reported.

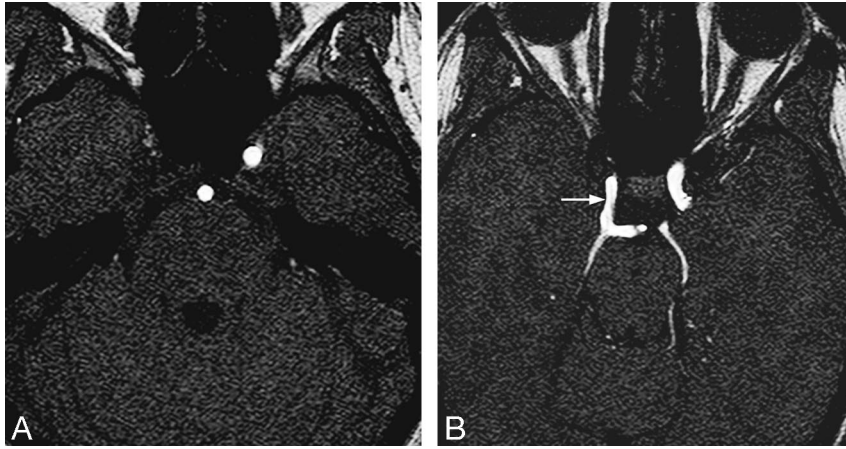
Most reported cases of aplasia and hypoplasia of the ICA are in asymptomatic patients. Arterial insufficiency is prevented via collateral pathways that include the circle of Willis, persistence of embryonic vessels, and transcranial collaterals via the external carotid artery.<sup>3,4</sup> These collateral pathways include fetal-type hypertrophied anterior communicating artery (AcomA) and PcomA supplying the anterior cerebral artery (ACA) and middle cerebral artery (MCA) respectively, adult type (hypertrophied AcomA supplying both of the ACA and MCA), and transcranial anastomosis arising from the contralateral ICA or from primitive vessels. Lie<sup>5</sup> described 6 pathways of collateral circulation in association with absence of the ICA. In types A, B, and C, unilateral (types A and B) or bilateral (type C) absence of the ICA is associated with hypertrophied AcomA and PcomA (type A), patent AcomA (type B), or carotid-vertebrobasilar anastomoses (type C). Type D represents intercavernous communication to the ipsilateral carotid siphon from the contralateral cavernous ICA in the setting of unilateral agenesis of the cervical segment of the ICA. In type E the ACAs are supplied by hypoplastic ICAs, whereas in type F transcranial anastomoses from the internal maxillary branches of the external carotid artery (ECA) system form supply to the distal ICA, the so-called rete mirabile. Our patient had a fetal type of collateral supply (Lie type A), with hypoplastic ICA and hypertrophied PcomA.

Changes in pupil size are governed by pupillary sphincter

Received June 17, 2005; accepted August 10.

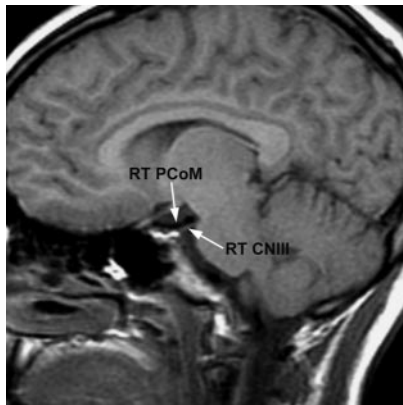
From the Departments of Radiology (M.I.), Diagnostic Imaging (H.M.B., M.M.S.), and Ophthalmology (J.R.B.), Hospital for Sick Children, Toronto, Ontario, Canada.

Address correspondence to Helen Branson, MD, c/o Jennifer J. Russell, Department of Diagnostic Imaging, The Hospital for Sick Children, 555 University Ave, Toronto, Ontario, M5G 1X8, Canada.



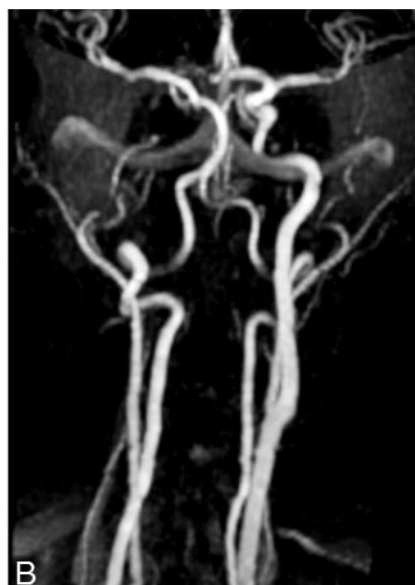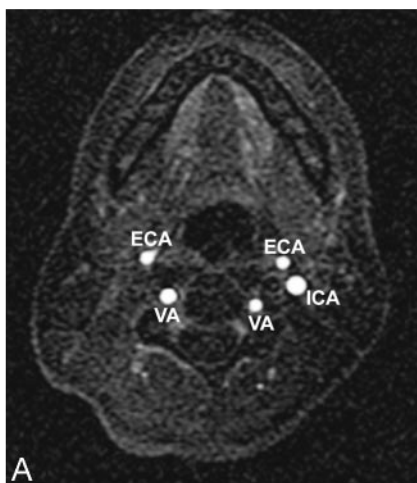
**Fig 2.** A, Source images from axial time-of-flight MRA demonstrates absence of the right ICA in the right parasellar region. The left ICA and basilar arteries are clearly seen.

B, Axial source MRA image superior to the prior image demonstrates an enlarged right PcomA.



**Fig 3.** Parasagittal T1-weighted sequence to the right of the midline demonstrates the enlarged right PcomA coursing along the superior aspect of the right third nerve.

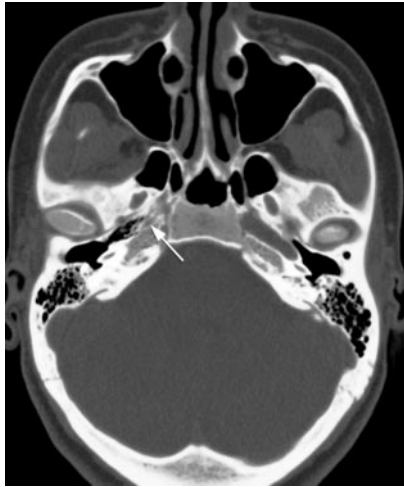(parasympathetic) and the pupillary dilator muscle (sympathetic) tone in response to ambient light, adrenergic and cholinergic tone, and local pharmacologic or pathophysiologic conditions. The parasympathetic (pupilloconstrictor) pathway originates in the Edinger-Westphal nucleus in the dorsal midbrain and exits with the motor fibers of the third cranial nerve (CN III) to the ciliary ganglion via the cavernous sinus.



**Fig 4.** Axial time-of-flight MRA of the neck with multiplanar intensity projection reformats demonstrating absent flow in the cervical right ICA.

Postganglionic fibers then travel to the sphincter muscle of the iris. Differential diagnosis of mydriasis includes cranial nerve dysfunction, Adie tonic pupil, CN III dysfunction, and pharmacologic blockade. Dysfunction of CN III can occur in a wide variety of settings and is found in association with uncal herniation, PcomA aneurysm, ophthalmoplegic migraine, peripheral neuropathies, Lyme disease, and alcoholism.<sup>6</sup> We postulate the underlying cause of mydriasis in our patient is related to hypertrophied PcomA intermittently compressing the cisternal segment of CN III and causing transient dysfunction of the sphincter muscle.

Horner syndrome results from an interruption of the sympathetic nerve supply to the eye. It may be congenital, acquired, or hereditary (autosomal dominant).<sup>7</sup> Birth trauma is a frequent cause of Horner syndrome.<sup>7</sup> Acquired Horner syndrome with no antecedent surgery is usually approached as being associated with potentially serious underlying disease. The interruption of the sympathetic fibers may occur centrally (ie, between the hypothalamus and the fibers' point of exit from the spinal cord [C8–T2]) or peripherally (ie, cervical sympathetic chain, superior cervical ganglion, or along the carotid artery). It is characterized by classic triad of miosis (constricted pupil), partial ptosis, and loss of hemifacial sweating (anhidrosis). Anhidrosis occurs with hyperaemia and warmth when oculosympathetic denervation of the sweat and vasoconstrictor fibers distributed through branches of the ECA occurs. Iris heterochromia is seen in congenital Horner syndrome, Horner syndrome that occurs in children younger than 2 years of age and in long-standing Horner syndrome. The association of Horner syndrome with congenital hypopla-



**Fig 5.** Axial CT through the skull base demonstrates an atretic right carotid canal on the right. Note the normal left-sided bony carotid canal.

sia of the ICA is rare, and only a few case reports have been published.<sup>2,8</sup>

In conclusion, the differential diagnosis of Horner syndrome is broad, with birth trauma the most common cause of

congenital Horner syndrome. The rare association with congenital hypoplasia of the ipsilateral ICA is reported. Multiple collateral flow pathways have been described to establish blood flow to the ipsilateral cerebral hemisphere. Such compensatory flow is essential but as seen in our case may cause further abnormalities.

## References

1. Claros P, Bandos R, Gilea I, et al. **Case report: major congenital anomalies of the internal carotid artery: agenesis, aplasia, and hypoplasia.** *Int J Pediatr Otorhinolaryngol* 1999;49:69–76
2. Dinç H, Alioglu Z, Erdöl Z, et al. **Agenesis of the internal carotid artery associated with aortic arch anomaly in a patient with congenital Horner's syndrome.** *AJNR Am J Neuroradiol* 2002;23:929–31
3. Midkiff RB, Boykin MW, McFarland DR, et al. **Agenesis of the internal carotid artery with intercavernous anastomosis.** *AJNR Am J Neuroradiol* 1995;16:1356–59
4. Chen CJ, Chen ST, Hsieh FY, et al. **Hypoplasia of the internal carotid artery with intercavernous anastomosis.** *Neuroradiology* 1998;40:252–54
5. Lie TA. *Congenital anomalies of the carotid arteries.* Amsterdam: Excerpta Medica;1968;35–51
6. Lee AG, Taber KH, Hayman LA, et al. **A guide to the isolated dilated pupil.** *Arch Fam Med* 1997;4:385–88
7. Jeffrey AR, Ellis FJ, Repka MX, et al. **Pediatric Horner syndrome.** *J Am Assoc Ped Ophthalmol* 1998;2:159–67
8. Given CA II, Huang-Hellinger F, Baker MD, et al. **Congenital absence of the internal carotid artery: case reports and review of the collateral circulation.** *AJNR Am J Neuroradiol* 2001;22:1953–59