

## Cephalometric comparison of adult anterior open bite treatment using clear aligners and fixed appliances

Bella Shen Garnett<sup>a</sup>; Kimberly Mahood<sup>b</sup>; Mai Nguyen<sup>c</sup>; Aliaa Al-Khateeb<sup>d</sup>; Siqi Liu<sup>e</sup>; Robert Boyd<sup>f</sup>; Heesoo Oh<sup>g</sup>

### ABSTRACT

**Objectives:** To compare fixed appliances and clear aligner therapy in correcting anterior open bite and in controlling the vertical dimension in adult patients with hyperdivergent skeletal patterns.

**Materials and Methods:** In this retrospective study, two treatment groups of adult ( $\geq 18$  years old) hyperdivergent patients (mandibular plane angles of  $\geq 38^\circ$ ) with anterior open bites were included: 17 fixed appliance patients and 36 clear aligner patients. Thirteen cephalometric measurements representing the vertical dimension were reported for each group. A two-sample *t*-test was used to assess differences in changes in mandibular plane angle and overbite between the two treatment groups.

**Results:** There were no statistical differences found in the magnitude of overbite correction and the changes in any of the cephalometric measurements for vertical control. The clear aligner group showed a slightly greater amount of lower incisor extrusion ( $P = .009$ ). The main mechanism of open bite correction was similar between the two treatment groups and was accomplished through retroclination of the upper and lower incisors while maintaining the vertical position of the upper and lower molars.

**Conclusions:** Cephalometric comparison of anterior open bite correction and changes in the mandibular plane angle associated with use of clear aligners and fixed appliances did not demonstrate statistically significant differences in adult hyperdivergent patients. (*Angle Orthod.* 2019;89:3–9.)

**KEY WORDS:** Vertical control; Clear Aligner; Fixed appliance; Open bite; Hyperdivergent; Adult

<sup>a</sup> Private Practice, San Francisco, Calif.

<sup>b</sup> Assistant Professor, Department of Orthodontics, University of the Pacific, Arthur A. Dugoni School of Dentistry, San Francisco, Calif.

<sup>c</sup> Instructor, Department of Orthodontics, Hanoi Medical University, Hanoi, Vietnam.

<sup>d</sup> Former Research Fellow, Department of Orthodontics, University of the Pacific, Arthur A. Dugoni School of Dentistry, San Francisco, Calif.

<sup>e</sup> Assistant Professor, First Clinical Division, Peking University School and Hospital of Stomatology, Beijing, China.

<sup>f</sup> Professor, Department of Orthodontics, University of the Pacific, Arthur A. Dugoni School of Dentistry, San Francisco, Calif.

<sup>g</sup> Professor and Program Director, Department of Orthodontics, University of the Pacific, Arthur A. Dugoni School of Dentistry, San Francisco, Calif.

Corresponding author: Dr Heesoo Oh, Department of Orthodontics, University of the Pacific, Arthur A. Dugoni School of Dentistry, 155 Fifth Street, San Francisco, CA 94103 (e-mail: hoh@pacific.edu)

Accepted: July 2018. Submitted: January 2018.

Published Online: October 3, 2018

© 2019 by The EH Angle Education and Research Foundation, Inc.

### INTRODUCTION

Vertical control during comprehensive orthodontic treatment has been a challenging problem in orthodontics.<sup>1,2</sup> It is known that fixed appliance therapy tends to extrude teeth and increase the mandibular plane angle during treatment.<sup>3,4</sup> This phenomenon has more significant adverse effects on nongrowing patients with hyperdivergent facial patterns (high mandibular plane angle) with or without the presence of an open bite, since it can lead to backward rotation of the mandible and reduction in chin projection.<sup>3,4</sup> Therefore, it is important to control the vertical dimension by preventing extrusion of the posterior teeth when selecting appliances and treatment mechanics in patients with high mandibular plane angles. Appliances that have been used in conjunction with fixed appliances in hyperdivergent patients for vertical control include posterior bite blocks,<sup>5</sup> vertical chin-cups,<sup>6</sup> high-pull headgears,<sup>7</sup> lingual holding arches,<sup>8</sup> posterior magnets,<sup>9</sup> temporary anchorage devices (TADS),<sup>10,11</sup> and surgical plates.<sup>12</sup>

More recently, some clinicians have introduced the use of clear aligners to control the vertical dimension, citing the development of posterior open bites at the end of clear aligner treatment.<sup>13,14</sup> Since its inception by Align Technology (Santa Clara, Calif) in 1999, the clear aligner system has become a popular treatment choice for adult patients. This is largely due to the superior esthetics and comfort that removable clear aligners provide over traditional full bonded fixed appliances.<sup>15</sup> Earlier studies<sup>16,17</sup> showed the significant limitations of Invisalign® treatment in treating complex malocclusions. However, with a series of improvements (G series) introduced over the past few years, several clinical case reports using clear aligners have shown good vertical control. Some clinicians claim that the clear aligner system can effectively treat open bites with high mandibular plane angles without extruding posterior teeth by incorporating intrusive forces and utilizing the plastic material thickness between the teeth.<sup>12,18</sup> In a recent systematic review analyzing the effectiveness of clear aligner therapy, Rossini et al.<sup>19</sup> reported that clear aligner therapy is effective in controlling anterior intrusion, but not anterior extrusion. However, no rigorous studies have been done to measure the magnitude of vertical control in patients with anterior open bites treated with clear aligners.

The purpose of this study was to examine the effectiveness of clear aligners in controlling the vertical dimension and in correcting anterior open bites by comparing the outcomes of clear aligner therapy to those of fixed appliance therapy in adult patients with hyperdivergent skeletal patterns (mandibular plane angles of  $\geq 38^\circ$ ). This was accomplished by testing the following two null hypotheses: (1) There is no difference in the magnitude of the anterior open bite correction in hyperdivergent patients with anterior open bites between the fixed and clear aligner groups; and (2) There is no difference in changes in the mandibular plane angle between the fixed and clear aligner groups.

## MATERIALS AND METHODS

The sample was drawn retrospectively from the practice of a single clinician who is considered an expert in both fixed appliance therapy and clear aligner therapy. The clinician is American Board of Orthodontics board-certified and is also a top 1% Invisalign-certified orthodontist. This study was approved by the institutional review board of the University of the Pacific (#16-104).

The study analysis was performed on adult patients over the age of 18 who were treated with either fixed appliance therapy between 2008 and 2014 (fixed appliance group) or clear aligner therapy between

2011 and 2014 (clear aligner group). This treatment time period for the clear aligner group was chosen because algorithms for intrusion of posterior teeth were introduced in 2011.

Hyperdivergent skeletal type was defined as having a mandibular plane–SN angle (MPA) of greater than or equal to  $38^\circ$  (normal =  $33^\circ \pm 6^\circ$ ), regardless of malocclusion type, and adult was defined as an individual older than 18 years at the start of treatment. A list of patients who started and completed their treatment within a selected time period (2008–2014 for fixed appliance and 2011–2014 for clear aligner) was generated using the clinician's practice management software program. The total number of adult patients eligible for screening was 597 (Table 1). To identify hyperdivergent patients, two research associates examined initial lateral cephalometric radiographs of all eligible adult patients in Dolphin™ imaging (version 11.8; Dolphin Imaging, Chatsworth, Calif) and used a  $38^\circ$  transparent plastic template to select patients with MPAs that exceeded  $38^\circ$  by visual inspection. Two hundred and ten patients were "collected" for further cephalometric tracing. Cephalometric landmarks were located by two calibrated tracers, and MPA was calculated to identify patients with MPAs of  $\geq 38^\circ$ . After all exclusion criteria were applied (Table 2), a total of 98 patients (36 patients for the fixed appliance group and 62 patients for the clear aligner group) remained in the hyperdivergent patient sample. For the present study, consecutively treated hyperdivergent patients with anterior open bites (less than 0 mm of overbite) were selected.

Sample size calculations were performed. In each group, a sample size of 16 subjects was estimated at a power of 80% and a .05 level of significance, which enabled the detection of significance between the two treatment groups in overbite changes of 1.5 mm and MPA changes of  $1.5^\circ$  with a standard deviation of 1.5.

The final anterior open bite sample consisted of 17 patients in the fixed appliance group and 36 patients in the clear aligner group (Figure 1). The clear aligner group had a higher proportion of anterior open bites (58%, 36/62) than did the fixed appliance group (47%, 17/36) in the hyperdivergent sample. More female patients were included in the clear aligner group (Table 3). The mean age for this adult open bite sample at the initial period (T1) was  $34.5 \pm 9.0$  years (ranging from 18.9 to 66.99 years). The final sample size for the clear aligner group was almost twice that of the fixed appliance group. However, the percentage of anterior open bite patients in the hyper-divergent sample was similar for the fixed and clear aligner groups.

With the introduction of the molar intrusion protocol for clear aligners in 2011, the clinician began to exclusively use clear aligners over fixed appliances in

**Table 1.** Practice Demographic Information

Appliance Group	Younger Than 18 y, n (%)	Older Than 18 y, n (%)	Total, n
Fixed appliance group (2008–2014)	339 (60)	217 (40)	546
Clear aligner group (2011–2014)	40 (9)	380 (91)	420
Total	379	597	966

correcting anterior open bites in adult patients. Figure 2 shows the pattern of appliance use prior to and after 2011.

**Treatment Modality**

In the fixed appliance group, various auxiliaries were utilized to control the vertical dimension. TADs were utilized in four patients (24%, 4/17) for molar intrusion. Transpalatal arches and lower lingual holding arches were also used to help minimize molar extrusion. In one patient, a lower bite block was utilized to control the vertical dimension and to help intrude the posterior teeth for 1 year prior to the placement of fixed appliances. Seven out of 17 patients (41%, 7/17) received bicuspid extraction therapy to resolve crowding and to protract the posterior teeth to help prevent the vertical dimension from increasing (wedging effect)<sup>20</sup> (Table 3).

Unlike the fixed appliance group, no TADs or extractions were utilized in the clear aligner group. Crowding was resolved by interproximal reduction (IPR) and arch expansion. Clear aligner therapy purportedly exerts intrusive forces on the posterior teeth and extrusive forces on the anterior teeth by utilizing optimized attachments; the anterior teeth are extruded as a unit by leveraging the posterior teeth as anchorage to close the open bite (Invisalign’s G4 protocol).

Prior to treatment, myofunctional therapy that incorporated 10 minutes of exercises was also discussed with all patients who presented with anterior tongue thrusts. Two patients in the fixed appliance group and seven patients in the clear aligner group used myofunctional therapy (Table 3).

**Lateral Cephalometric Analysis**

Lateral cephalometric landmarks were digitized independently by two calibrated judges. Outliers were excluded based on the landmark-specific envelopes of error.<sup>21</sup> The average values were recorded in a numerical database, and cephalometric measurements were calculated by computer operations. Anterior cranial base superimpositions were performed using the anterior wall of sella turcica, cribriform plate, and greater wing of the sphenoid bone. The T1 Frankfort

**Table 2.** Reasons for Exclusion<sup>a</sup>

Reasons	Fixed Appliance Group, n	Clear Aligner Group, n	Total, n
No final cephalometric radiographs	8	21	29
Orthognathic surgery	10	2	12
Phase 1 and 2 treatment	2	0	2
Use of TAD	NA	2	2
Total	20	25	45

<sup>a</sup> TAD indicates temporary anchorage device; NA, not applicable; TAD was considered one of the various auxiliary appliances used in fixed appliance therapy.

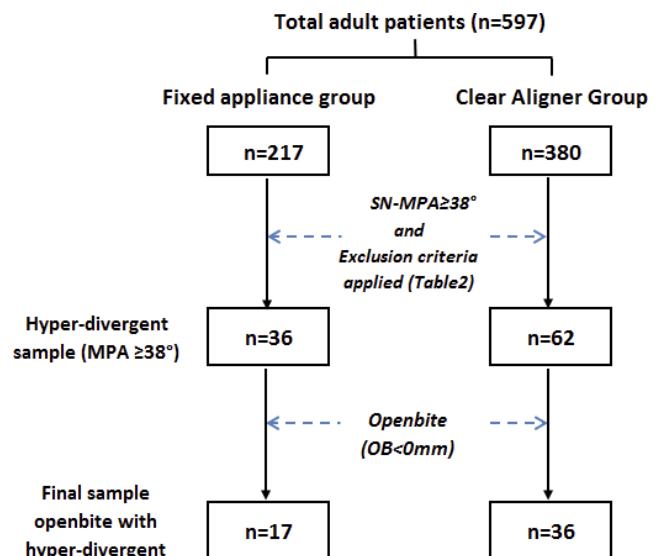
horizontal and Downs’ occlusal planes were transferred as reference planes to the final (T2) tracings (Figure 3).

**Statistical Analysis**

Descriptive statistics were generated to report the mean, standard deviation, and range of the demographic information for each of the three groups. Unpaired *t*-tests were used to compare mean differences, and chi-square tests were used to compare proportions. *P*-values of less than .05 were considered statistically significant. Statistical values were computed using the SAS statistical package (version 9.1; SAS, Cary, NC).

**RESULTS**

The mean age at T1 for the fixed appliance and clear aligner groups was 32.8 ± 11.9 years and 35.3 ± 7.3 years, respectively. Treatment times were similar between the fixed appliance (1.6 ± 0.7 years) and clear aligner (1.6 ± 0.6 years) groups.



**Figure 1.** Sampling process.

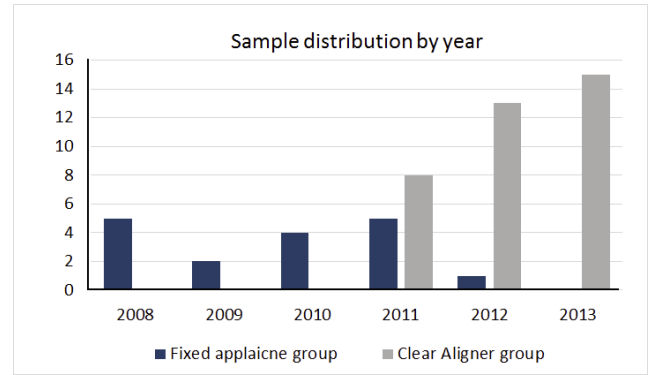
**Table 3.** Sample Characteristics for Anterior Open Bite Patients With Hyperdivergent Pattern<sup>a</sup>

Variables	Fixed Appliance Group (n = 17)		Clear Aligner Group (n = 36)		P*
	n	%	n	%	
Sex (female)	8	47	27	75	.05
Preorthodontic treatment history	4	24	7	20	NS
Myofunctional therapy	2	11.8	7	19.4	NS
Extraction	7	41	0	0	<.0001
TAD	4	24	NA	NA	NA

<sup>a</sup> TAD indicates temporary anchorage device; NS, not significant; NA, not applicable.

\* Chi-square/Fisher Exact Test.

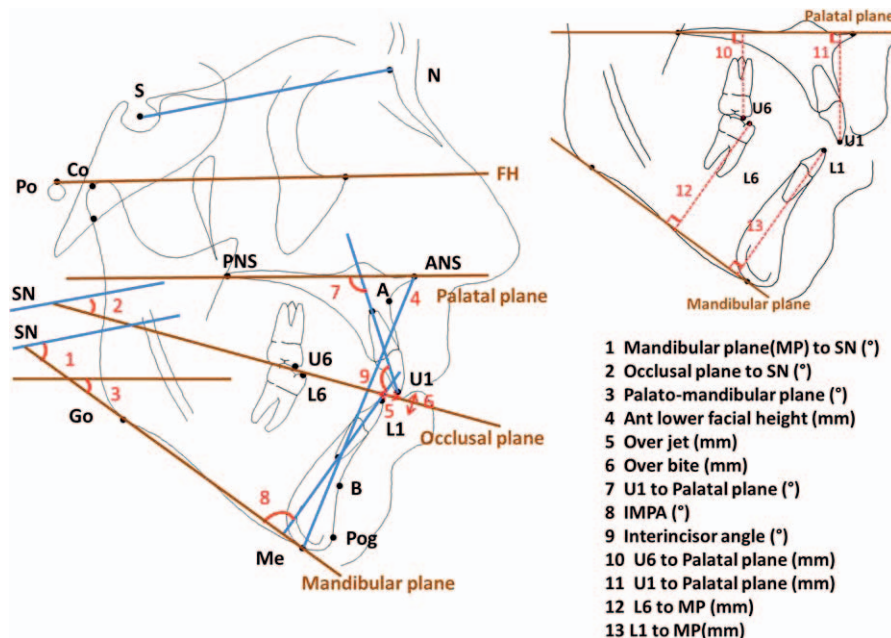
Table 4 shows the pretreatment (T1) and posttreatment (T2) cephalometric measurements for both groups. At T1, the means of the mandibular plane angle (43.2° vs 44.4°) and overbite (-1.3 mm vs -1.6 mm) were similar between the fixed and clear aligner groups. Figure 4 shows the distribution for open bite severity. The proportion of the moderate to severe open bites (less than -2 mm) was almost identical. Similarly, no differences were found in two outcome variables, MPA and OB, between the two groups at T2. In addition, there were no statistically significant differences found for any of the cephalometric measurements, including vertical position of the upper and lower molars and incisor inclinations at T1 and T2 (Table 4).



**Figure 2.** Sample distribution for fixed appliance and clear aligner groups during sampling period (2008–2014).

For changes during treatment (T1–T2), overbite correction was slightly greater in the clear aligner group (2.3 mm) than in the fixed appliance group (1.6 mm), but no statistical significance was found (Table 5). The mandibular plane angle changes showed a slightly greater increase in the clear aligner group (0.7 mm) than in the fixed appliance group (0.1 mm), but the difference was also not statistically significant. There were no statistical differences found in any of the cephalometric measurements for vertical control, such as palato-mandibular plane angle and anterior lower face height.

The only statistical difference found between the two groups was the vertical dental linear measurement from the mandibular plane (MP) to the lower incisor tip. This may indicate that the lower incisors were extruded



**Figure 3.** Cephalometric analysis.



**Table 4.** Comparison of Age and Cephalometric Measurements Between Fixed Appliance and Clear Aligner Groups at T1 and T2<sup>a</sup>

Variables	T1				T2			
	Fixed Appliance Group (n = 17)	Clear Aligner Group (n = 36)	Mean Difference	P	Fixed Appliance Group (n = 17)	Clear Aligner Group (n = 36)	Mean Difference	P
	Mean ± SD	Mean ± SD			Mean ± SD	Mean ± SD		
Age (year)	32.79 ± 12	35.29 ± 7.29	2.5	NS	34.37 ± 11.96	36.89 ± 7.28	2.52	NS
Skeletal-vertical dimension								
Mandibular plane angle, °	43.15 ± 3.83	44.43 ± 5.14	1.28	NS	43.26 ± 4.62	45.15 ± 5.31	1.89	NS
Palato-mandibular plane angle, °	33.53 ± 4.27	34.93 ± 5.5	1.45	NS	33.7 ± 4.17	35.13 ± 5.59	0.52	NS
Anterior lower facial height, mm	70.23 ± 5.09	68.84 ± 6.4	1.4	NS	70.04 ± 5.21	69.01 ± 6.23	1.43	NS
Dental-AP								
Over jet, mm	2.98 ± 2.09	3.32 ± 1.48	0.34	NS	2.69 ± 1.23	2.6 ± 0.64	0.09	NS
Dental-vertical measurements								
Overbite, mm	-1.3 ± 1.22	-1.57 ± 1.24	0.27	NS	0.46 ± 0.93	0.71 ± 0.94	0.25	NS
Occlusal plane angle, °	20.58 ± 3.76	21.49 ± 4.65	0.7	NS	22.24 ± 4.06	22.62 ± 4.62	0.37	NS
U6 to palatal plane distance, mm	25.24 ± 1.84	24.83 ± 2.71	0.41	NS	24.99 ± 2.2	24.85 ± 2.73	0.14	NS
U1 to palatal plane distance, mm	30.95 ± 2.32	31.07 ± 3.27	0.12	NS	31.48 ± 2.69	32.04 ± 3.08	0.56	NS
L6 to mandibular plane distance, mm	32.38 ± 3.55	31.47 ± 3.55	0.91	NS	32.55 ± 4.03	31.38 ± 3.64	1.17	NS
L1 to mandibular plane distance, mm	41.59 ± 3.66	40.7 ± 3.76	0.89	NS	41.46 ± 3.63	41.52 ± 3.63	0.06	NS
Dental-incisor inclination								
L1 to mandibular plane (IMPA), °	91.02 ± 8.5	93.39 ± 7.7	2.37	NS	85.29 ± 11.47	88.46 ± 7.24	3.17	NS
U1 to palatal plane angle, °	110.59 ± 5.26	107.96 ± 7.65	2.63	NS	105.84 ± 7.15	102.21 ± 7.44	3.63	NS
Interincisal angle, °	124.86 ± 10.2	123.72 ± 9.9	1.14	NS	135.18 ± 10.19	134.19 ± 8.83	0.99	NS

<sup>a</sup> NS indicates not significant; T1, pretreatment; T2, posttreatment; SD, standard deviation.

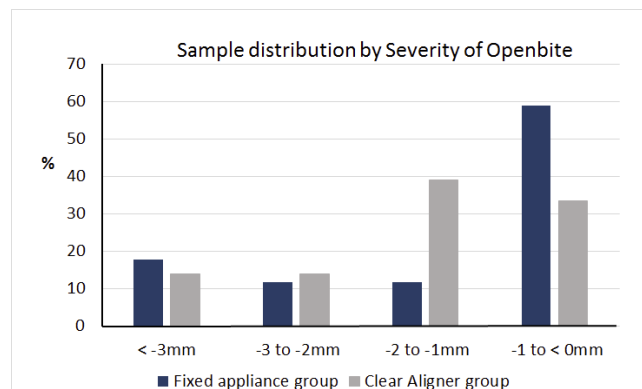
slightly more in the clear aligner group (0.8 mm) than in the fixed appliance group (-0.1 mm). The upper incisors were extruded in both groups. Significant treatment changes were found in the upper and lower incisor inclinations for both treatment groups. The magnitudes of change in the incisor inclination were very similar in both treatment groups; about 5° of upper and lower incisor retroclination and about 10° of total reduction in interincisal angle were observed (Table 5).

Therefore, there was a failure to reject the null hypotheses that there is no difference in controlling the vertical dimension (changes in MPA) and in the magnitude of anterior open bite correction between the fixed and clear aligner groups in hyperdivergent patients with anterior open bites.

**DISCUSSION**

Vertical control is critical in correcting anterior open bites in adult patients with hyperdivergent skeletal patterns. Anterior bite opening caused by extrusion of the posterior teeth would require more extrusion of the anterior teeth to correct the open bite, which has been shown to be unstable in the long term.<sup>22,23</sup> Contrary to the conventional belief that fixed appliance therapy tends to extrude molars and open the mandibular plane angle in hyperdivergent patients, the present study showed no statistically significant changes in the mandibular plane angle in both the fixed appliance and clear aligner groups. In both treatment groups of

hyperdivergent patients who had anterior open bites, the vertical dimension was well controlled. It seems that when experienced clinicians carefully plan and execute their mechanics in treating adult patients with anterior open bites and high MPAs, good vertical control can be achieved using either appliance. If the vertical dimension is not controlled with fixed appliances, the molars would extrude with initial leveling and aligning, when using intermaxillary elastics, or after bonding the second molars. Previous literature<sup>10-12</sup> supports the effectiveness of using TADs in controlling the vertical dimension by intruding the posterior teeth. In the present study, various auxiliaries, such as TADs, occlusal bite blocks, and extractions, were utilized to maintain the vertical dimension and to close anterior



**Figure 4.** Sample distribution by severity of anterior open bite at T1.

**Table 5.** Comparison of Treatment Time and Cephalometric Changes During Treatment (T1–T2) Between Fixed Appliance and Clear Aligner Groups<sup>a</sup>

Variables	Changes (T1–T2)			
	Fixed Appliance Group (n = 17)	Clear Aligner Group (n = 36)	Mean Difference	P
Treatment time (year)	1.58 ± 0.73	1.6 ± 0.61	0.02	NS
Skeletal-vertical dimension				
Mandibular plane angle, °	0.11 ± 1.82	0.71 ± 1.29	0.6	NS
Palato-mandibular plane angle, °	0.17 ± 1.57	0.2 ± 1.82	0.94	NS
Anterior lower facial height, mm	-0.19 ± 0.97	0.17 ± 1.6	0.03	NS
Dental-AP				
Overjet, mm	-0.39 ± 2.53	-0.72 ± 1.63	0.33	NS
Dental-vertical				
Overbite, mm	1.75 ± 1.54	2.28 ± 1.55	0.53	NS
Occlusal plane angle, °	1.66 ± 2.48	1.13 ± 2.25	1.01	NS
U6 to palatal plane distance, mm	-0.25 ± 0.85	0.01 ± 1.3	0.26	NS
U1 to palatal plane distance, mm	0.53 ± 1.26	0.97 ± 1.31	0.44	NS
L6 to mandibular plane distance, mm	0.16 ± 1.07	-0.09 ± 1.16	0.25	NS
L1 to mandibular plane distance, mm	-0.13 ± 1.37	0.82 ± 1.07	0.95	.009
Dental-incisor inclination				
L1 to mandibular plane (IMPA), °	-5.73 ± 7.42	-4.92 ± 6.08	0.81	NS
U1 to palatal plane angle, °	-4.76 ± 7.19	-5.75 ± 5.25	0.99	NS
Interincisal angle, °	10.31 ± 12.09	10.47 ± 7.88	0.16	NS

<sup>a</sup> NS indicates not significant; T1, pretreatment; T2, posttreatment; SD, standard deviation.

open bites in the fixed appliance group. Unlike the fixed appliance group, no TADs or extractions were utilized in the clear aligner group. It appears that posterior coverage of all the teeth helps to provide vertical control by acting as a posterior bite block to prevent extrusion of the posterior teeth, even when Class II and Class III elastics are used.

There was no difference in the magnitude of overbite correction between the two groups. The mean overbite change at the end of treatment was 2.3 mm for the clear aligner group and 1.8 mm for the fixed appliance group. Though these changes were slightly greater in the clear aligner group than in the fixed appliance group, the difference was not statistically significant. Five degrees of retroclination of both the upper and lower incisors appeared to contribute to open bite correction. Extrusion of the upper and lower incisors was less than 1 mm for both treatment groups, but the clear aligner group showed slightly greater lower incisor extrusion ( $P = .009$ ) that contributed to slightly greater overbite correction. Both treatment groups showed similar magnitudes of interincisal angle reduction at  $10.3^\circ \pm 12.1^\circ$  and  $10.5^\circ \pm 7.9^\circ$  for the fixed appliance and clear aligner groups, respectively.

In the clear aligner group, all patients were treated without extractions, so IPR was utilized to help decrease protrusion. Tongue thrust habits, which can cause infraeruption of the lower incisors, are frequently observed in patients with reverse Curve of Spee. With Invisalign's G4 protocol, extrusion attachments can be placed on the lower incisors to help extrude them in leveling the occlusal plane to help obtain a flat Curve of

Spee in the lower arch. This can be done without posterior extrusion and opening the vertical dimension.

The present study showed that clear aligners can be effective in controlling the vertical dimension and correcting even severe anterior open bites in adult hyperdivergent patients without utilizing TADs or other auxiliaries. Therefore, clear aligners can be a useful treatment modality when successful TAD placement is not readily achievable.

Most recent studies<sup>24,25</sup> that evaluated the effectiveness and efficiency of clear aligner therapy compared to fixed appliances have shown statistically significant shorter treatment times for the clear aligner group. However, there was no difference found in the present study.

Long-term stability of open bite correction has long been a problem. Relapse has been reported in 20–44% of conventionally treated patients.<sup>22,23</sup> Stability of anterior open bite correction using clear aligners has not been reported. Therefore, further research needs to be done to follow these patients during retention.

This study had some limitations. For instance, retrospective studies are particularly subject to incomplete records. In the present study, the rate of incomplete records was relatively low, and the study's deficiencies were documented in Table 2 and Figure 2. In addition, the present study sample was derived from a single clinician's practice, and the treatment modalities used in fixed appliance and clear aligner therapy may be unique to the clinician's skill and expertise. Therefore, generalization of the results of this study

may be limited, and the study should be carefully interpreted.

## CONCLUSIONS

- The magnitude of anterior open bite correction obtained using clear aligners and fixed appliances did not demonstrate a statistically significant difference in adult hyperdivergent patients. The vertical dimension was maintained, and changes in MPA were small in both treatment groups, with no statistical difference between the two groups. Therefore, there was a need to reject the two null hypotheses.
- Significant retroclination of the upper and lower incisors, good vertical control, and no significant extrusion of the posterior teeth appear to be the main mechanisms for open bite correction.

## REFERENCES

1. Subtelny JD, Sakuda M. Open-bite: diagnosis and treatment. *Am J Orthod.* 1964;50:337–358.
2. Dung DJ, Smith RJ. Cephalometric and clinical diagnoses of openbite tendency. *Am J Orthod.* 1988;94:484–490.
3. Arat M, Iseri H. Orthodontic and orthopaedic approach in the treatment of skeletal open bite. *Eur J Orthod.* 1992;14:207–215.
4. Ryan MJ, Schneider BJ, BeGole EA, Muhl ZF. Opening rotations of the mandible during and after treatment. *Am J Orthod Dentofacial Orthop.* 1998;114:142–149.
5. Kuster R, Ingervall B. The effect of treatment of skeletal open bite with two types of bite-blocks. *Eur J Orthod.* 1992;14:489–499.
6. Pearson LE. Vertical control in treatment of patients having backward-rotational growth tendencies. *Angle Orthod.* 1978;48:132–140.
7. Iscan HN, Dincer M, Gultan A, Meral O, Taner-Sarisoy L. Effects of vertical chin cap therapy on the mandibular morphology in open-bite patients. *Am J Orthod Dentofacial Orthop.* 2002;122:506–511.
8. Villalobos FJ, Sinha PK, Nanda RS. Longitudinal assessment of vertical and sagittal control in the mandibular arch by the mandibular fixed lingual arch. *Am J Orthod Dentofacial Orthop.* 2000;118:366–370.
9. Noar JH, Shell N, Hunt NP. The performance of bonded magnets used in the treatment of anterior open bite. *Am J Orthod Dentofacial Orthop.* 1996;109:549–556.
10. Kuroda S, Sakai Y, Tamamura N, Deguchi T, Takano-Yamamoto T. Treatment of severe anterior open bite with skeletal anchorage in adults: comparison with orthodontic surgery outcomes. *Am J Orthod Dentofacial Orthop.* 2007;132:599–605.
11. Deguchi T, Kurosaka H, Oikawa H, et al. Comparison of orthodontic treatment outcomes in adults with skeletal open bite between conventional edgewise treatment and implant-anchored orthodontics. *Am J Orthod Dentofacial Orthop.* 2011;139:S60–S68.
12. Sherwood KH, Burch JG, Thompson WJ. Closing anterior open bites by intruding molars with titanium miniplate anchorage. *Am J Orthod.* 2002;122:593–600.
13. Boyd RL. Complex orthodontic treatment using a new protocol for the Invisalign Appliance. *J Clin Orthod.* 2007;41:525–547.
14. Schupp W, Haubrich J, Neumann I. Treatment of anterior open bite with the Invisalign system. *J Clin Orthod.* 2010;44:501–507.
15. White DW, Julien KC, Jacob H, Campbell PM, Buschang PM. Discomfort associated with Invisalign and traditional brackets: a randomized, prospective trial. *Angle Orthod.* 2017;87:801–808.
16. Djeu G, Shelton C, Maganzini A. Outcome assessment of Invisalign and traditional orthodontic treatment compared with the American Board of Orthodontics Objective Grading System. *Am J Orthod Dentofacial Orthop.* 2005;128:292–298.
17. Kuncio D, Maganzini A, Shelton C, Freeman K. Invisalign and traditional orthodontic treatment postretention outcomes compared using the American Board of Orthodontics Objective Grading System. *Angle Orthod.* 2007;77:864–869.
18. Guarneri MP, Oliverio T, Silvestre I, Lombardo L, Siciliani G. Open bite treatment using clear aligners. *Angle Orthod.* 2013;83:913–919.
19. Rossini G, Parrini S, Castroflorio T, Deregibus A, Debernardi CL. Efficacy of clear aligners in controlling orthodontic tooth movement: a systematic review. *Angle Orthod.* 2015;85:881–889.
20. Gkantidis N, Halazonetis DJ, Alexandropoulos E, Haralabakis NB. Treatment strategies for patients with hyperdivergent Class II division 1 malocclusion: is vertical dimension affected? *Am J Orthod Dentofacial Orthop.* 2011;140:346–355.
21. Baumrind S, Miller D. Computer-aided head film analysis: The University of California San Francisco method. *Am J Orthod.* 1980;78:41–65.
22. Huang GJ. Long-term stability of anterior open-bite therapy: a review. *Sem Orthod.* 2002;8:162–172.
23. Janson G, Valarelli FP, Henriques JFC, de Freitas MR, Cançado RH. Stability of anterior open bite nonextraction treatment in the permanent dentition. *Am J Orthod Dentofacial Orthop.* 2003;124:265–276.
24. Buschang PH, Shaw SG, Ross M, Crosby D, Campbell PM. Comparative time efficiency of aligner therapy and conventional edgewise braces. *Angle Orthod.* 2014;84:391–396.
25. Gu J, Tang JS, Skulski B, et al. Evaluation of Invisalign treatment effectiveness and efficiency compared with conventional fixed appliances using the Peer Assessment Rating index. *Am J Orthod Dentofacial Orthop.* 2017;151:259–266.