



## CASE REPORT

# Recurrent Cellulitis Associated with Acupuncture with Migratory Gold Threads

Hyun Jin Kang, In Hye Choi, Chul Jong Park, Kyung Ho Lee

Department of Dermatology, College of Medicine, The Catholic University of Korea, Seoul, Korea

In Asian countries, acupuncture with gold threads has been widely used in the treatment of pain. However, several reports have suggested that the implanted gold threads can become fragmented and migrate to other parts of the body, damaging surrounding tissues. A 75-year-old female presented with diffuse erythematous edema with multiple vesicles on the right lower leg for 3 days. She had previously suffered from cellulitis on the same region twice for the last 1 year. Her past medical history included acupuncture with gold threads on the back due to lumbar herniated nucleus pulposus (HNP) about 10 years ago. Histopathological examination demonstrated marked subepithelial edema and diffuse perivascular infiltrate of inflammatory cells in the dermis. Simple radiography of the leg revealed numerous radiodense threads in the soft tissue. Since the patient did not receive acupuncture on any other sites except on the back, we hypothesized that the gold threads injected on the back may have migrated through the vessels to the leg. These metal fragments can cause inflammatory reaction and make the tissues more susceptible to secondary infections. The lesion gradually improved after treatment with systemic steroid and antibiotics for 1 week. (*Ann Dermatol* 33(3) 281 ~ 283, 2021)

**-Keywords-**

Acupuncture, Cellulitis, Gold thread

## INTRODUCTION

In Asian countries, acupuncture with gold threads has been widely used in the management of pain such as headache, osteoarthritis as a complementary therapy<sup>1</sup>. It is hypothesized that the gold threads implanted in the body act as a continuous stimulation, which can help to reduce pain. Although gold is an inert metal, permanent implantation of this foreign material can cause undesired complications. Particularly, there have been several reports proposing the possibility of gold threads migrating throughout the body and damaging surrounding tissues<sup>2,3</sup>. These damaged tissues are more susceptible to secondary infections. The following presentation is about a case of recurrent cellulitis in which migratory gold threads could have an indirect impact on the patient's susceptibility to secondary infections.

## CASE REPORT

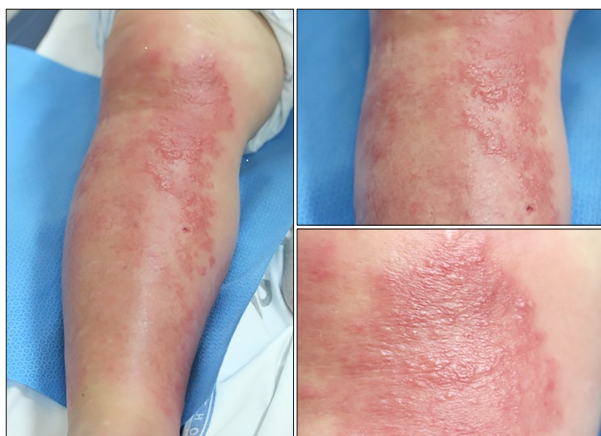A 75-year-old female presented with diffuse edema on the right lower leg for 3 days (Fig. 1). Physical examination showed painful and tender, ill-defined, erythematous edema with multiple vesicles. According to her past medical history, she received acupuncture with gold threads on the back about 10 years ago and denied of any procedure on any other parts of the body including the legs. For the last 1 year, she had suffered from cellulitis on the right lower leg twice and plucked several gold threads out of the skin surface of the leg. Laboratory examination revealed an elevated erythrocyte sedimentation rate (ESR) of 60 mm/hour (normal range, 0~20 mm/hour) and C-re-

Received October 17, 2019, Revised February 5, 2020, Accepted for publication February 11, 2020

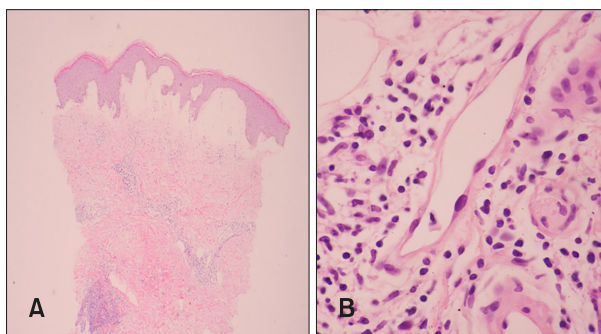
**Corresponding author:** Kyung Ho Lee, Department of Dermatology, Bucheon St. Mary's Hospital, College of Medicine, The Catholic University of Korea, 327 Sosa-ro, Wonmi-gu, Bucheon 14647, Korea. Tel: 82-32-340-2115, Fax: 82-32-340-2118, E-mail: beauty4u@catholic.ac.kr  
ORCID: <https://orcid.org/0000-0002-0108-3376>

This is an Open Access article distributed under the terms of the Creative Commons Attribution Non-Commercial License (<http://creativecommons.org/licenses/by-nc/4.0>) which permits unrestricted non-commercial use, distribution, and reproduction in any medium, provided the original work is properly cited.

Copyright © The Korean Dermatological Association and The Korean Society for Investigative Dermatology

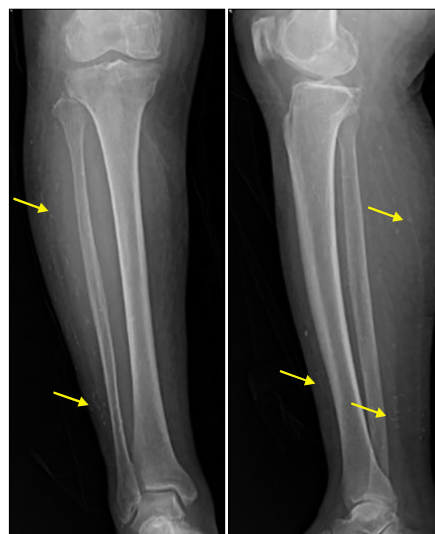


**Fig. 1.** Painful and tender, ill-defined, erythematous edema with multiple vesicles on the right lower leg for 3 days. We received the patient's consent form about publishing all photographic materials.



**Fig. 2.** (A) Histopathologic findings showing marked subepithelial edema and diffuse perivascular infiltrate of inflammatory cells (H&E,  $\times 40$ ). (B) The perivascular inflammatory cells are mainly composed of lymphocytes and histiocytes (H&E,  $\times 400$ ).

active protein (CRP) 124.60 mg/L (0~5 mg/L). Bacterial culture of the lesion with a sterile swab showed growth of gram positive rods. A biopsy specimen obtained from the leg demonstrated subepithelial edema and diffuse perivascular infiltrate of inflammatory cells, mainly composed of lymphocytes and histiocytes (Fig. 2). Moreover, innumerable radio-dense threads in the soft tissue were detected in the simple X-ray of the leg (Fig. 3). Based on the clinical, laboratory and radiological findings, we diagnosed the patient with cellulitis associated with gold threads. Considering the fact that she had previously received acupuncture with gold threads on the back, we hypothesized that they migrated from the back to the leg. The patient was treated with amoxicillin/clavulanate 3.6 g/day and prednisolone 40 mg/day for 7 days. Although the symptoms improved after the treatment, the patient was educated about potential recurrence in the future since the needle fragments



**Fig. 3.** Plain radiographs show numerous radio-dense threads (arrows) in the soft tissue of the right lower leg.

were not removed.

## DISCUSSION

Acupuncture is a subset of traditional Chinese medicine, as well as traditional Korean medicine that involves stimulating specific points on the body in order to restore balance to the body's energy flow<sup>4</sup>. The most common method used to stimulate acupoints involves placement of disposable sterile needles into the skin. In addition to the traditional method, there are various other stimulation techniques used in different circumstances.

For the last several decades, gold thread acupuncture has been used for the management of painful disorders. It is believed that insertion of thin pieces of sterile gold threads relieves pain by causing continuous stimulation in the body<sup>1</sup>. However, there are several complications associated with the practice. The lack of regulation can lead to frequent contamination of the tools causing infections. Also, there are several case reports regarding local adverse effects near the site of needle insertion such as bleeding, hematoma, inflammation and subsequent foreign body granuloma formation<sup>5,6</sup>. Moreover, migration of needles to other locations has been previously reported. For instance, Lazarow et al.<sup>7</sup> reported a case of a patient with innumerable gold needles scattered throughout the body. They were found not only in the superficial and deep abdominal and pelvic compartments, but also extended into the spinal canal, through the veins and bowel. The gold particles were demonstrated on the axial and abdomen/pelvis computed tomography.

In this case, the patient had previously received acupuncture with gold threads on the back, and she denied of the procedure on any other sites of the body. Ironically, cellulitis occurred repeatedly on the right lower leg, rather than the primary site of injection. The patient had no history of direct trauma on the leg or pre-existing disorders such as tinea pedis, intertrigo, venous insufficiency, diabetes mellitus and other systemic diseases that may predispose her to such recurrent cellulitis. Furthermore, there were incidences when the patient plucked several gold threads out of the leg, during which the tissues could have been damaged. In this regard, the numerous radio-dense threads observed in the plain radiograph of the leg further suggests the possibility that they may have indirectly caused cellulitis by damaging the surrounding tissues and making them more susceptible to secondary infections. We assume that the implanted particles on the back have migrated through the vessels to the legs. Since these particles are not self-absorbable, they remain in the tissue for years and cause secondary infections recurrently. To date, there is little scientific evidence to support the efficacy and safety of cultural practices such acupuncture<sup>1</sup>. However, in this era of globalization, they are widely performed throughout different regions of the world<sup>4</sup>. Thus, health care providers need to be familiar with their dermatologic and systemic complications. Especially, when the practice involves foreign particles such as gold, we need to be aware of the possibility that they can affect regions distant from the primary site of injection. In such cases, radiologic examinations can be helpful with visualization and localization of the migrated particles. Herein, we report an interesting case in which acupuncture with gold threads could have acted as a potential predisposing factor of recurrent cellulitis.

## CONFLICTS OF INTEREST

The authors have nothing to disclose.

## FUNDING SOURCE

None.

## DATA SHARING STATEMENT

Research data are not shared.

## ORCID

Hyun Jin Kang, <https://orcid.org/0000-0003-0586-9891>

In Hye Choi, <https://orcid.org/0000-0001-5065-2080>

Chul Jong Park, <https://orcid.org/0000-0003-3099-4109>

Kyung Ho Lee, <https://orcid.org/0000-0002-0108-3376>

## REFERENCES

1. Cho J, Park YS. Gold thread acupuncture for a headache. *Am J Med Sci* 2015;350:420.
2. Wang YF, Wang CC, Liu KL. A woman's secret. Filler rhinoplasty with Radiesse (Merz Aesthetics, San Mateo, CA) and gold thread implantation. *Ann Emerg Med* 2013;62:224, 234.
3. Stark GB, Bannasch H. The "golden thread lift": radiologic findings. *Aesthetic Plast Surg* 2007;31:206-208.
4. Vashi NA, Patzelt N, Wirya S, Maymone MBC, Zancanaro P, Kundu RV. Dermatoses caused by cultural practices: therapeutic cultural practices. *J Am Acad Dermatol* 2018;79: 1-16.
5. Jia J, Yu Y, Deng JH, Robinson N, Bovey M, Cui YH, et al. A review of Omics research in acupuncture: the relevance and future prospects for understanding the nature of meridians and acupoints. *J Ethnopharmacol* 2012;140:594-603.
6. Kim JY, Lee WJ, Kim DW, Lee SJ. Facial foreign body granuloma by gold thread needle-embedding therapy. *Korean J Dermatol* 2011;49:561-563.
7. Lazarow F, Andrews RH, Revels J, Shaves S. Migration of innumerable chronically retained acupuncture needles. *Radiol Case Rep* 2017;12:546-548.