

**ORIGINAL
RESEARCH**

C. Oppenheim
C. Lamy
E. Touzé
D. Calvet
M. Hamon
J.-L. Mas
J.-F. Méder

Do Transient Ischemic Attacks with Diffusion-Weighted Imaging Abnormalities Correspond to Brain Infarctions?

BACKGROUND AND PURPOSE: Our aim was to determine whether diffusion-weighted imaging (DWI) changes associated with transient ischemic attack (TIA) are reversible or correspond to permanent tissue injury.

METHODS: Among 103 consecutive patients admitted for TIA, 36 (34.9%) had abnormalities on initial DWI (delay from TIA = 30 ± 33 hours [mean \pm SD]). Thirty-three patients (59 DWI lesions) had an MR imaging follow-up (delay from TIA = 10.6 ± 5 months) including fluid-attenuated inversion recovery, T2, DWI, and 3D T1-weighted sequences. For each lesion, we recorded the quantitative parameters on initial DWI (volume, apparent diffusion coefficient [ADC]) and performed a comparison between reversible and irreversible lesions.

RESULTS: MR imaging failed to detect any permanent injury in 7 patients and identified subsequent infarct in regions corresponding to the original DWI abnormalities in 26 patients (79%). Of the 59 lesions initially identified on DWI, 45 (76.3%) were associated with permanent injury on follow-up MR imaging. The DWI volume was significantly larger (0.91 ± 1.7 versus 0.21 ± 0.21 cm³, $P = .003$) and the ADC ratio values lower ($79 \pm 15\%$ versus $91 \pm 9\%$, $P = .001$) in lesions with subsequent infarct than in those that were fully reversible.

CONCLUSION: By showing that most patients with DWI-positive TIAs share the same imaging outcome as stroke patients, our data provide additional support for the redefinition of TIA, which considers that all cases of transient deficit with characteristic neuroimaging abnormalities should be diagnosed as a stroke.

Brain imaging has challenged the assumption that because clinical transient ischemic attack (TIA) symptoms resolve, significant ischemic tissue does not occur.¹⁻⁴ MR imaging using diffusion-weighted imaging (DWI) reveals an ischemic lesion in approximately half of all TIAs (range, 21%–67%),^{1,4-11} with the probability of DWI positivity increasing with the duration of symptoms.^{7,12} Therefore, the TIA Working Group has proposed a new definition of TIA as a brief episode of neurologic dysfunction presumptively caused by focal brain or retinal ischemia, with clinical symptoms typically lasting less than 1 hour, and without neuroimaging evidence of acute infarction. The corollary is that persistent clinical signs or characteristic imaging abnormalities define infarction—that is, stroke.³ This implicitly assumes that imaging changes associated with these transient focal neurologic symptoms correspond to permanent injury (ie, infarction), a question that remains to be answered. In particular, we need to determine how often these signal intensity changes lead to an established infarct. Case studies^{13,14} and follow-up images in 9 nonconsecutive patients with TIA⁴ have suggested that acute DWI changes can reflect fully reversible ischemia. Conversely, another group recently described a series of 11 patients with TIA with DWI lesions at the hyperacute stage, all of which persisted at the subacute stage.¹⁵

To improve our knowledge of the pathophysiology of TIA-related DWI lesions, we performed a long-term MR follow-up of 33 consecutive TIA patients who initially had a positive DWI. We also compared TIA patients with a fully reversible lesion with the other patients, with the aim of identifying parameters that are predictive of subsequent infarction.

Methods

Patient Population

We studied clinical and imaging data of 105 consecutive patients admitted to our stroke unit for a TIA over a 15-month period (between January 1, 2003, and March 31, 2004). A senior neurologist initially examined all patients on admission. TIAs were defined as symptoms of presumed ischemic cerebrovascular origin lasting less than 24 hours. Patients with isolated amaurosis fugax were included in the study. The following clinical data were compiled for all patients: age, sex, symptoms of TIA, duration of symptoms, number of events, vascular territory, identifiable cause of TIA.¹⁶ For patients with multiple TIAs, only the longest attack was considered for the evaluation of the duration of symptoms. In cases of recurrent TIA events, the delay was calculated from the last event. All patients underwent routine blood biochemistry, electrocardiography, and cervical duplex ultrasonography. All but 2 patients had transthoracic or transesophageal echocardiography, and 79 patients had a cervical MR angiography.

All patients with TIA had brain MR imaging on the day of admission as part of their routine work-up, except for 2 patients (MR contraindication in 1 case and nonavailability of MR units in the other), leaving a group of 103 TIA patients. There were 58 men and 45 women, with a mean age \pm SD of 59.6 ± 17.9 years. The mean duration of symptoms was 1.8 ± 3.4 hours. The median time from onset of TIA symptoms to initial MR imaging study was 24 hours (range, 3.3

Received September 27, 2005; accepted after revision December 8.

From the Departments of Neuroradiology (C.O., J.-F.M.) and Neurology (C.L., E.T., D.C., J.-L.M.), Université Paris Descartes, Centre Hospitalier Sainte-Anne, Paris, France; Department of Neuroradiology, Centre Hospitalo-Universitaire, Caen, France, (M.H.); and Unité INSERM 562, Unité de Neuro-imagerie Anatomofonctionnelle (UNAF) Service Hospitalier Frédéric Joliot, CEA/DRM/DSV, Orsay, France (C.O.)

Address correspondence to Catherine Oppenheim, Département d'Imagerie Morphologique et Fonctionnelle, Centre Hospitalier Sainte-Anne, 1 rue Cabanis, 75674 Paris cedex 14, France; e-mail: c.oppenheim@ch-sainte-anne.fr

hours to 11.7 days). One neuroradiologist (C.O.) reviewed all initial MRIs for bright signal intensity changes on DWI on a dedicated workstation. Of the 103 patients studied, 36 (34.9%) presented at least 1 hyperintense lesion. A follow-up MR imaging, performed as part of routine work-up, was available in all but 3 of these patients, leaving a study group of 33 patients (delay from TIA onset to follow-up MR imaging, 10.6 ± 5 months; median, 11.5 months; range, 4–22 months).

Initial MR Imaging

Initial imaging studies were performed on a 1.5T MR unit equipped with echo-planar capability (Signa; GE Medical Systems, Milwaukee, Wis). The initial MR imaging was performed according to our routine MR stroke protocol, including the following 3-pulse sequences acquired in the anterior commissure-posterior commissure (AC-PC) plane with 24 contiguous 6-mm sections: (1) single-shot, echo-planar, spin-echo DWI with $b = 0, 1000 \text{ s/mm}^2$ (matrix, 128×128 ; field of view, $24 \times 24 \text{ cm}$; repetition time/echo time [TR/TE], 5000/86; number of excitations [NEX], 2). The diffusion trace images were calculated from 3 DWI acquisitions with the diffusion gradients sequentially applied along each of the 3 orthogonal axes; (2) fast fluid-attenuated inversion recovery (FLAIR) sequence (matrix, 256×160 ; field of view, $24 \times 24 \text{ cm}$; TR/TE/inversion time [TI], 10,002/148/2200 ms; NEX, 1); (3) gradient echo T2*-weighted sequence (matrix, 256×224 ; field of view, $24 \times 18 \text{ cm}$; TR/TE, 480/13 ms; flip angle, 25°; NEX, 1).

For patients with a positive initial DWI, a single neuroradiologist recorded the number of lesions and the affected arterial territory (anterior, posterior, multiple). Blinded to the results of the follow-up MR imaging (see below), a single observer then analyzed each DWI lesion separately by measuring its volume and apparent diffusion coefficient (ADC) with the aid of an image analysis software (FuncTool; GE Medical Systems). Volume measurements of DWI lesions were done by outlining the hyperintense area on DWI manually. The final volume for each lesion was then obtained by adding the contoured DWI lesion and multiplying by the section thickness. ADC maps were created from 2-point analysis and thresholded at $1200 \text{ mm}^2/\text{s}$ to minimize partial volume effect with the CSF. For each lesion, the ADC was computed using a small (size, 12 ± 6 ; range, 5–23 mm^2) circular region of interest (ROI) centered in the DWI hyperintensity. ROIs were mirrored onto the contralateral hemisphere to compute ADC ratios (rADC).

Follow-Up MR Imaging

The follow-up MR imaging included 4 sequences: DWI (matrix, 128×128 ; field of view, $24 \times 24 \text{ cm}$; TR/TE, 5000/82.4; NEX, 2; section thickness, 5 mm; gap, 0.5 mm; imaging time, 40 seconds), fast FLAIR (matrix, 256×192 ; field of view, $24 \times 24 \text{ cm}$; TR/TE/TI, 9802/156/2300 ms; NEX, 1; section thickness, 5 mm; gap, 0.5 mm; imaging time, 2 minutes 18 seconds), fast spin-echo (FSE) T2 (matrix 512×256 ; field of view, $24 \times 24 \text{ cm}$; TR/TE, 7540/85.2 ms; NEX, 2; section thickness, 5 mm; gap, 0.5 mm; imaging time, 2 minutes 39 seconds), and a 3D fast-spoiled gradient echo T1-weighted sequence ($124 \times 1.4\text{-mm}$ axial sections; matrix, 256×256 ; field of view, $24 \times 24 \text{ cm}$; TR/TE, 12/2.1 ms; NEX, 1; imaging time, 2 minutes 39 seconds). Except for the 3D T1 acquisition, all follow-up images were acquired in the AC-PC plane to ensure section positioning similar to that of the initial MR examinations. All but 4 patients completed the entire MR follow-up protocol. The remaining 4 patients underwent our routine MR stroke protocol including 2D T1 in the sagittal plane,

DWI, FLAIR, and T2-gradient echo, whereas the FSE T2- and 3D-T1-weighted sequence were missing.

All initial and follow-up MR images were retrospectively analyzed simultaneously on a dual-screen workstation. Where necessary, follow-up images were reformatted in the same plane as the initial MR acquisitions. On each follow-up MR image, a single neuroradiologist (C.O.) looked for signal intensity changes or signs of atrophy in a region corresponding to the initial DWI abnormalities. Each lesion was classified as either (1) fully reversible, when no signal intensity changes or atrophy existed on any of the follow-up MR images, or (2) infarction, when signal intensity changes or focal atrophy was seen. Patients harboring multiple lesions with different outcomes were classed in the infarction group.

Statistical Analysis

Analyses were performed with the SPSS statistical package (SPSS, Chicago, Ill). Patients with a fully reversible DWI lesion were compared with the others for age, sex, duration of symptoms, proportion with symptoms lasting less than 60 minutes, number of lesions on initial DWI (solitary versus multiple), delay from TIA onset to initial and follow-up MR imaging using nonparametric tests, including a Mann-Whitney *U* test for continuous variables and a Fisher exact test for categorical variables. We then considered each lesion individually and compared fully reversible lesions with those associated with subsequent permanent tissue injury for the quantitative DWI parameters (DWI volume, absolute ADC, and rADC) using a nonparametric Mann-Whitney test. Because these parameters were likely to be linked with each other, we also looked for any such correlation by using a Pearson correlation test. Finally, a multivariate logistic regression was conducted for variables that reached $P > .05$ on the univariate analysis. All descriptive statistics are expressed as mean \pm SD unless specified otherwise.

Results

As detailed in Table 1, the 33 TIA patients with a positive initial DWI who underwent a follow-up MR imaging consisted of 23 men and 10 women with a mean age of 60.6 ± 16 years. TIA symptoms were recorded as follows: aphasia (51.5%), motor weakness (70%), sensory disturbances (48%), visual deficits (12%), brain stem symptoms (12%), and cerebellar symptoms (3%). Isolated amaurosis fugax was observed in 1 case. Initial MR imaging (delay from TIA onset to MR imaging, 30 ± 33 hours; median, 21 hours; range, 4 hours to 6 days) was obtained within 12 hours after the onset of TIA in 13 (39%) patients and within 24 hours in 21 (64%) patients. On initial DWI, lesions were solitary in 17 patients and multiple in 16 patients, with a total number of 59 lesions. Lesions were located in the anterior circulation in 22 patients, in the posterior circulation in 7 patients, and involved both of them in the remaining 4 patients. Forty-four lesions (74.6%) were cortical, and 15 (25.4%) were deeply located. Of the latter, there were 7 small and solitary DWI lesions, probably lacunar. On initial DWI, lesions were small (volume, $0.74 \pm 1.5 \text{ mL}$; range, 0.03–10.4 mL) and ADC was moderately decreased (rADC = $82 \pm 15\%$). There was a positive correlation between absolute ADC and rADC ($P < .001, r = 0.8$), whereas absolute ADC or rADC was negatively correlated with the initial DWI lesion volume ($r = -0.47$ and -0.52 , respectively; $P < .001$).

In the 33 patients with TIA, follow-up MR imaging detected no permanent injury in 7 cases and identified a subse-

Table 1: Characteristics of transient ischemic attack (TIA) patients with and without infarction on follow-up MR imaging (MRI)

	Reversible (<i>n</i> = 7)	Infarction (<i>n</i> = 26)	All Patients (<i>n</i> = 33)	<i>P</i> Value
Male, %	5 (71%)	18 (70%)	23 (69%)	1
Age, y (mean ± SD)	58 ± 15	61 ± 17	60 ± 16	.5
Symptoms				
Duration, min (mean ± SD)	76 ± 85	188 ± 253	201 ± 262	.2
Duration <60 min	3 (43%)	10 (38%)	13 (39%)	1
Multiple TIA events	3 (43%)	10 (38%)	13 (39%)	1
Identified cause, %	3 (43%)	12 (46%)	15 (45%)	1
Initial MRI				
Delay from onset MRI, h	21 ± 10	33 ± 36	30 ± 33	.9
Solitary lesions	6 (86%)	11 (42%)	17 (51.5%)	.08
Follow-up MRI				
Delay from onset MRI, mo	11.6 ± 3.1	10.4 ± 5.5	10.6 ± 5	.75

Note:—Patients with multiple lesions of different outcome are classed in the infarction group.

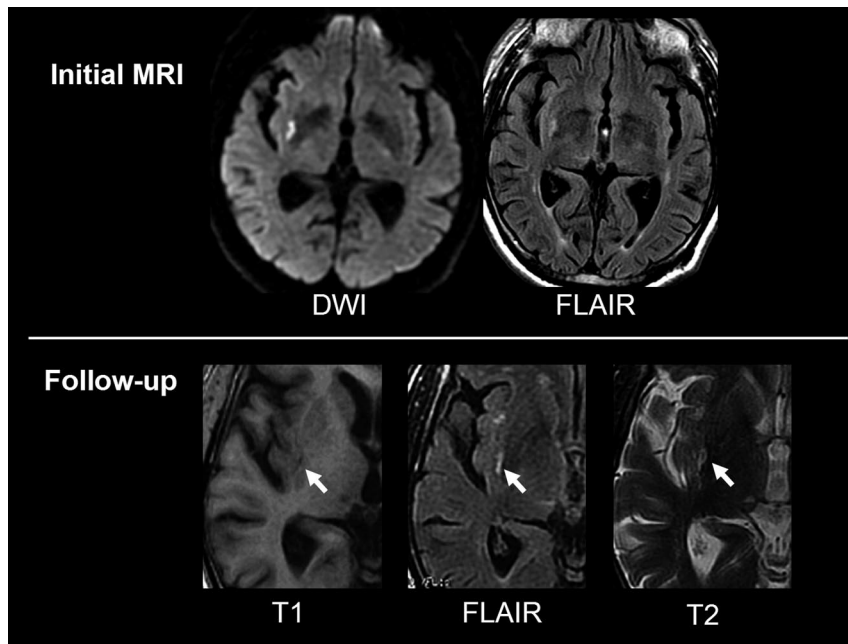


Fig 1. A 67-year-old man with a left sensory-motor deficit for 30 minutes. Initial MR imaging (3 days after onset) demonstrates a small DWI and FLAIR hyperintensity in the deep right middle cerebral artery (MCA) territory. On follow-up MR imaging (14 months after onset), focal signal intensity changes on all sequences indicate permanent injury in the corresponding area.

The characteristics of patients with TIA, according to the presence or absence of permanent injury on follow-up MR imaging, are presented in Table 1. None of the studied variables significantly differed between patients with fully reversible lesions and those with infarct. Patients with solitary lesions on initial DWI were more likely to be free of permanent injury than those with multiple lesions, though this difference did not reach statistical significance ($P = .08$). As detailed in Table 2, all quantitative MR parameters derived from the initial DWI differed significantly between the 2 groups of patients: the DWI volume

was significantly larger and the ADC values lower in lesions with subsequent infarction than in lesions that were fully reversible. Except for the absolute ADC, these differences remained significant when only lesions initially imaged within 24 hours were considered (DWI volume: $P = .02$; rADC: $P = .035$). Over the whole study group, half of the lesions with a DWI volume of less than 0.2 cm^3 ($n = 20$) were reversible, whereas only 10% regressed when their initial DWI volume exceeded this arbitrary threshold ($n = 39$). A multivariate logistic regression with rADC and DWI volume showed that only rADC remained significantly associated of tissue outcome ($P = .037$).

quent infarct in regions corresponding to the original DWI abnormalities in 26 (79.6%) patients (Figs 1–3). Of the 59 lesions initially identified on DWI, 45 (76.3%) were associated with permanent injury on follow-up MR imaging. If only lesions initially imaged within 12 ($n = 24$) or 24 hours ($n = 36$) were considered, the rates of permanent injury on follow-up MR imaging were 83.3% and 78%, respectively. Over the whole study group, the most typical MR hallmark of the 45 infarcts was bright signal intensity on follow-up FLAIR and T2-weighted sequences, and dark signal intensity on T1-weighted sequence with various degrees of focal atrophy. However, 5 lesions lacked signal intensity changes on FLAIR and/or conventional T2-weighted sequences and were identified solely because of focal atrophy or cortical bright spot on a T1-weighted sequence (Fig 4). Five additional cortical lesions were bright on FLAIR but not on FSE T2-weighted sequences. On DWI, most lesions were no longer visible, apart from 6 larger lesions that displayed a hypointense signal and 3 others associated with a T2 shine-through effect. Interestingly, in 1 patient, an additional, silent infarct was discovered in the cerebellum on MR follow-up. No patient had recent lesions seen as bright signal intensity on follow-up DWI.

was significantly larger and the ADC values lower in lesions with subsequent infarction than in lesions that were fully reversible. Except for the absolute ADC, these differences remained significant when only lesions initially imaged within 24 hours were considered (DWI volume: $P = .02$; rADC: $P = .035$). Over the whole study group, half of the lesions with a DWI volume of less than 0.2 cm^3 ($n = 20$) were reversible, whereas only 10% regressed when their initial DWI volume exceeded this arbitrary threshold ($n = 39$). A multivariate logistic regression with rADC and DWI volume showed that only rADC remained significantly associated of tissue outcome ($P = .037$).

Discussion

We found that 79.6% of TIA-related bright signals on initial DWI were the signature of established infarcts. To our knowledge, this is the first study to have focused on the long-term MR imaging outcome of TIA-related DWI lesions. Our results corroborate previous data obtained in a small subset of non-consecutive patients with TIA who all manifested a subsequent infarct in the region corresponding to the original DWI lesion.¹⁰ In line with this, subsequent infarction has also been

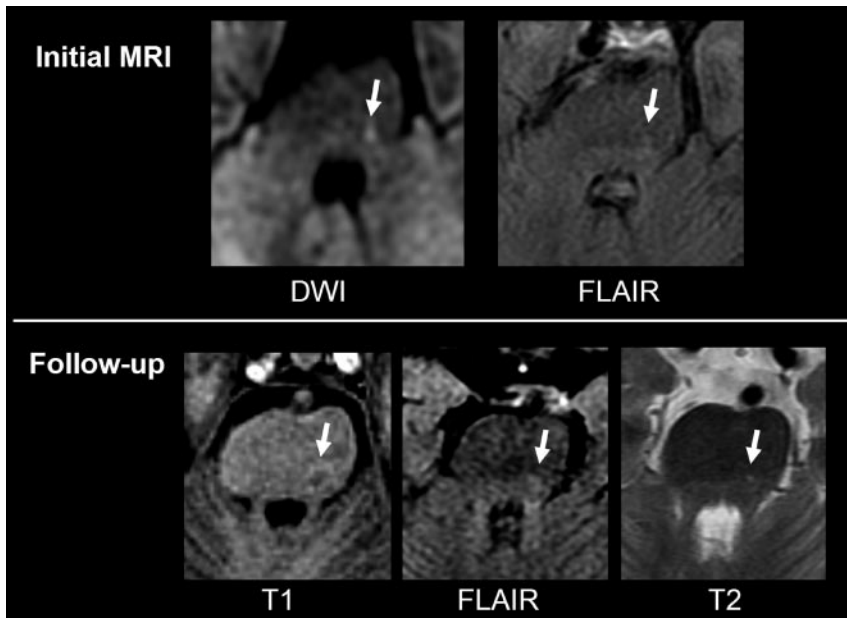


Fig 2. A 63-year-old man with a right sensory deficit for 10 hours. Initial MR imaging (63 hours after onset) demonstrates a focal DWI and FLAIR hyperintensity in the left brain stem (*arrow*). On follow-up MR imaging (6 months after onset), a small permanent injury can be seen as a dark signal intensity on T1-weighted sequence and a bright signal intensity on FLAIR/T2-weighted sequence in the corresponding area.

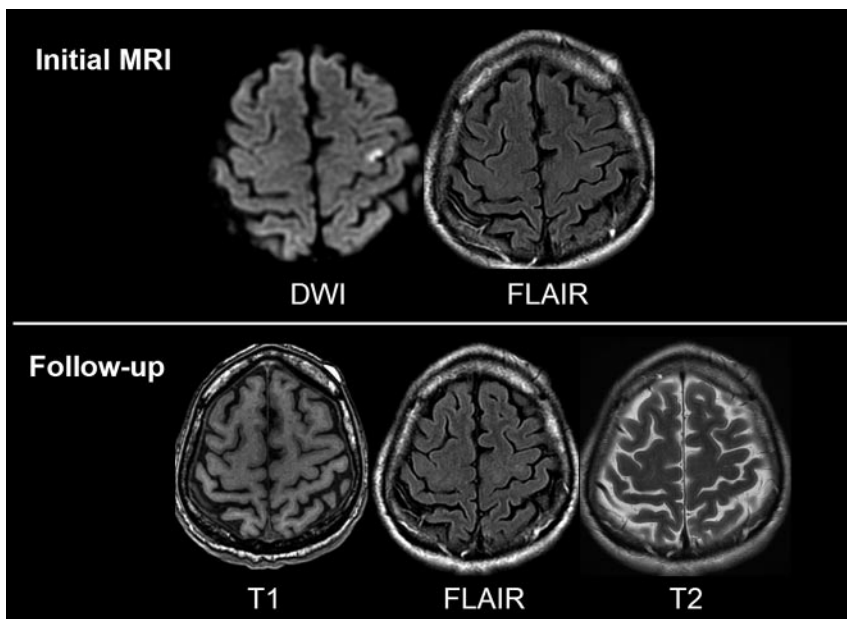


Fig 3. A 55-year-old man with sensory-motor deficit of the upper right limb for 90 minutes. Initial MR imaging (10 hours after onset) demonstrates a focal DWI hyperintensity with mild FLAIR signal intensity changes in the left primary motor cortex, matching clinical symptoms. On follow-up MR imaging (8 months after onset), no permanent injury can be identified.

reported in the subacute phase in a recent series of 11 patients.¹⁵ Our findings partially contradict the fact that approximately half of the TIA-related DWI abnormalities may be fully reversible. However, the latter findings were based on follow-up images obtained in 9 nonconsecutive TIAs.⁴ Along similar lines, others have advocated that the low rate (14%) of DWI-positive findings at the subacute stage of TIA suggests that most of these lesions do not persist after 2 weeks.⁵

The outcome of TIA-related brain lesions can be expected to be linked to several parameters, such as the duration of symptoms and those reflecting the severity of brain ischemia.² Prolonged symptoms imply a prolonged decrease in brain perfusion and may thus be associated with a higher risk of subsequent infarction. Therefore, several previous CT or conventional MR studies have suggested an association between the duration of TIA symptoms and the development of a subsequent infarct, with the probability of infarct increasing with

the duration of symptoms.^{17,18} In line with this is the shorter duration of symptoms in our patients with fully reversible DWI lesions (mean \pm SD, 76 ± 85 minutes) than in those with subsequent infarction (188 ± 253 minutes), though the difference did not reach statistical significance. Because the severity of ischemia may be reflected by the ADC, we expected ADC measurements at the acute stage to be predictive of tissue outcome in TIAs. In acute stroke, tissue with a marked ADC decrease often evolves toward infarction, whereas moderate ADC changes have been shown to be associated with reversible ischemic injury.^{19,20} Like others,^{4,6,21} we found that TIA-related ADC decrease is moderate compared with that of stroke patients. Furthermore, our data suggest that ADC values measured in the core of the initial DWI lesion may be predictive of long-term tissue outcome. Indeed, the initial ADC decrease was significantly more severe in lesions that evolved toward infarction than in those that were reversible (rADC = 79%

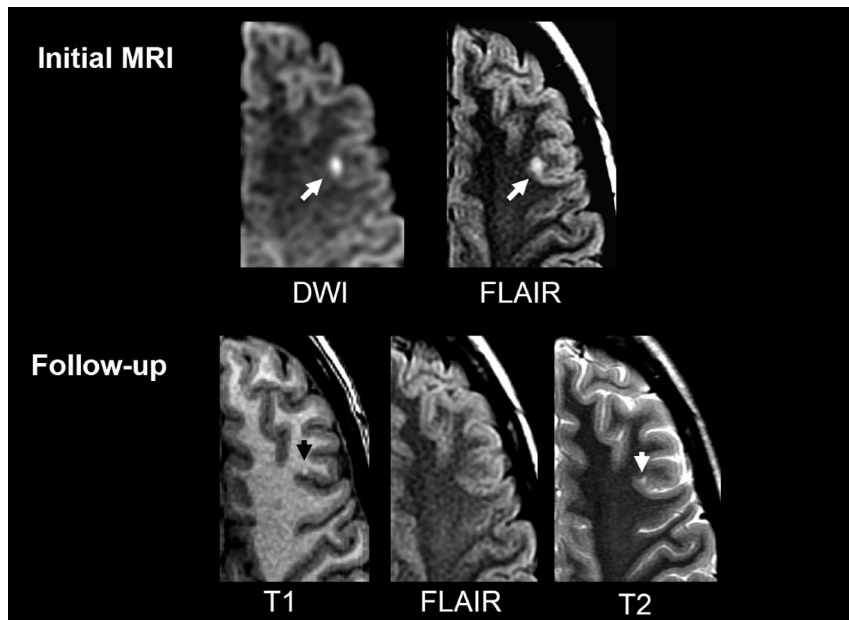


Fig 4. A 21-year-old woman with a right sensory-motor deficit and aphasia for 60 minutes. Initial MR imaging (4 days after onset) shows a punctate cortical DWI/FLAIR hyperintensity in the left superficial middle cerebral artery (MCA) territory. On follow-up MR imaging (15 months after onset), a small permanent injury can be seen as a bright cortical dot on T1-weighted sequence with mild atrophy on T2-weighted sequence. Note that no signal intensity change is seen on FLAIR.

result of a complete follow-up MR procedure that included T2-weighted sequences and 3D T1-weighted sequences with a millimeter resolution. Follow-up CT or T2-weighted sequences may thus be insufficient to be able to rule out small infarctions; this methodologic point could partly explain the higher rate of TIA patients with fully reversible DWI lesions previously reported.⁴ Using high-field MR units to increase spatial resolution or measuring the cortical thickness on 3D inversion-recovery pulse sequence may improve the detection of focal atrophy.

Our study is subject to some limitations. First, although this is the largest series of consecutive patients with TIA with long-term MR follow-up, the relatively small size of the study group may explain why we did not find a significant association between the duration of TIA symptoms and the risk of permanent injury. Second, in some patients with TIA with initial negative DWI, we might have missed rapidly reversible DWI abnormalities. Indeed, cases studies have previously shown the reversibility of TIA-associated DWI lesion in patients imaged soon after onset.^{13,14} By selecting patients based on a positive initial DWI, some of which were obtained 1 day or longer after onset, we might have introduced a selection bias, which could result in a study group of patients who are more likely to have irreversible lesions. However, we did not find a significant difference in the delay from onset-to-initial DWI between our TIA patients with reversible and irreversible lesions. Moreover, the rate of irreversible lesions over the whole population and the rate computed on lesions initially imaged within the first 12 or 24 hours were remarkably similar. This suggests that the timing of initial MR imaging is not a key parameter to predict subsequent tissue outcome. Third, the study design resulted in variations in the timing of follow-up imaging with respect to initial symptoms. Given the fact that the signal intensity of ischemic lesion evolves with time, one could argue that MR examinations obtained at different points in the time course do not have the same sensitivity for identifying permanent tissue injury. However, there was no significant difference for this parameter between patients with and patients without permanent injury. Last, the ADC values in small DWI lesions are likely to be contaminated by partial volume effects with the adjacent normal parenchyma. This confound could partially account for the higher ADC values associated with small DWI lesions.

Conclusions

The long-term MR follow-up of 33 consecutive DWI-positive TIA patients suggests that initial signal intensity changes most

Table 2: Quantitative diffusion-weighted MR imaging (DWI)-derived variables of the 59 transient ischemic attack (TIA) lesions according to imaging outcome

	Reversible (n = 14)	Infarction (n = 45)	P Value
DWI volume, cm ³ (mean ± SD)	0.21 ± 0.21	0.91 ± 1.7	.003
Absolute ADC, 10 ⁻⁶ mm ² /s (mean ± SD)	722 ± 118	631 ± 135	.022
rADC (mean ± SD)	91 ± 9%	79 ± 15%	.001

Note:—rADC corresponds to apparent diffusion coefficient (ADC) within the TIA lesion divided by the mirror ADC value.

versus 91%). The rather subtle ADC decrease seen in reversible lesions may correspond to a mild ischemia that does not cause advanced bioenergetic failure and subsequent permanent tissue injury.² Similar ADC changes have also been reported in association with reversal of DWI hyperintensities after extremely rapid reperfusion in acute stroke.^{22,23} Also consistent with this are the experimental data showing that adenosine triphosphate depletion with subsequent neuronal death occurs only in association with an ADC reduction of more than 10%.^{20,22}

A larger volume on initial DWI was also predictive of subsequent tissue injury. However, care should be taken before concluding that small DWI lesions are fully reversible. It is not known whether there are histopathologic changes corresponding to these reversible DWI lesions in patients with transient deficit. We thus cannot exclude the possibility that patients with normal follow-up imaging results may in fact have permanent injury that is too small to be detected by MR imaging.²⁴ At the acute stage, the detection of punctate lesions benefits from the high lesion-to-background signal intensity ratio on DWI. This is no longer true at the chronic stage, when signal intensity changes on T2-weighted or T1-weighted sequences are mild or absent, especially when lesions are in the vicinity of the CSF. When mainly atrophic and lacking T2-signal intensity changes, some infarcts may hardly be visible,¹⁴ even if comparison with the initial DWI is available for analysis.¹⁰ The high rate of permanent injury that we found was the

often reflect permanent tissue injury. The extent and severity of ischemia, as reflected by initial DWI volume or ADC decrease, seem to be the underlying physiologic factors that are most relevant for predicting evolution toward infarction. By showing that most DWI-positive TIAs share the same imaging outcome as stroke patients, our data provide additional support for the redefinition of TIA, which considers that all cases of transient deficit with characteristic neuroimaging abnormalities should be diagnosed as a stroke.³

References

- Gass A, Ay H, Szabo K, et al. Diffusion-weighted MRI for the "small stuff": the details of acute cerebral ischaemia. *Lancet Neurol* 2004;3:39–45
- Saver JL, Kidwell C. Neuroimaging in TIAs. *Neurology* 2004;62:S22–25
- Albers GW, Caplan LR, Easton JD, et al. Transient ischemic attack-proposal for a new definition. *N Engl J Med* 2002;347:1713–16
- Kidwell CS, Alger JR, Di Salle F, et al. Diffusion MRI in patients with transient ischemic attacks. *Stroke* 1999;30:1174–80
- Schulz UG, Briley D, Meagher T, et al. Abnormalities on diffusion weighted magnetic resonance imaging performed several weeks after a minor stroke or transient ischaemic attack. *J Neurol Neurosurg Psychiatry* 2003;74:734–38
- Winbeck K, Bruckmaier K, Etgen T, et al. Transient ischemic attack and stroke can be differentiated by analyzing early diffusion-weighted imaging signal intensity changes. *Stroke* 2004;35:1095–99
- Ay H, Oliveira-Filho J, Buonanno FS, et al. 'Footprints' of transient ischemic attacks: a diffusion-weighted MRI study. *Cerebrovasc Dis* 2002;14:177–86
- Inatomi Y, Kimura K, Yonehara T, et al. DWI abnormalities and clinical characteristics in TIA patients. *Neurology* 2004;62:376–80
- Engelter ST, Provenzale JM, Petrella JR, et al. Diffusion MR imaging and transient ischemic attacks. *Stroke* 1999;30:2762–63
- Rovira A, Rovira-Gols A, Pedraza S, et al. Diffusion-weighted MR imaging in the acute phase of transient ischemic attacks. *AJNR Am J Neuroradiol* 2002;23:77–83
- Crisostomo RA, Garcia MM, Tong DC. Detection of diffusion-weighted MRI abnormalities in patients with transient ischemic attack: correlation with clinical characteristics. *Stroke* 2003;34:932–37
- Ay H, Koroshetz WJ, Benner T, et al. Transient ischemic attack with infarction: a unique syndrome? *Ann Neurol* 2005;57:679–86
- Lecouvet FE, Duprez TP, Raymackers JM, et al. Resolution of early diffusion-weighted and FLAIR MRI abnormalities in a patient with TIA. *Neurology* 1999;52:1085–87
- Neumann-Haefelin T, Wittsack HJ, Wenserski F, et al. Diffusion- and perfusion-weighted MRI in a patient with a prolonged reversible ischaemic neurological deficit. *Neuroradiology* 2000;42:444–47
- Inatomi Y, Kimura K, Yonehara T, et al. Hyperacute diffusion-weighted imaging abnormalities in transient ischemic attack patients signify irreversible ischemic infarction. *Cerebrovasc Dis* 2005;19:362–68
- Adams H, Bendixen B, Kappelle L, et al. Classification of subtypes of acute ischemic stroke. Definition for use in multicenter clinical trial. *Stroke* 1993;24:35–41
- Bogousslavsky J, Regli F. Cerebral infarct in apparent transient ischemic attack. *Neurology* 1985;35:1501–03
- Awad I, Modic M, Little JR, et al. Focal parenchymal lesions in transient ischemic attacks: correlation of computed tomography and magnetic resonance imaging. *Stroke* 1986;17:399–403
- Oppenheim C, Grandin C, Samson Y, et al. Is there an apparent diffusion coefficient threshold in predicting tissue viability in hyperacute stroke? *Stroke* 2001;32:2486–91
- Back T, Hoehn-Berlage M, Kohno K, et al. Diffusion nuclear magnetic resonance imaging in experimental stroke: correlation with cerebral metabolites. *Stroke* 1994;25:494–500
- Kamal AK, Segal AZ, Ulug AM. Quantitative diffusion-weighted MR imaging in transient ischemic attacks. *AJNR Am J Neuroradiol* 2002;23:1533–38
- Rother J, de Crespigny AJ, D'Arceuil H, et al. Recovery of apparent diffusion coefficient after ischemia-induced spreading depression relates to cerebral perfusion gradient. *Stroke* 1996;27:980–86; discussion 986–87
- Fiehler J, Kucinski T, Knudsen K, et al. Are time-dependent differences in diffusion and perfusion within the first 6 hours after stroke onset? *Stroke* 2004;35:2099–104
- Marx JJ, Mika-Gruettner A, Thoenke F, et al. Diffusion weighted magnetic resonance imaging in the diagnosis of reversible ischaemic deficits of the brainstem. *J Neurol Neurosurg Psychiatry* 2002;72:572–75