

CASE REPORT

Open Access



A rare case report of late-onset phytobezoar formation following laparoscopic sleeve gastrectomy: delayed redo bariatric surgery

Shayan Aryannezhad¹, Yasaman Sadeghian¹, Parvin Shapoori², Majid Valizadeh¹ and Maryam Barzin^{1*}

Abstract

Background: Phytobezoar formation is a complication of bariatric surgery and mostly occurs after laparoscopic Roux-en-Y gastric bypass (LRYGB) operations. Here, we present an extremely rare case of late phytobezoar formation following laparoscopic sleeve gastrectomy (LSG).

Case presentation: A 52-year-old woman with a body mass index (BMI) of 40.7 kg/m² underwent LSG. Following persistent symptoms of nausea, vomiting, early satiety, and tremendous weight loss, endoscopy was performed, and gastric phytobezoar was detected at one-year post-operation. After endoscopic fragmentation, phytobezoar was removed by snare, and the patient later underwent redo bariatric surgery (conversion of LSG to LRYGB).

Conclusions: With an increase in the number of LSG procedures performed globally, and the late-onset nature of phytobezoar formation, more cases of this complication are expected to be detected in future. Long-term postoperative follow-up alongside applying surgical methods to avoid gastric stenosis are needed to reduce the chance of phytobezoar formation in patients undergoing LSG.

Keywords: Bariatric surgery, Bezoars, Gastrectomy, COVID-19, Case report

Background

Bezoars, which are intraluminal hard masses or concretions in the gastrointestinal (GI) system caused by the accumulation of indigestible ingested materials, are most commonly found in the stomach. Phytobezoars, as fiber-rich residues of vegetables and fruits, are the most common types of bezoars [1]. The etiology of phytobezoar formation is multifactorial encompassing both personal (e.g., consumption of high amounts of fibrous foods, gastric motility disorders) and anatomical (e.g., GI tract obstruction due to strictures, diverticulum, or tumors) factors [2]. The most common complications of phytobezoars are gastric ulceration and intestinal obstruction;

they can also be asymptomatic or present with a variety of GI symptoms [3].

Bariatric surgery has been proposed as the best available strategy to treat morbid obesity. Laparoscopic Roux-en-Y gastric bypass (LRYGB) and laparoscopic sleeve gastrectomy (LSG) are the two most frequently performed procedures today. Currently LSG has more favorable outcomes and is considered as an effective primary bariatric surgery [4]. While generally considered to be safe, bariatric operations permanently alter the patient's GI anatomy and, may lead to postoperative complications [5].

Moreover, the patients undergoing bariatric surgery are at the risk of the formation of phytobezoars due to reduced gastric motility, loss of pyloric function, hypoa-cidity, having a small gastric pouch, and most importantly, GI tract stenosis and strictures. Phytobezoars following bariatric surgery are mostly reported after

*Correspondence: m.barzin7@gmail.com

¹ Obesity Research Center, Research Institute for Endocrine Sciences, Shahid Beheshti University of Medical Sciences, Tehran, Iran
Full list of author information is available at the end of the article



LRYGB operations. LSG, preserves pyloric function, so extremely rare cases of phytobezoar formation post-LSG are mainly attributed to gastric stricture, especially in the incisura [6]. We here report a case of late phytobezoar formation after LSG, which required the patient to be re-operated.

Case presentation

A 52-year-old woman with a body mass index (BMI) of 40.7 kg/m^2 , without any underlying comorbidity or history of past surgeries, was referred for LSG. Two weeks prior to the operation, endoscopy was performed, which revealed the signs of minimal gastro esophageal reflux disease (GERD) in the esophagus and stomach, as well as *Helicobacter pylori* infection. The patient received appropriate treatments for these problems. She was a participant of the Tehran Obesity Treatment Study (TOTS) [7]. LSG was performed in August 2019, followed by normal post-operation recovery and routine nutritional consult at discharge [8]. In brief, the LSG procedure was performed by excision of 80% of the stomach. Using several stapler firings, the gastric tube was formed over a 36-F bougie and reinforced with running sutures and an omental pouch. At one-month post-operation, she experienced nausea, vomiting, and early satiety. She also had attempts for self-induced vomiting. The percentage of excess weight loss (EWL%) was 24.0%, and BMI reduced to 36.9 kg/m^2 . Antacid therapy (Pantoprazole) was initiated. At three-month post-operation (EWL% = 63.8%, BMI = 30.7 kg/m^2), due to the persistence of the patient's complaints, endoscopy was performed, which showed mild antral gastritis and GERD (grade B). She was advised to continue antacid therapy and refer for follow-up visits. Due to the persistence of her symptoms, barium meal (upper GI series) was performed, which indicated incisura stricture (Fig. 1 A). Therefore, she became a candidate for redo bariatric surgery. However, due to the Coronavirus disease (COVID-19) lockdown, she was unable to refer on time, and her follow-up nutritional assessments were not held as TOTS's routine protocol [8]. After one year of the operation, she returned with significant weight loss (EWL% = 95.5%, BMI = 25.7 kg/m^2) and the continuation of previous symptoms. So, she underwent endoscopy again, which showed medium-sized sliding hiatus hernia, large gastric phytobezoar in the body of the stomach, and suspicious rotation of antrum anatomy. Upon follow-up questioning, the patient reported routine consumption of raisins, seeds, and plums in her dietary habits. Following the consumption of oral Coca-Cola® drink for three days, another endoscopy was performed. The phytobezoar's size was reduced, and after fragmentation, it was removed by snare (Fig. 1B). Afterwards, control endoscopy showed

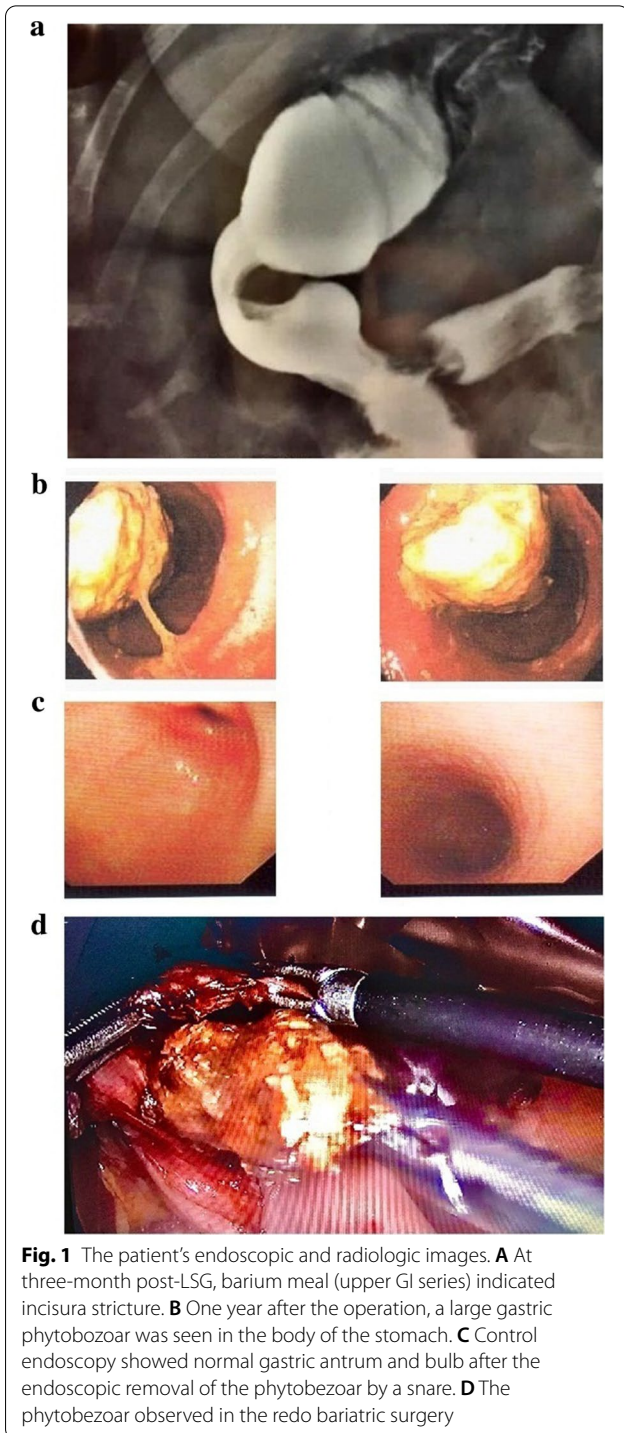


Fig. 1 The patient's endoscopic and radiologic images. **A** At three-month post-LSG, barium meal (upper GI series) indicated incisura stricture. **B** One year after the operation, a large gastric phytobezoar was seen in the body of the stomach. **C** Control endoscopy showed normal gastric antrum and bulb after the endoscopic removal of the phytobezoar by a snare. **D** The phytobezoar observed in the redo bariatric surgery

a normal stomach without any phytobezoar (Fig. 1 C). However, her symptoms persisted, and following the previous diagnosis of incisura stricture, she underwent redo bariatric surgery (conversion of LSG to LRYGB) in November 2020 (EWL% = 98%, BMI = 25.0 kg/m^2). Incisura stricture and phytobezoar were observed during

operation (Fig. 1D). After the surgery, the patient experienced severe bleeding from the drain site, which led to the transfusion of packed red cells. She was then stabilized, recovered, and discharged four days after the operation. She easily progressed toward consuming a regular diet. At one-month post-LRYGB, she had a good general condition and no symptoms.

Discussion and conclusion

As the number of bariatric surgeries is increasing globally, it is important to inform surgeons and physicians about the possible complications of these surgeries. Clinicians should be aware of phytobezoar's symptoms and signs particularly because this rare complication is prone to be neglected as it occurs late in post-operative period. Previous literature implies that bezoars happen mainly after LRYGB surgeries, but they are rare following LSG [6, 9–11]. As LSG is a bariatric procedure with a rising popularity, and phytobezoar formation can occur several years after the operation, more cases of post-LSG phytobezoar formation are expected to be reported in the future.

Prior gastrectomy has been proposed as the main risk factor of bezoar formation [12]. LRYGB delays gastric emptying and slows down the intestinal transit time, and include GI anastomosis which increases stricture risk [6]. Even though LSG procedure does not include a GI tract anastomosis, it alters gastric motility and acidity, and in combination with incisura stricture, it may exaggerate the risk of bezoar formation, which may be the case of our patient. From March 2013 to August 2019, this was the first report of phytobezoar formation among 2905 cases of LSG, 1155 cases of laparoscopic mini gastric bypass, and 169 cases of LRYGB in TOTS subjects (incidence rate: 0.02%).

Treatment options of bezoars should be tailored to the patient's condition. Consuming chemical solvents should always be considered as a first-line option because it is noninvasive and inexpensive. Endoscopic therapy after fragmenting the bezoar should be considered next. However, due to limitations of endoscope probe maneuvers in a sleeved stomach, even a normal endoscopic view cannot confidently guarantee bezoar removal, as happened in our case. Therefore, surgical removal should be reserved for patients with persistent symptoms, non-respondents to less invasive treatments, and those who suffer from anatomical defects (e.g., incisura stricture). In our experience, the patient underwent both chemical dissolution therapy by drinking Coca-Cola® and endoscopic fragmentation and removal by a snare, but surgery was performed as the final treatment.

Phytobezoars can appear even years after bariatric surgeries such as LSG and LRYGB. Thus, it is essential

to emphasize the importance of long-term follow-up in these patients. Clinicians must bear in mind gastric stricture as a possible postoperative complication, especially in the patients presenting with recurrent phytobezoars. In order to reduce the risk of phytobezoars, the surgical team performing LSG must consider preventive strategies to avoid gastric stenosis (i.e., incisura stricture), unintentional narrowing of the stomach (tubular diameter), and helical twist of tabularized stomach.

Abbreviations

LRYGB: Laparoscopic Roux-en-Y gastric bypass; LSG: Laparoscopic sleeve gastrectomy; BMI: Body mass index; GI: Gastrointestinal; GERD: Gastro esophageal reflux disease; EWL: Excess weight loss.

Acknowledgements

Not applicable.

Authors' contributions

SA: Data collection, manuscript preparation, revising the manuscript. YS: Data collection, manuscript preparation, revising the manuscript. PS: Study design, Patient's surgery, manuscript preparation, final approval of the manuscript. MV: Final approval of the manuscript. MB: Study design, patient's coordinator, manuscript preparation, final approval of the manuscript. All authors have read and approved the final manuscript.

Funding

No funding was obtained for this study.

Availability of data and materials

Data sharing not applicable to this article as no datasets were generated or analyzed during the current study.

Declarations

Ethics approval and consent to participate

The surgery was a standard procedure, and the patient was well informed of the operation risk. The patient was informed that treatment results are included in study analysis while patient's personal information will not be shared. Ethics approval was obtained from the ethics committee of Shahid Beheshti University of Medical Sciences.

Consent for publication

Written consent for publication was obtained from the patient for information and medical images about the patient herself. The patient also understands that the text and any pictures will be freely available on the internet and may be seen by the general public.

Competing interests

The authors have no conflicts of interest to disclose.

Author details

¹Obesity Research Center, Research Institute for Endocrine Sciences, Shahid Beheshti University of Medical Sciences, Tehran, Iran. ²Department of Surgery, Faculty of Medicine, Tehran Obesity Treatment Center, Shahed University, Tehran, Iran.

Received: 9 March 2021 Accepted: 17 May 2021

Published online: 22 May 2021

References

- Andrus CH, Ponsky JL. Bezoars: classification, pathophysiology, and treatment. *Am J Gastroenterol*. 1988;83(5):476–8.

2. Dikicier E, Altintoprak F, Ozkan OV, Yagmurkaya O, Uzunoglu MY. Intestinal obstruction due to phytobezoars: An update. *World J Clin Cases*. 2015;3(8):721–6.
3. Iwamuro M, Okada H, Matsueda K, Inaba T, Kusumoto C, Imagawa A, et al. Review of the diagnosis and management of gastrointestinal bezoars. *World J Gastrointest Endosc*. 2015;7(4):336–45.
4. Abraham A, Ikramuddin S, Jahansouz C, Arafat F, Hevelone N, Leslie D. Trends in bariatric surgery: procedure selection, revisional surgeries, and readmissions. *Obes Surg*. 2016;26(7):1371–7.
5. Lim R, Beekley A, Johnson DC, Davis KA. Early and late complications of bariatric operation. *Trauma Surg Acute Care Open*. 2018;3(1):e000219.
6. Ben-Porat T, Sherf Dagan S, Goldensluger A, Yuval JB, Elazary R. Gastrointestinal phytobezoar following bariatric surgery: systematic review. *Surg Obes Relat Dis*. 2016;12(9):1747–54.
7. Barzin M, Hosseinpanah F, Motamedi MA, Shapoori P, Arian P, Daneshpour MA, et al. Bariatric surgery for morbid obesity: Tehran Obesity Treatment Study (TOTS) rationale and study design. *JMIR Res Protoc*. 2016;5(1):e8.
8. Hosseini-Esfahani F, Khalaj A, Valizadeh M, Azizi F, Barzin M, Mirmiran P. Nutrient Intake and deficiency of patients 1 year after bariatric surgery: Tehran Obesity Treatment Study (TOTS). *J Gastrointest Surg*. 2021;25(4):911–8.
9. Ben-Porat T, Elazary R, Goldensluger A, Sherf-Dagan S, Grinbaum R, Beglaibter N. Phytobezoar: a rare late complication following laparoscopic sleeve gastrectomy surgery. *Int Surg J*. 2017;4(5):1803–5.
10. Arsalan O, Hussein A, El Malik S. A case of antroduodenal phytobezoar following laparoscopic sleeve gastrectomy. *Hamdan Med J*. 2014;7(1):117–20.
11. Martines G, Musa N, Aquilino F, Picciariello A, Altomare DF. Sleeve gastrectomy combined with Nissen fundoplication as a single surgical procedure, is it really safe? A case report. *Am J Case Rep*. 2020;21:e923543-e.
12. Cain GD, Moore P, Patterson M. Bezoars—a complication of the postgastrectomy state. *Am J Digest Dis*. 1968;13(9):801–9.

Publisher's Note

Springer Nature remains neutral with regard to jurisdictional claims in published maps and institutional affiliations.

Ready to submit your research? Choose BMC and benefit from:

- fast, convenient online submission
- thorough peer review by experienced researchers in your field
- rapid publication on acceptance
- support for research data, including large and complex data types
- gold Open Access which fosters wider collaboration and increased citations
- maximum visibility for your research: over 100M website views per year

At BMC, research is always in progress.

Learn more biomedcentral.com/submissions

