

# Treatment of Vertebrobasilar Occlusion by Using a Coronary Waterjet Thrombectomy Device: A Pilot Study

Thomas E. Mayer, Gerhard F. Hamann, Gernot Schulte-Altedorneburg, and Hartmut Brückmann

**BACKGROUND AND PURPOSE:** Despite improved patient outcomes because of intraarterial fibrinolysis, vertebrobasilar thromboembolism remains a fatal disease with a death rate of more than 50%. The outcome depends on the success of recanalization. Fibrinolysis achieves recanalization in only 50%–70% of the cases. Therefore, we investigated the feasibility of using a coronary mechanical device to increase the recanalization rate.

**METHODS:** Twelve patients with acute vertebrobasilar occlusion were included in the pilot study. The older 5F and the new 4F versions of the Possis Angiojet catheter, which use a waterjet to attract, fragment, and extract the thrombus, were used. Inclusion depended on the presence of acute multisegmental intracranial or any extracranial vertebrobasilar occlusion. Exclusion criteria included coma lasting >8 hours and age >80. The Angiojet treatment did not exclude other therapeutic options.

**RESULTS:** The Angiojet catheter accessed the thrombosed site in 10 of 12 patients. Combined treatment with the Angiojet and additional fibrinolysis or angioplasty resulted in a recanalization rate of 100%. Of 37 occluded vertebrobasilar segments, 30 were primarily recanalized with the Angiojet. Three symptomatic and two asymptomatic hemorrhages were detected by CT. Five of the 12 patients died. Fifty percent of all patients obtained a moderate to excellent outcome (Modified Rankin Scale 0–3).

**CONCLUSIONS:** Use of the coronary Angiojet in the vertebrobasilar system is feasible. The device has the potential to increase the recanalization rate, especially in cases of extensive thrombosis, and, thus, improve patient outcomes.

Intraarterial fibrinolysis has improved outcomes of patients with vertebrobasilar occlusion (VBO) by increasing the survival rate from 10%–15% (1–3) to about 30%–45%, excluding the highest and lowest values (2, 4–12). A major drawback of thrombolysis to restore posterior cerebral circulation, however, is the possibility of intracerebral hematomas, which occur in 0%–15% of cases (2, 4–13). Moreover, fibrinolysis is time-consuming, thus prolonging brain ischemia until recanalization is achieved. Previous studies reported that recanalization increases survival rates to 45%–55% after thrombolysis (2, 4, 6–12), also excluding the highest and lowest values; but recanalization rates range between only 50% and 75%, ex-

cluding the highest and lowest values (2, 4–13). In addition, recanalization by thrombolysis depends on the consistency, mass, and length of the clot, as well as the number of occluded segments—top of the basilar artery (BA), middle of the BA, caudal BA, and intracranial vertebral artery (VA), according to Archer and Horenstein (1). If more than two segments are occluded, the recanalization rate already drops to as low as 19% (7, 8, 11). Caudal BA occlusions often involve three or more segments, and rethrombosis may occur shortly after fibrinolysis, if the underlying vertebrobasilar arteriosclerotic stenosis remains untreated.

Therefore, we sought a device that was sufficiently flexible for neurovascular use to extract large thrombus masses and that would also help to accelerate the process of recanalization. Of the commercially available clot busters, the Angiojet (Possis Medical, Minneapolis, MN), a rheolytic device based on the Bernoulli effect, seemed to be the most flexible available. It has been successfully used to recanalize acutely occluded coronary arteries (14), limb arteries (15), bypasses (16), hemodialysis grafts (17), and pulmo-

Received April 6, 2004; accepted December 24.

From the Departments of Neuroradiology (T.E.M., G.S.-A., H.B.) and Neurology (G.F.H.), Klinikum Grosshadern, University of Munich, Germany; and the Department of Neurology (G.F.H.), Dr. Horst Schmidt Klinik, Wiesbaden, Germany.

Address correspondence to Thomas E. Mayer, MD, Department of Neuroradiology, Klinikum Grosshadern, Marchioninistrasse 15, D-81377 Munich, Germany.

nary arteries (18). Successful recanalizations of three cervical carotid arteries and five dural sinuses have also been reported (19–23). In this prospective study, we investigated the feasibility of using the coronary Angiojet in acute VBO.

## Methods

### *Patients*

From March 1999 through October 2003, consecutive patients having acute extensive VBO with progressive brain stem stroke were included in a prospective single-center study to evaluate the off-label use of the coronary Angiojet rheolytic catheter. Inclusion criteria included occlusion of multiple intracranial vertebrobasilar segments, an occlusion site in the extracranial VA confirmed by intraarterial angiography, and a diameter of >2 mm in the vessel to be treated. The institutional ethics committee approved the study. Treatment with the Angiojet rheolytic system was initiated after obtaining the informed written consent of the patient, if possible, or of the relatives.

Patients were excluded from the study if their coma had lasted >8 hours before treatment or if the patient was >80 years of age. Further exclusion criteria for the use of the Angiojet were an acute intracerebral hematoma and extensive brain stem or thalamic infarction detected by CT or MR.

### *Device*

The Possis Angiojet consists of a high-pressure pulsatile pump that is connected with a 4F coronary catheter XMI (used in five patients) or a 5F catheter LF 140 (used in seven patients). The Angiojet catheter has a small-caliber, stainless steel tip and high-pressure tubing. It is based on the principle of Bernoulli, according to which high-speed saline jets create a low-pressure region at the tip. This low-pressure zone pulls the thrombus from the artery. Once inside the jet, the thrombus is fragmented into particles smaller than erythrocytes and is evacuated through the device's larger lumen, as described elsewhere (24, 25).

The stiffness of the coronary Angiojet afforded a proximally stronger supporting (coronary) microwire instead of the more floppy neurovascular microwires (Choice PT extra support 0.014 inch; Boston Scientific, Natick, MA).

### *Technique*

All procedures were performed under systemic heparinization with an activated clotting time (ACT) of about 200–250 seconds. Intracranial acute VBO was confirmed by a four-vessel angiography including both the VA and the carotid artery. A 6F guiding catheter was placed proximal to the atlas loop of the VA. A floppy microwire (Transend 10; Boston Scientific) and a microcatheter (Prowler 10; Cordis Johnson & Johnson, Miami, FL) were advanced through the thrombus to verify the extension of the occlusion by a subsequent selective angiography. A 3-meter-long Choice PT extra support microwire was introduced, which caused a straightening of the first atlas loop; the microcatheter was removed, and finally the Angiojet was inserted into the distal VA. Then, one or two passes (first, from proximal to distal, and, second, distal to proximal) with the Angiojet were performed at a rate of 1–2 mm/s.

Altogether, the preparation of the Angiojet system, introduction of the microcatheter, exchange of the microwire, and introduction of the Angiojet catheter took about 30 minutes. Additional fibrinolysis by recombinant tissue plasminogen activator (rt-PA) and the administration of a GP-IIb/IIIa platelet receptor inhibitor (tirofiban) were allowed. Intracranial stenoses, which could cause rethrombosis, could be treated by bal-

loon or stent angioplasty (2.5–4-mm coronary stent; Medtronic, Santa Rosa, CA).

### *Evaluation*

Vessel patency was measured by the thrombolysis in myocardial infarction (TIMI) score: TIMI 0 (no perfusion), TIMI 1 (penetration without perfusion), TIMI 2 (partial perfusion), TIMI 3 (complete perfusion). Occlusion was defined as TIMI 0 or 1, and patency as TIMI 2 or 3.

Procedure-related complications were defined as vessel injury (dissection or rupture). Pre- and postprocedural brain CT scans were regularly performed in all patients. Additional MR imagings were performed in four patients before and in seven patients after treatment. MR images and CT scans were examined for the presence and size of any related ischemic changes or hemorrhage.

The initial neurologic status before the endovascular treatment was rated by an experienced vascular neurologist by using the National Institutes of Health stroke scale and the Glasgow coma scale. Clinical outcome was measured by using the modified Rankin scale (MR spectroscopy) at 90 days post-treatment by an independent, experienced neurologist who was not blinded to the type of treatment.

## Results

Twelve patients with acute occlusions of the VA or BA (three women and nine men; mean age, 56 years; range, 40–73 years) met the inclusion criteria. Eleven patients had had an acute, severely progressive brain stem stroke 5–216 hours (this time window was irrelevant for inclusion) before the endovascular procedure; seven of them had been in a coma for 3–8 hours (only the duration of coma was relevant for inclusion).

### *Angiographic and Interventional Findings*

The location and extensiveness of the VBO are summarized in Table 1; for an illustrative case, see Figs 1–6.

A total of 37 vertebrobasilar vessel segments were occluded in the 12 patients, and all were recanalized. This resulted in a recanalization rate of 100% for the combined endovascular treatment. Initially more than three vessel segments were thrombosed per patient.

Access to the occlusion site was achieved in 10 patients by using the Angiojet. In nine of these 10 patients and in 30 of the total 31 occluded vessel segments, the thrombus could be completely removed by the Angiojet alone. Recanalization with the Angiojet failed in one segment of one patient. In this case, another pass with the Angiojet was not performed, because of the small size of the remaining thrombus. Instead, the procedure was completed with intraarterial fibrinolysis, which achieved complete recanalization (patient 12). In another case fibrinolysis was applied after the Angiojet treatment because of the thrombosis of a periprocedurally implanted VA stent, which resolved (patient 1). In another two patients unsuccessful fibrinolysis preceded the use of the Angiojet (patients 3 and 9). Distal embolization of a thrombus fragment into the posterior cerebral artery occurred in one patient, but it was not further

TABLE 1: Patient characteristics and angiographical results

Patient (no.)	Sex	Age (y)	BA, Top	BA, Mid	BA, Caudal	V4	Vc	Catheter	Access	PreTIMI jet	PostTIMI jet	TIMI end	Embolism	% Stenosis Site	Angioplasty
1	M	49	x	x	x	x		5F	Yes	0	2	3	—	95, V4	Stent
2	M	47					x	5F	Yes	1	3	3	P2	50, V1	—
3	M	56	x	x	x	x	x	5F	Yes	0	3	3	—	70, V1	—
4	F	61			x	x		5F	No	0	n.a.*	3	—	95, V4	Balloon
5	M	62	x	x	x			5F	Yes	0	3	3	—	70, BA	Balloon
6	M	55	x	x	x	x		5F	No	0	n.a.*	2	—	80, BA	—
7	M	43	x	x	x	x	x	5F	Yes	0	3	3	—	80, V4	Stent
8	M	62	x	x	x	x		4F	Yes	0	3	3	—	95, BA	Stent
9	F	40					x	4F	Yes	1	3	3	—	—	—
10	M	73		x	x	x		4F	Yes	0	3	3	—	90, BA	Stent
11	M	64			x	x	x	4F	Yes	0	2	2	—	80, V4	—
12	F	54	x	x				4F	Yes	0	1	3	—	—	—

Note.—\*: no access-no angiojet treatment possible; BA: basilar artery; n.a.: not applicable; V1: origin of the vertebral artery; V4: intracranial segment of the vertebral artery; Vc: cervical segments of the vertebral artery; x: occluded segments.

treated (patient 2). Because of intracranial arteriosclerotic stenoses at the site of the thrombosis, one patient received additional balloon angioplasty (patient 5), and four patients were treated with stent angioplasty (patients 1, 7, 8, and 10) after the Angiojet procedure. Two intracranial stenoses were left untreated. Tirofiban was administered to five patients with stenoses after the Angiojet treatment.

In two of the 12 patients, the Angiojet could not be advanced beyond the atlas loops to the occlusion site because of the stiffness of the 5F device (there was no access failure of the new 4F device). Thus, balloon angioplasty (patient 4) and intraarterial fibrinolysis (patient 6) had to be performed in these cases and lead to successful recanalization. No dissection or vessel rupture due to the Angiojet was observed in this study.

#### *Intracranial Hematoma and Ischemic Lesions*

Hemorrhages and pre- and post-treatment ischemic infarctions revealed by CT and/or MR imaging are presented in Table 2. Intracranial hematoma occurred in three of 10 patients treated by the Angiojet. They were associated with additional rt-PA or tirofiban treatment; one of them was symptomatic (patient 1).

Symptomatic hemorrhages were also observed in both patients in whom the Angiojet could not be advanced beyond the atlas loops (patients 4 and 6).

Ten patients had various ischemic infarctions in the territory of the posterior circulation. One patient died of malignant cerebellar infarction (patient 3).

#### *Clinical Outcome*

The clinical results after 3 months are summarized in Table 2. Seven of the 10 patients treated by the Angiojet survived. Four of these seven patients had only minimal or no deficits (Modified Rankin Scale [MRS] 0–1), and two patients experienced a relatively favorable outcome with an MRS of 3. One patient had a poor outcome, because he suffered from a

locked-in syndrome (MRS 5). Both patients who could not be treated by the Angiojet died.

#### **Discussion**

Our pilot study found that the Angiojet achieves a high recanalization rate in acute VBO, even in cases of extensive thrombosis, which is unlikely to be recanalized by fibrinolysis (7). This suggests that patients with extended caudal basilar or vertebral occlusions might profit most from the use of the Angiojet.

The thrombus reached by the Angiojet could be quickly and almost completely removed. This depends, however, on the possibility of intracranial access of the Angiojet, which failed in two of 12 patients in the current study. The use of the new 4F coronary catheter seemed to ensure more reliable access to the BA than the older 5F catheter.

Because the extent of brain damage is related to the severity and duration of ischemia (11, 26), patients should be treated as early as possible and the recanalization procedure should be as brief as possible. Fibrinolysis by rt-PA or urokinase regularly requires about 1.5–2.5 hours to dissolve the clot. The time needed for the diagnostic angiography and positioning of the microcatheter must be added (11). By contrast, the Angiojet requires only the time needed for positioning plus the time for the angiography.

Another disadvantage of fibrinolysis is that fragments of the thrombus migrate distally into the posterior cerebral arteries in about 50% of all cases (according to our unpublished cases treated with intraarterial fibrinolysis). This occurred in only one of 10 cases when the Angiojet was used. The placement of a balloon in the subclavian artery, which induces backflow, can provide proximal protection in such a situation (27).

Other mechanical devices allowing for recanalization of BA thrombosis have been described in case reports and small series. It was possible to reach an intracranial position with a 4F catheter to aspirate the thrombus in young patients who had nontortuous vessels (28, 29). Retrievers were used to fragment the

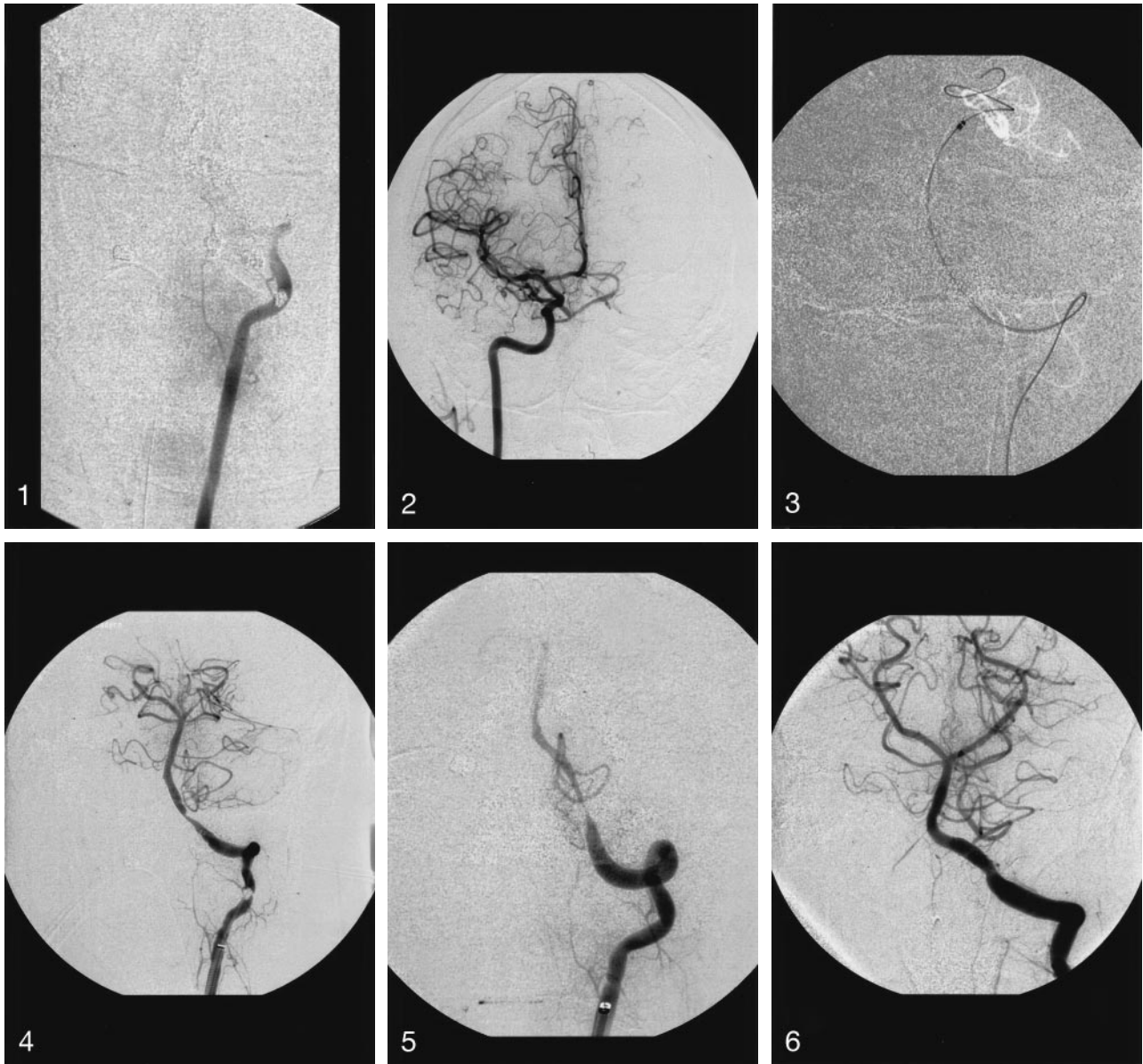


FIG 1. Patient 7, a 43-year-old male, with hemiplegia right, anarthria, and dysphagia for 7.5 hours. Occlusion of the extra- and intracranial left VA and the entire BA is shown.

FIG 2. Collateralization of the tip of the BA.

FIG 3. The Choice-PT microwire (black) with its tip in the posterior cerebral artery (white vessels) straightened the atlas loop (white line in the roadmap) and the Angiojet reached the basilar tip.

FIG 4. Complete thrombus extraction was achieved, but a high-grade stenosis of the VA remained.

FIG 5. The stenosis worsened due to rethrombosis despite heparinization (ACT >250).

FIG 6. Therefore, tirofiban was infused, and a 4-mm Medtronic stent was implanted. Complete recanalization was achieved. Shortly after the procedure, the patient improved significantly and returned to work.

thrombus (30) or to remove the embolus by using a snare (31, 32), a spiral (33), or a net. The latter did not function without flow reversal (33, 34) but was successful after backflow was induced (27, 34). All these means of mechanical recanalization were limited to use with small emboli.

Rethrombosis due to intracranial stenosis is a frequent problem in atherothrombotic VBO (35, 36). Fibrinolysis may exacerbate it by activating the coagulation cascade, and the resulting fibrin fragments may mask heparin (37). Angioplasty and stent placement have proved quite successful in intracranial ar-

tery stenosis (38–44), but there are only a few reports about their use in acute stroke (11, 45–47). Because balloon angioplasty is often insufficient or may cause dissection, we preferred stent placement for intracranial stenosis. A drawback of stent placement in acute VBO, however, is the obligatory requirement of antiplatelet treatment, which might increase the risk of intracranial hemorrhage, especially following intraarterial fibrinolysis.

Five intracranial bleedings were documented in the current study, two of them in patients not treated (intended to treat) by the Angiojet. Four of these

TABLE 2: Imaging and clinical results

Patient (no.)	mg rt-PA Order	Antiplatelet	Hematoma	Sites of Infarction	Time (h) Window of Stroke	Time (h) Window of Coma	NIHSS, Prior	GCS, Prior	MRS, After 3 Months
1	80 after	Tirofiban	ICH, SAH	c	7	5	21	6	6
2	—	—	—	o	5	4.5	26	4	3
3	40 before	—	—	c, o	18	3	25	5	6
4	*	—	ICH	c	216	6	25	5	6
5	—	—	—	—	8.5	8	23	5	1
6	*120	—	ICH, SAH	b, c	4	0	19	10	6
7	—	Tirofiban	—	c	7.5	0	20	13	1
8	—	Tirofiban	—	b	7	4	21	7	5
9	15 before	—	—	—	0	0	n.a.**	n.a.**	0
10	—	Tirofiban	SAH	b	84	0	12	13	3
11	—	Tirofiban	—	c	12	6	13	4	6
12	60 after	—	SAH	c, o	15	0	14	13	1

Note.—\*: no access-no angiojet treatment possible; \*\*: patient was under general anesthesia, when occlusion occurred; b = brainstem infarction; c = cerebellar infarction; GCS: Glasgow coma scale; ICH: intracerebral hemorrhage; MRS: Modified Rankin Scale (0 = normal, 6 = deceased); n.a.: not applicable; NIH: National Institutes of Health Stroke Scale; o = occipital and thalamic infarction; SAH: subarachnoid hemorrhage.

hemorrhages occurred in patients who received fibrinolysis or GP-IIb/IIIa thrombocyte receptor blockers. One patient who received both, in addition to the Angiojet treatment, died. This single case is in contrast to case reports and small series, in which the combination of intraarterial or systemic fibrinolysis and GP-IIb/IIIa thrombocyte receptor blockers yielded good results and seemed to be superior to fibrinolysis alone (35–37, 48).

In a recent study investigating systemic treatment of basilar thrombosis by rt-PA (49), the authors report a recanalization rate of about 50%. This suggests the possibility of a “bridging” model, which would use mechanical recanalization in those cases, in which systemic treatment fails. Therefore, a prospective multicenter study of the treatment of caudal thrombotic occlusions with the Angiojet is now called for.

## Conclusion

It is feasible to use the Angiojet to treat VA and BA thrombosis and embolism. In light of the small number of cases in the present series, no definitive statement can yet be made on the efficacy and safety of this novel endovascular device. Caudal and multi-segmental vertebrobasilar artery occlusions seem to be indications for the application of the Angiojet, a technique that may help optimize recanalization and thus improve clinical outcome of VBO patients.

## References

- Archer CR, Horenstein S. Basilar artery occlusion. *Stroke* 1977;8:383–390
- Hacke W, Zeumer H, Ferbert A, et al. Intra-arterial thrombolytic therapy improves outcome in patients with acute vertebrobasilar occlusive disease. *Stroke* 1988;19:1216–1222
- Kunze I, Glahn J, Busse O. Heparin therapy in embolic cerebral infarct: a retrospective study. *Nervenarzt* 1991;628:477–482
- Bockenheimer S, Reinhuber F, Mohs C. Intraarterielle Thrombolysse hirnversorgender Gefäße. *Radiologe* 1991;31:210–215
- Zeumer H, Freitag HJ, Zanella F, et al. Local intraarterial fibrinolytic therapy in patients with stroke: urokinase versus recombinant tissue plasminogen activator (rTPA). *Neuroradiology* 1993;35:159–162
- Becker KJ, Monsien LH, Ulatowski J. Intraarterial thrombolysis in vertebrobasilar occlusion. *AJNR Am J Neuroradiol* 1996;17:255–262
- Brandt T, von Kummer R, Mueller-Kueppers M, Hacke W. Thrombolytic therapy of acute basilar artery occlusion: variables affecting recanalization and outcome. *Stroke* 1996;27:875–881
- Cross DT 3rd, Moran CJ, Akins PT, et al. Relationship between clot location and outcome after basilar artery thrombolysis. *AJNR Am J Neuroradiol* 1997;18:1221–1228
- Cross DT 3rd, Moran CJ, Akins PT, et al. Collateral circulation and outcome after basilar artery thrombolysis. *AJNR Am J Neuroradiol* 1998;19:1557–1563
- Cross DT 3rd, Derdeyn CP, Moran CJ. Bleeding complications after basilar artery fibrinolysis with tissue plasminogen activator. *AJNR Am J Neuroradiol* 2001;22:521–525
- Eckert B, Kucinski T, Pfeiffer G, et al. Endovascular therapy of acute vertebrobasilar occlusion: early treatment onset as the most important factor. *Cerebrovasc Dis* 2002;14:42–50
- Levy EI, Firlirk AD, Wisniewski S, et al. Factors affecting survival rates for acute vertebrobasilar artery occlusions treated with intra-arterial thrombolytic therapy: a meta-analytical approach. *Neurosurgery* 1999;45:539–548
- Moebius E, Berg-Dammer E, Kuehne D, Nahser HC. Local thrombolytic therapy in acute basilar artery occlusion: experience with 18 patients. In: Hacke W, del Zoppe GJ, Hirschberg M, eds. *Thrombolytic therapy in acute ischemic stroke*. New York: Springer-Verlag;1991:213–215
- Nakagawa Y, Matsuo S, Kimura T, et al. Thrombectomy with Angiojet catheter in native coronary arteries for patients with acute or recent myocardial infarction. *Am J Cardiol* 1999;83:994–999
- Silva JA, Ramee SR, Collins TJ, et al. Rheolytic thrombectomy in the treatment of acute limb-threatening ischemia: immediate results and six-month follow-up of the multicenter Angiojet registry. *Cathet Cardiovasc Diagn* 1998;45:386–393
- Wagner H-J, Muller-Hulsbeck S, Pitton MB, et al. Rapid thrombectomy with a hydrodynamic catheter: results from a prospective, multicenter trial. *Radiology* 1997;205:675–681
- Vesely TM, Williams D, Weiss M, et al. Comparison of the Angiojet rheolytic catheter to surgical thrombectomy for the treatment of thrombosed hemodialysis grafts. *J Vasc Interv Radiol* 1999;10:1195–1205
- Koning R, Cribier A, Gerber L, et al. A new treatment for severe pulmonary embolism: percutaneous rheolytic thrombectomy. *Circulation* 1997;96:2498–2500
- Bellon RJ, Putman CM, Budzik RF, et al. Rheolytic thrombectomy of the occluded internal carotid artery in the setting of acute ischemic stroke. *AJNR Am J Neuroradiol* 2001;22:526–530
- Opatowsky MJ, Morris PP, Regan JD, et al. Rapid thrombectomy of superior sagittal sinus and transverse sinus thrombosis with a rheolytic catheter device. *AJNR Am J Neuroradiol* 1999;20:414–417
- Dowd CF, Malek AM, Phatouros CC, Hemphill JC. Application of a

- rheolytic thrombectomy device in the treatment of dural sinus thrombosis: a new technique. *AJNR Am J Neuroradiol* 1999;20:568–570
22. Scarrow AM, Williams RL, Jungreis CA, et al. Removal of a thrombus from the sigmoid and transverse sinuses with a rheolytic thrombectomy catheter. *AJNR Am J Neuroradiol* 1999;20:1467–1469
  23. Chow K, Gobin YP, Saver J, et al. Endovascular treatment of dural sinus thrombosis with rheolytic thrombectomy and intra-arterial thrombolysis. *Stroke* 2000;31:1420–1425
  24. Stahr P, Rupprecht H-J, Voightlander T, et al. A new thrombectomy catheter device (AngioJet) for the disruption of thrombi: an in vitro study. *Cathet Cardiovasc Intervent* 1999;47:381–389
  25. Whisenant BK, Baim DS, Kuntz RE, et al. Rheolytic thrombectomy with the Possis Angiojet: technical considerations and initial clinical experience. *J Invasiv Cardiol* 1999;11:421–426
  26. Mayer TE, Mull M, Brueckmann HJ, Thron A. Local intraarterial fibrinolysis in vertebrobasilar arterial occlusion: urokinase versus recombinant tissue plasminogen activator. *Neuroradiology* 1995;37(suppl): 462–465
  27. Mayer TE, Hamann GF, Brueckmann HJ. Treatment of basilar artery embolism with a mechanical extraction device: the necessity of flow reversal. *Stroke* 2002;33:2232–2235
  28. Chapot R, Houdart E, Rogopoulos A, et al. Thromboaspiration in the basilar artery: report of two cases. *AJNR Am J Neuroradiol* 2002;23:282–284
  29. Vallee JN, Crozier S, Guillevin R, et al. Acute basilar artery occlusion treated by thromboaspiration in a cocaine and ecstasy abuser. *Neurology* 2003;61:839–841
  30. Qureshi AI, Siddiqui AM, Suri MF, et al. Aggressive mechanical clot disruption and low-dose intra-arterial third-generation thrombolytic agent for ischemic stroke: a prospective study. *Neurosurgery* 2002;51:1319–1327
  31. Kerber CW, Barr JD, Berger RM, Chopko BW. Snare retrieval of intracranial thrombus in patients with acute stroke. *J Vasc Interv Radiol* 2002;13:1269–1274
  32. Wikholm G. Transarterial embolectomy in acute stroke. *AJNR Am J Neuroradiol* 2003;24:892–894
  33. Yu W, Binde D, Foster-Barber A, et al. Endovascular embolectomy of acute basilar artery occlusion. *Neurology* 2003;61:1421–1423
  34. Mayer TE, Hamann GF, Brueckmann HJ. Mechanical extraction of a basilar-artery embolus with the use of flow reversal and a microbasket. *N Engl J Med* 2002;347:769–770
  35. Wallace RC, Furlan AJ, Moliterno DJ, et al. Basilar artery rethrombosis: successful treatment with platelet glycoprotein IIb/IIIa receptor inhibitor. *AJNR Am J Neuroradiol* 1997;18:1257–1260
  36. Kueker W, Friese S, Vogel W, et al. Incomplete resolution of basilar artery occlusion after intra-arterial thrombolysis: abciximab and heparin prevent early rethrombosis. *Cerebrovasc Dis* 2000;10:484–486
  37. Junghans U, Seitz RJ, Wittsack HJ, et al. Treatment of acute basilar artery thrombosis with a combination of systemic alteplase and tirofiban, a nonpeptide platelet glycoprotein IIb/IIIa inhibitor: report of four cases. *Radiology* 2001;221:795–801
  38. Levy EI, Hanel RA, Bendok BR, et al. Staged stent assisted angioplasty for symptomatic intracranial vertebrobasilar artery stenosis. *J Neurosurg* 2002;97:1294–1301
  39. Lylyk P, Cohen JE, Ceratto R, et al. Angioplasty and stent placement in intracranial atherosclerotic stenoses and dissections. *AJNR Am J Neuroradiol* 2002;23:430–436
  40. Mori T, Kazita K, Chokyu K, et al. Short-term arteriographic and clinical outcome after cerebral angioplasty and stenting for intracranial vertebrobasilar and carotid atherosclerotic occlusive disease. *AJNR Am J Neuroradiol* 2000;21:249–54
  41. Nahser HC, Henkes H, Weber W, et al. Intracranial vertebrobasilar stenosis: angioplasty and follow-up. *AJNR Am J Neuroradiol* 2000;21:1293–301
  42. Horowitz MB, Pride GL, Graybeal DF, Purdy PD. Percutaneous transluminal angioplasty and stenting of midbasilar stenoses: three technical case reports and literature review. *Neurosurgery* 1999;45:925–930
  43. Gomez CR, Misra VK, Liu MW, et al. Elective stenting of symptomatic basilar artery stenosis. *Stroke* 2000;31:95–99
  44. Rasmussen PA, Perl J 2nd, Barr JD, et al. Stent-assisted angioplasty of intracranial vertebrobasilar atherosclerosis: an initial experience. *J Neurosurg* 2000;92:771–778
  45. Nakayama T, Tanaka K, Kaneko M, et al. Thrombolysis and angioplasty for acute occlusion of intracranial vertebrobasilar arteries: report of three cases. *J Neurosurg* 1998;88:919–922
  46. Price RF, Sellar R, Leung C, O'Sullivan MJ. Traumatic vertebral arterial dissection and vertebrobasilar arterial thrombosis successfully treated with endovascular thrombolysis and stenting. *AJNR Am J Neuroradiol* 1998;19:1677–1680
  47. Phatouros CC, Higashida RT, Malek AM, et al. Endovascular stenting of an acutely thrombosed basilar artery: technical case report and review of the literature. *Neurosurgery* 1999;44:667
  48. Eckert B, Koch C, Thomalla G, et al. Acute basilar artery occlusion treated with combined intravenous abciximab and intra-arterial tissue plasminogen activator: report of 3 cases. *Stroke* 2002;33:1424–1427
  49. Lindsberg PJ, Soine L, Tatlisumak T, et al. Long-term outcome after intravenous thrombolysis of basilar artery occlusion. *JAMA* 2004;292:1862–1866