



## EXCEPTIONAL CASE

# Extremely rapid stone formation in cystinuria: look out for dietary supplements!

Valentine Gillion<sup>1,2</sup>, Thibaud-Pierre Saussez<sup>2,3</sup>, Sandy Van Nieuwenhove<sup>2,4</sup> and Michel Jadoul <sup>1,2</sup>

<sup>1</sup>Nephrology Department, Cliniques Universitaires Saint-Luc, Brussels, Belgium, <sup>2</sup>Institut de Recherche Expérimentale et Clinique, Université catholique de Louvain, Brussels, Belgium, <sup>3</sup>Urology Department, Cliniques Universitaires Saint-Luc, Brussels, Belgium and <sup>4</sup>Radiology Department, Cliniques Universitaires Saint-Luc, Brussels, Belgium

Correspondence to: Valentine Gillion; E-mail: valentine.gillion@uclouvain.be

## ABSTRACT

Cystinuria is an autosomal recessive disease characterized by recurrent nephrolithiasis. The prevention of new stones is based on diluting and alkalinizing urine, as well as a low salt and moderate protein intake. The avoidance of food rich in methionine (the precursor of cystine) is also advocated. We report the case of a young adult adherent to the preventative strategy who was stone-free and within months formed a large stone. This coincided with the recent intake of a dietary supplement containing both cystine and methionine. Patients and physicians should be aware of the potential harm of such supplements in patients with cystinuria.

**Keywords:** amino acid, cystine, cystinuria, kidney stone, methionine, nephrolithiasis

## BACKGROUND

Cystinuria (OMIM 220100) is a rare genetic disease characterized by recurrent stones in the urinary tract. Cystine is filtered by the glomerulus and normally reabsorbed in the proximal tubule through a transporter made from two subunits rBAT and b<sup>0</sup>+AT encoded by the SLC3A1 and SLC7A9 genes, respectively. Mutations in these genes underly cystinuria [1]. Because cystine is poorly soluble at a urine pH under 7, the excess of urinary cystine results in recurrent cystine stones. Alkaline hyperdiuresis is therefore the cornerstone of the management of these patients [1]. Generous fluid intake should induce a urine output large enough to maintain a cystine concentration <250 mg/L. Dietary adaptations are also needed such as a low salt and moderate protein diet (1 g/kg/day). Patients are also advised to avoid

foods with a high content in methionine, in order to lower cystine production. Such foods include Emmental cheese, horse meat, dried cod or oily fish [1].

## CASE REPORT

A 22-year-old patient with genetically proven cystinuria (homozygous SCL3A1 mutation c.1400 T>C) had a history of kidney stones since the age of 16 years, with acute renal colic episodes in May 2015, February 2018 and April 2019. After extracorporeal shockwave lithotripsy in August 2019, the patient was stone-free in September 2019 (Figure 1A). The last 24-h urine sample in July 2019 was as follows: urinary output of 1.2 L with an estimated intake of 11 g of NaCl/day and protein intake of 0.9 g/kg

Received: 7.1.2021; Editorial decision: 11.01.2021

© The Author(s) 2021. Published by Oxford University Press on behalf of ERA-EDTA.

This is an Open Access article distributed under the terms of the Creative Commons Attribution Non-Commercial License (<http://creativecommons.org/licenses/by-nc/4.0/>), which permits non-commercial re-use, distribution, and reproduction in any medium, provided the original work is properly cited. For commercial re-use, please contact [journals.permissions@oup.com](mailto:journals.permissions@oup.com)

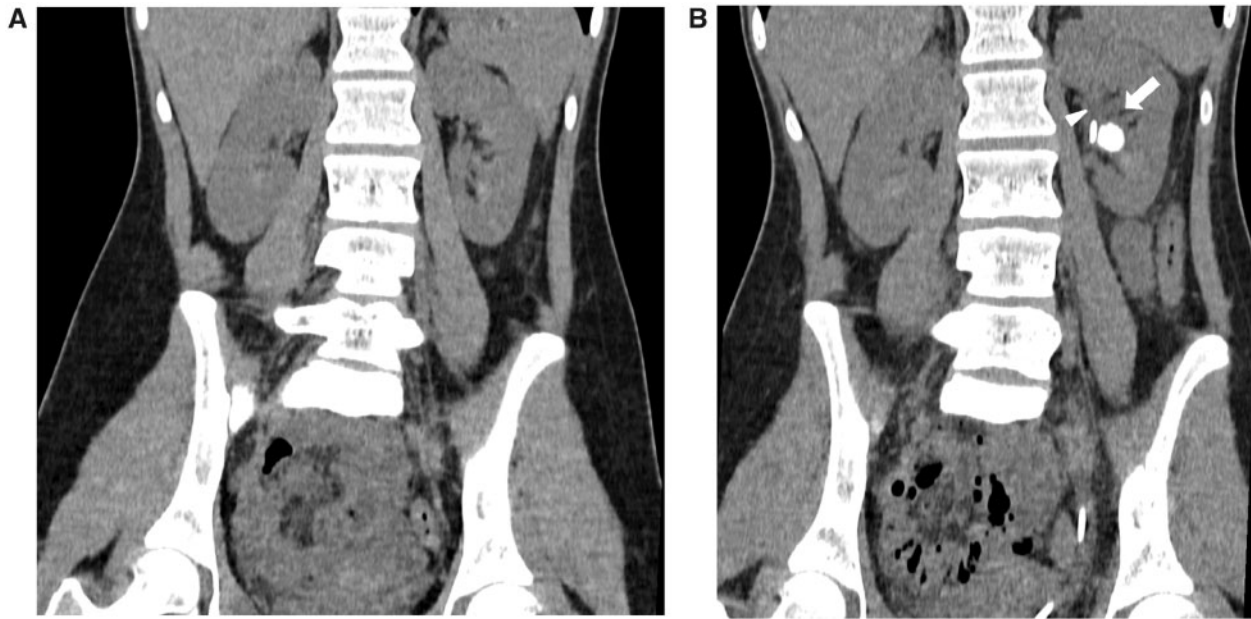


FIGURE 1: (A) Stone-free low-dose unenhanced CT—September 2019 (120 KVp, 40 mAs, DLP 141.7 mGy\*cm), multiplanar coronal reconstruction. (B) Follow-up low-dose unenhanced CT—February 2020 (120 KVp, 40 mAs, DLP 146.3 mGy\*cm) shows a 15-mm left kidney stone (arrow) next to the double-J stent (arrowhead).

day. Urinary pH was 8 with oral supplements of sodium bicarbonate 3 g/day. Previous urinary pH measurements were 7 and 8.5. The cystine urinary concentration was 490 mg/L. She presented at the emergency room in January 2020 for recurrent lumbar pain. An ultrasound revealed a 15-mm stone in the left renal pelvis, causing hydronephrosis. A double-J stent was inserted. A low-dose computed tomography (CT) confirmed the left pelvicalyceal stone (Figure 1B). A retrograde utereroscopy was performed with vaporization. The stone has a typical macroscopic aspect of cystine stone.

Further inquiry, prompted by this rapid stone formation in a recently stable, stone-free patient, revealed the recent start of a food supplement (Novophane<sup>®</sup>) prescribed by her dermatologist for hair loss. This complex contains 100 mg of cystine and 100 mg of methionine per pill. She took this twice a day from October to November.

## DISCUSSION

Cystinuria is the most frequent monogenic cause of kidney stone and accounts for 1% and 5% of nephrolithiasis in adults and children, respectively [1]. In a French cohort [2], the median age at onset of symptoms was 16.7 years, consistent with our case. Our patient had two more renal colics 35 and 49 months later, respectively. In patients with nephrolithiasis, the number of new stones in a patient denotes the clinical activity of the stone disease. Metabolic activity on the other hand refers to an active crystallization-driving process leading to the formation of new stones or to the growth of existing ones. There is no reliable marker of this metabolic activity. For example, a recurrent calcium stone former, who has passed many new stones in a relatively short period of time, should be considered as metabolically active [3]. Our patient was not considered as a clinically or metabolically active stone former. Even though her metabolic parameters were not well controlled in the last lab tests [a low urinary daily output (<3 L/day); a high salt intake (>6 g/day)

leading to a urinary cystine concentration twice above the target (>250 mg/L)], her urinary pH and protein intake were in the advised ranges. Her previous urinary cystine concentrations were 720 mg/L in July 2015, 340 mg/L in December 2015 and 70 mg/L in July 2018, showing that despite her urinary cystine concentration often being above the target concentration, she only occasionally had renal colic. This suggested that a new factor was involved in the very fast (4 months) formation of a large stone. The use of a food supplement with a high content of methionine and cystine very likely explains this rapid stone formation. Admittedly, we did not measure urinary cystine during the intake of this supplement. Finally, this case highlights the importance of considering an external source of cystine in patients with rapid stone formation. Patients and physicians should be aware of the potential harm of these types of dietary supplements, whose intake has become very popular in the western world [4] in patients with cystinuria.

## PATIENT CONSENT

Authors confirm that written consent for publication of the case report was obtained from the patient.

## ACKNOWLEDGEMENTS

An Ethics Committee (Comité d'Ethique Hospitalo-Facultaire Saint-Luc) approved this study (approval number 2020/03JUL/357).

## CONFLICT OF INTEREST STATEMENT

None declared.

## REFERENCES

1. Servais A, Thomas K, Dello Strologo L *et al*; Metabolic Nephropathy Workgroup of the European Reference Network

- for Rare Kidney Diseases (ERKNet) and eUROGEN. Cystinuria: clinical practice recommendation. *Kidney Int* 2021; 99: 48–58
2. Prot-Bertoye C, Lebbah S, Daudon M et al. CKD and its risk factors among patients with cystinuria. *Clin J Am Soc Nephrol* 2015; 10: 842–851
  3. Khan SR, Pearle MS, Robertson WG et al. Kidney stones. *Nat Rev Dis Primers* 2016; 2: 16008
  4. Clarke TC, Black LI, Stussman BJ et al. Trends in the use of complementary health approaches among adults: United States, 2002-2012. *Natl Health Stat Report* 2015; 1–16