



Since January 2020 Elsevier has created a COVID-19 resource centre with free information in English and Mandarin on the novel coronavirus COVID-19. The COVID-19 resource centre is hosted on Elsevier Connect, the company's public news and information website.

Elsevier hereby grants permission to make all its COVID-19-related research that is available on the COVID-19 resource centre - including this research content - immediately available in PubMed Central and other publicly funded repositories, such as the WHO COVID database with rights for unrestricted research re-use and analyses in any form or by any means with acknowledgement of the original source. These permissions are granted for free by Elsevier for as long as the COVID-19 resource centre remains active.



Does COVID-19 pneumonia signify secondary organizing pneumonia?: A narrative review comparing the similarities between these two distinct entities

Woon H. Chong, MD^{a,*}, Biplab K. Saha, MD^b, Amit Chopra, MD^a

^a Department of Pulmonary and Critical Care Medicine, Albany Medical Center, 43 New Scotland Avenue, Albany 12208, New York, USA

^b Department of Pulmonary and Critical Care, Ozarks Medical Center, West Plains, Missouri, USA

ARTICLE INFO

Article History:

Received 27 February 2021

Revised 7 April 2021

Accepted 12 April 2021

Available online 29 May 2021

Keywords:

Severe acute respiratory syndrome coronavirus 2

SARS-CoV-2

Coronavirus disease 2019

COVID-19

Organizing pneumonia

Secondary organizing pneumonia

ABSTRACT

Multiple observational studies have described the similarities between COVID-19 pneumonia and organizing pneumonia (OP). These two entities clinically manifest with mild and subacute respiratory symptoms, often with a delayed diagnosis due to the atypical ARDS and silent hypoxemia presentation. Radiological features are often indistinguishable between the two. With the increase in antemortem lung biopsies and autopsies being performed, more histopathological findings of OP and its variant, acute fibrinous and organizing pneumonia (AFOP), are being diagnosed. These entities are known complications of viral infections as a delayed immunological process, explaining the favorable response to corticosteroids. Clinicians should be vigilant to diagnose this under-recognized entity of secondary OP in people with COVID-19 when clinical deterioration occurs, especially with compatible radiologic findings and recent cessation of corticosteroids. Despite the proven benefits of corticosteroids in treating COVID-19, treatment approaches can be more effective as OP often requires higher doses and a more prolonged therapy duration for remission and preventing relapses. The purpose of our narrative review is to compare the similarities between COVID-19 pneumonia and OP, emphasizing the clinical, radiological, and histopathological features based on the evidence available in the literature.

© 2021 Elsevier Inc. All rights reserved.

Introduction

Coronavirus disease 2019 (COVID-19) results from severe acute respiratory syndrome coronavirus 2 (SARS-CoV-2) infection leading to the ongoing worldwide pandemic. As the wave of COVID-19 disease continues to spread across the globe, many medical publications have followed as part of scientific efforts to characterize, treat, and prevent this disease. COVID-19 can present with a wide variety of respiratory complications that range from self-limiting upper respiratory tract infection to acute respiratory failure from diffuse bilateral lung infiltrates, resulting in acute respiratory distress syndrome (ARDS).^{1–3} By their very nature, histopathology manuscripts have lagged behind those describing the clinical and imaging characteristics, but we are now seeing an abundant amount of publications giving us insight into the histopathological findings in COVID-19 pneumonia. Organizing pneumonia (OP) is defined pathologically as the presence of intra-alveolar buds of granulation tissue consisting of fibroblasts and myofibroblasts mixed with a loose connective matrix extending from the alveoli into the lumen of distal bronchioles

(Fig. 1). OP is a rare distinctive form of interstitial lung disease (ILD) that is often contributed to idiopathic causes, termed cryptogenic organizing pneumonia (COP). The “cryptogenic” nature of OP could be related to the limited knowledge about all entities leading to secondary organizing pneumonia (secondary OP). Various known etiologies such as infections (commonly viral-induced), drugs, rheumatological diseases, aspiration, radiation, drugs, and toxins have been well recognized to cause secondary OP.^{4–7} Historically, a strong correlation exists between secondary OP and various infections involving adenovirus, cytomegalovirus, herpes virus, human immunodeficiency virus, parainfluenza virus, and influenza virus, perhaps via stimulation of the immune system by viral antigens.^{5–8} This entity has even been reported among highly contagious viruses responsible for previous global pandemics such as severe acute respiratory syndrome (SARS), Middle East respiratory syndrome (MERS), and influenza A.^{9–12} The association between COVID-19 pneumonia and secondary OP has been called into question considering the increased recognition of the similarities between these two entities despite being limited to several case reports/series and post-mortem findings. Based on the current evidence in the medical literature, the purpose of our narrative view is to compare and describe the similarities between COVID-19 pneumonia and OP, with a strong emphasis

* Corresponding author.

E-mail address: chongw@amc.edu (W.H. Chong).

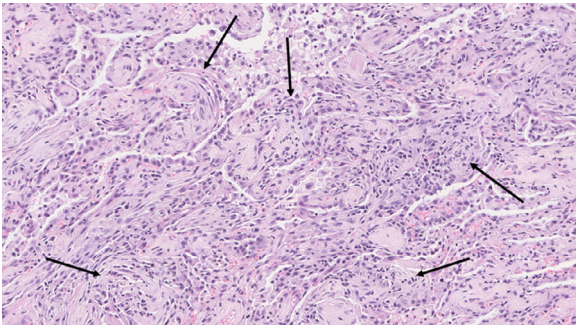


Fig. 1. Multiple intra-alveolar buds of granulation tissue, termed Masson Bodies (black arrow), containing fibroblasts and myofibroblasts mixed with a loose connective matrix extending into the lumen of distal bronchioles consistent with organizing pneumonia.

on the clinical characteristics, radiological features, histopathological findings, and available therapies.

Methods

A literature search was performed through MEDLINE, Pubmed, and SCOPUS databases using keywords of “coronavirus disease 2019 (COVID-19),” “severe acute respiratory syndrome coronavirus 2 (SARS-CoV-2),” “organizing pneumonia (OP),” “cryptogenic organizing pneumonia (COP),” and “secondary organizing pneumonia (secondary OP).” All specified keywords were combined using the “OR” operator and “AND” operator for searching the literature. Articles published up to February 1st, 2021, were included from peer-reviewed journals. We simultaneously searched the reference lists of all recovered articles for potentially eligible studies. All research study types, such as case series, case reports, and observational studies, were included. No document restriction was applied, and no methodology filters were used. Two authors (W.H. and B.S.) independently reviewed the titles and abstracts of all search results for eligibility. If an article was considered potentially eligible, both authors independently examined the full article for inclusion. A consensus-based discussion resolved disagreements between the authors. If no consensus was reached, a third reviewer (A.C.) made the final decision.

We identified 5 case reports and 3 case series describing secondary OP diagnosis among hospitalized COVID-19 patients with histopathological confirmation (Table 1). These studies were analyzed for month, year, and country of publication; age and gender; hospital course (radiological and histopathological findings); and outcomes. Data extraction was based on conclusions found in reviews, methods and results gathered from observational studies, and results reported in case reports and case series. Observational studies identified were autopsies describing histopathological findings of OP in the lungs of people with COVID-19 or descriptive radiological studies. Case reports and case series described the antemortem diagnosis of OP based on either histopathological findings and/or radiological features in people hospitalized with COVID-19. As the literature data are limited and heterogeneous, it was not feasible to perform a qualitative assessment, statistical analysis, or provide high-quality, evidence-based recommendations. Still, consensus, recommendations and opinions are provided where appropriate.

Clinical characteristics of COVID-19 and OP

The symptoms of COVID-19 infection are primarily respiratory with cough, dyspnea, myalgia, and fever, although often indistinguishable from other viral illnesses.^{1–3,13} Many presents with mild and non-specific symptoms. Only a few seek medical attention, especially during the early phase of the disease. In a large multi-center

observational study involving 1,099 people with COVID-19, the overall incidence of ARDS is 3.4% but increases to 17–29% among those requiring hospital admission.^{1–3} The median time from illness onset to development of dyspnea is 8 (5–13) days, whereas the time to develop ARDS and ICU admission is 12 (8–15) days.^{2,13} In OP, the mean age of diagnosis is 59.0 +/- 13.6 years, with non-specific symptoms often described as a flu-like illness.^{5,8} In a similar fashion to COVID-19, OP symptoms are usually mild at the initial onset with subacute presentation over a few weeks.^{6,7} Due to the mild and non-specific nature of presentation, it may take approximately 2–3 months before the diagnosis of OP can be made.⁵ Fever and shorter duration of symptoms are often helpful clues to indicate an underlying infectious etiology for secondary OP.^{4,6,14} The majority of people diagnosed with COVID-19 pneumonia and OP are non-smokers or ex-smokers.^{1–3,5,13,15} These clinical characteristics have been described in the many case reports and series included in Table 1.

Pathophysiology

COVID-19-related ARDS does not present and progress in a typical ARDS pattern with clinical symptoms often inconsistent with the severity of laboratory and radiologic findings.¹⁶ Furthermore, lung compliance may be relatively normal to high, and the onset of COVID-19-related ARDS of 8–12 days is inconsistent with ARDS Berlin criteria, defining ARDS onset within a week from known insult.^{2,13,16} COVID-19-related ARDS have a time-related disease spectrum with two primary phenotypes of type L and type H that explains the delayed subacute symptomatic presentation (Fig. 2).¹⁷ Type L phenotype is characterized by low elastance, low ventilation to perfusion (V/Q) ratio, low lung weight and lung recruitability. In the early course of the disease (phenotype L), elastance remains low, but compliance is high due to the incomplete alveolar filling, which partially reduces ventilation in these regions with less impact on elastic recoil.¹⁸ Severe hypoxemia occurs due to the loss of lung perfusion regulation and hypoxic vasoconstriction. At this time, people with COVID-19 typically show no signs of respiratory distress, giving the term “silent hypoxemia or happy hypoxemia” from the lack of compensatory respiratory drive as a minimal increase in minute ventilation will cause a rapid reduction in PaCO₂ in the setting of low elastance.¹⁹ The respiratory centers are more sensitive to changes in PaCO₂, where minimal changes in PaCO₂ will outweigh PaO₂ in influencing the respiratory drive.²⁰ Similar phenomena are observed during the early stage of OP where marked hypoxemia occurs from defective pulmonary vasoconstriction (Type L phenotype) in the areas of poorly ventilated and well-perfused lung regions due to intra-alveolar buds occupying the entire lumen of alveoli.^{6,7}

Over time, the progression and accumulation of edema become more prominent secondary to high permeability from ongoing lung inflammation, causing an increase in lung weight and dependent atelectasis. Clinical deterioration will ensue with the evolution from type L to type H phenotype, especially in critically ill patients. Type H phenotype is characterized by a high elastance, high V/Q ratio, high lung weight and lung recruitability. This will result in further right-to-left shunting, dead space ventilation, and lower tidal volumes generated. As a result, respiratory distress will occur from normalization and retention of PaCO₂, and activation of both hypoxic and hypercapnic ventilatory drive in the respiratory center.^{17,19,20}

Radiological features of COVID-19 and OP

Multiple COVID-19 radiological manifestations have been described in the current literature to determine the typical radiological features of COVID-19 pneumonia. Furthermore, several observational studies have assessed the different stages of COVID-19 pneumonia from the time of illness onset.^{21–26} In the early phase of COVID-19 disease (0–4 days), alveolar opacities [predominantly

Table 1

Case series and reports describing secondary organizing pneumonia in people hospitalized with COVID-19.

Case Series/Reports With Histopathological Confirmation		
Author	Month Year, Country	(Age, Gender) Hospital Course [Outcome]
Bae et al. ⁶⁴	June 2020, Korea	(46, Female) Radiological: Admission chest CT demonstrated peripheral predominant diffuse multifocal consolidation and GGO. No changes on day 15 and 22 of hospitalization but improvement on day 35 with corticosteroids. Histopathological: Hospitalization day 19, VATs biopsy of RUL revealed intra-alveolar organizing fibroblastic tissues and lymphoplasmacytic infiltration. Treatment: Lopinavir and ritonavir for 14 days, ceftriaxone for 10 days. After biopsy, started on 50mg/day IV methylprednisolone for 7 days before tapering to oral prednisolone 30mg daily with slow taper over several months. [Survived]
Kanaoka et al. ⁶⁵	February 2021, Japan	(56, Male) Radiological: Admission chest CT showed bilateral peripheral-predominant GGO of both lungs. No changes on day 16 but improved on day 41. Histopathological: Hospitalization day 29, transbronchial biopsies revealed intra-alveolar granulation, interstitial lymphocyte infiltration, and fibroblastic tissue proliferation. Treatment: On admission, started on favipiravir and dexamethasone till day 13 but relapse after so oral 60 mg/day prednisolone started on day 35 with slow taper leading to clinical improvement. [Survived] (84, Female) Radiological: Admission chest CT showed patchy peripheral GGOs of right lung. No changes on day 23 and 43 but improved on day 57. Histopathological: Hospitalization day 45, transbronchial biopsies revealed intra-alveolar granulation, interstitial lymphocyte infiltration, and fibroblastic tissue proliferation. Treatment: On admission, started on favipiravir and dexamethasone till day 24 but relapse after so oral prednisolone 60 mg/day with slow taper leading to clinical improvement. [Survived]
Pernazza et al. ⁷⁶	April 2020, Italy	(61, Male) Radiological: On day 5 after elective thorascopic lobectomy, chest CT demonstrated bilateral, peripheral, ill-defined GGO, predominantly in the bibasilar with scattered areas of consolidations. Histopathological: Histology from elective thorascopic lobectomy revealing lung adenocarcinoma, inflammatory infiltrates, and fibrous plugs in the absence of hyaline membranes. Treatment: Tocilizumab and chloroquine hydrate. [Survived]
Pogatchnik et al. ⁷⁷	August 2020, USA	(61, Female) Radiological: Hospitalization day 3, chest CT showed peripheral and bibasilar patchy opacities with peribular sparing. Histopathological: Hospitalization day 5, transbronchial biopsies of right lung revealing scattered fibromyxoid plugs within distal airspaces. Treatment: Remdesivir. [Survived]
Takumida et al. ⁶²	December 2020, Japan	(70, Male) Radiological: Admission chest CT demonstrated peripheral GGOs and consolidations along the bronchovascular bundles, progressed to extensive consolidations with pleural effusion and RLL fibrosis on day 23 of hospitalization. Histopathological: Hospitalization day 28, transbronchial biopsies of RUL revealed intra-alveolar myxoid matrix. Treatment: Favipiravir and 70mg IV methylprednisolone for 5 days, but relapsed requiring 70mg oral prednisolone on day 31 with 4 weeks tapering regimen. [Survived]
Tian et al. ⁷⁹	February 2020, China	(84, Female) Radiological: 1 day post-elective RML lobectomy, chest CT showed GGO of BLL with subpleural distribution. Histopathological: RML histology revealed intra-alveolar focal fibrin clusters mixed with inflammatory and multinucleated giant cells. Treatment: NR [Died] (73, Male) Radiological: 2 days post-elective RLL lobectomy, chest CT showed patchy GGO of BUL. Histopathological: RLL histology revealed intra-alveolar focal fibroblast plug and multinucleated giant cells. Treatment: NR [Survived]
Vadasz et al. ⁶³	November 2020, Germany	(57, Male) Radiological: Day 20 hospitalization, chest CT revealed extensive subpleural patchy consolidation, fibrotic bands of the RML and BLL. Histopathological: Day 20 hospitalization, transbronchial biopsy revealed mesenchymal plugs (Masson bodies) filling the alveolar lumen. (70, Male) Radiological: Day 28 of admission, chest CT showed similar findings to patient 1. Histopathological: After day 28 of admission, transbronchial biopsy revealed similar findings of patient 1. (76, Male) Radiological: Day 4 hospitalization, chest CT showed similar findings of patient 1. Histopathological: Day 60 hospitalization, transbronchial biopsies revealed similar findings of patient 1. Treatment: All patients received oral prednisolone 1mg/kg/day for 4 weeks with slow taper. [All survived]
Zhang et al. ⁸²	March 2020, China	(72, Male) Radiological: Day 14 hospitalization, chest CT demonstrated bilateral GGO. Histopathological: Day 28 hospitalization, transthoracic needle biopsy of LUL revealed intra-alveolar loose fibrous plugs of OP, with presence of intra-alveolar organizing fibrin. Treatment: Antiviral therapy. [Died]
Case Series/Reports Without Histopathological Confirmation		
Author	Month Year, Country	(Age, Gender) Hospital Course [Outcome]
De Oliveira Filho et al. ⁶⁷	December 2020, Brazil	(52, Male) Radiological: Day 10 of admission, chest CT demonstrate peripheral areas of consolidation in BLL. (60, Female) Radiological: Day 14 of admission, chest CT demonstrate patchy areas of subpleural consolidation with peribular distribution and reticulations. Treatment: cefepime, meropenem but worsen so 10 days of 6mg oral dexamethasone on day 14 and 1mg/kg/day oral prednisone after. [Survived] (63, Female) Radiological: Day 2 of hospitalization, chest CT demonstrate RML and RLL consolidations and GGOs with peribular distribution, patchy GGO in the left lung. Treatment: Patients 1 and 3 received azithromycin, amoxicillin-clavulanate but no improvement so 10 days of 6mg oral dexamethasone and 1mg/kg/day oral prednisone after. [Survived]
Fang et al. ⁸⁰	April 2020, China	(45, Female) Radiological: On admission, chest CT demonstrated multiple bilateral areas of peripheral consolidation and interlobular septal thickening with crazy paving appearance. (32, Male) Radiological: On admission, chest CT demonstrated subpleural RLL consolidation. Treatment: Both patients received antiviral therapy. [Both survived]

(continued)

Table 1 (Continued)

Case Series/Reports Without Histopathological Confirmation			
Author	Month Year, Country	(Age, Gender)	Hospital Course [Outcome]
Horii et al. ⁸³	November 2020, Japan	(70, Female)	Radiological: Admission chest CT showed bilateral GGOs superimposed with interlobular reticulations and crazy-paving pattern that worsen on day 10 but improved on day 17. Treatment: Favipiravir, ciclesonide, nafamostat for 5-7 days but no improvement so oral prednisolone on day 13 with tapering regimen over 3 months. [Survived]
John et al. ⁸⁴	September 2020, USA	(62, Female)	Radiological: Day 7 hospitalization, chest CT showed migratory GGO bilaterally but worsen on day 17. Treatment: Convalescent plasma causing relapse with improvement on 1mg/kg/day of IV methylprednisolone on day 17 hospitalization. [Survived]
McLaren et al. ⁷⁸	July 2020, USA	(59, Female)	Radiological: On admission, chest CT showed patchy, bilateral GGOs with reverse halo signs. Treatment: Hydroxychloroquine, IV vitamin C, ceftriaxone, doxycycline. [Survived]
Okamori et al. ⁸⁵	August 2020, Japan	(29, Female)	Radiological: On admission chest CT demonstrated similar findings to patient 1. Treatment: NR. [Survived]
		(60, Male)	Radiological: Admission chest CT showed bilateral patchy GGOs, predominantly in the subpleural areas but worsen on day 6 before improving on day 23 of hospitalization with corticosteroids. Treatment: Ciclesonide, favipiravir, levofloxacin with no improvement before 3 days of 1 gram IV methylprednisolone on day 6 and 80 mg/day oral prednisolone after for 3 weeks. [Survived]
Rea et al. ⁸⁶	October 2020, Italy	(60, Female)	Radiological: Bilateral consolidations with band-like shapes and distributed in subpleural and bronchovascular regions but worsen on day 6 before improving on day 17 with corticosteroids. Treatment: Azithromycin, ceftriaxone, hydroxychloroquine, favipiravir with no improvement before starting prednisolone 50mg/day on day 6 with taper over 3 weeks. [Survived]
		(57, Male)	Radiological: On admission chest CT showed reverse halo signs and peripheral GGO in the BLL that worsen on day 11 and 18 of hospitalization. Improved on day 30 of hospitalization. Treatment: NR. [Survived]
Simoes et al. ⁸⁷	January 2021, Portugal	(71, Male)	Radiological: Admission chest CT showed bilateral GGOs, peripheral and BLL predominant but worsen on day 23 with patchy linear opacities and perilobular distribution. Improved with 4 months prednisolone. Treatment: Lopinavir/ritonavir, hydroxychloroquine, ceftriaxone, azithromycin for 10 days but relapsed, so 1mg/kg/day oral prednisolone on day 11 with 4 months taper. [Survived]
		(83, Male)	Radiological: 1 month after illness, chest CT showed patchy GGOs and consolidations with peripheral and bronchovascular distribution, predominantly in RML and BLL. Improved with 4 months prednisolone. Treatment: Lopinavir/ritonavir, hydroxychloroquine for 4 days but relapsed, so oral 1mg/kg/day methylprednisolone on day 5 with 4 months taper. [Survived]

Abbreviations: BLL: bilateral lower lobes, BUL: bilateral upper lobes, COPD: chronic obstructive pulmonary disease, CT: computed tomography, DM: diabetes mellitus, GGO: ground-glass opacification, HLD: hyperlipidemia, HTN: hypertension, IV: intravenous, LLL: left lower lobe, LUL: left upper lobe, NR: non-reported, RML: right middle lobe, RUL: right upper lobe RLL: right lower lobe.

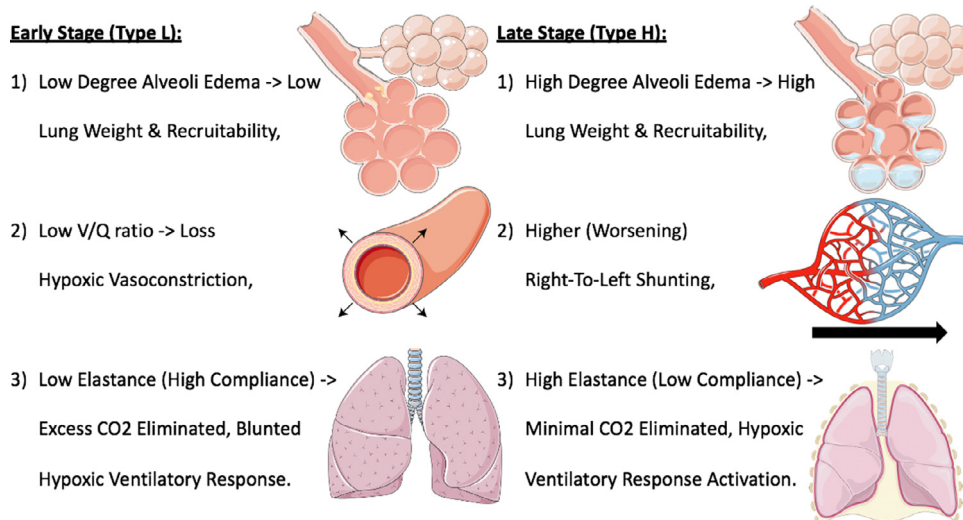


Fig. 2. Overview of the possible silent hypoxemia (happy hypoxemia) mechanism in COVID-19 and organizing pneumonia patients. This figure was created using Servier Medical Art templates, which are licensed under a Creative Commons Attribution 3.0 Unported License; <https://smart.servier.com>.

ground-glass opacities (GGOs) and reticulations] favoring the peripheral, bronchovascular, and basilar lung regions occur that will increase in lung distribution on day 5-9 (intermediate stage) by diffusely involve multiple lung regions and interstitium giving rise to interlobular and crazy-paving patterns. In the later stage (day ten and more), the evolution of alveolar opacities into consolidation occurs where GGO interspersed with consolidations and reticulations plus reverse halo signs (central GGO surrounded by complete/incomplete ring of consolidation) are common findings on CT chest.^{21–26} The typical radiological pattern of OP is characterized by bilateral, patchy, perilobular alveolar opacities

(with a density ranging from GGO to consolidation) that are frequently subpleural (Fig. 3) or bronchovascular in distribution with predominance for the middle and lower lung zones.^{4,27} In a similar fashion to COVID-19, the opacities in OP will evolve into a more consolidative appearance with reverse halo signs.^{28–31} Peripheral and lower-lobe predominant GGOs concerning for OP have been described on chest CT during influenza A pandemic.^{12,32} With the wide variety of radiological manifestations described, it is not surprising why COVID-19 pneumonia can be an excellent mimicker of a variety of different infectious and inflammatory respiratory diseases including OP.³³

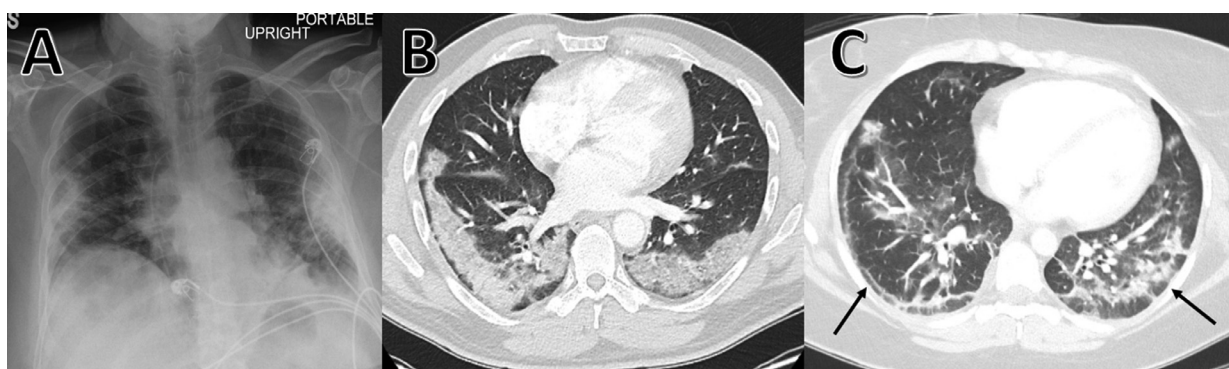


Fig. 3. Similarities between the radiological features of organizing pneumonia and COVID-19 pneumonia. (A) Chest radiograph showing bilateral opacities predominantly in the lung peripheries. (B) Chest CT demonstrating bilateral lower lobes consolidation in the subpleural regions. (C) Chest CT revealing bilateral, peripheral, ill-defined patchy GGOs and consolidations in a peribulbar pattern. Reverse-halo signs (black arrow) are seen peripherally.

To date, two observational radiological studies by Wang et al. and Jin et al. have described COVID-19 patients with a presumptive diagnosis of secondary OP based on chest CT findings.^{31,34} A multi-center study by Jin et al. assessed 165 people with COVID-19 in which 54.5% (99/165) had a preliminary diagnosis of OP and the remainder with non-OP.³⁴ In that study, the radiological findings of OP conveyed better outcomes with less likelihood of ICU admission, invasive mechanical ventilation (IMV) requirement, mortality, and healing with pulmonary fibrosis than with a non-OP pattern. A case series by Vasu et al. reported that pleural effusions were notably more common in secondary OP (60% vs. 0%; $p = 0.004$), although pleural effusions were generally small in size.¹⁴ Multiple observational studies assessing the COVID-19 radiological characteristics revealed that pleural effusion incidence, although highly variable (4.2–23.5%), increases in frequency after 12 days from onset of symptoms.^{22,35–37} It is possible that pleural effusions likely represent a more severe inflammatory radiological evolution of COVID-19 pneumonia with increasing frequency during the hospital course and concomitant progression of opacities from GGOs to consolidations. This correlation of secondary OP has been seen in people with SARS, MERS, and influenza A, demonstrating radiological findings of alveolar opacities (GGOs and consolidations) predominantly in the peripheral, basilar, and bronchovascular lung regions with pleural effusion. However, no lung histopathological confirmation exists to solidify this hypothesis.^{9–12}

Histopathological findings of COVID-19 and OP

The histopathological findings that have been described during post-mortem examinations of patients with COVID-19 pneumonia are commonly diffuse alveolar damage (DAD), less frequently OP, and rarely acute fibrinous and organizing pneumonia (AFOP).^{38–41} DAD in classic ARDS is divided into acute/exudative (1–8 days) and organizing/proliferative (9–17 days) phase.⁴² The early acute/exudative phase is defined as alveolar injury leading to leakage of fluid and protein accumulation in the alveoli giving rise to the hyaline membrane. This will be followed by the late organizing/proliferative phase, with resolving hyaline membrane and interstitial infiltration by myofibroblasts with collagen deposition.^{39,41,43–45} In OP, leakage of coagulative proteins occurs during alveolar injury that will trigger an accumulation of fibrin from diminished fibrinolytic activity with fibroblast activation and proliferation ensuing giving the intra-alveolar buds of granulation tissue (Masson bodies) appearance (Fig. 1). AFOP often termed a severe form of OP, is characterized by an extensive intra-alveolar fibrin deposition called “fibrin balls” as opposed to hyaline membranes seen in DAD.^{41,46,47} Historically, AFOP was considered a variant of DAD due to the similarities shared involving

clinical course and outcome; however, recent studies have refuted this claim to be closer to those of OP.^{48,49} Clinically, AFOP likely represents a rapidly progressive course of OP with symptomatic presentation and exhibit extensive radiological findings of diffuse, bibasilar-predominant lung infiltrates.^{6,7,43} It is reasonable to hypothesize that DAD, the most common lung histopathological finding reported, predominates in the early phase of COVID-19 pneumonia before the organizing phase of DAD ensues with transformation into OP and AFOP.^{4,39,40,44,45} Hence, it is not infrequent to see areas of OP, AFOP, and DAD in the same autopsy specimen from a person dying of COVID-19 pneumonia.^{39,41,42,45,47} In all of these different histopathological phenotypes, healing may occur in the form of fibrosis (fibrotic phase), weeks to months after initial injury with distortion of lung architecture depending on the severity of lung inflammation. In extreme cases, these changes may resemble usual interstitial pneumonia (UIP).^{39,41,43–45}

Two large post-mortem lung examinations of 100 people diagnosed with COVID-19 reported the histopathological findings of OP in up to 44% of cases.^{45,50} The deceased had a prolonged illness duration [median 20 (5–58) days]. Autopsies of six people with COVID-19 who died later in their disease course (20 days after onset of symptoms) described histopathological findings of AFOP.³⁸ Similarly, post-mortem histopathological OP and AFOP patterns of acute lung injury were also noted during the SARS and influenza A epidemic, especially in people suffering from prolonged illness duration (around 20 days and more).^{47,51–54} It is important to note that the lung parenchymal involvement in OP is typically patchy, with normal lung architecture immediately adjacent to the disease. Therefore, it can be present as a bystander in many pulmonary disease processes, such as lung malignancy, lymphoma, connective tissue disease-associated ILD (CTD-ILD), vasculitis, non-specific interstitial pneumonia, chronic eosinophilic pneumonia, hypersensitivity pneumonitis (HP), and DAD.^{4,6} The diagnosis of OP cannot be made unless it represents the predominant histopathologic abnormality. Thus, a transbronchial biopsy can be misleading but remains useful if clinical and radiological findings are compatible. The histopathological evidence of OP was found on lung autopsies by De Michele et al. and Roden et al. in 27.3% (3/11) and 37.5% (3/8) of people with COVID-19 who died at a median of 20.5 (5.0–25.0) days from admission.^{39,55} Moreover, incidental findings of pleural effusions supporting secondary OP were frequently observed.^{4,14} It is not unusual for intra-alveolar Masson Body, the histopathological hallmark of OP, or even predominant intra-alveolar fibrin deposition (indicative of AFOP) to be seen during the proliferative phase of DAD.^{39,56} A post-mortem lung examination of a deceased person with COVID-19 observed the transitioning of lung histopathology in COVID-19 pneumonia from DAD (most common) to AFOP during the later stage of infection.⁴⁶

Therapies for COVID-19 and OP

Generally, corticosteroids are the cornerstone of therapy for OP with regression of symptoms within weeks and radiographic improvement within a month after secondary causes have been ruled out or treated. Current consensus recommends an initial dose of 0.75–1.5 mg/kg/day of prednisone for four weeks with a slow taper over 3–6 months.^{6,7} It is not uncommon for relapse to occur during weaning of corticosteroids in 13 to 68% of cases when the corticosteroid dosing is reduced below 20 mg/day of prednisone equivalents or following the cessation of corticosteroids. A dramatic response to resumed therapy is observed in most cases, with doses of 20 mg prednisone daily often sufficient to treat relapse. Roughly one-quarter who suffer a relapse will go on to experience two or more relapses.^{7,15} The risk of relapse is at its highest within the first year after the initial diagnosis of OP despite corticosteroid therapy.^{5,7} Factors associated with an increased risk of relapse include delayed treatment initiation during the initial OP diagnosis and elevated liver enzymes.¹⁵ The identification of secondary OP is clinically significant, as the management consists of treating OP and underlying disease. Corticosteroid therapy has emerged as an effective therapy for COVID-19 pneumonia, and current guidelines recommend the use of corticosteroid, primarily dexamethasone, as the mainstay therapy.^{57,58} In contrast, corticosteroids are not recommended for the treatment of respiratory failure in the setting of SARS, MERS, and influenza A infection due to association with delayed viral clearance, increased in superimposed infection, and mortality.^{59–61} In those studies, it is unclear how many patients had radiological patterns consistent with OP.

Several case series and case reports have reported the strong association between COVID-19 infection and secondary OP requiring high doses of corticosteroid therapy over a prolonged treatment duration, typically weeks to months (Table 1).^{62–64} Intravenous (IV) treatment with methylprednisolone daily over 5–12 days was shown to be insufficient in preventing relapse in respiratory status after completion of therapy. In contrast, clinical improvement was achieved with 60 mg oral prednisolone daily with a gradual taper over a few months.^{62,65} A single-center prospective observational study by Myall et al. assessed 325 COVID-19 patients post-discharge around 6–8 weeks from their hospital.⁶⁶ 24% of COVID-19 patients who recovered had recurring dyspnea with restrictive limitations on pulmonary function tests and ongoing radiologic lesions concerning for OP. High-dose oral prednisolone was resumed in the outpatient setting with slow taper resulting in clinical and radiological improvements. A case series even suggested using high-dose corticosteroids beyond the recommended 10-day course for people with COVID-19 if there is no clinical improvement.⁶⁷ A prolonged period of corticosteroid therapy is frequently required to achieve remission from acute respiratory failure in the setting of OP and AFOP secondary to MERS and influenza A viruses.^{52,68–71} At present, there is a lack of evidence that treatment of OP secondary to COVID-19 infection with corticosteroids, especially after ARDS, can prevent or reduce the development of residual pulmonary fibrosis. Macrolide therapy has even been studied to treat both OP and COVID-19 pneumonia, owing to their anti-inflammatory properties. However, a recent large, multi-center randomized control trial (RCT) study demonstrated a lack of clinical improvement in hospitalized COVID-19 patients receiving macrolide therapy of azithromycin.⁷² Furthermore, the benefit of using macrolide therapy as an alternative option for people with OP diagnosis who are intolerant to corticosteroids or have frequent relapses is limited to small case series and case reports.^{6,7} Therefore, a large, multi-center RCT is required to determine the indication, optimal dosage, and duration of corticosteroid therapy among those with suspected OP secondary to COVID-19 infection.

Limitations

Our review has several limitations. The majority of studies assessing OP secondary to COVID-19 are confined to case reports, case series, autopsies, and presumptive diagnosis in inadequate sample size observational studies, irrespective of histopathological confirmation (Table 1). Due to its rarity, OP is challenging to diagnose and likely under-recognized and under-reported, particularly in the setting of ARDS in which clinical features and radiological findings in OP resemble those of COVID-19 pneumonia. Furthermore, publication bias is likely for these reasons. The relationship between these two entities cannot be accurately assessed amid the current pandemic due to the scarcity of clinical data from the reluctance to perform aerosol-generating procedures such as lung biopsies and autopsies in order to reduce host transmission and conserve medical supplies. The use of bronchoscopy in people with COVID-19 has been recommended when an alternate diagnosis provided by BAL and/or transbronchial biopsies would significantly impact clinical management.⁷³ A low CD4+: CD8+ T-cell ratio on BAL can be seen in COVID-19 patients, but it does not contribute significantly to the diagnosis of secondary OP.^{67,62} The BAL findings in OP are non-specific and often show mixed cellularity of neutrophils, lymphocytes, and eosinophils, although helpful in ruling out infectious and malignant etiologies, with similar sensitivity and negative predictive value compared to surgical lung biopsy.⁶ BAL analysis may demonstrate lymphocytosis (>20%) only in those with secondary OP.^{5,8} The mixed cellularity of white blood cells in BAL was observed in few case reports of COVID-19 patients diagnosed with biopsy-confirmed OP (Table 1).^{62,64,65}

Implications

In view of the compatible clinical presentations, radiological abnormalities, and histopathological findings of secondary OP in COVID-19 patients (Table 1), concerns exist that the recommended dose of 6 mg dexamethasone daily for ten days is insufficient to achieve complete remission. COVID-19-induced dysregulated immune response termed cytokine storm typically manifests with elevated inflammatory markers, relapse in clinical symptoms, and multi-organ failures.⁷⁴ This phenomenon frequently occurs weeks after the initial injury from COVID-19 infection. As high inflammatory markers of erythrocyte sedimentation rate and C-reactive protein are also commonly seen in patients with OP, the timely administration of corticosteroids, especially in the early stage of the hyperinflammatory phase of cytokine storm, can effectively prevent and induce remission of COVID-19-related ARDS and secondary OP.^{5–8,75} Given the delayed onset of cytokine storm, these findings likely explain why respiratory symptoms and radiologic features of lung infiltrates continue for an extended period even after viral clearance was achieved and lengthy treatment with corticosteroids required. Upon ruling out superimpose and nosocomial infections, we recommend resuming high-dose corticosteroids in people with COVID-19-induced respiratory failure when relapses occur, possibly at initial doses of 0.75–1.5 mg/kg/day of prednisone or equivalent for 2–4 weeks with a slow taper over several months. Although rare, spontaneous remission can be achieved without corticosteroid therapy in OP (Table 1).^{76–81} There is currently no large-scale epidemiological data assessing this condition as a complication of COVID-19 infection, including the incidence, clinical course, outcomes, and treatment. For people diagnosed with secondary OP from COVID-19, a large, well-designed RCT is required to determine: 1) the ideal duration and dosing of corticosteroids therapy such as short-term (10 days and less) versus long-term with a slow tapering regimen, 2) effective non-invasive means of diagnosing secondary OP from COVID-19 based on serum inflammatory markers and BAL findings, and 3) radiological and laboratory markers that are indicative of good corticosteroid response allowing weaning to occur.

Conclusion

Based on our findings, secondary OP should be considered as part of the differential diagnosis among patients with COVID-19 pneumonia, especially in the setting of persistent or relapsing respiratory symptoms and ongoing radiologic features of lung infiltrate even during the recovery phase. It is possible that, as has been described with other viruses, secondary OP in the setting of COVID-19 represents an immunological process after initial infection explaining the favorable response to immunosuppressive therapy of corticosteroids. We suspected that OP is much more common in COVID-19 infection despite the few reports to this day. OP can be present in isolation or combination with DAD and/or AFOP during post-mortem examinations of the lungs in deceased COVID-19 patients. Moreover, the timely diagnosis and treatment initiation may lead to less IMV requirement, redundant use of antibiotics, and improved overall survival. As our knowledge continues to grow during this current pandemic, with lung biopsies being increasingly warranted and performed in COVID-19 patients under the guidance of proper infection control protocol, we hope that a large, well-designed study can be implemented to determine the relationship of OP secondary to COVID-19 infection. A high clinical suspicion should exist for secondary OP when clinical deterioration occurs in people with COVID-19 when radiologic findings are compatible, especially in the setting of recent cessation of corticosteroid therapy.

Funding

None.

Author contribution

All authors had access to the data and were involved in writing the manuscript.

Declaration of Competing Interest

None.

References

- Chen N, Zhou M, Dong X, et al. Epidemiological and clinical characteristics of 99 cases of 2019 novel coronavirus pneumonia in Wuhan, China: a descriptive study. *Lancet*. 2020;395(10223):507–513. [https://doi.org/10.1016/S0140-6736\(20\)30211-7](https://doi.org/10.1016/S0140-6736(20)30211-7).
- Huang C, Wang Y, Li X, et al. Clinical features of patients infected with 2019 novel coronavirus in Wuhan, China. *Lancet*. 2020;395(10223):497–506. [https://doi.org/10.1016/S0140-6736\(20\)30183-5](https://doi.org/10.1016/S0140-6736(20)30183-5).
- Guan W-J, Ni Z-Y, Hu Y, et al. Clinical characteristics of coronavirus disease 2019 in China. *N Engl J Med*. 2020;382(18):1708–1720. <https://doi.org/10.1056/NEJMoa2002032>.
- Kligerman SJ, Franks TJ, Galvin JR. From the radiologic pathology archives: organization and fibrosis as a response to lung injury in diffuse alveolar damage, organizing pneumonia, and acute fibrinous and organizing pneumonia. *Radio Graphics*. 2013;33(7):1951–1975. <https://doi.org/10.1148/rg.337130057>.
- Drakopanagiotakis F, Paschalaki K, Abu-Hijleh M, et al. Cryptogenic and secondary organizing pneumonia. *Chest*. 2011;139(4):893–900. <https://doi.org/10.1378/chest.10-0883>.
- Cottin V, Cordier J-F. Cryptogenic organizing pneumonia. *Semin Respir Crit Care Med*. 2012;33(05):462–475. <https://doi.org/10.1055/s-0032-1325157>.
- Cordier J-F. Cryptogenic organising pneumonia. *Eur Respir J*. 2006;28(2):422–446. <https://doi.org/10.1183/09031936.06.00013505>.
- Baha A, Yildirim F, Clinic of Pulmonary Disease and Intensive Care Unit. Diskapi Yildirim Beyazit Training and Research Hospital, Ankara, Turkey. Cryptogenic and secondary organizing pneumonia: clinical presentation, radiological and laboratory findings, treatment, and prognosis in 56 cases. *Turk Thorac J*. 2018;19(4):201–208. <https://doi.org/10.5152/TurkThoracJ.2018.18008>.
- Wong KT, Antonio GE, Hui DSC, et al. Thin-section CT of severe acute respiratory syndrome: evaluation of 73 patients exposed to or with the disease. *Radiology*. 2003;228(2):395–400. <https://doi.org/10.1148/radiol.2283030541>.
- Ooi GC, Khong PL, Müller NL, et al. Severe acute respiratory syndrome: temporal lung changes at thin-section CT in 30 patients. *Radiology*. 2004;230(3):836–844. <https://doi.org/10.1148/radiol.2303030853>.
- Ajlan AM, Ahayd RA, Jamjoom LG, Alharthy A, Madani TA. Middle east respiratory syndrome coronavirus (MERS-CoV) infection: chest CT findings. *Am J Roentgenol*. 2014;203(4):782–787. <https://doi.org/10.2214/AJR.14.13021>.
- Ajlan AM, Khashoggi K, Nicolaou S, Müller NL. CT Utilization in the prospective diagnosis of a case of swine-origin influenza A (H1N1) viral infection. *J Radiol Case Rep*. 2010;4(3):24–30. <https://doi.org/10.3941/jrcr.v4i3.427>.
- Zhou F, Yu T, Du R, et al. Clinical course and risk factors for mortality of adult inpatients with COVID-19 in Wuhan, China: a retrospective cohort study. *Lancet*. 2020;395(10229):1054–1062. [https://doi.org/10.1016/S0140-6736\(20\)30566-3](https://doi.org/10.1016/S0140-6736(20)30566-3).
- Vasu TS, Cavallazzi R, Hirani A, Sharma D, Weibel SB, Kane GC. Clinical and radiologic distinctions between secondary bronchiolitis obliterans organizing pneumonia and cryptogenic organizing pneumonia. *Respir Care*. 2009;54(8):5.
- Lazor R, Vandevenne A, Pelletier A, Leclerc P, Court-Fortune L, Cordier J-F. Cryptogenic organizing pneumonia. 2000;162:7.
- Li X, Ma X. Acute respiratory failure in COVID-19: is it “typical” ARDS? *Crit Care*. 2020;24(1):198. <https://doi.org/10.1186/s13054-020-02911-9>.
- Gattinoni L, Chiumello D, Caironi P, et al. COVID-19 pneumonia: different respiratory treatments for different phenotypes? *Intensive Care Med*. 2020;46(6):1099–1102. <https://doi.org/10.1007/s00134-020-06033-2>.
- Swenson KE, Ruoss SJ, Swenson ER. The pathophysiology and dangers of silent hypoxemia in COVID-19 lung injury. *Ann Am Thorac Soc*. 2021. <https://doi.org/10.1513/AnnalsATS.202011-1376CME>. Published online February 23, 2021;AnnalsATS.202011-1376CME.
- Jouiniaux V, Rodenstein DO, Mahjoub Y. On happy hypoxia and on sadly ignored “acute vascular distress syndrome” in patients with COVID-19. *Am J Respir Crit Care Med*. 2020;202(11):1598–1599. <https://doi.org/10.1164/rccm.202006-2521LE>.
- Tobin MJ, Laghi F, Jubran A. Why COVID-19 silent hypoxemia is baffling to physicians. *Am J Respir Crit Care Med*. 2020;202(3):356–360. <https://doi.org/10.1164/rccm.202006-2157CP>.
- Pan F, Ye T, Sun P, et al. Time course of lung changes on chest CT during recovery from 2019 novel coronavirus (COVID-19) pneumonia. *Radiology*. 2020. <https://doi.org/10.1148/radiol.2020200370>. Published online February 13, 2020;200370.
- Ding X, Xu J, Zhou J, Long Q. Chest CT findings of COVID-19 pneumonia by duration of symptoms. *Eur J Radiol*. 2020;127: 109009. <https://doi.org/10.1016/j.ejrad.2020.109009>.
- Bernheim A, Mei X, Huang M, et al. Chest CT findings in coronavirus disease-19 (COVID-19): relationship to duration of infection. *Radiology*. 2020. <https://doi.org/10.1148/radiol.2020200463>. Published online February 20, 2020;200463.
- Shi H, Han X, Jiang N, et al. Radiological findings from 81 patients with COVID-19 pneumonia in Wuhan, China: a descriptive study. *Lancet Infect Dis*. 2020;20(4):425–434. [https://doi.org/10.1016/S1473-3099\(20\)30086-4](https://doi.org/10.1016/S1473-3099(20)30086-4).
- Wang Y, Dong C, Hu Y, et al. Temporal changes of CT findings in 90 patients with COVID-19 pneumonia: a longitudinal study. *Radiology*. 2020;296(2):E55–E64. <https://doi.org/10.1148/radiol.202000843>.
- Zhang Z, Tang R, Sun H, et al. Temporal lung changes on thin-section CT in patients with COVID-19 pneumonia. *Sci Rep*. 2020;10(1):19649. <https://doi.org/10.1038/s41598-020-76776-x>.
- Kim SJ, Lee KS, Ryu YH, et al. Reversed halo sign on high-resolution CT of cryptogenic organizing pneumonia: diagnostic implications. *Am J Roentgenol*. 2003;180(5):1251–1254. <https://doi.org/10.2214/ajr.180.5.1801251>.
- Lee JW, Lee KS, Lee HY, et al. Cryptogenic organizing pneumonia: serial high-resolution CT findings in 22 patients. *Am J Roentgenol*. 2010;195(4):916–922. <https://doi.org/10.2214/AJR.09.3940>.
- Zare Mehrjardi M, Kahkouee S, Pourabdollah M. Radio-pathological correlation of organizing pneumonia (OP): a pictorial review. *Br J Radiol*. 2017;90(1071) 20160723. <https://doi.org/10.1259/bjr.20160723>.
- Mogami R, Lopes AJ, Araújo Filho RC, et al. Chest computed tomography in COVID-19 pneumonia: a retrospective study of 155 patients at a university hospital in Rio de Janeiro, Brazil. *Radiol Bras*. 2021;54(1):1–8. <https://doi.org/10.1590/0100-3984.2020.0133>.
- Wang Y, Jin C, Wu CC, et al. Organizing pneumonia of COVID-19: Time-dependent evolution and outcome in CT findings. *Tan W PLOS ONE*. 2020;15(11) e0240347. <https://doi.org/10.1371/journal.pone.0240347>.
- Agarwal PP, Cinti S, Kazerooni EA. *Chest Radiographic and CT Findings in Novel Swine-Origin Influenza A (H1N1) Virus (S-OIV) Infection*. 2009;2009:6. Published online.
- Duzgun SA, Durhan G, Demirkazik FB, Akpınar MG, Ariyurek OM. COVID-19 pneumonia: the great radiological mimicker. *Insights Imaging*. 2020;11(1):118. <https://doi.org/10.1186/s13244-020-00933-z>.
- Jin C, Tian C, Wang Y, et al. A pattern categorization of CT findings to predict outcome of COVID-19 pneumonia. *Front Public Health*. 2020;8: 567672. <https://doi.org/10.3389/fpubh.2020.567672>.
- Xiong Y, Sun D, Liu Y, et al. Clinical and high-resolution CT features of the COVID-19 infection: comparison of the initial and follow-up changes. *Invest Radiol*. March 2020;1. <https://doi.org/10.1097/RLI.0000000000000674>. Published online.
- Han X, Cao Y, Jiang N, et al. Novel coronavirus disease 2019 (COVID-19) pneumonia progression course in 17 discharged patients: comparison of clinical and thin-section computed tomography features during recovery. *Clin Infect Dis Off Publ Infect Dis Soc Am*. 2020;71(15):723–731. <https://doi.org/10.1093/cid/ciaa271>.
- Zhou S, Wang Y, Zhu T, Xia L. CT features of coronavirus disease 2019 (COVID-19) pneumonia in 62 patients in Wuhan, China. *Am J Roentgenol*. March 5, 2020;1–8. <https://doi.org/10.2214/AJR.20.22975>. Published online.
- The Lille COVID-19 ICU and Anatomopathology Group Copin M-C, Parmentier E, Duburcq T, Poissy J, Mathieu D. Time to consider histologic pattern of lung injury to treat critically ill patients with COVID-19 infection. *Intensive Care Med*. 2020;46(6):1124–1126. <https://doi.org/10.1007/s00134-020-06057-8>.

39. De Michele S, Sun Y, Yilmaz MM, et al. Forty postmortem examinations in COVID-19 patients. *Am J Clin Pathol*. 2020;154(6):748–760. <https://doi.org/10.1093/ajcp/aqaa156>.
40. Hanley B, Naresh KN, Roufousse C, et al. Histopathological findings and viral tropism in UK patients with severe fatal COVID-19: a post-mortem study. *Lancet Microbe*. 2020;1(6):e245–e253. [https://doi.org/10.1016/S2666-5247\(20\)30115-4](https://doi.org/10.1016/S2666-5247(20)30115-4).
41. Bhat V, Bhat V, Gadabanahalli K, Ramanjaneya R. *The Expanding Spectrum of COVID-19 Lung Imaging: Exploring Inputs from Radiologic-Pathologic Data for Disease Detection*. 7. 202120212021:10.
42. Nicholson AG, Osborn M, Devaraj A, Wells AU. COVID-19 related lung pathology: old patterns in new clothing? *Histopathology*. 2020;77(2):169–172. <https://doi.org/10.1111/his.14162>.
43. Kory P, Kanne JP. SARS-CoV-2 organising pneumonia: 'Has there been a widespread failure to identify and treat this prevalent condition in COVID-19?'. *BMJ Open Respir Res*. 2020;7(1):e000724. <https://doi.org/10.1136/bmjresp-2020-000724>.
44. Carsana L, Sonzogni A, Nasr A, et al. *Pulmonary Post-Mortem Findings in a Large Series of COVID-19 Cases from Northern Italy*. 2020. <https://doi.org/10.1101/2020.04.19.20054262>. Infectious Diseases (except HIV/AIDS).
45. Elsoukary SS, Mostyka M, Dillard A, et al. Autopsy findings in 32 patients with COVID-19: a single-institution experience. *Pathobiology*. 2021;88(1):56–68. <https://doi.org/10.1159/000511325>.
46. Buja LM, Wolf DA, Zhao B, et al. The emerging spectrum of cardiopulmonary pathology of the coronavirus disease 2019 (COVID-19): Report of 3 autopsies from Houston, Texas, and review of autopsy findings from other United States cities. *Cardiovasc Pathol Off J Soc Cardiovasc Pathol*. 2020;48: 107233. <https://doi.org/10.1016/j.carpath.2020.107233>.
47. Hariri LP, North CM, Shih AR, et al. Lung histopathology in coronavirus disease 2019 as compared with severe acute respiratory syndrome and H1N1 influenza. *Chest*. 2021;159(1):73–84. <https://doi.org/10.1016/j.chest.2020.09.259>.
48. Beasley MB, Franks TJ, Galvin JR, Gochoico B, Travis WD. Acute fibrinous and organizing pneumonia: a histological pattern of lung injury and possible variant of diffuse alveolar damage. *Arch Pathol Lab Med*. 2002;126(9):1064–1070. doi:10.1043/0003-9985(2002)126<1064:FAFOP>2.0.CO;2.
49. Feinstein MB, DeSouza SA, Moreira AL, et al. A comparison of the pathological, clinical and radiographical, features of cryptogenic organising pneumonia, acute fibrinous and organising pneumonia and granulomatous organising pneumonia. *J Clin Pathol*. 2015;68(6):441–447. <https://doi.org/10.1136/jclinpath-2014-202626>.
50. Borczuk AC, Salvatore SP, Seshan SV, et al. COVID-19 pulmonary pathology: a multi-institutional autopsy cohort from Italy and New York City. *Mod Pathol*. 2020;33(11):2156–2168. <https://doi.org/10.1038/s41379-020-00661-1>.
51. Hwang DM, Chamberlain DW, Poutanen SM, Low DE, Asa SL, Butany J. Pulmonary pathology of severe acute respiratory syndrome in Toronto. *Mod Pathol*. 2005;18(1):1–10. <https://doi.org/10.1038/modpathol.3800247>.
52. Ng W, To K, Lam W, Ng T, Lee K. The comparative pathology of severe acute respiratory syndrome and avian influenza A subtype H5N1—a review. *Hum Pathol*. 2006;37(4):381–390. <https://doi.org/10.1016/j.humpath.2006.01.015>.
53. Tse GM-K. Pulmonary pathological features in coronavirus associated severe acute respiratory syndrome (SARS). *J Clin Pathol*. 2004;57(3):260–265. <https://doi.org/10.1136/jcp.2003.013276>.
54. Otto C, Huzly D, Kemna L, et al. Acute fibrinous and organizing pneumonia associated with influenza A/H1N1 pneumonia after lung transplantation. *BMC Pulm Med*. 2013;13:30. <https://doi.org/10.1186/1471-2466-13-30>.
55. Roden AC, Bois MC, Johnson TF, et al. The spectrum of histopathologic findings in lungs of patients with fatal coronavirus disease 2019 (COVID-19) infection. *Arch Pathol Lab Med*. 2021;145(1):11–21. <https://doi.org/10.5858/arpa.2020-0491-SA>.
56. Zubieta-Calleja G, Zubieta-DeUrioste N. Pneumolysis and "Silent Hypoxemia" in COVID-19. *Indian J Clin Biochem*. 2021;36(1):112–116. <https://doi.org/10.1007/s12291-020-00935-0>.
57. The WHO Rapid Evidence Appraisal for COVID-19 Therapies (REACT) Working Group-Sterne JAC, Murthy S, et al. The WHO Rapid Evidence Appraisal for COVID-19 Therapies (REACT) Working Group. Association between administration of systemic corticosteroids and mortality among critically ill patients with COVID-19: a meta-analysis. *JAMA*. 2020;324(13):1330. <https://doi.org/10.1001/jama.2020.17023>.
58. The RECOVERY Collaborative Group. Dexamethasone in hospitalized patients with Covid-19 — preliminary report. *N Engl J Med*. July 17, 2020 NEJMoa2021436. <https://doi.org/10.1056/NEJMoa2021436>. Published online.
59. Arabi YM, Mandourah Y, Al-Hameed F, et al. Corticosteroid Therapy for critically ill patients with middle east respiratory syndrome. *Am J Respir Crit Care Med*. 2018;197(6):757–767. <https://doi.org/10.1164/rccm.201706-11720C>.
60. Auyeung TW, Lee JSW, Lai WK, et al. The use of corticosteroid as treatment in SARS was associated with adverse outcomes: a retrospective cohort study. *J Infect*. 2005;51(2):98–102. <https://doi.org/10.1016/j.jinf.2004.09.008>.
61. Zhou Y, Fu X, Liu X, et al. Use of corticosteroids in influenza-associated acute respiratory distress syndrome and severe pneumonia: a systemic review and meta-analysis. *Sci Rep*. 2020;10(1):3044. <https://doi.org/10.1038/s41598-020-59732-7>.
62. Takumida H, Izumi S, Sakamoto K, et al. Sustained coronavirus disease 2019-related organizing pneumonia successfully treated with corticosteroid. *Respir Investig* January 2021 S2212534521000022. <https://doi.org/10.1016/j.resinv.2020.12.005>. Published online.
63. Vadász I, Husain-Syed F, Dorfmueller P, et al. Severe organising pneumonia following COVID-19. *Thorax*. November 11, 2020. <https://doi.org/10.1136/thoraxjnl-2020-216088>. Published online thoraxjnl-2020-216088.
64. Bae I-G, Hong K-W, Yang J-W, et al. Persistent pneumonic consolidations due to secondary organizing pneumonia in a patient recovering from covid-19 pneumonia: a case report. In Review; 2020. doi:10.21203/rs.3.rs-37580/v1.
65. Kanaoka K, Minami S, Ihara S, Tanaka T, Yasuoka H, Komuta K. Secondary organizing pneumonia after coronavirus disease 2019: two cases. *Respir Med Case Rep*. 2021;32: 101356. <https://doi.org/10.1016/j.rmcr.2021.101356>.
66. Myall KJ, Mukherjee B, Castanheira AM, et al. Persistent post-COVID-19 inflammatory interstitial lung disease: an observational study of corticosteroid treatment. *Ann Am Thorac Soc*. January 12, 2021. <https://doi.org/10.1513/AnnalsATS.202008-10020C>. Published online AnnalsATS.202008-10020C.
67. de Oliveira Filho CM, Vieceli T, de Fraga Bassotto C, da Rosa Barbato JP, Garcia TS, Scheffel RS. Organizing pneumonia: a late phase complication of COVID-19 responding dramatically to corticosteroids. *Braz J Infect Dis*. 2021;25(1) 101541. <https://doi.org/10.1016/j.bjid.2021.101541>.
68. López-Cuenca S, Morales-García S, Martín-Hita A, Frutos-Vivar F, Fernández-Segoviano P, Esteban A. Severe acute respiratory failure secondary to acute fibrinous and organizing pneumonia requiring mechanical ventilation: a case report and literature review. *Respir Care*. 2012;57(8):1337–1341. <https://doi.org/10.4187/respcare.01452>.
69. Wang K, Du X, Wu Q, Cheng D. A case report of acute fibrinous and organizing pneumonia. *Medicine (Baltimore)*. 2019;98(49):e18140. <https://doi.org/10.1097/MD.00000000000018140>.
70. Cornejo R, Llanos O, Fernandez C, et al. Organizing pneumonia in patients with severe respiratory failure due to novel A (H1N1) influenza. *Case Rep*. 2010;2010(jul16 2). <https://doi.org/10.1136/bcr.02.2010.2708>. bcr0220102708-bcr0220102708.
71. Kim I, Lee JE, Kim K-H, Lee S, Lee K, Mok JH. Successful treatment of suspected organizing pneumonia in a patient with Middle East respiratory syndrome coronavirus infection: a case report. *J Thorac Dis*. 2016;8(10):E1190–E1194. <https://doi.org/10.21037/jtd.2016.09.26>.
72. Furtado RHM, Berwanger O, Fonseca HA, et al. Azithromycin in addition to standard of care versus standard of care alone in the treatment of patients admitted to the hospital with severe COVID-19 in Brazil (COALITION II): a randomised clinical trial. *Lancet*. 2020;396(10256):959–967. [https://doi.org/10.1016/S0140-6736\(20\)31862-6](https://doi.org/10.1016/S0140-6736(20)31862-6).
73. Wahidi MM, Lamb C, Murgu S, et al. American Association for Bronchology and Interventional Pulmonology (AABIP) Statement on the Use of Bronchoscopy and Respiratory Specimen Collection in Patients with Suspected or Confirmed COVID-19 Infection. *J Bronchol Interv Pulmonol*. 2020. <https://doi.org/10.1097/LBR.0000000000000681>. Publish Ahead of Print.
74. Fajgenbaum DC, June CH. Cytokine Storm. *Longo DL, ed. N Engl J Med*. 2020;383(23):2255–2273. <https://doi.org/10.1056/NEJMra2026131>.
75. Ye Q, Wang B, Mao J. The pathogenesis and treatment of the 'Cytokine Storm' in COVID-19. *J Infect*. 2020;80(6):607–613. <https://doi.org/10.1016/j.jinf.2020.03.037>.
76. Pernazza A, Mancini M, Rullo E, et al. Early histologic findings of pulmonary SARS-CoV-2 infection detected in a surgical specimen. *Virchows Arch Int J Pathol*. 2020;477(5):743–748. <https://doi.org/10.1007/s00428-020-02829-1>.
77. Pogatchnik BP, Swenson KE, Sharifi H, Bedi H, Berry GJ, Guo HH. Radiology-pathology correlation in recovered COVID-19, demonstrating organizing pneumonia. *Am J Respir Crit Care Med*. July 1, 2020. <https://doi.org/10.1164/rccm.202004-12781M>. Published online.
78. McLaren TA, Gruden JF, Green DB. The bullseye sign: a variant of the reverse halo sign in COVID-19 pneumonia. *Clin Imaging*. 2020;68:191–196. <https://doi.org/10.1016/j.clinimag.2020.07.024>.
79. Tian S, Hu W, Niu L, Liu H, Xu H, Xiao S-Y. Pulmonary pathology of early-phase 2019 novel coronavirus (COVID-19) pneumonia in two patients with lung cancer. *J Thorac Oncol Off Publ Int Assoc Study Lung Cancer*. 2020;15(5):700–704. <https://doi.org/10.1016/j.jtho.2020.02.010>.
80. Fang Y, Zhang H, Xu Y, Xie J, Pang P, Ji W. CT Manifestations of two cases of 2019 novel coronavirus (2019-nCoV) pneumonia. *Radiology*. 2020;295(1):208–209. <https://doi.org/10.1148/radiol.2020020280>.
81. Rea G. The many faces of covid-19: organizing pneumonia (OP) pattern HRCT features. *Transl Med UniSa*. 2020;23(4). <https://doi.org/10.37825/2239-9747.1001>.
82. Zhang H, Zhou P, Wei Y, et al. Histopathologic changes and SARS-CoV-2 immunostaining in the lung of a patient with COVID-19. *Ann Intern Med*. 2020;172(9):629–632. <https://doi.org/10.7326/M20-0533>.
83. Horii H, Kamada K, Nakakubo S, et al. Rapidly progressive organizing pneumonia associated with COVID-19. *Respir Med Case Rep*. 2020;31: 101295. <https://doi.org/10.1016/j.rmcr.2020.101295>.
84. John TM, Malek AE, Mulanovich VE, et al. Migratory pulmonary infiltrates in a patient with COVID-19 infection and the role of corticosteroids. *Mayo Clin Proc*. 2020;95(9):2038–2040. <https://doi.org/10.1016/j.mayocp.2020.06.023>.
85. Okamori S, Lee H, Kondo Y, et al. Coronavirus disease 2019-associated rapidly progressive organizing pneumonia with fibrotic feature: two case reports. *Medicine (Baltimore)*. 2020;99(35):e21804. <https://doi.org/10.1097/MD.00000000000021804>.
86. Rea G, Valente T, Lieto R, et al. The many faces of covid-19: organizing pneumonia (OP) pattern HRCT features. *Transl Med UniSa*. 2020;23:16–18.
87. Simões JP, Alves Ferreira AR, Almeida PM, et al. Organizing pneumonia and COVID-19: a report of two cases. *Respir Med Case Rep*. 2021;32: 101359. <https://doi.org/10.1016/j.rmcr.2021.101359>.