

Available online at www.sciencedirect.com

ScienceDirect

journal homepage: www.elsevier.com/locate/radcr

Case report

Cutaneous metastasis as a first sign of breast carcinoma [☆]

Amalik Sanae, Resident in Radiology*, Imrani Kaoutar, Resident in Radiology, El Fenni Jamal, Professor in Radiology, Edderai Meryem, Professor in Radiology

Radiology department, Military Hospital Mohammed V, Rabat, Morocco

ARTICLE INFO

Article history:

Received 30 March 2021

Revised 23 April 2021

Accepted 25 April 2021

Keywords:

Cutaneous metastasis

Breast cancer

Squamous cell carcinoma

ABSTRACT

Unlike visceral, lymphonodal or bone metastases, skin metastases are rare and their identification portends of a bad prognosis. They may appear as the first sign revealing the primary tumour, synchronous or developing late in the course of neglected primary cancer. We report a case of 86 year-old women witch belongs to this rare group of patients in whom cutaneous metastasis were identified before the primary cancer. This case showed the interest of biopsy and imaging in the confirmation of the diagnosis.

© 2021 The Authors. Published by Elsevier Inc. on behalf of University of Washington.

This is an open access article under the CC BY-NC-ND license

(<http://creativecommons.org/licenses/by-nc-nd/4.0/>)

Introduction

Cutaneous metastasis account for 1-10% of all metastases and breast cancer represent 30% of all cases [1]. They can be the first sign revealing a clinically silent cancer or the first manifestation of a recurrence of treated cancer [1]. We report a case of 86 year-old women who presented with skin lesions distributed across the abdomen as the first sign of breast squamous cell carcinoma.

Case report

An 86 year-old female patient reported the appearance of multiple asymptomatic cutaneous nodules 1 month prior to the

consultation. She had a history of hypertension and type II diabetes mellitus with no relevant family history.

Clinical examination revealed erythematous and ulcerated plaque with superficial erosions and crusting (Fig. 1). This lesion had well defined margins, and was fixed to underlying tissues, measuring 3 - 4 cm, associated to satellite indurated nodules with no other accompanying symptoms.

Histopathological examination of the skin biopsy, performed on the cutaneous nodules, showed an undifferentiated malignant tumor and the sample was sent for immunohistochemical examination.

Immunohistochemical markers were negative for antibody anti- CK7 (OV-TL 12/30, Bio SB), antibody anti-CK20 (KS20.8, Bio SB), antibody anti-CDX-2 (EP25, Bio SB), antibody anti-TTF1 (8G7G3/1, Bio SB), antibody anti-HMB45 (HMB45, Bio SB), antibody anti- RE (SP&, ThermoScientific) and antibody anti-

[☆] Competing Interests: The authors have declared that no competing interests exist.

* Corresponding author. A.Sanae

E-mail address: sanaeamalik@gmail.com (A. Sanae).

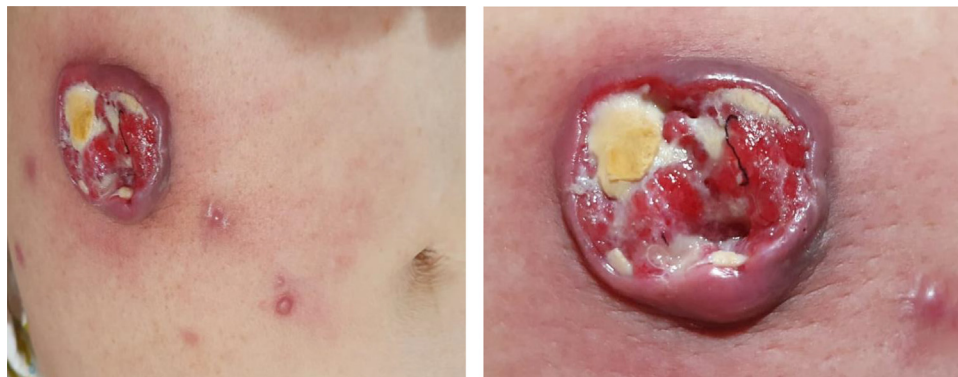

Fig. 1 – Erythematous and ulcerated plaque with superficial erosions associated with satellite indurated nodules.

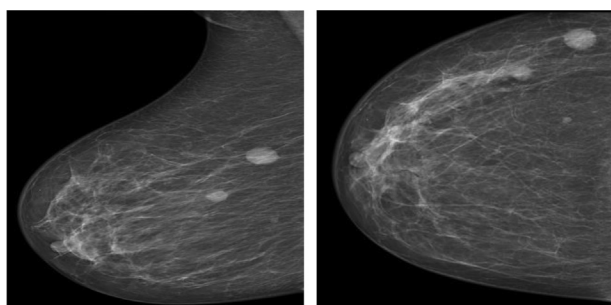


Fig. 2 – Two high-density round masses with well circumscribed borders in the upper outer right quadrant

GATA-3(L50-823, Bio SB) and positive for antibody anti-P 40 (polyclonal- Diagnostic Biosystems).

Immunohistochemistry showed a dermal location of an invasive, little differentiated, squamous cell carcinoma, whose primary or secondary origin requires deeper investigations.

Thoracic, abdominal and pelvic computed tomography (CT) imaging revealed two masses within the upper outer quadrant of the right breast with ipsilateral axillary lymphadenopathy, three subpleural pulmonary nodules, inguinal and iliac lymph nodes suspicious of malignancy.

Given the computed tomography findings, the patient underwent breast ultrasound and mammography to better study the breast masses which confirmed the presence of two hypoechoic irregular masses in the upper outer right quadrant

with lateral attenuation measuring 12×13 mm and 10×9 mm classified as Birads 4, with right axillary adenopathy (Fig. 2, Fig. 3).

Ultrasound-guided core needle biopsy was taken from the largest breast lesion and immunohistochemical markers were positive for CK 5-6 and P40. The breast mass biopsy result confirmed the diagnosis of metaplastic breast cancer (squamous cell carcinoma). The patient was referred to the Oncology Department for further treatment.

Discussion

In women, breast carcinoma is the second most common cancer and the most common tumor causing skin metastasis, with an estimated incidence of 23,9% [2]. Infrequently, skin metastasis may appear as the first clinical manifestation of breast cancer [3].

The most common localization of cutaneous manifestations of breast carcinoma are the chest wall and abdomen, but they can occur less frequently to the back, upper arms and rarely to the buttocks, perianal region, lower extremities and eyelids [4].

Cutaneous metastases have several aspects and nodules are the most common presentation. Metastatic nodules are generally few in number and may adopt a regional grouping that varies depending on the nature of the primary cancer. They are firm and usually painless [4]. The histological and

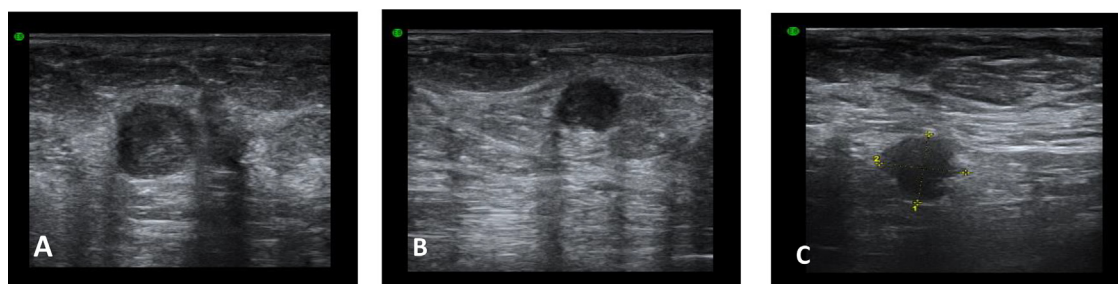

Fig. 3 – Two irregular hypoechoic suspicious lesions (A,B) in the upper outer right quadrant with lateral attenuation, measuring 12×13 mm and 10×9 mm classified as Birads 4 with right axillary adenopathy suspicious of malignancy (C) .

immunohistological examinations help establishing the diagnosis [1,4].

Cutaneous metastasis from breast cancer usually occur in advanced stages and have poor prognosis, with nearly half of patients dying within 6 months of diagnosis [3].

Conclusion

Skin metastases most often appear during a known neoplasia. However, they may appear as the first clinical manifestation of breast cancer. Their clinical aspects are nonspecific. Therefore their early recognition, especially in breast cancer cases leads to rapid implementation of treatment to reduce morbidity and mortality.

Patient consent statement

Written informed consent for publication was obtained from the patient.

REFERENCES

- [1] Araújo E, Barbosa M, Costa R, Sousa B, Costa V. A first sign not to be missed: cutaneous metastasis from breast cancer. *EJCRIM* 2020;7. doi:10.12890/2020_001356.
- [2] Bittencourt MJS, Carvalho AH, Macêdo do Nascimento BA, Freitas LKM, Amanda MP. Cutaneous metastasis of a breast cancer diagnosed 13 years before. *An Bras Dermatol* 2015;90(3 Suppl 1):S134–7.
- [3] Prabhu S, Pai SB, Handattu S, Kudur MH, Vasanth V. Cutaneous metastases from carcinoma breast: The common and the rare. *Indian J Dermatol Venereol Leprol* 2009;75:499–502.
- [4] Giorgi VDe, Grazzini M, Alfaioli B, Savarese I, Corciova SA, Guerriero G, et al. Cutaneous manifestations of breast carcinoma. *Dermatol Therap* 2010;23:581–9.