

## Eosinophilic gastroenteritis with abdominal pain and ascites: A case report

Xiao-Qing Tian, Xiang Chen, Sheng-Liang Chen

**ORCID number:** Xiao-Qing Tian 0000-0003-4265-7679; Xiang Chen 0000-0002-6550-5494; Sheng-Liang Chen 0000-0001-7672-5014.

**Author contributions:** Tian XQ and Chen X were the patient's physicians in charge, reviewed the literature and contributed to manuscript drafting; Chen SL reviewed the literature and drafted the manuscript; All authors issued final approval for the version to be submitted.

### Informed consent statement:

Informed written consent was obtained from the patient for publication of this report and any accompanying images.

**Conflict-of-interest statement:** The authors declare that they have no conflict of interest.

### CARE Checklist (2016) statement:

The authors have read the CARE Checklist (2016), and the manuscript was prepared and revised according to the CARE Checklist (2016).

**Open-Access:** This article is an open-access article that was selected by an in-house editor and fully peer-reviewed by external reviewers. It is distributed in accordance with the Creative Commons Attribution NonCommercial (CC BY-NC 4.0)

Xiao-Qing Tian, Xiang Chen, Sheng-Liang Chen, Department of Gastroenterology, Renji Hospital, School of Medicine, Shanghai Jiao Tong University, Shanghai 200001, China

**Corresponding author:** Sheng-Liang Chen, MD, PhD, Doctor, Department of Gastroenterology, Renji Hospital, School of Medicine, Shanghai Jiao Tong University, No. 145 Middle Shandong Road, Shanghai 200001, China. [chenslmd@163.com](mailto:chenslmd@163.com)

## Abstract

### BACKGROUND

Eosinophilic gastroenteritis (EGE) is a rare disease that presents many unspecific gastroenterological symptoms. The disease includes three types depending on the depth of eosinophil infiltration in the gastrointestinal tract. The serosal type is the most rare, presenting as ascites.

### CASE SUMMARY

A 34-year-old man presented with abdominal pain, diarrhea without bloody stool, or nausea. Laboratory test results revealed a peripheral blood eosinophil count ( $4.85 \times 10^9/L$ ), which was remarkably elevated. Computed tomography scan demonstrated extensive intestinal wall edema thickening in the duodenum, jejunum, ascending colon and transverse colon; multiple exudative effusion surrounding the intestinal tract, and ascites in the abdominal cavity. A series of examinations excluded eosinophil elevation in secondary diseases. Endoscopic multipoint biopsy detected eosinophilic infiltration in the mucous layer of the transverse colon, with  $\geq 50$  eosinophils/high power field. All symptoms vanished after a few days of steroid therapy and ascites disappeared within 2 wk.

### CONCLUSION

EGE should be considered in patients with abdominal pain, ascites, and eosinophilia. Multiple point biopsies are essential for diagnosis.

**Key Words:** Eosinophilic gastroenteritis; Abdominal pain; Ascites; Endoscopy; Prednisone; Case report

©The Author(s) 2021. Published by Baishideng Publishing Group Inc. All rights reserved.

license, which permits others to distribute, remix, adapt, build upon this work non-commercially, and license their derivative works on different terms, provided the original work is properly cited and the use is non-commercial. See: <http://creativecommons.org/licenses/by-nc/4.0/>

**Manuscript source:** Unsolicited manuscript

**Specialty type:** Gastroenterology and hepatology

**Country/Territory of origin:** China

**Peer-review report's scientific quality classification**

Grade A (Excellent): 0  
Grade B (Very good): B  
Grade C (Good): 0  
Grade D (Fair): 0  
Grade E (Poor): 0

**Received:** January 24, 2021

**Peer-review started:** January 24, 2021

**First decision:** March 8, 2021

**Revised:** March 21, 2021

**Accepted:** April 9, 2021

**Article in press:** April 9, 2021

**Published online:** June 16, 2021

**P-Reviewer:** Baryshnikova NV

**S-Editor:** Liu M

**L-Editor:** Filipodia

**P-Editor:** Li X



**Core Tip:** Eosinophilic gastroenteritis (EGE) is a rare disease that presents many unspecific gastroenterological symptoms. We present a case with abdominal pain, ascites, and eosinophilia after raw and cold seafood. The patient was eventually diagnosed with EGE based on biopsy findings. The case highlights the ultimate importance of multiple point biopsies in diagnosis and the effectiveness of corticosteroid therapy in EGE patients.

**Citation:** Tian XQ, Chen X, Chen SL. Eosinophilic gastroenteritis with abdominal pain and ascites: A case report. *World J Clin Cases* 2021; 9(17): 4238-4243

**URL:** <https://www.wjgnet.com/2307-8960/full/v9/i17/4238.htm>

**DOI:** <https://dx.doi.org/10.12998/wjcc.v9.i17.4238>

## INTRODUCTION

Eosinophilic gastroenteritis (EGE) is a rare inflammatory disease with many unspecific presentations, depending on the depth of eosinophil infiltration in gastrointestinal (GI) tract[1]. EGE can affect the entire GI tract, with the antrum and duodenum being the most common sites. Symptoms correlate with the affected segment and layer of the GI wall. The diagnosis of EGE requires high sensitivity for this disease in the clinic. EGE is diagnosed according to GI mucosa pathology.

Here, we report a case of EGE that presented with abdominal pain and diarrhea.

## CASE PRESENTATION

### Chief complaints

A 34-year-old man was admitted to the emergency department due to abdominal pain and diarrhea for 1 d.

### History of present illness

One day earlier, the patient had eaten raw and cold seafood with several friends. He reported the aggravation of abdominal pain for 6 h. He denied other symptoms including fever, vomiting, hematochezia, skin rash, as well as recent medication intake.

### History of past illness

He had a history of recurrent iritis, spondylarthritis, and chronic viral hepatitis B. He denied a previous history of asthma and seasonal allergic rhinitis.

### Personal and family history

The patient had no special family history.

### Physical examination

On physical examination, the patient's temperature was 37.3 °C, heart rate was 98 beats per min, respiratory rate was 18 breaths per min, blood pressure was 128/80 mmHg, and oxygen saturation in room air was 99%. There was abdominal tenderness and no rebound pain. The cardiopulmonary examination was normal. The clinical neurological examination was also normal.

### Laboratory examinations

Blood tests revealed leukocytosis (14560/ $\mu$ L) with 15.6% of eosinophils (2270/ $\mu$ L), which was marginally elevated. C-reactive protein was only slightly elevated (8.13 mg/L). There was no elevation of hepatobiliary and pancreatic enzyme levels. His feces test was negative for occult blood and multiple enteric pathogens. The parasitological exams in his stool and blood were also negative. Serum IgE level was normal. T-spot test was within normal ranges. To exclude other systemic diseases, the rheumatological index, serum protein electrophoresis, and immunostationary electrophoresis were tested, which were negative. To rule out blood diseases, peripheral

blood smear and FIP1L1-PDGFRa fusion gene qualitative test were performed, which were both negative. Laboratory test of ascitic fluid was suggested as exudate with a low serum albumin-ascitic gradient, as well as bacterial culture and tuberculosis was negative.

### **Imaging examinations**

Computed tomography scan demonstrated extensive intestinal wall edema thickening in the duodenum, jejunum, ascending colon and transverse colon; multiple exudative effusion surrounding the intestinal tract; and ascites in the abdominal cavity (Figure 1).

---

## **FURTHER DIAGNOSTIC WORK-UP**

For further diagnosis, colonoscopy was performed. Terminal ileum and the entire colonic mucosa scattered in hyperemia and edema (Figure 2). Multiple point biopsies were taken respectively from the terminal ileum, ascending colon, transverse colon, and rectum. The gastroscopy showed “hyperemia of the body and antrum mucosa”; biopsies were taken from multiple sites including the esophagus, gastric body, gastric antrum, duodenal bulb, and descending duodenal part.

---

## **PATHOLOGICAL RESULTS**

Multiple colon biopsies showed the following results: active enteritis with multiple lymphatic follicles forming in the terminal ileum; increased intraepithelial lymphocytes and interstitial eosinophils ( $\geq 20$  eosinophils/high power field (HPF) in the ascending colon; interstitial edema and significant increased interstitial eosinophils ( $> 50$  eosinophils/HPF) with degranulation in the transverse colon (Figure 3); and inflammatory cell infiltration with interstitial edema in the rectum. The pathology results of the gastroscopy biopsies showed little eosinophilic infiltration.

---

## **FINAL DIAGNOSIS**

The final diagnosis of the presented case was EGE.

---

## **TREATMENT**

The patient was treated with 40 mg methylprednisolone/day. Following treatment, his abdominal pain vanished in a few days and ascites disappeared within 2 wk. The dose of prednisone was gradually reduced until it was discontinued after 6 mo.

---

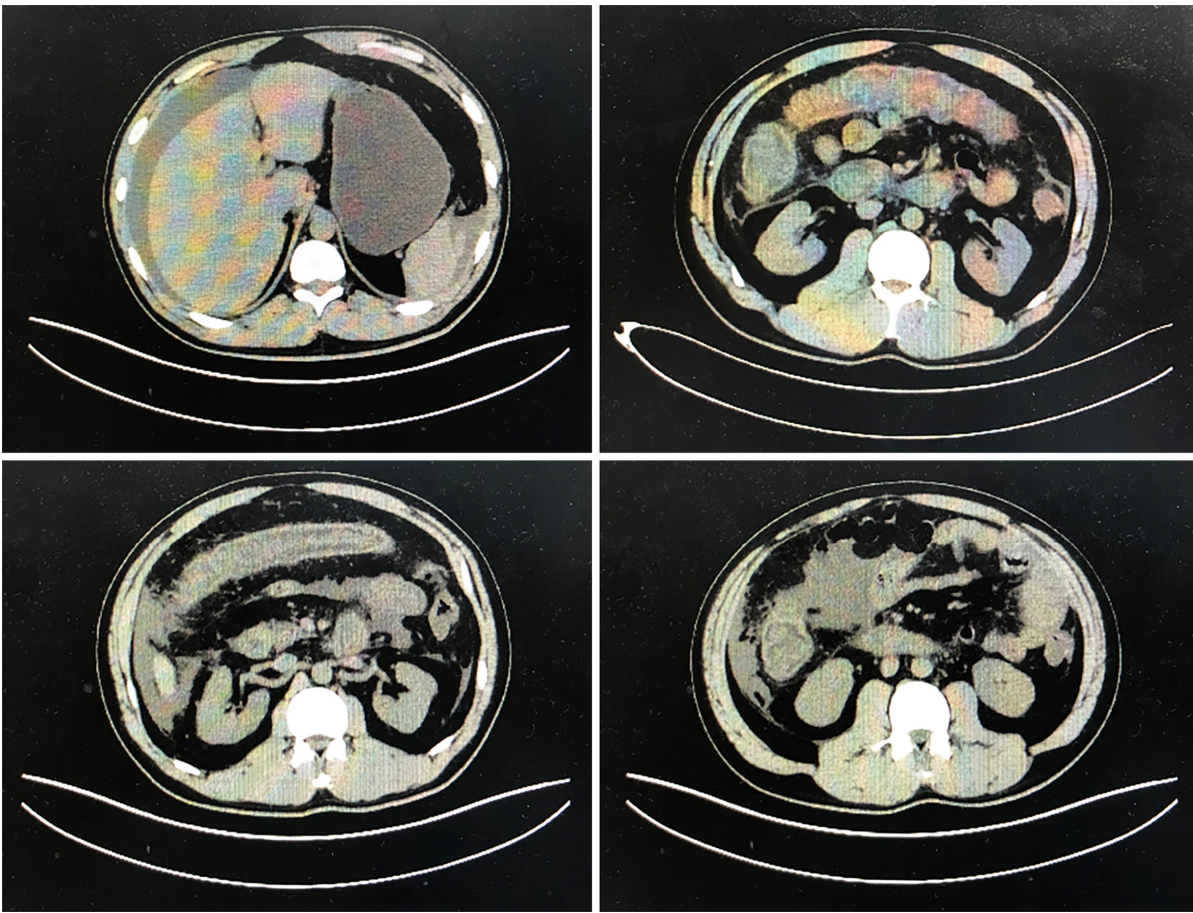
## **OUTCOME AND FOLLOW-UP**

To date, the patient had stopped taking corticosteroids for 6 mo and remains asymptomatic.

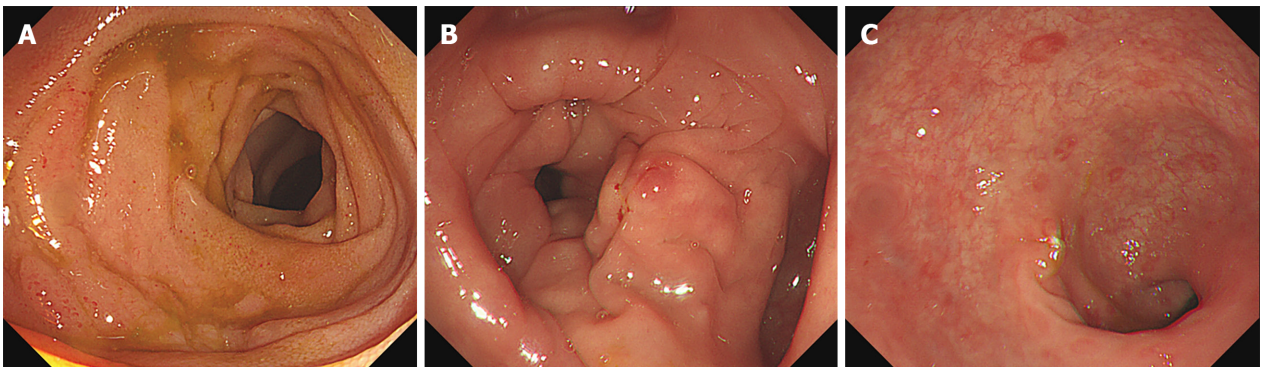
---

## **DISCUSSION**

EGE is a rare disorder that presents with nonspecific clinical symptoms. Prevalence is from 8.4 to 28 per 100000, which is higher in children. Most adults are diagnosed between 30-years-old and 50-years-old[2]. Diagnosis requires a high degree of vigilance. More than 50% of the reported EGE cases have other allergic diseases including rhinitis, eczema, asthma, drug allergies, or food allergies[2,3]. A relationship with some autoimmune disorders has been described such as celiac disease, ulcerative colitis, and systemic lupus erythematosus[3]. It is essential to exclude other diseases such as parasitosis, tuberculosis, and cancer.

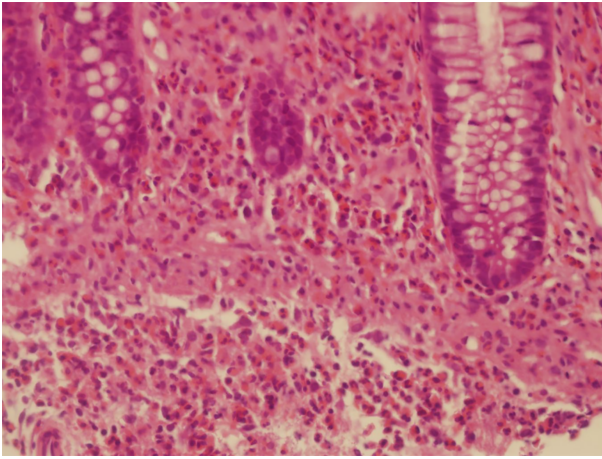


**Figure 1** Abdominal computed tomography scan. Abdominal computed tomography scan demonstrated extensive intestinal wall edema thickening in the duodenum, jejunum, ascending colon and transverse colon; multiple exudative effusion surrounding the intestinal tract; and ascites in the abdominal cavity.



**Figure 2** Colonoscopy results showed the terminal ileum and entire colonic mucosa scattered in hyperemia and edema. A: Terminal ileum; B: Transverse colon; C: Rectum.

The clinical manifestations of EGE depend on the location, range, and depth of eosinophilic infiltration of the GI wall. EGE was classified into three types according to the depth of eosinophilic infiltration: mucosal, muscular, and serosal. The disease with the mucosal layer infiltration is the most frequent type. This type present with nonspecific symptoms include general abdominal pain, nausea, vomiting, and diarrhea. The severe patient may present with GI bleeding, iron deficiency anemia, and protein-losing enteropathy. The second type is eosinophilic infiltration in the muscular layer, causing thickening of the digestive tract wall and intestinal obstruction[4]. The serosal type is in only 10% reported cases[5], presenting with ascites. The characteristic of this type is eosinophilia in the ascitic fluid. This type has a better response to steroid therapy, without a chronic course[4].



**Figure 3** Biopsy results confirm the diagnosis of eosinophilic gastroenteritis. Biopsies showed mucosa with interstitial edema and eosinophilic infiltration throughout the whole colon region with  $\geq 20$  eosinophils/high power field (HPF). A maximum of 50 eosinophils/HPF were found in the transverse colon (hematoxylin and eosin staining; 400  $\times$ ).

As absence of unified diagnostic criteria, the cutoff value for eosinophil counts should be individualized to the different biopsy sites[6]. To confirm the histological pathological diagnosis, many researchers have suggested that at least 20 eosinophils/HPF are considered necessary[7].

Treatment with corticosteroids are generally effective in EGE patients. Prednisolone dose typically starts at 40 mg/d for 7-14 d, then gradually decreases. Second-line therapies include antihistamines, mast cell stabilizers (sodium cromoglycate), leukotriene antagonists (montelukast), elimination diet (elimination of milk, soy, wheat, eggs, peanuts, and seafood), immunomodulators (azathioprine), tumor necrosis factors inhibitors (infliximab), mepolizumab, and IgE monoclonal antibody (omalizumab)[8].

The course and prognosis of different patients are variable. Some patients do not relapse, while other patients have recurring symptoms and require repeated or long-term steroid therapy. In these patients, the second-line therapies mentioned above may be considered[9].

## CONCLUSION

According to this case, EGE should be considered in patients with abdominal pain, ascites, and eosinophilia in blood routine examination, especially after a special diet. Multiple point biopsies are essential for diagnosis. Treatment with corticosteroids is generally effective in EGE patients.

## REFERENCES

- 1 Tien FM, Wu JF, Jeng YM, Hsu HY, Ni YH, Chang MH, Lin DT, Chen HL. Clinical features and treatment responses of children with eosinophilic gastroenteritis. *Pediatr Neonatol* 2011; **52**: 272-278 [PMID: 22036223 DOI: 10.1016/j.pedneo.2011.06.006]
- 2 Abou Rached A, El Hajj W. Eosinophilic gastroenteritis: Approach to diagnosis and management. *World J Gastrointest Pharmacol Ther* 2016; **7**: 513-523 [PMID: 27867684 DOI: 10.4292/wjgpt.v7.i4.513]
- 3 Shih HM, Bair MJ, Chen HL, Lin IT. Eosinophilic Gastroenteritis : Brief Review. *Acta Gastroenterol Belg* 2016; **79**: 239-244 [PMID: 27382945]
- 4 Uppal V, Kreiger P, Kutsch E. Eosinophilic Gastroenteritis and Colitis: a Comprehensive Review. *Clin Rev Allergy Immunol* 2016; **50**: 175-188 [PMID: 26054822 DOI: 10.1007/s12016-015-8489-4]
- 5 Quack I, Sellin L, Buchner NJ, Theegarten D, Rump LC, Henning BF. Eosinophilic gastroenteritis in a young girl--long term remission under Montelukast. *BMC Gastroenterol* 2005; **5**: 24 [PMID: 16026609 DOI: 10.1186/1471-230X-5-24]
- 6 Matsushita T, Maruyama R, Ishikawa N, Harada Y, Araki A, Chen D, Tauchi-Nishi P, Yuki T, Kinoshita Y. The number and distribution of eosinophils in the adult human gastrointestinal tract: a study and comparison of racial and environmental factors. *Am J Surg Pathol* 2015; **39**: 521-527 [PMID: 25581733 DOI: 10.1097/PAS.0000000000000370]

- 7 **Kinoshita Y**, Ishimura N, Oshima N, Mikami H, Okimoto E, Jiao DJ, Ishihara S. Recent Progress in the Research of Eosinophilic Esophagitis and Gastroenteritis. *Digestion* 2016; **93**: 7-12 [PMID: 26789117 DOI: 10.1159/000441668]
- 8 **Alhmod T**, Hanson JA, Parasher G. Eosinophilic Gastroenteritis: An Underdiagnosed Condition. *Dig Dis Sci* 2016; **61**: 2585-2592 [PMID: 27234270 DOI: 10.1007/s10620-016-4203-5]
- 9 **Straumann A**. Idiopathic eosinophilic gastrointestinal diseases in adults. *Best Pract Res Clin Gastroenterol* 2008; **22**: 481-496 [PMID: 18492567 DOI: 10.1016/j.bpg.2007.09.001]



Published by **Baishideng Publishing Group Inc**  
7041 Koll Center Parkway, Suite 160, Pleasanton, CA 94566, USA

**Telephone:** +1-925-3991568

**E-mail:** [bpgoffice@wjgnet.com](mailto:bpgoffice@wjgnet.com)

**Help Desk:** <https://www.f6publishing.com/helpdesk>

<https://www.wjgnet.com>

