

## Evaluation of characteristics of the craniofacial complex and dental maturity in girls with central precocious puberty

Hee-Kyung Lee<sup>a</sup>; Sung-Hwan Choi<sup>b</sup>; Dong Fan<sup>c</sup>; Kyung-Mi Jang<sup>d</sup>; Min-Seon Kim<sup>e</sup>; Chung-Ju Hwang<sup>f</sup>

### ABSTRACT

**Objectives:** To identify unique characteristics of the craniofacial complex and dental maturity in girls with central precocious puberty (CPP).

**Materials and Methods:** This study included 34 Korean girls with idiopathic CPP (mean age,  $8.6 \pm .5$  years) and 28 normal healthy girls of the same chronological age. An initial evaluation of the growth pattern of the craniofacial complex and dental maturity was conducted by analyzing lateral cephalometric and panoramic radiographs.

**Results:** The mandibular ramus height ( $44.4 \pm 4.1$  mm) and total mandibular length ( $10.8 \pm 4.3$  mm) ( $P = .004$  and  $.021$ , respectively) were greater and the lower anterior facial height was lesser ( $63.2 \pm 2.4$  mm) ( $P = .040$ ) in the CPP group than in the reference group. In addition, the gonial angle ( $12.9 \pm 6.1^\circ$ ;  $P = .045$ ) and the mandibular plane angle ( $34.9 \pm 4.8^\circ$ ;  $P = .012$ ) were smaller in girls with CPP than in normal healthy girls. All the mandibular teeth were more mature in girls with CPP ( $P < .001$ ). A strong positive correlation was observed between the mandibular tooth formation stages and the presence of CPP in girls ( $r = .756$  to  $.957$ ;  $P < .001$ ).

**Conclusions:** CPP had an effect on the anteroposterior growth of the mandible in the craniofacial complex and the rotation of the mandibular plane angle. Early maturation of the mandibular teeth was observed in girls with CPP. (*Angle Orthod.* 2018;88:582–589.)

**KEY WORDS:** Central precocious puberty; Craniofacial complex; Dental maturity; Bone age

### INTRODUCTION

Precocious puberty is defined as the appearance of Tanner Stage 2 secondary sexual characteristics,

\* Contributed equally to this work.

<sup>a</sup> Professor, Department of Dentistry, College of Medicine, Yeungnam University, Daegu, Korea.

<sup>b</sup> Assistant Professor, Department of Orthodontics, Institute of Craniofacial Deformity, College of Dentistry, Yonsei University, Seoul, Korea.

<sup>c</sup> Graduate Student, Department of Dentistry, College of Medicine, Yeungnam University, Daegu, Korea.

<sup>d</sup> Fellow, Department of Pediatrics and Adolescent Medicine, College of Medicine, Yeungnam University, Daegu, Korea.

<sup>e</sup> Researcher, Department of Dentistry, College of Medicine, Yeungnam University, Daegu, Korea.

<sup>f</sup> Professor, Department of Orthodontics, Institute of Craniofacial Deformity, College of Dentistry, Yonsei University, Korea.

Corresponding author: Chung-Ju Hwang, Professor, Department of Orthodontics, Institute of Craniofacial Deformity, College of Dentistry, Yonsei University, 50-1 Yonsei-ro, Seodaemun-gu, Seoul 03722, Korea (e-mail: hwang@yuhs.ac)

Accepted: March 2018. Submitted: November 2017.

Published Online: April 30, 2018

© 2018 by The EH Angle Education and Research Foundation, Inc.

such as breast buds in girls and testicular volume of  $>3$ – $4$  mL in boys, at an age below the age for normal puberty onset. These characteristics appear before the age of 8 years in girls and 9 years in boys.<sup>1</sup> The incidence of precocious puberty is 10- to 15-fold higher in girls than boys, and the annual incidence in girls is 15–29 per 100,000 girls over an 8-year period.<sup>2</sup>

Precocious puberty is classified as either central (gonadotropin-releasing hormone [GnRH]-dependent) or peripheral (GnRH-independent). Central precocious puberty (CPP) exists in 80% of patients with precocious puberty. CPP is idiopathic in the majority of cases, and it is caused by the early maturation of the hypothalamic–pituitary–ovarian axis.<sup>3</sup>

In girls with CPP, the acceleration of skeletal maturation along with the premature fusion and ossification of epiphyseal growth plates due to an increase in sex hormones result in an overall reduction in final adult height.<sup>4</sup> Fujita et al.<sup>5</sup> reported that craniofacial growth, including that of the nasomaxillary bone and mandible, was inhibited in new bone in mice with sex hormone disturbances due to orchietomy and

ovariectomy. Izquierdo et al.<sup>6</sup> reported that a significant increase in total synchondrosis width during cranial growth was observed in Wistar rats in pharmacologically induced precocious puberty.

To date, most previous findings were made after experimentally inducing precocious puberty in animals. Although the growth stage or period varies among children, it is necessary to identify the craniofacial characteristics and dental maturity to provide timely effective treatment to improve skeletal and dental discrepancies via orthopedic growth modification.

Therefore, the aim of this study was to identify characteristics of the craniofacial complex and dental maturity in girls with CPP that discriminate them from normal healthy girls in order to gain further insight into the influence of CPP on the craniofacial complex and dental development. The hypothesis was that the growth pattern of the craniofacial complex and dental maturity in girls with CPP differs significantly from those in normal healthy girls.

## MATERIALS AND METHODS

### Study Design/Sample

This study included 38 Korean girls who underwent treatment for CPP from March 2014 to September 2016 at the Department of Pediatrics and Adolescent Medicine at College of Medicine, Yeungnam University, Daegu, Korea. The study protocol conformed to the Declaration of Helsinki and was approved by the Institutional Review Board of Yeungnam University Hospital, Daegu, Korea.

CPP was diagnosed based on the appearance of Tanner Stage 2 or higher breast development before the age of 8 years, the presence of advanced bone age (at least a year difference between the bone age and chronological age), and findings of the GnRH stimulation tests conducted between the ages of 7.0 and 8.9 years. Luteinizing hormone-releasing hormone (100  $\mu$ g) is intravenously injected, following which the levels of luteinizing hormone and follicle stimulating hormone are continuously measured at intervals of 15–30 minutes for 90–120 minutes; CPP is diagnosed if the peak luteinizing hormone level reaches  $\geq 5$  IU/L. The exclusion criteria were as follows: peripheral precocious puberty, a type of precocious puberty caused by organic brain lesions, and chronic endocrinological disorders. Girls who showed signs of hair development due to ovarian, thyroid, and adrenal disorders and those who were overweight were also excluded.

All of the guardians of the 38 girls provided consent to perform lateral cephalometric and panoramic radiographs to analyze the craniofacial complex and dental

maturity at the same time when taking a hand–wrist radiograph to diagnose idiopathic CCP before treatment with a GnRH analog. Of these 38 girls, two were excluded because of severe facial asymmetry, two were excluded because of errors in the lateral cephalometric radiographs; thus, the final selection included 34 girls.

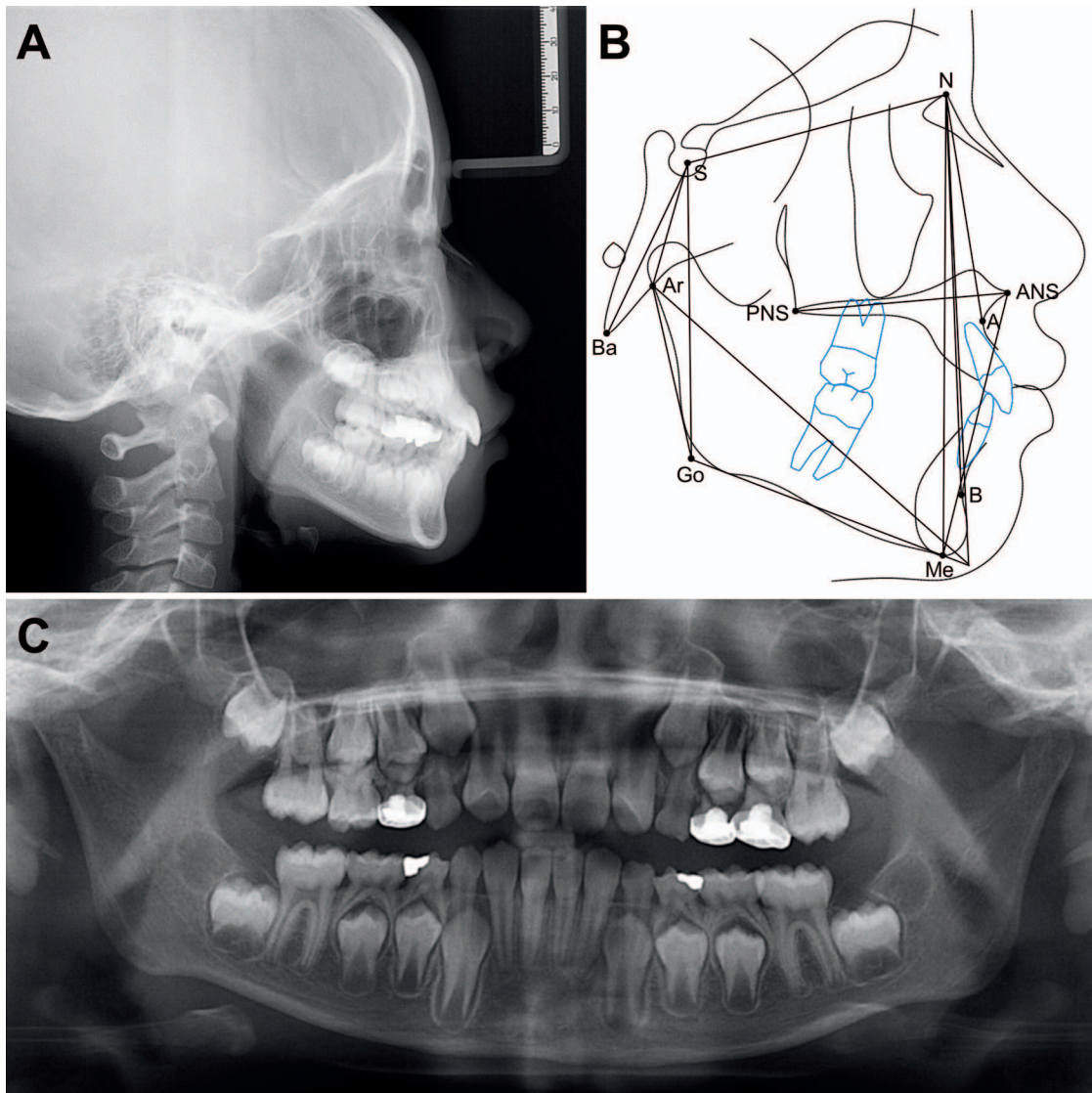
The reference group consisted of 28 healthy girls who visited the Department of Orthodontics, Yonsei Dental Hospital, Seoul, Korea, from July 2009 to May 2016. They had normal transverse and anteroposterior skeletal development (such as a menton deviation of  $\leq 4$  mm and an ANB [A point, nasion, B point] angle of  $\geq 0$  mm and  $\leq 4$  mm) and dental characteristics and were referred for treatment of simple crowding or spacing of the maxillary and mandibular anterior dentition. Written informed consent was obtained from all participants and their parents before taking lateral cephalometric, panoramic, and hand–wrist radiographs. Clinical data, such as chronological age, bone age, height, weight, and body mass index (BMI), were collected for all participants. Bone age was evaluated by an observer by using the Tanner–Whitehouse 3 (TW3) method and evaluating hand–wrist radiographs.<sup>7</sup> The TW3 method assigns a standard degree of skeletal maturity to each of the 13 bones constituting the left hand and determines bone age by converting the standards into corresponding scores.

### Radiographic Analysis

The craniofacial structure and dental maturity were measured by an orthodontist at the Department of Dentistry, Yeungnam University, Daegu, Korea, by evaluating lateral cephalometric and panoramic radiographs (Figure 1).

Lateral cephalograms were used to evaluate the craniofacial complex. The lateral cephalograms were digitized using V-ceph 5.5 (Osstem, Seoul, Korea) by an observer who was blinded to the participants' clinical status. Nine linear and seven angular cephalometric measurements were used to evaluate the characteristics of the craniofacial complex in each group, as in a previous study.<sup>8</sup>

Evaluation of dental maturity was conducted by an observer who was blinded to the participants' clinical status by using panoramic radiographs. Only the mandibular teeth were evaluated because of the ease of evaluation owing to relatively clear teeth images and minimal overlapping. The central incisors, canines, first premolars, and first molars in each panoramic radiograph were evaluated, and a higher tooth formation stage was assigned when a discrepancy between the left and right teeth was observed. The numerical tooth formation stages were classified into 13 stages



**Figure 1.** (A) Lateral cephalometric radiograph. (B) Cephalometric reference points, lengths, and angles. N indicates nasion; S, sella; Ar, articulare; Ba, basion; ANS, anterior nasal spine; PNS, posterior nasal spine; A, point A; B, point B; Go, gonion; Me, menton; N–S, anterior cranial base length; S–Ba, posterior cranial base length; ANS–PNS, maxillary length; Ar–Go, mandibular ramus height; Go–Me, mandibular corpus length; Ar–Me, total mandibular length; ANS–Me, lower anterior facial height; N–Me, anterior facial height; S–Go, posterior facial height; N–S–Ar, cranial base angle; SN–ArGo, ramal angle; Ar–Go–Me, gonial angle; SN–GoMe, mandibular plane angle; SNA, maxilla-cranial base relation; SNB, mandible-cranial base relation; ANB, maxilla-mandible relation. (C) Panoramic radiograph.

(permanent uniradicular teeth) or 14 stages (permanent multiradicular teeth) according to the Moorrees' classification<sup>9,10</sup> (Figure 2).

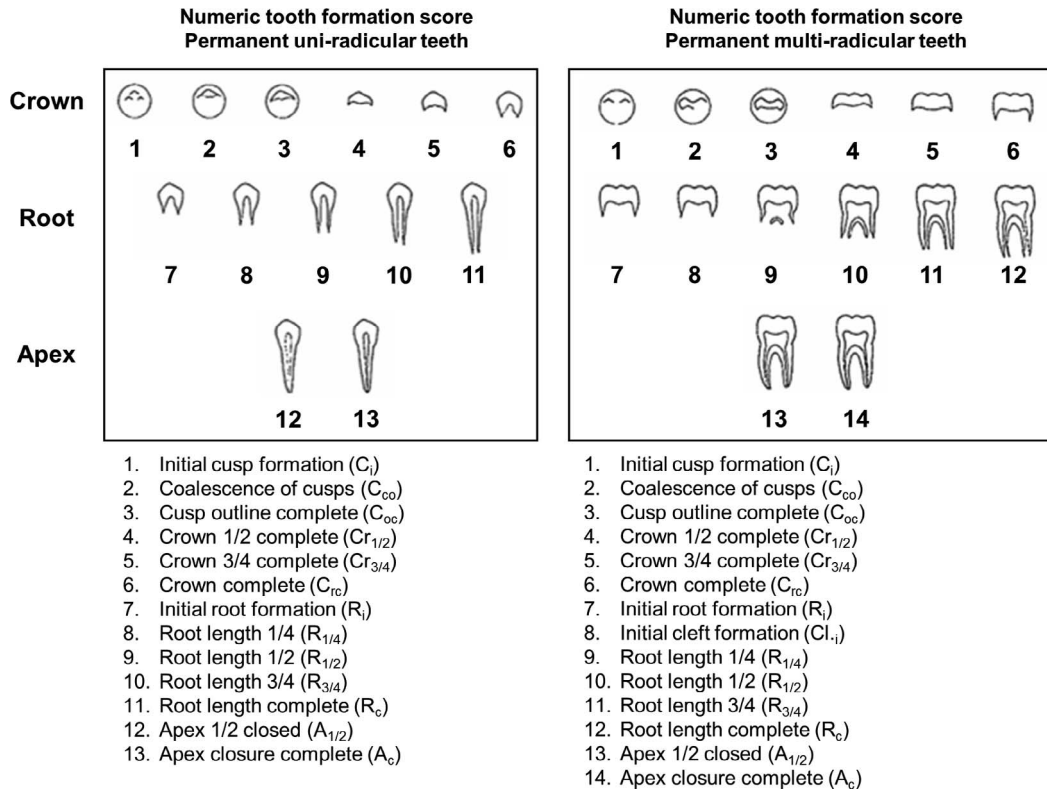
### Reproducibility

Reproducibility was determined by comparing measurements obtained during the original examinations with those obtained during repeated examinations. All measurements were repeated by the same observer after 2 weeks. The intraclass correlation coefficient (ICC) was used to calculate the method error, which

was  $>.90$  for all linear and angular cephalometric measurements and tooth formation stages.

### Statistical Analysis

All statistical analyses were performed using IBM SPSS software, version 23.0 (IBM Korea Inc., Seoul, Korea) for Windows. Based on the preliminary study, a minimum sample size of 52 was required (G\*Power 3, Dusseldorf, Germany), with a  $P$  value  $< .05$  indicating statistical significance, a power of 80%, and an effect size of .8 for detecting differences in skeletal and dental measurements between two groups. To verify



**Figure 2.** Tooth formation stages for assessing the maturity of permanent uniradicular and multiradicular mandibular teeth.

the normality of data distribution, the Shapiro–Wilk test was used. The Mann-Whitney *U*-test was used to analyze the differences in the participants’ chronological age, bone age, height, and weight between the two groups. The differences in the cephalometric measurements between the two groups were analyzed by performing an independent *t* test. The distributions of tooth formation stages according to the mandibular teeth and groups were analyzed using the  $\chi^2$  test.

The correlations between group (the CPP and reference groups), age, bone age, skeletal, and dental variables were evaluated using Spearman’s rank correlation coefficient. A *P* value of  $<.05$  was considered significant.

**RESULTS**

Thirty-four girls with CPP (mean age,  $8.6 \pm .5$  years) met the inclusion criteria (Table 1). The peak luteinizing hormone and follicle-stimulating hormone levels in these girls were 17.4 IU/L (95% confidence interval, 11.8–23.1 IU/L) and 11.3 IU/L (95% confidence interval, 9.3–13.3 IU/L), respectively. There were no significant differences in chronological age between the CPP and reference groups (28 girls; mean age,  $8.6 \pm .8$  years). Bone age was significantly higher in the CPP ( $1.6 \pm 1.2$ ) than in the reference group ( $8.4 \pm 1.3$  years) by 2.2 years ( $P < .001$ ). Body height, weight,

and BMI were also higher in the CPP group than in the reference group.

The mandibular ramus height ( $44.4 \pm 4.1$  mm) and total mandibular length ( $10.8 \pm 4.3$  mm) ( $P = .004$  and  $.021$ , respectively) were greater and the lower anterior facial height ( $63.2 \pm 2.4$  mm) ( $P = .040$ ) was lesser in the CPP group than in the reference group (Table 2). In addition, the gonial angle ( $12.9 \pm 6.1^\circ$ ) and mandibular plane angle ( $34.9 \pm 4.8^\circ$ ) ( $P = .045$  and  $.012$ , respectively) were lesser and the mandible-cranial base relation ( $77.3 \pm 3.1^\circ$ ) was greater in the CPP group than in the reference group ( $P = .046$ ).

The mandibular teeth were more mature in the CPP group than in the reference group, regardless of tooth type ( $P < .001$ ) (Table 3). All the mandibular central incisors of the girls with CPP reached the 12th tooth formation stage (apex closed), but only one such instance (3.6%) was noted in the reference group ( $P < .001$ ). In the CPP group, the canine tooth formation stage reached the 11th stage (root length complete) in 22 (64.7%) girls; however, this stage was attained in only 3 (1.7%) in the reference group ( $P < .001$ ). The first molar tooth formation reached the 11th stage in 32 (94.1%) girls with CPP and only five (17.9%) girls in the reference group ( $P < .001$ ).

The lower and total anterior facial height of the girls, regardless of the presence or absence of CPP, was weakly proportional to that of girls of the same

**Table 1.** Subject Characteristics

	CPP (n = 34) <sup>a</sup>	Reference (n = 28)	P Value
Chronological age (year)	8.6 ± .5	8.6 ± .8	.729
Bone age (year)	1.6 ± 1.2	8.4 ± 1.3	< .001
Body height (cm)	134.4 ± 5.8	127.8 ± 4.2	< .001
Body weight (kg)	31.7 ± 5.4	27.1 ± 2.5	< .001
BMI (kg/m <sup>2</sup> )	2.0 ± .2	17.5 ± 2.1	.003

P values were calculated by the Mann-Whitney U-test.

<sup>a</sup> CPP indicates central precocious puberty.

chronological age ( $r$ , .299 to .377) (Table 4). The total length of the mandible increased with increasing bone age ( $r$ , .273 to .279;  $P < .05$ ). The increase in the mandibular ramus height and posterior facial height were greater in the CPP group than in the reference group ( $r$ , .251 to .333). The decrease in the gonial angle and mandibular plane angle was greater in the CPP group than in the reference group ( $r$ , -.317 to -.277;  $P < .05$ ). A strong positive correlation was observed between the tooth formation stages of the mandibular teeth and the presence of CPP in girls ( $r$ , .756 to .957;  $P < .001$ ) and increasing bone age ( $r$ , .562 to .658;  $P < .001$ ).

## DISCUSSION

The hypothesis of the study was that there is a significant difference in the growth pattern of the craniofacial complex and dental maturity between girls with and without CPP. Importantly, this study revealed that girls with CPP had a longer mandibular ramus height and mandibular length by about 2–3 mm, and the mandibular plane angle was rotated counterclockwise as compared to healthy girls of the same chronological age. Moreover, all the mandibular teeth

of the girls with CPP were significantly more mature than those of normal girls. These data provide important insights into the effects of CPP on the growth and development of the craniofacial complex, including tooth development, in girls.

In this study, body weight was significantly higher (approximately 4–5 kg) in the CPP group than in the reference group at the same chronological age. The BMI was also significantly higher in the CPP group than in the reference group, indicating that girls with CPP have an above-average obesity index with respect to their chronological age before GnRH agonist treatment. The body height and bone age were significantly higher by 6–7 cm and by 2 years, respectively, in the CPP group than in the reference group at the same chronological age. Girls with CPP had premature growth spurts associated with advanced skeletal maturity of more than 2 years and epiphyseal ossification, resulting in a short adult height.<sup>11</sup>

Previous studies reported that lack of sex hormone production led to greater disturbances in both femoral and mandibular growth immediately after birth in mice.<sup>5</sup> In this study, the mandibular ramus height

**Table 2.** Mean and Standard Deviation of Cephalometric Measurements Compared Between the Two Groups

Variables	CPP <sup>a</sup>	Reference	P Value
Linear measurements (mm)			
Anterior cranial base length (N–S)	66.0 ± 2.7	66.3 ± 3.2	.664
Posterior cranial base length (S–Ba)	32.2 ± 3.3	32.5 ± 3.2	.763
Maxillary length (ANS–PNS)	48.0 ± 3.0	48.4 ± 2.4	.569
Mandibular ramus height (Ar–Go)	44.4 ± 4.1	41.3 ± 3.8	.004
Mandibular corpus length (Go–Me)	7.8 ± 4.0	69.0 ± 4.0	.093
Total mandibular length (Ar–Me)	10.8 ± 4.3	98.2 ± 4.2	.021
Lower anterior facial height (ANS–Me)	63.2 ± 2.4	65.4 ± 5.5	.040
Anterior facial height (N–Me)	114.5 ± 3.5	115.7 ± 7.3	.408
Posterior facial height (S–Go)	73.7 ± 5.1	71.2 ± 4.6	.051
Angular measurements (°)			
Cranial base angle (N–S–Ar)	126.1 ± 6.0	124.8 ± 4.2	.335
Ramal angle (SN–ArGo)	94.1 ± 3.9	94.4 ± 4.5	.735
Gonial angle (Ar–Go–Me)	12.9 ± 6.1	123.9 ± 5.5	.045
Mandibular plane angle (SN–GoMe)	34.9 ± 4.8	38.3 ± 5.6	.012
Maxilla–cranial base relation (SNA)	79.6 ± 3.2	78.3 ± 2.8	.110
Mandible–cranial base relation (SNB)	77.3 ± 3.1	75.8 ± 2.7	.046
Maxilla–mandible relation (ANB)	2.3 ± 1.0	2.6 ± 1.3	.374

P values were calculated by the independent *t* test.

<sup>a</sup> CPP indicates central precocious puberty.

**Table 3.** Distribution of Tooth Formation Stages Among the Participants According to the Mandibular Teeth and Groups

TFS	Central Incisors			Canines			First Premolars			First Molars		
	CPP	Reference	<i>P</i> Value	CPP	Reference	<i>P</i> Value*	CPP	Reference	<i>P</i> Value	CPP	Reference	<i>P</i> Value
5			< .001			< .001			< .001			< .001
6												
7								2 (7.1%)				
8					4 (14.3%)			11 (39.3%)				
9					8 (28.6%)		4 (11.8%)	11 (39.3%)			9 (32.1%)	
10		2 (7.1%)		3 (8.8%)	13 (46.4%)		17 (5.0%)	4 (14.3%)		2 (5.9%)	14 (5.0%)	
11		25 (89.3%)		22 (64.7%)	3 (1.7%)		11 (32.4%)			32 (94.1%)	5 (17.9%)	
12	34 (10.0%)	1 (3.6%)		9 (26.5%)			2 (5.9%)					

\* *P* values were calculated by the chi-square test.

<sup>a</sup> TFS indicates tooth formation stage; CPP, central precocious puberty.

and total mandibular length of girls with CPP were higher than those in the reference group. Although there was no significant difference in the maxilla-mandible relation between the groups, the mandible-cranial base relation (SNB) was greater in the CPP group than in the reference group. Additionally, the mandibular gonial angle and mandibular plane angle were lesser in the CPP group than in the reference group, indicating the counterclockwise, anterior rotation of the mandible in girls with CPP. These results indicated that the interstitial cartilage growth of the mandibular condyles due to growth hormones stimulated by sex hormones had a greater influence in girls with CPP. The principal mechanism of mandibular growth is endochondral bone formation; therefore, it is

assumed that the mandibular condyle is affected more than the maxillary and mandibular corpus because condylar height is mainly controlled by endochondral bone formation.<sup>12</sup> The increase in the total length of mandible observed in this study was not related to an increase in the mandibular corpus but was related to an increase in the ramal height associated with condylar growth in other groups. Moreover, the mandibular growth direction, ie, counterclockwise, and the anterior rotation of the mandible resulted in a reduction of the lower anterior facial height in the CPP group.

The evaluation of the maturity of the maxillary teeth according to the superposition of root and anatomical structure in panoramic radiographs has some limita-

**Table 4.** Correlation Coefficient Between Group, Age, Bone Age, and Skeletal and Dental Variables

Variables	Group		Age		Bone Age	
	<i>r</i>	<i>P</i> Value*	<i>r</i>	<i>P</i> Value**	<i>r</i>	<i>P</i> Value***
Linear measurements (mm)						
Anterior cranial base length (N-S)	-.092	.475	.135	.296	-.039	.762
Posterior cranial base length (S-Ba)	-.052	.690	.401**	.001	.053	.684
Maxillary length (ANS-PNS)	-.080	.538	.047	.718	-.012	.927
Mandibular ramus height (Ar-Go)	.333**	.008	.079	.540	.222	.083
Mandibular corpus length (Go-Gn)	.244	.055	.203	.114	.212	.097
Total mandibular length (Ar-Gn)	.273*	.031	.149	.248	.279*	.028
Lower anterior facial height (ANS-Me)	-.198	.122	.299*	.018	-.041	.753
Total anterior facial height (N-Me)	-.071	.585	.377**	.003	.015	.906
Posterior facial height (S-Go)	.251*	.049	.316*	.012	.247	.053
Angular measurements (°)						
Cranial base angle (N-S-Ar)	.078	.547	-.016	.899	.091	.484
Ramal angle (SN-ArGo)	-.109	.401	.016	.904	-.193	.132
Gonial angle (Ar-Go-Me)	-.277*	.029	-.081	.530	-.121	.351
Mandibular plane angle (SN-GoMe)	-.317*	.012	-.015	.910	-.197	.124
Maxilla-cranial base relation (SNA)	.209	.103	.009	.945	.212	.097
Mandible-cranial base relation (SNB)	.272*	.033	-.046	.721	.216	.092
Maxilla-mandible relation (ANB)	-.155	.229	.073	.572	.021	.869
Tooth formation stages of the mandibular teeth						
Central incisors	.957***	< .001	.031	.808	.658***	< .001
Canines	.786***	< .001	.340**	.007	.617***	< .001
First premolars	.756***	< .001	.439***	< .001	.562***	< .001
First molars	.769***	< .001	.236	.065	.594***	< .001

Group (Reference, 1; CPP, central precocious puberty, 2).

\* *P* < .05, \*\* *P* < .01, \*\*\* *P* < .001.

tions. Therefore, only the mandibular teeth were analyzed as in a previous study.<sup>13</sup> When the mandibular tooth formation stages were compared between the two groups, it was found that mandibular central incisors and first molars progressed toward the 11th to 12th stages, at which point dental development is almost complete, in more girls in the CPP group. All the central incisors in the CPP group reached the 12th stage, and the first molars reached the 11th stage in 94.1% of girls in the CPP group. Previous studies have reported an association between dental maturity and chronological and bone age.<sup>14,15</sup> The findings of this study showed that a higher tooth formation stage, regardless of the tooth type, was strongly associated with higher chronological and bone age.

In this study, the vertical growth of the craniofacial complex, such as lower and total anterior facial heights, was proportional to chronological age, but anteroposterior mandibular growth, ie, total mandibular length and dental maturity of all mandibular teeth, was positively related to the presence or absence of CPP and bone age. These results indicate that the relative increase in bone age due to CPP results in an increase in the anteroposterior length of the mandible and induces early maturation of the mandibular tooth. Therefore, the evaluation of total mandibular length and dental maturity of the mandibular teeth might be helpful to determine whether to perform the GnRH stimulation test.

This study had several limitations with regard to data interpretation. First, this study included a limited number of subjects, but the number of samples in each group was sufficient to show differences in skeletal measurements between the two groups. Second, mean age of the girls included in this study was about 8.6 years old and it was not enough to show maturity of normal girls to allow comparison with the CPP group that matures early. However, since most CPPs are diagnosed at the age of 8 years, it is not ethical to evaluate their craniofacial growth patterns by observing CPP without treatment until after 15–16 years of age when female growth stops. Third, tooth formation stage might also be affected by other genetic, ethnic, nutritional, and environmental factors, which were not analyzed in this study.<sup>16</sup> Finally, a longitudinal study may be justified to better understand how endocrine therapy effects craniofacial growth in girls with CPP because the craniofacial pattern in these patients can change. Further longitudinal studies involving large numbers of subjects and evaluating skeletal maturation through cervical skeletal maturity indicators without additional radiation exposure through hand–wrist radiographs are required to evaluate changes in the growth patterns of

the craniofacial complex and dental maturity in individuals with CPP and before and after treatment with a GnRH analog.

## CONCLUSIONS

- CPP had an effect on anteroposterior growth of the mandible in the craniofacial complex and rotation of the mandibular plane angle.
- Early maturation of the mandibular teeth was observed in girls with CPP. These data provide important insights into the effects of CPP on the growth and development of the craniofacial complex in girls.
- The evaluation of the dental maturity of the mandibular teeth might be helpful to determine whether to perform the GnRH stimulation test.

## ACKNOWLEDGMENT

This research was supported by Basic Science Research Program through the National Research Foundation of Korea (NRF) funded by the Ministry of Education (NRF-2017R1D1A1B03035930).

## REFERENCES

1. Berberoglu M. Precocious puberty and normal variant puberty: definition, etiology, diagnosis and current management. *J Clin Res Pediatr Endocrinol.* 2009;1:164–174.
2. Fuqua JS. Treatment and outcomes of precocious puberty: an update. *J Clin Endocrinol Metab.* 2013;98:2198–2207.
3. Giabicani E, Lemaire P, Brauner R. Models for predicting the adult height and age at first menstruation of girls with idiopathic central precocious puberty. *PLoS One.* 2015;10:e0120588.
4. Phillip M, Lazar L. Precocious puberty: growth and genetics. *Horm Res.* 2005;64 Suppl 2:56–61.
5. Fujita T, Ohtani J, Shigekawa M, et al. Effects of sex hormone disturbances on craniofacial growth in newborn mice. *J Dent Res.* 2004;83:250–254.
6. Izquierdo AD, Mishima FD, Carrard VC, Farina M, Nojima MDG. Effects of induced precocious puberty on cranial growth in female Wistar rats. *Eur J Orthod.* 2012;34:133–140.
7. Tanner JM. *Assessment of Skeletal Maturity and Prediction of Adult Height (TW3 Method).* 3rd ed. London: W.B Saunders; 2001.
8. Choi SH, Fan D, Hwang MS, Lee HK, Hwang CJ. Effect of growth hormone treatment on craniofacial growth in children: idiopathic short stature versus growth hormone deficiency. *J Formos Med Assoc.* 2017;116:313–321.
9. Moorrees CF, Fanning EA, Hunt EE Jr. Formation and resorption of three deciduous teeth in children. *Am J Phys Anthropol.* 1963;21:205–213.
10. Moorrees CF, Fanning EA, Hunt EE Jr. Age variation of formation stages for ten permanent teeth. *J Dent Res.* 1963;42:1490–1502.
11. Giabicani E, Lemaire P, Brauner R. Models for predicting the adult height and age at first menstruation of girls with idiopathic central precocious puberty. *PLoS One.* 2015;1.
12. Hernandez RAM, Ohtani J, Fujita T, et al. Sex hormones receptors play a crucial role in the control of femoral and

- mandibular growth in newborn mice. *Eur J Orthod.* 2011;33:564–569.
13. Kumar S, Singla A, Sharma R, Viridi MS, Anupam A, Mittal B. Skeletal maturation evaluation using mandibular second molar calcification stages. *Angle Orthod.* 2012;82:501–506.
  14. Cho SM, Hwang CJ. Skeletal maturation evaluation using mandibular third molar development in adolescents. *Korean J Orthod.* 2009;39:120–129.
  15. Baik JS, Choi JW, Kim SJ, Kim JH, Kim S, Kim JH. Predictive value of dental maturity for a positive gonadotropin-releasing hormone stimulation test result in girls with precocious puberty. *J Korean Med Sci.* 2017;32:296–302.
  16. Karkhanis S, Mack P, Franklin D. Dental age estimation standards for a Western Australian population. *Forensic Sci Int.* 2015;257:509 e501–509.