


Catatonic syndrome as the presentation of encephalitis in association with COVID-19

Damaris Vazquez-Guevara,¹ Sandra Badial-Ochoa,¹ Karen M Caceres-Rajo,² Idefonso Rodriguez-Leyva ^{1,3}

¹Neurology, Hospital Central Dr Ignacio Morones Prieto, San Luis Potosi, Mexico

²Internal Medicine, Facultad de Medicina, Universidad Autonoma de San Luis Potosi, San Luis Potosi, Mexico

³Facultad de Medicina, Universidad Autonoma de San Luis Potosi, San Luis Potosi, Mexico

Correspondence to

Dr Idefonso Rodriguez-Leyva; ilrole@yahoo.com.mx

Accepted 29 April 2021

SUMMARY

COVID-19 has shown different neurological manifestations even sometimes there are the initial or the main presentation.

The following case report is about a middle-aged woman who, over 3 days, developed fever, clinical neurological alterations (stupor, muteness, fixed gaze and catatonia), cerebrospinal fluid (16 lymphocytes) and an electroencephalogram (EEG) (4–6 Hz generalised activity) with characteristics of encephalitis. A serum IgG, IgM, nasopharyngeal swab PCR for SARS-CoV-2. The patient responded positively to support measures, symptomatic and corticosteroid treatment. At discharge, the patient was independent and improved considerably.

We report the presence of catatonia as a possible and atypical manifestation of encephalitis in association with COVID-19.

BACKGROUND

Much of the focus regarding the COVID-19 pandemic was initially centred on cardiovascular, pulmonary and haematologic complications. However, the prevalence of neurological symptoms in these patients has become more evident.¹ One of these conditions is catatonia, described in 1874 by Karl Kahlbaum as a very diverse psychomotor syndrome with a clinical picture ranging from mutism, catalepsy agitation to echolalia, echopraxia and stereotypes.² The most common aetiology of catatonia is a psychiatric illness, and there were reports of other general medical conditions. The frequency of catatonia due to general medical conditions represents 20%–39% of aetiology in catatonia syndrome.³ The most common neurological aetiologies were metabolic encephalopathy, autoimmune, paraneoplastic and infectious encephalitis.⁴

The mechanism used by a virus to cause neurological damage is an immune dysregulation associated with a failure in motor connectivity; this suggests dysfunction of the movement circuit (thalamus, cerebellum, pontine nuclei, the corticocortical pathways, the supplementary motor area, among others), with a cytokine-related injury, damage to specific receptors, inflammation and secondary hypoxia along nerve fibres.⁵

CASE PRESENTATION

A 43-year-old woman was brought to the emergency department suffering from stupor, silence and staring. Three days prior, her husband

noticed that the patient had apathy, slow thinking and decreased mobility. On presentation to the emergency department, her heart rate was 110 beats per minute. Neurological examination revealed stupor, muteness, fixed gaze, negativism, stiffness in the left hemibody, gegenhalten sign on the right side of the body, global hyperreflexia and no neck stiffness. The Bush-Francis Catatonia rating scale was 19 points. The approach was based on catatonic syndrome (video 1). Initially, a CT scan of the head was requested without alterations. An electroencephalogram (EEG) showed generalised slow activity (figure 1). Even during the EEG, the patient had motor stereotypes that did not correlate with brain activity. Initial blood test reported a white cell count of 9.5×10^9 (reference range 4–11), C reactive protein of 5.7 mg/L. Serum electrolytes, creatine phosphokinase, the liver and renal functions were normal, and thiamine levels were unremarkable. Lumbar puncture revealed an opening pressure of 17 cm H₂O. The white blood cell count in the cerebrospinal fluid (CSF) was 16 mm³ (100% lymphocytes). Treatment with acyclovir for the probable viral encephalitis and a diazepam infusion for the catatonic syndrome was started.

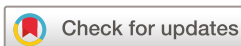On day 2 of admission, she had a cough, a fever of 102.92°F (39.4°C), and 88% oxygen saturation on pulse oximetry. On examination, chest auscultation was normal. CT of the chest showed basal bilateral pulmonary infiltrate. A serum IgG, IgM and a nasopharyngeal swab PCR test for the SARS-CoV-2 was performed.

CSF cytology was normal. The direct Gram stain of the CSF and CSF culture was negative, and PCR was negative for herpes virus (HSV) type 1 and 2. MRI of the brain showed no abnormalities.

The approach was then focused on autoimmune aetiology, and she was treated empirically with a bolus of methylprednisolone 1 g per day for 5 days.

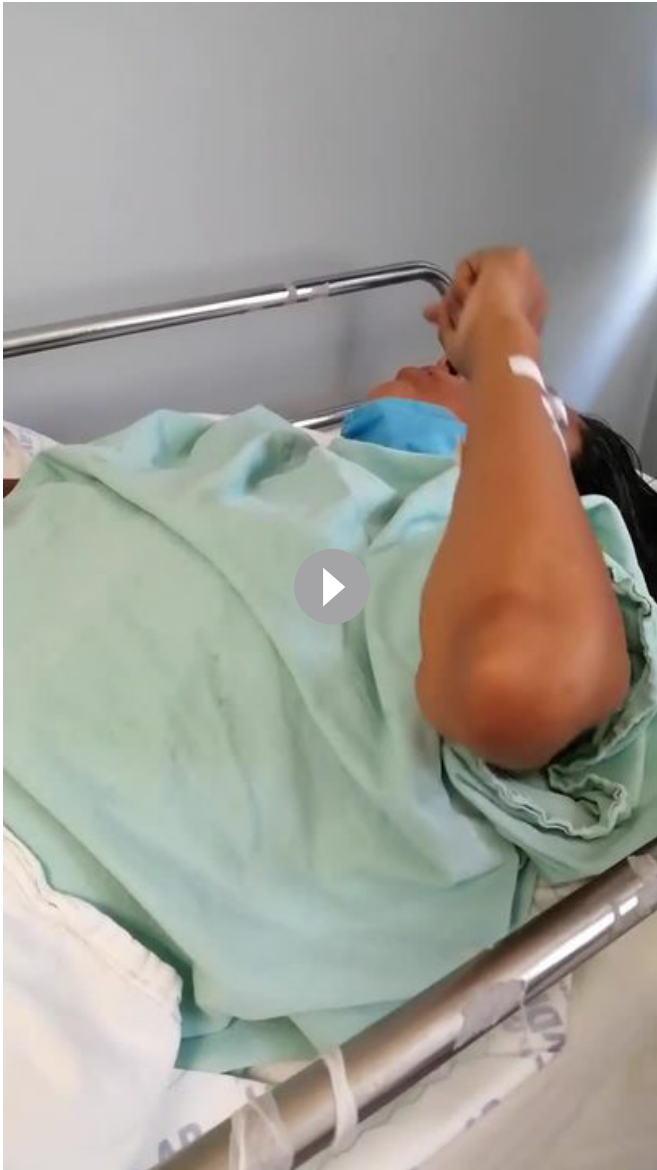On day 3 of admission, she presented with orofacial dyskinesias, upper limb stereotypes and waxy postures. A thyroid nodule was detected with standard thyroid tests, antiperoxidase antibodies, and antithyroglobulin antibodies were negative. The histological report of the thyroid nodule was lymphoid hyperplasia.

Serum IgG and IgM and PCR were positive for SARS-CoV-2; the patient presented mild typical respiratory symptoms. The catatonic



© BMJ Publishing Group Limited 2021. No commercial re-use. See rights and permissions. Published by BMJ.

To cite: Vazquez-Guevara D, Badial-Ochoa S, Caceres-Rajo KM, et al. *BMJ Case Rep* 2021;**14**:e240550. doi:10.1136/bcr-2020-240550



Uncited Video 1 In this short movie, it is possible to observe the catatonic activity in the patient

syndrome was related to encephalitis in association with COVID-19.

DIFFERENTIAL DIAGNOSIS

Initially, our differential diagnosis included psychiatric catatonic syndrome (schizophrenia or bipolar syndrome) or organic brain disorders causes.⁶ The approach of the catatonic syndrome was for organic brain disorders.

On the day of admission, a CT of the head was performed to search for lesions such as brain haemorrhages and bi-frontal masses; however, it was unremarkable. Status epilepticus was suspected, so a trial with benzodiazepines was initially performed without clinical improvement. An EEG was conducted during which stereotypes were presented, which did not correlate with the brain activity generalised dysfunction.⁷

The differential diagnosis was then focused on the cause of encephalitis.⁸ An autoimmune aetiology was suspected. The pertinent screening was carried out where one thyroid

nodule was identified, and a biopsy was performed, which led to a high suspicion of Hashimoto's encephalitis.⁹ However, there was normal thyroid function, a pathology report of the thyroid nodule showed lymphoid hyperplasia, and negative antiperoxidase and antithyroglobulin antibodies were found.

The patient presented mild respiratory symptoms, and CT showed basal bilateral pulmonary infiltrate. Serum IgG, IgM and PCR were positive for SARS-CoV-2. CSF was not tested for SARS-CoV-2 because many reports did it and concluded the lack of PCR to detect SARS-CoV-2 on CSF.¹⁰ We could not rule out other possibilities due to the family's economic limitations and our institution, such as other autoimmune limbic encephalitides (Anti-NMDA (N-methyl-D-aspartate) receptor, anti-LGI1 (Leucine-rich glioma-inactivated 1) and Anti-CASPR2 (Contactin Associated Protein 2)).¹¹ The encephalitis was classified as possibly viral and associated with a pulmonary process caused by COVID-19 and a rare manifestation of a catatonic syndrome.

TREATMENT

The initial treatment was for the catatonic syndrome with low doses of infusion diazepam with no good response. Initially, with probable viral encephalitis, the patient was under treatment with acyclovir only 2 days; it was discontinued after negative CSF PCR for HSV. The respiratory symptoms were treated with supplemental oxygen therapy.

Apart from acyclovir, no specific treatment was given for encephalitis due to a lack of diagnostic certainty. The patient was treated with an intravenous bolus of methylprednisolone for 5 days, and then she received oral prednisone.

OUTCOME AND FOLLOW-UP

There was a remarkable improvement when finished with the boluses of steroids. The patient awoke with significant cognitive decline characterised by the disorientation of time and a deficit of the working, short and semantic memory with 17 on the Montreal Cognitive Assessment in Spanish (MoCA-S) test. She also presented rest tremor on the right hand and hypokinesia, with hypokinesia on the left hemi-body and rest tremor on the right hand.

At discharge from the hospital, the patient could walk and perform daily living activities such as bathing, eating and dressing.

DISCUSSION

The COVID-19 pandemic infection is caused by the SARS-CoV-2. The primary manifestation is a respiratory syndrome, where the symptoms are fever, dry cough, fatigue, dyspnoea, chest pain, fatigue and myalgia.¹⁰ There are many neurological manifestations in the central nervous system and peripheral nervous system; these manifestations are considered direct effects of the nervous system's virus, para-infectious or post-infectious immune-mediated disease.¹² The neurological manifestations in the current COVID-19 pandemic are olfactory and taste disorders, dizziness, altered mental status, seizure, acute cerebrovascular disease, neuralgia, ataxia, Guillain-Barre syndrome and encephalitis.¹³ There are few case reports about encephalitis, where the main neurological clinical presentation was generalised seizures, altered mental state as confusion and meningism.⁸ The definitive diagnosis of encephalitis by SARS-COV-2 is difficult because the virus dissemination is transient, and its CSF titre may be extremely low.¹⁴ There is no specific treatment. Catatonia is reported

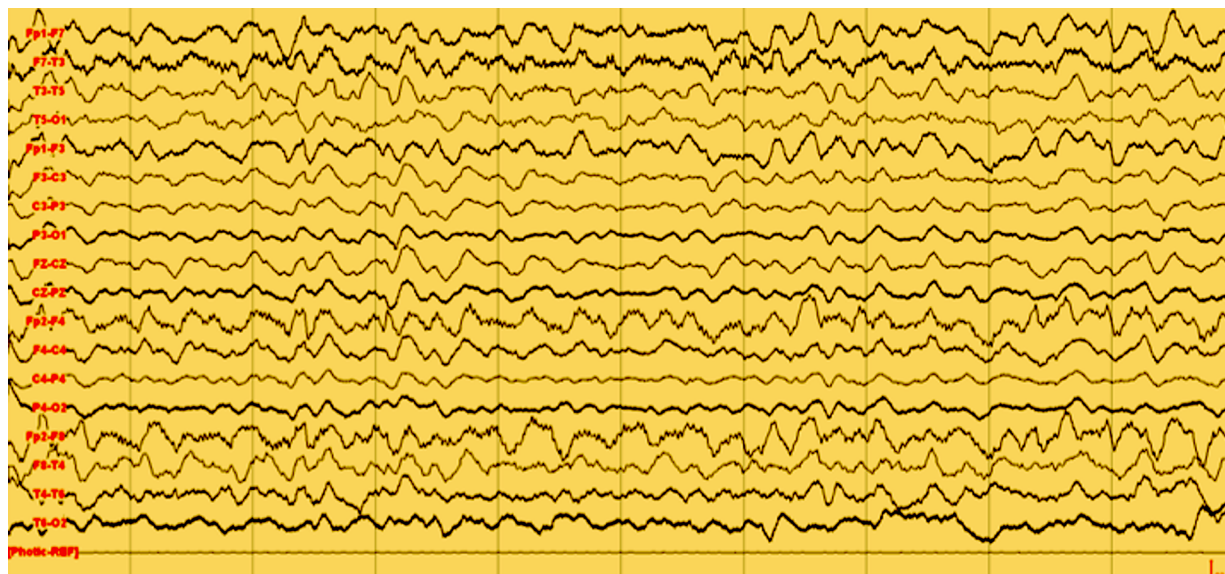


Figure 1 Electroencephalogram was showing slow generalised theta activity of 4–6 Hz.

as a clinical manifestation in infectious encephalitis, and its prevalence is unknown. The appropriate diagnostic workup of catatonia should be done. A recent case report described a man without a history of any neuropsychiatric condition, which initially developed respiratory symptoms due to COVID-19 then presented catatonia, also considered associated with drugs (azithromycin, methocarbamol).¹⁵ There are two other case reports of catatonia associated with COVID-19, one in a 61-year-old man with a history of schizophrenia¹⁶ and the other in an older man with diabetes, hypertension, atrial fibrillation who also developed catatonia associated with SARS-CoV-19 infection.¹⁷

Among the possibilities of neuropsychiatric presentations of coronavirus-associated infections, a systematic review and meta-analysis included catatonia as a possibility,¹⁸ associating the coronavirus pandemic in its acute phase of the disease to depression and anxiety in the majority of cases and in a minority of patients to psychosis and catatonia.¹⁹

This case report shows a patient with catatonic syndrome as the presentation of encephalitis in association with COVID-19. The catatonic syndrome could be considered an initial manifestation of encephalitis.

Acknowledgements IR-L is the corresponding author. He has the right to grant and grants on behalf of all authors. He gives an exclusive license to BMJ Publishing Group Ltd ('BMJ') and its licensors to allow this work, if accepted, to be published in BMJ Case Reports and any other BMJ product and to exploit all rights, as set out in our license.

Contributors DV-G and SB-O participated in the planning, writing and editing of the report. IR-L was the corresponding author. IR-L edited the report, figures and videos. KMC-R participated in the writing of the report.

Funding The authors have not declared a specific grant for this research from any funding agency in the public, commercial or not-for-profit sectors.

Competing interests None declared.

Patient consent for publication Parental/guardian consent obtained.

Provenance and peer review Not commissioned; externally peer reviewed.

This article is made freely available for use in accordance with BMJ's website terms and conditions for the duration of the covid-19 pandemic or until otherwise determined by BMJ. You may use, download and print the article for any lawful, non-commercial purpose (including text and data mining) provided that all copyright notices and trade marks are retained.

Patient's perspective

The patient and her family were delighted about the evolution and outcome of the problem.

Learning points

- ▶ Neurological manifestation could be the initial manifestation of COVID-19.
- ▶ It is always important to rule out typical infectious, autoimmune and paraneoplastic causes of encephalitis.
- ▶ Catatonia syndrome can be a manifestation of encephalitis in association with SARS-CoV2 infection.
- ▶ Encephalitis can give generalised dysfunction in the electroencephalogram without significant abnormalities on MRI of the brain.
- ▶ If faced with a patient with catatonia in association with COVID-19 infection, the appropriate complementary tests should be carried out to make the differential diagnosis and subsequently establish an association.

ORCID iD

Idefonso Rodriguez-Leyva <http://orcid.org/0000-0002-3316-1471>

REFERENCES

- 1 Ellul MA, Benjamin L, Singh B, *et al*. Neurological associations of COVID-19. *Lancet Neurol* 2020;19:767–83.
- 2 Rogers JP, Pollak TA, Blackman G, *et al*. Catatonia and the immune system: a review. *Lancet Psychiatry* 2019;6:620–30.
- 3 Wijemanne S, Jankovic J. Movement disorders in catatonia. *J Neurol Neurosurg Psychiatry* 2015;86:825–32.
- 4 Smith JH, Smith VD, Philbrick KL, *et al*. Catatonic disorder due to a general medical or psychiatric condition. *J Neuropsychiatry Clin Neurosci* 2012;24:198–207.
- 5 Yachou Y, El Idrissi A, Belapasov V, *et al*. Neuroinvasion, neurotropic, and neuroinflammatory events of SARS-CoV-2: understanding the neurological manifestations in COVID-19 patients. *Neurol Sci* 2020;41:2657–69.
- 6 Walther S, Strik W. Catatonia. *CNS Spectr* 2016;21:341–8.
- 7 Walther S, Stegmayer K, Wilson JE, *et al*. Structure and neural mechanisms of catatonia. *Lancet Psychiatry* 2019;6:610–9.
- 8 Rabinstein AA. Herpes virus encephalitis in adults: current knowledge and old myths. *Neurol Clin* 2017;35:695–705.

- 9 Erdoğan S, Kalin S, Department of Radiology, Health Sciences University Umraniye Training and Research Hospital Istanbul, Turkey. Hashimoto encephalopathy. *Turk J Anaesth Reanim* 2018;46:402–5.
- 10 Destras G, Bal A, Escuret V, et al. Systematic SARS-CoV-2 screening in cerebrospinal fluid during the COVID-19 pandemic. *Lancet Microbe* 2020;1:e149.
- 11 Gadoth A, Pittock SJ, Dubey D, et al. Expanded phenotypes and outcomes among 256 LGI1/CASPR2-IgG-positive patients. *Ann Neurol* 2017;82:79–92.
- 12 Harapan H, Itoh N, Yufika A, et al. Coronavirus disease 2019 (COVID-19): a literature review. *J Infect Public Health* 2020;13:667–73.
- 13 Tsai S-T, Lu M-K, San S, et al. The neurologic manifestations of coronavirus disease 2019 pandemic: a systemic review. *Front Neurol* 2020;11:1–7.
- 14 Ye M, Ren Y, Lv T. Encephalitis as a clinical manifestation of COVID-19. *Brain Behav Immun* 2020;88:945–6.
- 15 Caan MP, Lim CT, Howard M. A case of catatonia in a man with COVID-19. *Psychosomatics* 2020;61:556–60.
- 16 Rogers JP, Chesney E, Oliver D, et al. Psychiatric and neuropsychiatric presentations associated with severe coronavirus infections: a systematic review and meta-analysis with comparison to the COVID-19 pandemic. *Lancet Psychiatry* 2020;7:611–27.
- 17 Butler M, Pollak TA, Rooney AG, et al. Neuropsychiatric complications of covid-19. *BMJ* 2020;371:m3871.
- 18 Zandifar A, Badrfam R. Exacerbation of psychosis accompanied by seizure and catatonia in a patient with COVID-19: a case report. *Psychiatry Clin Neurosci* 2021;75:63–4.
- 19 Gouse BM, Spears WE, Nieves Archibald A, et al. Catatonia in a hospitalized patient with COVID-19 and proposed immune-mediated mechanism. *Brain Behav Immun* 2020;89:529–30.

Copyright 2021 BMJ Publishing Group. All rights reserved. For permission to reuse any of this content visit <https://www.bmj.com/company/products-services/rights-and-licensing/permissions/>
BMJ Case Report Fellows may re-use this article for personal use and teaching without any further permission.

Become a Fellow of BMJ Case Reports today and you can:

- ▶ Submit as many cases as you like
- ▶ Enjoy fast sympathetic peer review and rapid publication of accepted articles
- ▶ Access all the published articles
- ▶ Re-use any of the published material for personal use and teaching without further permission

Customer Service

If you have any further queries about your subscription, please contact our customer services team on +44 (0) 207111 1105 or via email at support@bmj.com.

Visit casereports.bmj.com for more articles like this and to become a Fellow