



Since January 2020 Elsevier has created a COVID-19 resource centre with free information in English and Mandarin on the novel coronavirus COVID-19. The COVID-19 resource centre is hosted on Elsevier Connect, the company's public news and information website.

Elsevier hereby grants permission to make all its COVID-19-related research that is available on the COVID-19 resource centre - including this research content - immediately available in PubMed Central and other publicly funded repositories, such as the WHO COVID database with rights for unrestricted research re-use and analyses in any form or by any means with acknowledgement of the original source. These permissions are granted for free by Elsevier for as long as the COVID-19 resource centre remains active.



Guillain Barré syndrome associated with COVID-19- lessons learned about its pathogenesis during the first year of the pandemic, a systematic review

Dear editor,

The disease caused by the coronavirus SARS-CoV-2 (COVID-19), which emerged in China in December 2019 [1], has become a global pandemic in just a few months. The concomitant presentation of COVID-19 and some autoimmune diseases has also been reported, among which is Guillain Barré Syndrome (GBS) [2]. GBS is considered an immune-mediated neuropathy preceded 1 to 6 weeks in 70% of cases by a bacterial or a viral infection. In many cases associated with *Campylobacter jejuni* (the predominant pathogen) the presence of antiganglioside antibodies is observed. This supports a post-infectious mechanism, with molecular mimicry and antibody cross-response [3]. However, in GBS associated with Zika virus infection, an earlier onset is seen, and associated antiganglioside antibodies are rarely present, suggesting a para-infectious pathogenetic mechanism [4]. There is contradictory information on whether GB associated with COVID-19 has also characteristics that may indicate a para-infectious pathogenetic process [5–7]. To review the accumulated evidence about the pathogenic mechanism of this association, we carried out a review of the literature with a selection of the clinical cases reported until February 1st 2021, adding one own case. We selected studies reporting adult patients with all: Guillain-Barré syndrome, according to diagnostic criteria of the GBS Classification Group [8]; SARS-CoV-2 infection confirmed by nasopharyngeal reverse transcription polymerase chain reaction, antigen-detecting rapid diagnostic tests or serum antibody test; Detailed individual clinical description; A minimum of 6/8 points using the Joanna Briggs Institute Critical Appraisal Checklist for Case Reports and for Case Series studies [9,106,107]. Finally, we selected 82 full text access articles with information about 104 clinical cases (Table 1) to which we added our own case (Patient 32). We searched suggestive features of the three pathogenic pathways proposed to neurologic damage in COVID-19 so far [11, 12]: direct damage, dysregulated inflammatory response and antibody-mediated injury (Fig. 1). **Direct damage:** As seen in some viral infections such as poliovirus, enterovirus D68, cytomegalovirus, or other human coronaviruses, SARS-Cov-2 has neuroinvasive capacity [12,13]. The proposed access routes have been through circulation, the blood-brain barrier, or retrograde axonal transport, through the olfactory nerve or the enteric nervous system [12]. Endothelium, glial cells, and neurons express angiotensin-converting enzyme receptor 2 (ACE2) and type II transmembrane serine protease (TMPRSS2), both necessary for the virus to get into the cells [14]. A post mortem study found SARS-CoV-2 RNA in neuroanatomical areas receiving olfactory tract projections [15]. However, PCR in CSF for COVID-19 virus was negative in all reported cases of GBS (Table 1), suggesting no intrathecal viral replication. Furthermore, a recent systematic review and meta-analysis showed that no study detected live SARS-COV-2 in various body fluids beyond day 9 of illness [16] and yet the median days of infection until

the debut of GBS in the actual review has been 11 days. **Dysregulated inflammatory response:** In the “inflammatory phase” of COVID-19 infection, which characteristically begins throughout the second week of infection, elevated IL-2, IL-2R, IL-6, IL-10, IFN- γ , TNF- α , CCL2, procalcitonin, CRP, erythrocyte sedimentation rate and white blood cell, are characteristic [17]. In 2005, brain autopsy studies demonstrate the infiltration of monocytes, macrophages, and T-lymphocytes into gliocytes and brain mesenchyme of SARS-CoV patients [19]. Pilotto et al. has also described the presence of elevated neuroinflammatory parameters (IL-6, IL-8, β 2M and TNF- α) in the CSF of 13 patients with encephalitis and COVID-19 [20]. On the other hand, marked increase of cytokines has previously been reported in GBS and its variants, as well as in experimental autoimmune neuritis, the animal model of GBS [21]. Cell-mediated immunity seems to play a crucial role in immunopathology of all types of GBS, especially the AIDP subtype [22]. Of note, AIDP subtype is the predominant in the current systematic revision (73%, counting with mixed forms) (Table 1). Also, in the present work the medium time between the onset of COVID-19 and the neurological symptoms was 11 days, that is, in the stages of the infection in which inflammatory processes predominate over antibody-mediated. In addition, serum inflammatory parameters were elevated at the beginning of the neurological symptoms in 39/53 patients (73%). **Antibody-mediated injury.** Anti-GM1 IgG are present in a high proportion of patients with classic GBS, mostly those with AMAN or AMSAN. Also, anti-GQ1b IgG antibodies are present in in 80–95% of patients with Miller-Fisher syndrome (MFS), the most common clinical variant of GBS [23]. Nevertheless, Keddie et al. found no significant similarity between SARS CoV-2 and human genome [24] and only 6/58 cases (10%) in our review had positive antiganglioside antibodies, interestingly only 3 of the 17 patients with Miller-Fisher syndrome (20%) (Table 1). Patient number 92 was seropositive for IgM antibodies against panneurofascin without posterior seroconversion to IgG [25]. However, anti-neurofascin antibodies may also have been triggered by tissue damage related to GBS.

In conclusion, the absence of autoantibodies in most GBS cases associated with SARS-CoV2 infection, would force us to think about pathogenic mechanisms other than molecular mimicry. Both the short of the interval of days between the onset of COVID-19 and the neurological symptoms, and the high proportion of patients with serum elevation of inflammation markers at the beginning of neurological symptoms, support the hypothesis that cell-mediated immunity could play a role, as previously proposed for GBS related to Zika.

Funding

The study had no specific funding.

<https://doi.org/10.1016/j.autrev.2021.102875>

Received 5 April 2021; Accepted 11 April 2021

Available online 10 June 2021

1568-9972/© 2021 Elsevier B.V. All rights reserved.

Table 1

Clinical cases obtained in the systematic review of the literature of patients with Guillen Barre Syndrome and a proven history of SARS-Cov-2 infection. Demographic and clinical characteristics, complementary examinations and evaluation of the quality of the case report.

First author (Ref.)	Age	Sex	Severity COVID19 ¹	Latency ²	GBS Clinical variant ³	EMG	SARS-COV-2 CSF	Antiganglioside antibodies	Biomarkers	Treatment COVID-19	Treatment GBS	Evolution at day 30	Study quality [106, 107]	
Abbaslou [26]	Patient 1	55	F	3	32	paraparetic GBS	AMSAN	--	--	LPV/r	Ig iv	dead (ARDS)	7/8	
Abolmaali [27]	Patient 2	88	F	3	--3	classic SGB	AMSAN	--	--	DEXA, LPV/r, HCQ	PPH	poor	7/8	
	Patient 3	58	M	4	9	classic SGB	AMSAN	--	--	Remdensivir, Favipiravir, LPV/r, HCQ	Ig iv + PPH	dead (multi-organ failure)	7/8	
Abrams [28]	Patient 4	67	F	2	10	classic SGB	--	PCR Neg	Neg	--	PPH	partial improvement	7/8	
Agosti [29]	Patient 5	68	M	2	5	classic SGB	AIDP	--	--	antiviral	Ig iv	partial improvement	7/8	
Alberti [30]	Patient 6	71	M	2	4	classic SGB	AIDP	PCR Neg	--	LPV/r, HCQ	Ig iv	dead (ARDS)	7/8	
Ameer [31]	Patient 7	30	M	1	4	classic SGB	AMAN	PCR Neg	Neg	--	Ig iv	complet recovery	8/8	
Arnaud [32]	Patient 8	64	M	2	21	classic SGB	AIDP	PCR Neg	Neg	CXM, AZM, HCQ	Ig iv	complet recovery	8/8	
Assini [33]	Patient 9	55	M	3	--	Miller-Fisher	AIDP	PCR Neg	Neg	HCQ, LPV/r, Arbidol	Ig iv	complet recovery	7/8	
	Patient 10	60	M	3	--	classic SGB	AMSAN	--	Neg	HCQ, LPV/r, TCZ	Ig iv	partial improvement	6/8	
Atakla [34]	Patient 11	40	M	3	11	classic SGB	AIDP	PCR Neg	--	AZM	Ig iv	partial improvement	7/8	
Barranchina-Esteve [35]	Patient 12	54	F	3	0	classic SGB	AMSAN	PCR Neg	Neg	CXM, AZM, HCQ, LPV/r, MP, TCZ	Ig iv	complet recovery	8/8	
Bigaut [36]	Patient 13	43	M	2	21	classic SGB	AIDP	PCR Neg	Neg	--	Ig iv	partial improvement	8/8	
	Patient 14	70	F	3	7	classic SGB	AIDP	PCR Neg	Neg	elevated CRP	Ig iv	partial improvement	8/8	
Boostani [37]	Patient 15	37	M	3	15	classic SGB	AIDP	--	--	elevated ESR, CRP	Ig iv	partial improvement	7/8	
Bracaglia [38]	Patient 16	66	F	1	--	classic SGB	AIDP	--	Neg	LPV/r, HCQ,	Ig iv	partial improvement	7/8	
Bueso [39]	Patient 17	60	F	2	22	classic SGB	--	--	--	AZM, HCQ	Ig iv	partial improvement	7/8	
Caamaño [40]	Patient 18	61	M	2	10	BWDP	--	PCR Neg	--	HCQ, LPV/r	PRED low dose	partial improvement	8/8	
Camdessanche [41]	Patient 19	64	M	2	11	classic SGB	AIDP	--	Neg	LPV/r	Ig iv	--	6/8	
Chan [42]	Patient 20	58	M	2	--	BWDP	AIDP	PCR Neg	--	thrombocytopenia, elevated DD	CXM, AZM, Ig iv	partial improvement	7/8	
Civardi [43]	Patient 21	72	F	1	10	classic SGB	AIDP	PCR Neg	anti-GM1, anti-GD1a and anti-GD1b	elevated fibrinogen, CRP	HCQ, DOX,	Ig iv	partial improvement	8/8
Coen [44]	Patient 22	70	M	1	10	classic SGB	AIDP	PCR Neg	Neg	--	Ig iv	partial improvement	8/8	
Colonna [45]	Patient 23	62	M	3	21	classic SGB	AIDP	--	--	elevated CRP	LPV/r, MP (60 mg/24 h)	Ig iv	partial improvement	7/8
Defabio [46]	Patient 24	70	F	1	90	classic SGB	--	--	--	ND	Ig iv	complet recovery	7/8	
Diez-Porras [47]	Patient 25	54	M	1	5	classic SGB	AIDP	--	IgM for GM2 and GD3 and a weak IgG for GT1b	elevated CRP, LDH y CK	AZM, HCQ, LPV/r	Ig iv	partial improvement	7/8
El Otmani [48]	Patient 26	70	F	2	3	classic SGB	AMSAN	PCR Neg	--	lymphopenia	HCQ, AZM	Ig iv	poor	7/8
Elkhouly [49]	Patient 27	75	M	--	--	classic SGB	--	--	--	MP	Ig iv	partial improvement	6/8	
Esteban [50]	Patient 28	55	F	2	14	classic SGB	AIDP	--	--	elevated CRP	HCQ, CXM, AZM	Ig iv	partial improvement	7/8
Farzi [51]	Patient 29	41	M	2	10	classic SGB	AIDP	--	--	lymphopenia, elevated CRP	LPV/r, HCQ	Ig iv	partial improvement	7/8
Fernandez-Dominguez [52]	Patient 30	74	F	2	15	Miller-Fisher	AIDP	--	Neg	--	HCQ, LPV/r	Ig iv	partial improvement	7/8

(continued on next page)

Table 1 (continued)

First author (Ref.)	Age	Sex	Severity COVID19 ¹	Latency ²	GBS Clinical variant ³	EMG	SARS-COV-2 CSF	Antiganglioside antibodies	Biomarkers	Treatment COVID-19	Treatment GBS	Evolution at day 30	Study quality [106, 107]	
Ferraris [53]	Patient 31	65	F	4	23	classic SGB	AIDP	--	--	elevated IL-6	HCQ, HBPM, AZM, TCZ, LPV/r, MP	Ig iv	partial improvement	7/8
Freire	Patient 32	71	M	2	9	classic SGB	AIDP	--	Neg	Elevated CRP, DD, LDH, ferritin, IL-6	MP	Ig iv	partial improvement	7/8
Gale [54]	Patient 33	58	M	2	--	classic SGB	AIDP	--	--	lymphopenia, elevated CRP	--	Ig iv	partial improvement	6/8
Garcia-Manzanedo [55]	Patient 34	77	M	2	21	PCBW	Mixed	--	--	--	LPV/r, HCQ	Ig iv	partial improvement	7/8
Garnero [56]	Patient 35	65	M	2	--	classic SGB	AIDP	--	Neg	--	--	Ig iv	--	6/8
	Patient 36	73	M	2	0	classic SGB	--	PCR Neg	Neg	--	--	Ig iv	--	7/8
	Patient 37	55	M	2	20	Miller-Fisher-GBS overlap	--	PCR Neg	Neg	--	--	Ig iv	--	7/8
	Patient 38	46	F	1	3	classic SGB	--	PCR Neg	Neg	--	--	Ig iv	--	7/8
	Patient 39	60	M	2	20	classic SGB	AMSAN	PCR Neg	Neg	--	--	Ig iv	--	7/8
	Patient 40	63	F	2	15	classic SGB	AMSAN	--	Neg	--	--	Ig iv	--	7/8
Ghosh [57]	Patient 41	20	M	1	8	classic SGB	AMAN	--	Neg	lymphopenia	--	Ig iv	partial improvement	7/8

First author (Ref.)	Age	Sex	Severity COVID19 ¹	Latency ²	GBS Clinical variant ³	EMG	SARS-COV-2 CSF	Antiganglioside antibodies	Biomarkers	Treatment COVID-19	Treatment GBS	Evolution at day 30	Study quality ⁴	
Gigli [58]	Patient 42	53	M	2	--	paraparetic SGB	AIDP	--	Neg	elevated IL-8, IL-6	--	Ig iv	partial improvement	7/8
Granjer [59]	Patient 43	48	M	1	25	classic SGB	AIDP	--	--	--	PPH	partial improvement	7/8	
Guijarro-Castro [60]	Patient 44	70	M	2	21	classic SGB	Mixed	--	Neg	lymphopenia, thrombocythaemia,	HCQ, CXM, AZM, DXM	Ig iv	partial improvement	7/8
Gutierrez-Ortiz [61]	Patient 45	50	M	1	5	Miller-Fisher	--	PCR Neg	anti-GD1b	lymphopenia, elevated CRP	--	Ig iv	complet recovery	7/8
Helbok [62]	Patient 46	68	M	2	14	classic SGB	AIDP	PCR Neg	Neg	elevated CRP, ESR, fibrinogen	--	Ig iv + PPH	partial improvement	8/8
Hirayama [63]	Patient 47	54	F	2	20	classic SGB	AMAN	--	Neg	normal	--	PPH	partial improvement	8/8
Hutchins [64]	Patient 48	21	M	2	16	BWDP	Mixed	--	Neg	lymphopenia	--	PPH	partial improvement	7/8
Kajani [65]	Patient 49	50	M	1	--	Miller-Fisher	--	PCR Neg	Neg	normal	--	Ig iv	dead (ventricular arrhythmia)	6/8
Khaja [66]	Patient 50	44	M	1	0	Bifacial weakness	--	PCR Neg	Neg	normal	--	Ig iv	complet recovery	8/8
Kopsick [67]	Patient 51	31	M	1	0	Miller-Fisher	--	--	anti-GQ1b	--	convalescent plasma, TCZ	Ig iv	partial improvement	7/8
Korem [68]	Patient 52	58	F	1	14	classic SGB	--	--	--	normal	AZM	Ig iv	partial improvement	7/8
Lampe [69]	Patient 53	65	M	1	1	classic SGB	AIDP	--	Neg	leucopenia, elevated CRP	--	Ig iv	partial improvement	7/8
Lantos [70]	Patient 54	36	M	1	4	Miller-Fisher	--	--	Neg	--	HCQ	Ig iv	complet recovery	7/8
Lascano [71]	Patient 55	52	F	1	15	classic SGB	AIDP	PCR Neg	Neg	normal	--	Ig iv	complet recovery	8/8
	Patient 56	63	F	1	7	classic SGB	AIDP	PCR Neg	--	lymphopenia, elevated transaminases	--	Ig iv	poor	7/8
	Patient 57	61	F	1	22	classic SGB	AIDP	PCR Neg	--	lymphopenia	--	Ig iv	partial improvement	7/8
Lowery [72]	Patient 58	45	M	2	14	Overlap Miller Fisher + SGB	--	--	anti-GQ1b	--	HCQ	Ig iv	partial improvement	8/8
Liberatore [73]	Patient 59	49	M	2	12	PCBW	AMAN	PCR Neg	Neg	lymphopenia, thrombocythaemia. eElevated CRP	HCQ, LPV/r, CXM	--	partial improvement	8/8
MacDonell [74]	Patient 60	54	M	2	3	classic SGB	--	--	Neg	normal	HCQ	Ig iv	complet recovery	8/8

(continued on next page)

Table 1 (continued)

First author (Ref.)	Age	Sex	Severity COVID19 ¹	Latency ²	GBS Clinical variant ³	EMG	SARS-COV-2 CSF	Antiganglioside antibodies	Biomarkers	Treatment COVID-19	Treatment GBS	Evolution at day 30	Study quality ⁴	
Maideniuc [75]	Patient 61	61	F	1	28	classic SGB	AMAN	PCR Neg	normal		PPH	partial improvement	8/8	
Manganotti [76]	Patient 62	50	F	2	16	Miller-Fisher		—	Neg	LPV/r, HCQ	Ig iv	complet recovery	7/8	
Manganotti [77]	Patient 63	72	M	2	18	classic SGB	AIDP	PCR Neg	Neg	Elevated IL6	HCQ, Oseltamivir, darunavir, MP, TCZ	Ig iv	partial improvement	8/8
	Patient 64	72	M	2	30	classic SGB	Mixed	PCR Neg	Neg	Normal	HCQ, LPV/r, MP	Ig iv	partial improvement	8/8
	Patient 65	49	F	2	14	Miller-Fisher	AIDP	PCR Neg	Neg	Normal	HCQ, LPV/r, MP	Ig iv	partial improvement	8/8
	Patient 66	94	M	2	33	classic SGB	AIDP	—	—	—	MP	MP	poor	7/8
	Patient 67	76	M	2	22	classic SGB	AIDP	PCR Neg	Neg	Elevated IL6	HCQ, Oseltamivir, darunavir, MP, TCZ.	Ig iv	partial improvement	8/8
Marta-Enguita [78]	Patient 68	78	F	2	8	classic SGB	—	—	—	thrombocythaemia, Elevated DD	—	—	dead	7/8
Naddaf [79]	Patient 69	58	F	2	17	classic SGB	AIDP	PCR Neg	Neg	Elevated DD, ferritine	HCQ, MP	PPH	partial improvement	8/8
Nanda [80]	Patient 70	55	F	1	10	classic SGB	AMAN	—	—	elevated CRP, Ferritine, IL6, DD, LDH	—	Ig iv	complet recovery	7/8
	Patient 71	72	M	2	6	classic SGB	AIDP	—	—	elevated CRP, Ferritine, IL6, DD, LDH	—	Ig iv	dead	7/8
	Patient 72	55	M	1	7	classic SGB	AMSAN	—	—	Elevated CRP, Ferritine, IL6, DD, LDH	—	Ig iv	complet recovery	7/8
	Patient 73	49	M	2	10	classic SGB	AMAN	—	—	Elevated ferritin, LDH	—	Ig iv	complet recovery	7/8
Oguz-Akarsu [81]	Patient 74	53	F	2	0	classic SGB	AIDP	PCR Neg	—	lymphopenia, elevated CRP	HCQ, AZM	PPH	complet recovery	7/8
Ottavani [5]	Patient 75	66	F	3	7	classic SGB	Mixed	PCR Neg	Neg	lymphopenia, elevated CRP, DD.	LPV/r, HCQ,	Ig iv	—	7/8
Paybast [82]	Patient 76	38	M	1	21	classic SGB	Mixed	—	—	normal	HCQ	PPH	partial improvement	7/8
Pelea [83]	Patient 77	56	F	1	7	classic SGB	Mixed	PCR Neg	Neg	normal	—	PPH + Ig iv	partial improvement	8/8
Petrelli [84]	Patient 78	57	M	1	17	classic SGB	AMAN	PCR Neg	anti-GM1, anti-GD1a	—	—	Ig iv, DM	partial improvement	8/8
Padroni [85]	Patient 79	70	F	1	24	classic SGB	AIDP	—	—	linfocitosis	—	Ig iv	poor	7/8

First author (Ref.)	Age	Sex	Severity COVID19 ¹	Latency ²	GBS Clinical variant ³	EMG	SARS-COV-2 CSF	Antiganglioside antibodies	Biomarkers	Treatment COVID-19	Treatment GBS	Evolution at day 30	Study quality ⁴	
Raahimi [86]	Patient 80	46	M	3	45	classic SGB	AIDP	—	—	Normal	—	Ig iv	partial improvement	7/8
Rajdev [87]	Patient 81	36	M	3	18	classic SGB	AIDP	—	—	—	remdesivir	Ig iv, PPH	partial improvement	7/8
Rana [88]	Patient 82	54	M	1	14	overlap Miller Fisher - classic SGB	AIDP	—	—	—	amoxicilin, short course steroids, HCQ, AZM	Ig iv, PPH	—	7/8
Ray [89]	Patient 83	63	M	1	1	Miller Fisher	—	—	—	Elevated CRP, lymphopenia, neutropenia	—	—	partial improvement	6/8
Redondo [90]	Patient 84	54	F	2	15	classic SGB	AIDP	PCR Neg	—	Normales	—	Ig iv	partial improvement	7/8
Reyes-Bueno [91]	Patient 85	51	F	1	15	overlap Miller Fisher - classic SGB	AIDP	—	Neg	—	—	Ig iv, gabapentina	partial improvement	7/8
Riva [92]	Patient 86	sixties	M	2	20	classic SGB	AIDP	PCR Neg	Neg	—	—	Ig iv	—	7/8

(continued on next page)

Table 1 (continued)

First author (Ref.)	Age	Sex	Severity COVID19 ¹	Latency ²	GBS Clinical variant ³	EMG	SARS-COV-2 CSF	Antiganglioside antibodies	Biomarkers	Treatment COVID-19	Treatment GBS	Evolution at day 30	Study quality ⁴
Sancho-Saldaña [93]	Patient 87	56	F	2	15	classic SGB	AIDP	Neg	Elevated IL-6, ferritina, LDH, fibrinógeno	HCQ, AZM	Ig iv	--	7/8
Scheidl [94]	Patient 88	54	F	1	21	classic SGB	AIDP	--	CRP normal	--	Ig iv	complet recovery	7/8
Sedaghat [95]	Patient 89	65	M	2	14	classic SGB	AMAN		Elevated ESR, CRP	HCQ, LPV/r, AZM	Ig iv		7/8
Senel [96]	Patient 90	61	M	1	20	Miller Fisher	AIDP	PCR Neg Ac Neg	Neurofilament light chain (NfL) protein elevated	--	Ig iv	complet recovery	8/8
Su [97]	Patient 91	72	M	1	6	classic SGB	AIDP	PCR Neg			Ig iv	poor	7/8
Tard [25]	Patient 92	76	M	1	7	overlap Miller Fisher - classic SGB	AIDP	PCR Neg	Neg, Anti-NF155 and anti-NF186 IgM, no IgG seroconversion	--	Ig iv, PPH, MP	partial improvement	7/8
Tiet [98]	Patient 93	49	M	1	21	classic SGB	AIDP	PCR Neg			Ig iv, gabapentina	partial improvement	7/8
Toscano [99]	Patient 94	77	F	2	7	classic SGB	AMAN	PCR Neg	lymphopenia, Elevated CRP, LDH	--	Ig iv	poor	8/8
	Patient 95	23	M	1	10	overlap Miller Fisher - classic SGB	AMAN	PCR Neg	lymphopenia, Elevated ferritine, CRP, LDH, AST	--	Ig iv	partial improvement	7/8
	Patient 96	55	M	2	10	classic SGB	AMAN	PCR Neg	lymphopenia, Elevated CRP, LDH, AST, GGT	--	Ig iv	poor	8/8
	Patient 97	76	M	1	5	overlap Miller Fisher - classic SGB	AIDP	PCR Neg	lymphopenia Raised CRP,	--	Ig iv	partial improvement	7/8
	Patient 98	61	M	2	7	classic SGB	AIDP	PCR Neg	Lymphocytopenia Elevated CRP, LDH, AST	--	Ig iv, PPH	poor	8/8
Velayos [100]	Patient 99	43	M	2	10	classic SGB	AIDP	--		HCQ, LPV/r, corticoids (NE)	Ig iv	satisfactory	7/8
Virani [101]	Patient 100	54	M	2	10	classic SGB	--	--		--	Ig iv	partial improvement	7/8
Webb [102]	Patient 101	57	M	2	7	classic SGB	AIDP	PCR Neg	lymphopenia, thrombocythaemia, raised CRP		Ig iv	partial improvement	8/8
Zhao [103]	Patient 102	61	F	2	7	classic SGB	AIDP		lymphopenia thrombocytopenia elevated CRP	arbidol, LPV/r	Ig iv	complet recovery	8/8
Zito [104]	Patient 103	57	M	1	12	classic SGB	AMAN	Neg			Ig iv	complet recovery	8/8
Zubair [105]	Patient 104	32	M	4	60	classic SGB	AMSAN	--		TCZ, HCQ,	Ig iv	partial improvement	7/8
	Patient 105	61	M	4	60	classic SGB	AMSAN	--		TCZ	Ig iv	partial improvement	7/8

-: information not available; ¹ 1: uncomplicated disease, 2: mild pneumonia, 3: respiratory distress, 4: septic shock; ² Days from onset of COVID-19 symptoms to onset of GB symptoms; ³ According to diagnostic criteria for GBS, MFS and their subtypes of the GBS Classification Group [8].; ⁴ JBI (Joanna Briggs Institute) Critical Appraisal Checklist for Case Reports and for Case Series studies [,]; F: female; M: male; BWDP: bifacial weaknees whit distal parestesias; PCBW: pharyngeal-cervical-brachial weakness; AMSAN: acute motor-sensory axonal neuropathy; AIDP: Acute inflammatory demyelinating polyneuropathy; AMAN: acute motor axonal neuropathy; Neg: negative; Pos: positive; PCR SARS-COV-2 CSF: Polymerase chain reaction detection of SARS-Cov-2 in cerebrospinal fluid; DD: D-dimer; CRP: c-reactive protein; ESR: erythrocyte sedimentation rate; LPV/r: Lopinavir/ritonavir; NE: not specified; HCQ: Hydroxychloroquine; CXM: ceftriaxone; AZM: azithromycin; MP: methylprednisolone; TCZ: tocilizumab; DOX: doxycycline; DXM: dexamethasone; Ig iv: intravenous immunoglobulins; PPH: plasmapheresis; PRED: prednisone; ARDS: acute respiratory distress syndrome.

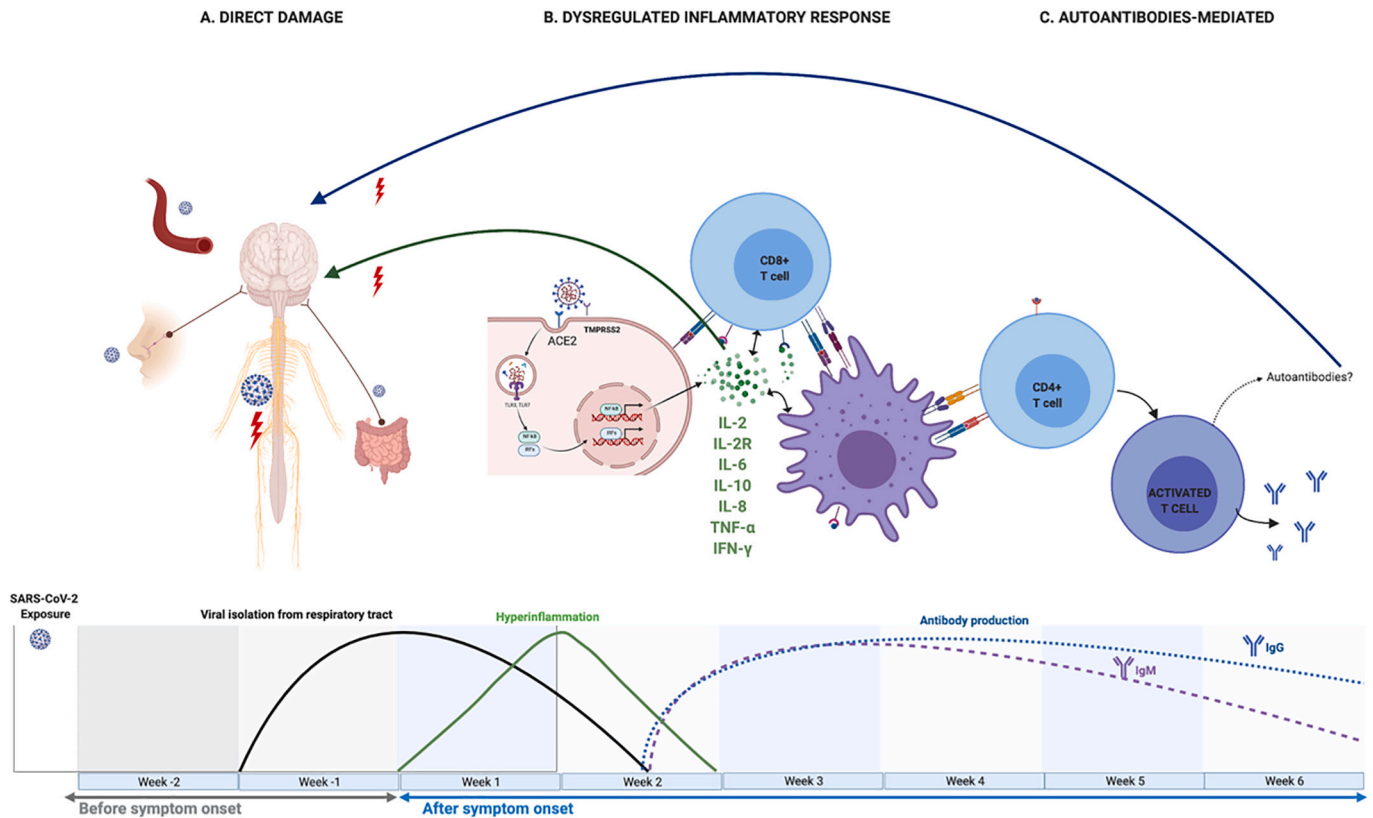


Fig. 1. Existing hypotheses about pathogenic pathways for neurologic damage associated with COVID-19. A. Direct damage. SARS-CoV-2 could reach the central nervous system through circulation or retrograde axonal transport, through the olfactory nerve or the enteric nervous system. B. Dysregulated inflammatory response. IL-2, IL-2R, IL-6, IL-10, IFN- γ and TNF- α , are elevated in the “inflammatory phase” of COVID-19 infection. These molecules can stimulate macrophages, dendritic cells, Schwann cells, and epithelial cells that would damage the nervous system. ACE2: Angiotensin-converting enzyme 2; TMPRSS2: Transmembrane protease, serine 2. C. Autoantibody-mediated injury. The existence of a cross-reactivity between epitopes of the SARS-CoV-2 spike and the glycolipids of the peripheral nerve would be probable. This figure was created using BioRender (<https://biorender.com/>).

Declaration of Competing Interest

The authors declare that no conflict of interest exists.

References

[1] Guan W-J, Ni Z-Y, Hu Y, Liang W-H, Ou C-Q, He J-X, et al. Clinical characteristics of coronavirus disease 2019 in China. *N Engl J Med* 2020;382(18):1708–20.

[2] Dotan A, Muller S, Kanduc D, David P, Halpert G, Shoenfeld Y. The SARS-CoV-2 as an instrumental trigger of autoimmunity. *Autoimmun Rev* 2021;Vol. 20: 102792.

[3] Hao Y, Wang W, Jacobs BC, Qiao B, Chen M, Liu D, et al. Antecedent infections in Guillain-Barré syndrome: a single-center, prospective study. *Ann Clin Transl Neurol* 2019;6(12):2510–7.

[4] Parra B, Lizarazo J, Jiménez-Arango JA, Zea-Vera AF, González-Manrique G, Vargas J, et al. Guillain-Barré syndrome associated with Zika virus infection in Colombia. *N Engl J Med* 2016;375(16):1513–23.

[5] Ottaviani D, Boso F, Tranquillini E, Gapei I, Pedrotti G, Cozzio S, et al. Early Guillain-Barré syndrome in coronavirus disease 2019 (COVID-19): a case report from an Italian COVID-hospital. *Neurol Sci* 2020;41(6):1351–4.

[6] Abu-Rumeileh S, Abdelhak A, Foschi M, Tumani H, Otto M. Guillain-Barré syndrome spectrum associated with COVID-19: an up-to-date systematic review of 73 cases. *J Neurol* 2020;95:1–38.

[7] Hasan I, Saif-Ur-Rahman K, Hayat S, Papri N, Jahan I, Azam R, et al. Guillain-Barré syndrome associated with SARS-CoV -2 infection: a systematic review and individual participant data meta-analysis. *J Peripher Nerv Syst* 2020;25(4): 335–43.

[8] Wakerley BR, Uncini A, Yuki N. Guillain-Barré and miller fisher syndromes - new diagnostic classification. *Nat Rev Neurol* 2014;10(9):537–44.

[11] Guadarrama-Ortiz P, Choreño-Parra J, Sánchez-Martínez C, Al E. Neurological aspects of SARS-CoV-2 infection: mechanisms and manifestations. *Front Neurol* 2020;11:1039.

[12] Mohammadi S, Moosaie F, Arabi MH. Understanding the immunologic characteristics of neurologic manifestations of SARS-CoV-2 and potential immunological mechanisms. *Mol Neurobiol* 2020;57(12):5263–75.

[13] Li YC, Bai WZ, Hashikawa T. The neuroinvasive potential of SARS-CoV2 may play a role in the respiratory failure of COVID-19 patients. *J Med Virol* 2020;92(6): 552–5.

[14] Rabi FA, Al Zoubi MS, Al-Nasser AD, Kasasbeh GA, Salameh DM. Sars-cov-2 and coronavirus disease 2019: what we know so far. *Pathogens*. 2020;9(3):231.

[15] Meinhardt J, Radke J, Dittmayer C, Mothes R, Franz J, Laue M, et al. Olfactory transnasal SARS-CoV-2 invasion as part of central nervous system entry in COVID-19 patients. *Nat Neurosci* 2020;24(2):168–75.

[16] Cevik M, Tate M, Lloyd O, Maraolo AE, Schafers J, Ho A. SARS-CoV-2, SARS-CoV, and MERS-CoV viral load dynamics, duration of viral shedding, and infectiousness: a systematic review and meta-analysis. *Lancet Microbe* 2021;2(1):e13–22.

[17] López-Collazo E, Avendaño-Ortiz J, Martín-Quiros A, Aguirre LA. Immune response and COVID-19: a mirror image of sepsis. *Int J Biol Sci* 2020;16(14): 2479–89.

[19] Xu J, Zhong S, Liu J, Li L, Li Y, Wu X, et al. Detection of severe acute respiratory syndrome coronavirus in the brain: potential role of the chemokine mig in pathogenesis. *Clin Infect Dis* 2005;41(8):1089–96.

[20] →Pilotto A, Masciocchi S, Volonghi I, De Giuli V, Caprioli F, Mariotto S, et al. SARS-CoV-2 encephalitis is a cytokine release syndrome: evidences from cerebrospinal fluid analyses. *Clin Infect Dis* 2021;Jan 4:ciaa1933.

[21] Wu X, Wang J, Liu K, Zhu J, Zhang HL. Are Th17 cells and their cytokines a therapeutic target in Guillain-Barré syndrome? *Expert Opin Ther Targets* 2016;20 (2):209–22.

[22] Ebrahim Soltani Z, Rahmani F, Rezaei N. Autoimmunity and cytokines in Guillain-Barré syndrome revisited: review of pathomechanisms with an eye on therapeutic options. *Eur Cytokine Netw* 2019;30(1):1–14.

[23] Goodfellow JA, Willison HJ. Guillain-Barré syndrome: a century of progress. *Nat Rev Neurol* 2016;12(12):723–31.

[24] Keddie S, Pakpoor J, Mouselle C, Pipis M, Machado PM, Foster M, et al. Epidemiological and cohort study finds no association between COVID-19 and Guillain-Barré syndrome. *Brain*. 2021 Mar;144(2):682–93.

[25] Tard C, Maurice CA, de Paula AM, Cassim F, Delval A, Kuchcinski G, et al. Anti-paranodopathy IgM in COVID-19-related Guillain-Barré syndrome: evidence for a nodo-paranodopathy. *Neurophysiol Clin* 2020;50(5):397–9.

[26] Abbaslou MA, Karbasi M, Mozhdehpanah H. A rare axonal variant of guillain-barré syndrome as a neurological complication of covid-19 infection. *Arch Iran Med* 2020;23(10):718–21.

- [27] Abolmaali M, Heidari M, Zeinali M, Moghaddam P, Ghamsari MR, Makiani MJ, et al. Guillain-Barre syndrome as a parainfectious manifestation of SARS-CoV-2 infection: a case series. *J Clin Neurosci* 2021 Jan;83:119–22.
- [28] Abrams RMC, Kim BD, Markantone DM, Reilly K, Paniz-Mondolfi AE, Gitman MR, et al. Severe rapidly progressive Guillain-Barré syndrome in the setting of acute COVID-19 disease. *J Neuro-Oncol* 2020;26(5):797–9.
- [29] Agosti E, Giorgianni A, D'Amore F, Vinacci G, Balbi S, Locatelli D. Is Guillain-Barré syndrome triggered by SARS-CoV-2? Case report and literature review. *Neurol Sci* 2020;42(2):607–12.
- [30] Alberti P, Beretta S, Piatti M, Karantzoulis A, Piatti ML, Santoro P, et al. Guillain-Barré syndrome related to COVID-19 infection. *Neurol Neuroimmunol Neuro-Inflam* 2020;7(4):1–3.
- [31] Ameer N, Shekhda KM, Cheesman A. Guillain-Barré syndrome presenting with COVID-19 infection. *BMJ Case Rep* 2020;13(9):3–5.
- [32] Arnaud S, Budowski C, Ng Wing Tin S, Degos B. Post SARS-CoV-2 Guillain-Barré syndrome. *Clin Neurophysiol* 2020;131(7):1652–4.
- [33] Assini A, Benedetti L, Di Maio S, Schirrinzi E, Del Sette M. Correction to: New clinical manifestation of COVID-19 related Guillain-Barré syndrome highly responsive to intravenous immunoglobulins: two Italian cases (*Neurological Sciences*, (2020), 41, 7, (1657–1658)). *Neurol Sci* 2020;41(8):2307. <https://doi.org/10.1007/s10072-020-04484-5>.
- [34] Atakla HG, Noudohoussi MMUD, Sacca H, Tassiou NRA, Noudohoussi WC, Houinato DS. Acute guillain-barré polyradiculoneuritis indicative of covid-19 infection: a case report. *Pan Afr Med J* 2020;35(Suppl 2):1–6.
- [35] Barrachina-Esteve O, Palau-Domínguez A, Hidalgo-Torrico I, Viguera Martínez M. Guillain-Barré syndrome as the first manifestation of SARS-CoV-2 infection. *Neurología*. 2020;35(9):710–2.
- [36] Bigaut K, Mallaret M, Baloglu S, Nemoz B, Morand P, Baicry F, et al. Guillain-Barré syndrome related to SARS-CoV-2 infection. *Neurol Neuroimmunol Neuro-Inflam* 2020;7(5):4–6.
- [37] Boostani R, Talab FR, Meibodi NT, Zemorshidi F. COVID-19 associated with sensorimotor polyradiculoneuropathy and skin lesions: a case report. *J Neuroimmunol* 2021;350:577434.
- [38] Bracaglia M, Naldi I, Govoni A, Brillanti Ventura D, De Massis P. Acute inflammatory demyelinating polyneuritis in association with an asymptomatic infection by SARS-CoV-2. *J Neurol* 2020;267(11):3166–8.
- [39] Bueso T, Montalvan V, Lee J, Gomez J, Ball S, Shoustari A, et al. Guillain-Barre syndrome and COVID-19: a case report. *Clin Neurol Neurosurg* 2021;200:106413.
- [40] Juliao Caamaño DS, Alonso Beato R. Facial diplegia, a possible atypical variant of Guillain-Barré syndrome as a rare neurological complication of SARS-CoV-2. *J Clin Neurosci* 2020;77:230–2.
- [41] Camdessanche JP, Morel J, Pozzetto B, Paul S, Tholance Y, Botelho-Nevers E. COVID-19 may induce Guillain-Barré syndrome. *Rev Neurol (Paris)* 2020;176(6):516–8.
- [42] Chan JL, Ebadi H, Sarna JR. Guillain-Barré syndrome with facial Diplegia related to SARS-CoV-2 infection. *Can J Neurol Sci* 2020;47(6):852–4.
- [43] Civardi C, Collini A, Geda DJ, Geda C. Antiganglioside antibodies in Guillain-Barré syndrome associated with SARS-CoV-2 infection. *J Neurol Neurosurg Psychiatry* 2020;91(12):1361–2.
- [44] Coena M, Jeansonc G, Culebras Almeida LA, Hübersd A, Stierlina F, Najjara I, et al. Guillain-Barré syndrome as a complication of SARS-CoV-2 infection. *Brain Behav Immun* 2020;87:111–2.
- [45] Colonna S, Sciume L, Giarda F, Innocenti A, Beretta G, Dalla Costa D. Case report: Postacute rehabilitation of Guillain-Barre syndrome and cerebral Vasculitis-like pattern accompanied by SARS-CoV-2 infection. *Front Neurol* 2021;11:602554.
- [46] Defabio AC, Scott TR, Stenberg RT, Simon EL. Guillain-Barré syndrome in a patient previously diagnosed with COVID-19. *Am J Emerg Med* 2020. Epub: S0735–6757(20)30669–0.
- [47] Diez-Porras L, Vergés E, Gil F, Vidal MJ, Massons J, Arboix A. Guillain-Barré-Strohl syndrome and COVID-19: case report and literature review. *Neuromuscul Disord* 2020;30(10):859–61.
- [48] El Otmani H, El Moutawakil B, Rafai MA, El Benna N, El Kettani C, Soussi M, et al. Covid-19 and Guillain-Barré syndrome: more than a coincidence! *Rev Neurol (Paris)* 2020;176(6):518–9.
- [49] Elkhoully A, Kaplan AC. Noteworthy neurological manifestations associated with COVID-19 infection. *Cureus*. 2020;12(7):3–7.
- [50] Esteban A, Mata M, Sánchez P, Carrillo A, ISancho I, Sanjuan T. Guillain-Barré syndrome associated with SARS-CoV-2 infection. *Med Int* 2020;44(8):513–9.
- [51] Farzi MA, Ayromlou H, Jahanbakhsh N, Bavil PH, Janzadeh A, Shayan FK. Guillain-Barré syndrome in a patient infected with SARS-CoV-2, a case report. *J Neuroimmunol* 2020;346:577294.
- [52] Fernández-Domínguez J, Ameijide-Sanluis E, García-Cabo C, García-Rodríguez R, Mateos V. Miller-fisher-like syndrome related to SARS-CoV-2 infection (COVID 19). *J Neurol* 2020;267(9):2495–6.
- [53] Ferraris LE, Sala G, Casalino S, Losurdo L, De Filippis V. Mesenteric artery thrombosis, microvascular intestinal Endothelitis, and Guillain-Barré syndrome in the same SARS-CoV-2 patient. *Cureus*. 2020;12(11):4–9.
- [54] Gale A, Sabaretnam S, Lewinsohn A. Guillain-Barré syndrome and COVID-19: association or coincidence. *BMJ Case Rep* 2020;13(11):e239241.
- [55] García-Manzanedo S, López de la Oliva Calvo L, Ruiz Álvarez L. Guillain-Barré syndrome after covid-19 infection. *Med Clin (Barc)* 2020;155(8):366.
- [56] Garnero M, Del Sette M, Assini A, Beronio A, Capello E, Cabona C, et al. COVID-19-related and not related Guillain-Barré syndromes share the same management pitfalls during lock down: The experience of Liguria region in Italy. *J Neurol Sci* 2020;418:117114.
- [57] Ghosh R, Roy D, Sengupta S, Benito-León J. Autonomic dysfunction heralding acute motor axonal neuropathy in COVID-19. *J Neuro-Oncol* 2020;96:4–6.
- [58] Gigli GL, Vogrig A, Nilo A, Fabris M, Biasotto A, Curcio F, et al. HLA and immunological features of SARS-CoV-2-induced Guillain-Barré syndrome. *Neurol Sci* 2020;41(12):3391–4.
- [59] Granger A, Omari M, Jakubowska-Sadowska K, Boffa M, Zakin E. SARS-CoV-2-associated Guillain-Barre syndrome with good response to plasmapheresis. *J Clin Neuromuscul Dis* 2020;22(1):58–9.
- [60] Gujjarro-Castro C, Rosón-González M, Abreu A, García-Arratibel A, Ochoa-Mulas M. Guillain-Barré syndrome associated with SARS-CoV-2 infection. Comments after 16 published cases. *Neurología*. 2020;35(6):412–5.
- [61] Gutiérrez-Ortiz C, Méndez-Guerrero A, Rodrigo-Rey S, San Pedro-Murillo E, Bermejo-Guerrero L, Gordo-Mañas R, et al. Miller fisher syndrome and polyneuritis cranialis in COVID-19. *Neurology*. 2020;95(5):e601–5.
- [62] Helbok R, Beer R, Löscher W, Boesch S, Reindl M, Hornung R, et al. Guillain-Barré syndrome in a patient with antibodies against SARS-COV-2. *Eur J Neurol* 2020;27(9):1754–6.
- [63] Hirayama T, Hongo Y, Kaida K, Kano O. Guillain-Barré syndrome after COVID-19 in Japan. *BMJ Case Rep* 2020;13(10):1–4.
- [64] Hutchins KL, Jansen JH, Comer AD, Scheer RV, Zahn GS, Capps AE, et al. COVID-19-associated bifacial weakness with paresthesia subtype of guillain-barré syndrome. *Am J Neuroradiol* 2020;41(9):1707–11.
- [65] Kajani S, Kajani R, Huang C-W, Tran T, Liu AK. Miller fisher syndrome in the COVID-19 era - a novel target antigen calls for novel treatment. *Cureus*. 2021;13(1):e12424.
- [66] Khaja M, Roa Gomez GP, Santana Y, Hernandez N, Haider A, Lara JLP, et al. A 44-year-old hispanic man with loss of taste and bilateral facial weakness diagnosed with Guillain-Barré syndrome and Bell's palsy associated with SARS-CoV-2 infection treated with intravenous immunoglobulin. *Am J Case Rep* 2020;21:1–6.
- [67] Kopsck M, Giourgas B, Presley B. A case report of acute motor and sensory polyneuropathy as the presenting symptom of SARS-CoV-2. *Clin Pract Cases Emerg Med* 2020;4(3):352–4.
- [68] Korem S, Gandhi H, Dayag DB. Guillain-Barré syndrome associated with COVID-19 disease. *BMJ Case Rep* 2020;13(9):e237215.
- [69] Lampe A, Winschel A, Lang C, Steiner T. Guillain-Barré Syndrome and SARS-CoV-2. 2020. 10–2.
- [70] Lantos J, Strauss S, Lin E. COVID-19 – Associated Miller Fisher Syndrome: MRI Findings. 2020. p. 1184–6.
- [71] Lascano AM, Epiney JB, Coen M, Serratrice J, Bernard-Valnet R, Lalive PH, et al. SARS-CoV-2 and Guillain-Barré syndrome: AIDP variant with a favourable outcome. *Eur J Neurol* 2020;27(9):1751–3.
- [72] Lowery MM, Taimur Malik M, Seemiller J, Tsal CS. Atypical variant of Guillain Barre syndrome in a patient with COVID-19. *J Crit Care Med* 2020;6(4):231–6.
- [73] Liberatore G, De Santis T, Doneddu PE, Gentile F, Albanese A, Nobile-Orazio E. Clinical reasoning: a case of COVID-19-associated pharyngeal-cervical-brachial variant of Guillain-Barré syndrome. *Neurology*. 2020;95(21):978–83.
- [74] McDonnell EP, Altomare NJ, Parekh YH, Gowda RC, Parikh PD, Lazar MH, et al. COVID-19 as a trigger of recurrent Guillain-Barré syndrome. *Pathogens*. 2020;9(1):1–9.
- [75] Maidenluc C, Memon AB. Acute necrotizing myelitis and acute motor axonal neuropathy in a COVID-19 patient. *J Neurol* 2020;268(2):739.
- [76] Manganotti P, Pesavento V, Buoite Stella A, Bonzi L, Campagnolo E, Bellavita G, et al. Miller fisher syndrome diagnosis and treatment in a patient with SARS-CoV-2. *J Neuro-Oncol* 2020;26(4):605–6.
- [77] Manganotti P, Bellavita G, D'Acunto L, Tommasini V, Fabris M, Sartori A, et al. Clinical neurophysiology and cerebrospinal liquor analysis to detect Guillain-Barré syndrome and polyneuritis cranialis in COVID-19 patients: a case series. *J Med Virol* 2020;93(2):766–74.
- [78] Marta-Enguita J, Rubio-Baines I, Gastón-Zubimendi I. Síndrome de Guillain-Barré fatal tras infección por el virus SARS-CoV-2. *Neurología*. 2020;35(4):265–7.
- [79] Naddaf E, Laughlin RS, Klein CJ, Toledano M, Theel ES, Binnicker MJ, et al. Guillain-Barré syndrome in a patient with evidence of recent SARS-CoV-2 infection. *Mayo Clin Proc* 2020;95(8):1799–801.
- [80] Nanda S, Handa R, Prasad A, Anand R, Zutshi D, Dass SK, et al. Covid-19 associated Guillain-Barre syndrome: contrasting tale of four patients from a tertiary care Centre in India. *Am J Emerg Med* 2021 Jan;39:125–8.
- [81] Oguz-Akarsu E, Ozpar R, Mirzayev H, Acet-Ozturk NA, Hakyemez B, Ediger D, et al. Guillain-Barré syndrome in a patient with minimal symptoms of COVID-19 infection. *Muscle Nerve* 2020;62(3):E54–7.
- [82] Paybast S, Gorji R, Mavandadi S. Guillain-Barré syndrome as a neurological complication of novel COVID-19 infection: a case report and review of the literature. *Neurologist*. 2020;25(4):101–3.
- [83] Pelea T, Reuter U, Schmidt C, Laubinger R, Siegmund R, Walther BW. SARS-CoV-2 associated Guillain-Barré syndrome. *J Neurol* 2020;268(4):1191–4. Epub(Aug 8):1–4.
- [84] Petrelli C, Scendoni R, Paglioriti M, Logullo FO. Acute motor axonal neuropathy related to COVID-19 infection: a new diagnostic overview. *J Clin Neuromuscul Dis* 2020;22(2):120–1.
- [85] Padroni M, Mastrangelo V, Asioli GM, Pavolucci L, Abu-Rumeileh S, Piscaglia MG, et al. Guillain-Barré syndrome following COVID-19: new infection, old complication? *J Neurol* 2020;267(7):1877–9.
- [86] Raahimi MM, Kane A, Moore CE, Alareed AW. Late onset of Guillain-Barré syndrome following SARS-CoV-2 infection: part of “long COVID-19 syndrome”? *BMJ Case Rep* 2021;14(1):e240178.

- [87] Rajdev K, Victor N, Buckholtz ES, Hariharan P, Saeed MA, Hershberger DM, et al. A case of Guillain-Barré syndrome associated with COVID-19. *J Investig Med* 2020;8 (high impact case reports). 2324709620961198.
- [88] Rana S, Lima AA, Chandra R, Valeriano J, Desai T, Freiberg W, et al. Novel coronavirus (COVID-19)-associated Guillain-Barré syndrome: case report. *J Clin Neuromuscul Dis* 2020 Jun;21(4):240–2.
- [89] Ray A. Miller fisher syndrome and COVID-19: is there a link. *BMJ Case Rep* 2020; 13(8):19–22.
- [90] Redondo-Urda MJ, Rodríguez-Peguero FJ, Pérez-Gil O, Del Valle-Sánchez M, Carrera-Izquierdo M. SARS-CoV-2, nuevo agente causal del síndrome de Guillain-Barré. *Rev Neurol* 2020;71(7):275–6.
- [91] Reyes-Bueno JA, García-Trujillo L, Urbaneja P, Ciano-Petersen NL, Postigo-Pozo MJ, Martínez-Tomás C, et al. Miller-fisher syndrome after SARS-CoV-2 infection. *Eur J Neurol* 2020;27(9):1759–61.
- [92] Riva N, Russo T, Falzone YM, Strollo M, Amadio S, Del Carro U, et al. Post-infectious Guillain-Barré syndrome related to SARS-CoV-2 infection: a case report. *J Neurol* 2020;267(9):2492–4.
- [93] Sancho-Saldaña A, Lambea-Gil Á, Capablo Liesa JL, Barrena Caballo MR, Garay MH, Celada DR, et al. Guillain-Barré syndrome associated with leptomeningeal enhancement following SARS-CoV-2 infection. *Clin Med J R Coll Physicians London* 2020;20(4):E93–4.
- [94] Scheidl E, Canseco DD, Hadji-Naumov A, Bereznaï B. Guillain-Barré syndrome during SARS-CoV-2 pandemic: a case report and review of recent literature. *J Peripher Nerv Syst* 2020;25(2):204–7.
- [95] Sedaghat Z, Karimi N. Guillain Barre syndrome associated with COVID-19 infection: a case report. *J Clin Neurosci* 2020;76:233–5.
- [96] Senel M, Abu-Rumeileh S, Michel D, Garibashvili T, Althaus K, Kassubek J, et al. Miller-fisher syndrome after COVID-19: neurochemical markers as an early sign of nervous system involvement. *Eur J Neurol* 2020;27(11):2378–80.
- [97] Su XW, Palka SV, Rao RR, Chen FS, Brackney CR, Cambi F. SARS-CoV-2-associated Guillain-Barré syndrome with dysautonomia. *Muscle Nerve* 2020;62(2):E48–9.
- [98] Tiet MY, Alshaiikh N. Guillain-Barré syndrome associated with COVID-19 infection: a case from the UK. *BMJ Case Rep* 2020;13(7):1–4.
- [99] Toscano G, Palmerini F, Ravaglia S, Ruiz L, Invernizzi P, Cuzzoni MG, et al. Guillain-Barré syndrome associated with SARS-CoV-2. *N Engl J Med* 2020;382(26):2574–6.
- [100] Velayos Galán A, del Saz Saucedo P, Peinado Postigo F, Botia Paniagua E. Síndrome de Guillain-Barré asociado a infección por SARS-CoV-2. *Neurología*. 2020;35(4):268–9.
- [101] Virani A, Rabold E, Hanson T, Haag A, Elrufay R, Cheema T, et al. Guillain-Barré syndrome associated with SARS-CoV-2 infection. *IDCases*. 2020;20:e00771.
- [102] Webb S, Wallace VCJ, Martin-Lopez D, Yogarajah M. Guillain-Barré syndrome following COVID-19: a newly emerging post-infectious complication. *BMJ Case Rep* 2020;13(6):1–4.
- [103] Zhao H, Shen D, Zhou H, Liu J, Chen S. Guillain-Barré syndrome associated with SARS-CoV-2 infection: causality or coincidence? *Lancet Neurol* 2020;19(5):383–4.
- [104] Zito A, Alfonsi E, Franciotta D, Todisco M, Gastaldi M, Cotta Ramusino M, et al. COVID-19 and Guillain-Barré syndrome: a case report and review of literature. *Front Neurol* 2020;11:909.
- [105] Zubair AS, Zubair AS, Desai K, Abulaban A, Roy B. Guillain-Barre syndrome as a complication of COVID-19. *Cureus*. 2021 Jan;13(1):e12695.
- [106] Joanna Briggs Institute Checklist for Case Reports. [Accessed 1 March 2021].
- [107] Joanna Briggs Institute Checklist for Case Series. [Accessed 1 March 2021].

Mayka Freire^{a,*}, Ariadna Andrade^a, Bernardo Sopena^a, Maria Lopez-Rodriguez^a, Pablo Varela^b, Purificación Cacabelos^c, Helena Esteban^d, Arturo González-Quintela^a

^a *Unidad de Enfermedades Sistémicas e Inmunopatología, Servicio de Medicina Interna, Hospital Clínico Universitario de Santiago de Compostela, Spain*

^b *Unidad de Enfermedades Infecciosas, Servicio de Medicina Interna, Hospital Clínico Universitario de Santiago de Compostela, Spain*

^c *Servicio de Neurología, Hospital Clínico Universitario de Santiago de Compostela, Spain*

^d *Servicio de Farmacia, Hospital Clínico Universitario de Santiago de Compostela, Spain*

* Corresponding author at: Department of Internal Medicine, Hospital Clínico Universitario, 15706 Santiago de Compostela, Spain.
E-mail address: maria.carmen.freire.dapena@sergas.es (M. Freire).