



Since January 2020 Elsevier has created a COVID-19 resource centre with free information in English and Mandarin on the novel coronavirus COVID-19. The COVID-19 resource centre is hosted on Elsevier Connect, the company's public news and information website.

Elsevier hereby grants permission to make all its COVID-19-related research that is available on the COVID-19 resource centre - including this research content - immediately available in PubMed Central and other publicly funded repositories, such as the WHO COVID database with rights for unrestricted research re-use and analyses in any form or by any means with acknowledgement of the original source. These permissions are granted for free by Elsevier for as long as the COVID-19 resource centre remains active.

References

- [1] Bril F, Al Difalha S, Dean M, Fettig DM. Autoimmune hepatitis developing after coronavirus disease 2019 (COVID-19) vaccine: causality or casualty? *J Hepatol* 2021;75:222–224. <https://doi.org/10.1016/j.jhep.2021.04.003>.
- [2] Sasaki T, Suzuki Y, Ishida K, Kakisaka K, Abe H, Sugai T, et al. Autoimmune hepatitis following influenza virus vaccination: two case reports. *Med (United States)* 2018;97:e11621. <https://doi.org/10.1097/MD.00000000000011621>.
- [3] Berry PA, Smith-Laing G. Hepatitis A vaccine associated with autoimmune hepatitis. *World J Gastroenterol* 2007;13:2238–2239. <https://doi.org/10.3748/wjg.v13.i15.2238>.
- [4] Segal Y, Shoenfeld Y. Vaccine-induced autoimmunity: the role of molecular mimicry and immune crossreaction. *Cell Mol Immunol* 2018;15:586–594. <https://doi.org/10.1038/cmi.2017.151>.
- [5] Sinigaglia F, Hammer J. Defining rules for the peptide-MHC class II interaction. *Curr Opin Immunol* 1994;6:52–56. [https://doi.org/10.1016/0952-7915\(94\)90033-7](https://doi.org/10.1016/0952-7915(94)90033-7).
- [6] Rojas M, Restrepo-Jiménez P, Monsalve DM, Pacheco Y, Acosta-Ampudia Y, Ramírez-Santana C, et al. Molecular mimicry and autoimmunity. *J Autoimmun* 2018;95:100–123. <https://doi.org/10.1016/j.jaut.2018.10.012>.
- [7] Kanduc D, Shoenfeld Y. Molecular mimicry between SARS-CoV-2 spike glycoprotein and mammalian proteomes: implications for the vaccine. *Immunol Res* 2020;68:310–313. <https://doi.org/10.1007/s12026-020-09152-6>.
- [8] Talotta R. Do COVID-19 RNA-based vaccines put at risk of immune-mediated diseases? In reply to “potential antigenic cross-reactivity between SARS-CoV-2 and human tissue with a possible link to an increase in autoimmune diseases. *Clin Immunol* 2021;224:108665. <https://doi.org/10.1016/j.clim.2021.108665>.

Maria-Carlota Londoño<sup>1,\*</sup>

Jordi Gratacós-Ginès<sup>1</sup>

Joaquín Sáez-Peñarato<sup>2</sup>

<sup>1</sup>Liver Unit, Hospital Clínic Barcelona, IDIBAPS, CIBERehd, Barcelona, Spain

<sup>2</sup>Clinical Pharmacology Department, Medicines Area. Technical Committee for pharmacovigilance. Hospital Clínic Barcelona, Universitat de Barcelona, Barcelona, Spain

\*Corresponding author. Address: Liver Unit, Hospital Clínic Barcelona, IDIBAPS, CIBERehd, Barcelona, Spain; Tel.: 0034932275753. E-mail address: [mlondono@clinic.cat](mailto:mlondono@clinic.cat) (M.-C. Londoño)



## Autoimmune hepatitis developing after the ChAdOx1 nCoV-19 (Oxford-AstraZeneca) vaccine

To the Editor:

We read with interest the recent letter published by Bril *et al.* recently published in *Journal of Hepatology*.<sup>1</sup> The authors describe a possible case of COVID-19 vaccine-associated autoimmune hepatitis (AIH) in a 35-year-old woman 3 months post-partum. The patient presented with pruritis and jaundice 13 days after receiving a BNT162b2 mRNA (Pfizer-BioNTech) COVID-19 vaccine, which may be the first report of COVID-19 vaccine-associated liver injury. As vaccination programs are being rolled out globally,<sup>2</sup> many clinically significant side effects are starting to be identified, such as vaccine-induced immune thrombotic thrombocytopenia.<sup>3</sup>

Herein, we report the case of a 36-year-old Iraqi-born male physician who developed likely vaccine-induced AIH following COVID-19 vaccination. He has a past medical history of hypertension treated with olmesartan and laser eye surgery 2 weeks prior that required topical fluoroquinolone eye drops, 1 g of acetaminophen TDS, and 400 mg of ibuprofen TDS for 1 week total. He had no previous history of liver disease. Of note, he had his first dose of ChAdOx1 nCoV-19 vaccine (Oxford-AstraZeneca) 26 days prior to presentation with a subsequent mild febrile reaction requiring 1 g of acetaminophen TDS, and 400 mg of ibuprofen TDS for 3 days. He was referred to our emergency department after a finding of markedly abnormal liver function tests on routine blood tests and was asymptomatic at the time.

His physical examination was unremarkable. Blood tests were significant for the following: bilirubin 17  $\mu\text{mol/L}$ , alanine aminotransferase (ALT) 1,774 U/L, aspartate aminotransferase

(AST) 633 U/L, gamma glutamyltransferase 136 U/L, alkaline phosphatase 118 U/L, albumin 45 g/L, and international normalized ratio 1.1. Serology was negative for hepatitis A, B, C and E, Epstein-Barr virus, cytomegalovirus, herpes simplex virus, and HIV. Antinuclear antibody was positive at a titre of 1:160 in a speckled pattern. Immunoglobulins were normal with an IgG of 12.8 g/L (ref 7.0–16.5 g/L). Anti-liver-kidney microsomal, anti-smooth muscle, anti-mitochondrial antibodies, and anti-soluble liver antigen were normal. His caeruloplasmin, transferrin saturation, alpha-1-antitrypsin level and creatine kinase levels were also normal. Abdominal ultrasound revealed a normal-sized

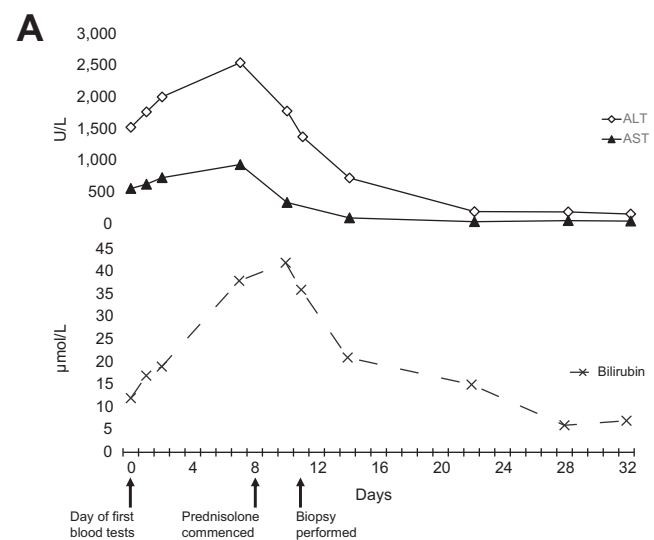


Fig. 1. Trends of plasma biochemistry over time.

Keywords: COVID-19 vaccine; autoimmune hepatitis; immune mediated.

Received 3 June 2021; received in revised form 9 June 2021; accepted 10 June 2021; available online 22 June 2021

<https://doi.org/10.1016/j.jhep.2021.06.014>

liver. No thrombus was identified in the portal, splenic, hepatic, or superior mesenteric veins. An MRI cholangiogram revealed mild peri-portal oedema, no biliary dilatation, and smooth bile duct contour with no evidence of stricturing.

During ongoing close follow-up, he developed pruritus and had a corresponding worsening of his liver function tests (with a bilirubin of 38  $\mu\text{mol/L}$ , ALT of 2550 U/L, and AST of 943 U/L). He was commenced on 60 mg of prednisolone daily, admitted to hospital, and had a liver biopsy 3 days after commencing the corticosteroids. His biopsy was significant for interface hepatitis with a mixed, predominantly lymphocytic, inflammatory cell infiltrate without significant fibrosis. Copper and iron stains were negative. These findings are consistent with an acute hepatitis of autoimmune aetiology. The post-biopsy pre-treatment Revised Original Score for Autoimmune Hepatitis<sup>4</sup> is 15 (supporting a *probable* diagnosis of AIH). His prednisolone has been weaned over the following month and is now down to 20 mg/day, with an ALT of 163 U/L and bilirubin of 7  $\mu\text{mol/L}$  (Fig. 1) after 24 days of corticosteroid therapy.

In contrast to the communicate published by Brill *et al.*,<sup>1</sup> our patient received the Oxford-AstraZeneca vaccine and did not have any apparent confounding factors such as pregnancy. This case supports the notion of COVID-19 vaccine-triggered autoimmune phenomena irrespective of the vaccine's mechanism of action, though this is the first report of an adenovirus-based vaccine precipitating AIH. Similar to the previously described case by Brill *et al.*,<sup>1</sup> causation cannot be definitively proven and it is possible that other factors, including drugs or toxins, may have contributed to the presentation. In this case, however, the patient is a practicing physician with excellent health literacy and we feel it is unlikely that other potential aetiologies were missed on history.

The case of this 36-year-old previously well man developing apparent AIH precipitated by a COVID 19-vaccine is another salient reminder to be vigilant of the rapidly changing landscape of potentially rare complications associated with novel vaccine agents and mass immunisation programs worldwide.

### Financial support

The authors received no financial support to produce this manuscript.

### Conflict of interest

The authors declare no conflict of interest.

Please refer to the accompanying ICMJE disclosure forms for further details.

### Authors' contributions

DCC provided patient care as well as co-wrote the original manuscript and edited the final submission; DS co-wrote the original manuscript and edited the final submission; EF provided patient care, assisted with conceptualisation, and edited the final submission; WK provided patient care, assisted with conceptualisation, and edited the final submission; SKR provided patient care, assisted with conceptualisation, and edited the final submission.

### Supplementary data

Supplementary data to this article can be found online at <https://doi.org/10.1016/j.jhep.2021.06.014>.

### References

- [1] Brill F, Al Diffalha S, Dean M, Fettig DM. Autoimmune hepatitis developing after coronavirus disease 2019 (COVID-19) vaccine: causality or casualty? *J Hepatol* 2021;75:222–224. <https://doi.org/10.1016/j.jhep.2021.04.003>.
- [2] Dagan N, Barda N, Kepten E, Miron O, Perchik S, Katz MA, et al. BNT162b2 mRNA covid-19 vaccine in a nationwide mass vaccination setting. *N Engl J Med* April 15 2021;384:1412–1423. <https://doi.org/10.1056/NEJMoa2101765>.
- [3] Schultz NH, Sørvoll IH, Michelsen AE, Munthe LA, Lund-Johansen F, Ahlen MT, et al. Thrombosis and thrombocytopenia after ChAdOx1 nCoV-19 vaccination. *N Engl J Med* April 9 2021. <https://doi.org/10.1056/NEJMoa2104882>.
- [4] Alvarez F, Berg PA, Bianchi FB, Bianchi L, Burroughs AK, Cancado EL, et al. International Autoimmune Hepatitis Group Report: review of criteria for diagnosis of autoimmune hepatitis. *J Hepatol* 1999;31(5):929–938. [https://doi.org/10.1016/s0168-8278\(99\)80297-9](https://doi.org/10.1016/s0168-8278(99)80297-9).

Daniel Clayton-Chubb<sup>1,\*</sup>

Daniel Schneider<sup>1</sup>

Elliot Freeman<sup>1</sup>

William Kemp<sup>1,2</sup>

Stuart K. Roberts<sup>1,2</sup>

<sup>1</sup>Department of Gastroenterology, Alfred Health, Melbourne, Victoria, Australia

<sup>2</sup>Central Clinical School, Department of Medicine, Monash University, Melbourne, Victoria, Australia

\*Corresponding author. Address: Daniel Clayton-Chubb, Alfred Health, 55 Commercial Rd, Melbourne, Victoria, Australia, 3004; Tel: +613 9076 7000.

E-mail address: [d.clayton-chubb@alfred.org.au](mailto:d.clayton-chubb@alfred.org.au) (D. Clayton-Chubb)



## Autoimmune hepatitis following COVID-19 vaccination: True causality or mere association?

To the Editor:

The COVID-19 pandemic is still raging across the world and vaccination is expected to lead us out of this pandemic. Although

the efficacy of the vaccines is beyond doubt, as many vaccines were granted expedited approval, safety still remains a concern.<sup>1</sup> In light of this, we read with great interest a recent article by Brill *et al.*<sup>2</sup> They described a case of autoimmune hepatitis (AIH) possibly triggered by COVID-19 vaccination. However, as the patient was 3-months post-partum a true causal relationship is difficult to determine.<sup>3</sup> We hereby describe a case of severe AIH

Keywords: COVID-19; mRNA Vaccine; Autoimmune Hepatitis.

Received 7 June 2021; accepted 9 June 2021; available online 18 June 2021

<https://doi.org/10.1016/j.jhep.2021.06.009>