



Since January 2020 Elsevier has created a COVID-19 resource centre with free information in English and Mandarin on the novel coronavirus COVID-19. The COVID-19 resource centre is hosted on Elsevier Connect, the company's public news and information website.

Elsevier hereby grants permission to make all its COVID-19-related research that is available on the COVID-19 resource centre - including this research content - immediately available in PubMed Central and other publicly funded repositories, such as the WHO COVID database with rights for unrestricted research re-use and analyses in any form or by any means with acknowledgement of the original source. These permissions are granted for free by Elsevier for as long as the COVID-19 resource centre remains active.



## A Series of Patients With Myocarditis Following SARS-CoV-2 Vaccination With mRNA-1279 and BNT162b2



Wide availability of the 3 vaccines approved by the U.S. Food and Drug Administration for emergency use against SARS-CoV-2 has led to reports of adverse reactions not seen during clinical trials: We now report a series of patients who developed CMR-proven myocarditis shortly after vaccination.

Six previously healthy men (17-37 years of age) with no infectious prodrome developed severe chest pain and elevated troponin I within 2 days-4 days of their second vaccination (**Figure 1**). Five patients had ST-segment elevation on presentation, with 4 demonstrating no coronary artery obstruction. All patients had negative nasopharyngeal SARS-CoV-2 PCR testing. CMR revealed patchy midmyocardial increased T<sub>2</sub> signal with corresponding late gadolinium enhancement consistent with the acute inflammation of myocarditis (**Figure 1**). Five patients had abnormal left ventricular systolic function. None of the patients developed any other complications, and all were discharged home.

Large clinical trials of both BNT162b2 and mRNA-1273 in more than 70,000 individuals in the United States showed good safety profiles for both of the mRNA-based vaccines and no reports of myocarditis (1,2). However, myocarditis has been described after other vaccinations, such as seasonal influenza (3) and smallpox (4) and regulatory agencies are evaluating the risk of COVID-19 vaccine-associated myocarditis based on post-Emergency Use Authorization reports. CMR findings in patients with suspected COVID-19 vaccine-associated myocarditis have not been well described in published reports, and our report tries to document some of these

changes. Although the clinical presentation, CMR findings, and temporal association strongly suggest the possibility of vaccine-associated myocarditis in our 6 patients, we cannot conclude definitively that COVID-19 vaccine was causative or that other etiologies for myocarditis can be definitively excluded in our patients. Nevertheless, clinicians should be suspicious of myocarditis in recently vaccinated patients with symptoms consistent with this diagnosis.

John B. Dickey, MD\*  
Elisabeth Albert, MD  
Mai Badr, MD  
Kristin M. Laraja, MD  
Laureen M. Sena, MD  
David S. Gerson, MD  
Jason E. Saucedo, MD  
Waqas Qureshi, MD, MS  
Gerard P. Aurigemma, MD

\*Department of Medicine  
Division of Cardiovascular Medicine  
University of Massachusetts Medical School  
55 Lake Avenue North  
Worcester, Massachusetts 01655, USA  
E-mail: [John.Dickey@umassmemorial.org](mailto:John.Dickey@umassmemorial.org)  
<https://doi.org/10.1016/j.jcmg.2021.06.003>

© 2021 by the American College of Cardiology Foundation. Published by Elsevier.

The authors have reported that they have no relationships relevant to the contents of this paper to disclose.

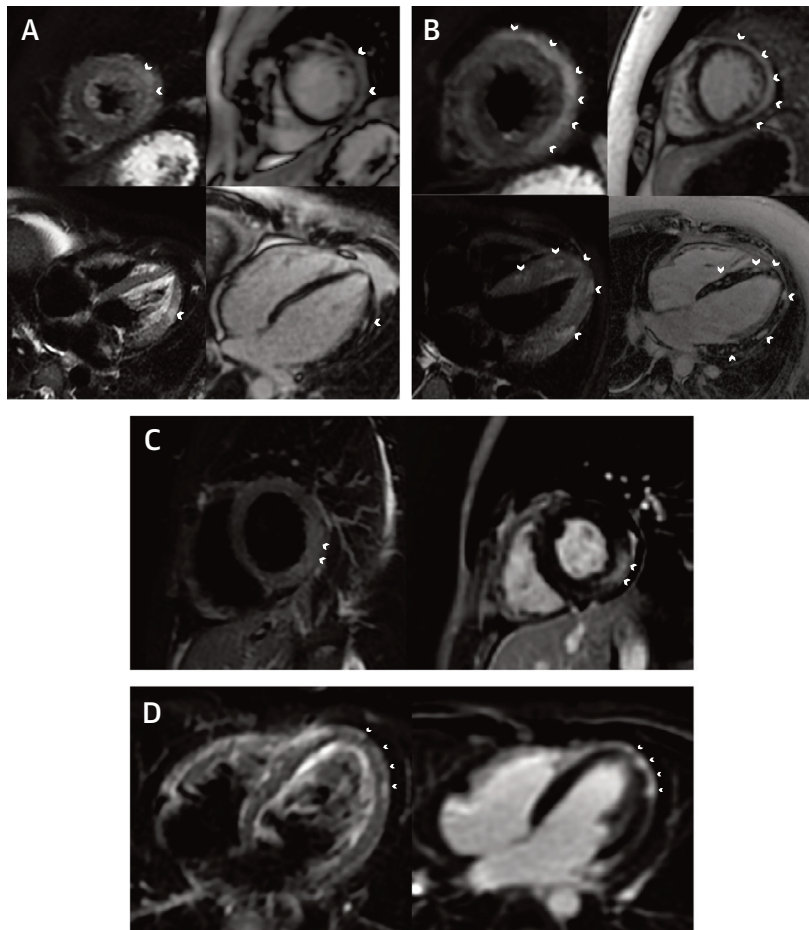
The authors attest they are in compliance with human studies committees and animal welfare regulations of the authors' institutions and Food and Drug Administration guidelines, including patient consent where appropriate. For more information, visit the [Author Center](#).

## REFERENCES

1. Polack FP, Thomas SJ, Kitchin N, et al. Safety and efficacy of the BNT162b2 mRNA Covid-19 vaccine. *N Engl J Med*. 2020;383(27):2603-2615.
2. Baden LR, El Sahly HM, Essink B, et al. Efficacy and safety of the mRNA-1273 SARS-CoV-2 vaccine. *N Engl J Med*. 2021;384(5):403-416.
3. Cheng MP, Kozoriz MG, Ahmadi AA, Kelsall J, Paquette K, Onrot JM. Post-vaccination myositis and myocarditis in a previously healthy male. *Allergy Asthma Clin Immunol*. 2016;12:6.
4. Keinath K, Church T, Kurth B, Hulten E. Myocarditis secondary to smallpox vaccination. *BMJ Case Rep*. 2018;2018:bcr2017223523.

**FIGURE 1 Clinical Characteristics and Cardiac Magnetic Resonance Imaging of Patients Following SARS-CoV-2 Vaccination**

	Patient 1	Patient 2	Patient 3	Patient 5	Patient 6	Patient 7
Age range (years)	35-40	16-20	20-25	20-25	16-20	16-20
COVID vaccine received	BNT162b2	BNT162b2	mRNA-1273	BNT162b2	BNT162b2	BNT162b2
Lag between vaccination and presentation	4 days	3 days	4 days	2 days	4 days	3 days
Fever	No	Yes, 3 days into hospitalization	No	Yes, on presentation	No	No
Symptoms at presentation	Positional and pleuritic chest and neck pain; chills; and myalgias	Pleuritic and positional chest pain; rhinorrhea; headache	Pleuritic and positional chest pain; chills; myalgias; and subjective fever	Non-positional chest pain radiating to back; myalgia; malaise	Pleuritic and positional chest pain; headache	Non-positional chest pressure; myalgias
Electrocardiogram	Sinus rhythm with inferolateral ST elevation	Sinus rhythm with diffuse ST elevation	Sinus rhythm with diffuse ST elevation	Sinus rhythm with diffuse ST elevation and PR depression; non-sustained ventricular tachycardia	Sinus rhythm with non-specific T wave abnormalities	Ectopic atrial rhythm with diffuse ST elevation and PR depression
Peak cardiac troponin I (ng/mL)	5.41	38.3	18.94	13.4	5.21	19.7
Ejection fraction (normal > 55%)	45%	53%	58%	48%	46%	50%



**(Top)** Clinical characteristics of patients with myocarditis following SARS-CoV-2 vaccination. **(Bottom)** Cardiac magnetic resonance of myocarditis following vaccination. In each panel, T<sub>2</sub>-weighted sequences are on the left and late gadolinium (LGE) sequences are on the right. **(A)** Patient 1: short-axis and 4-chamber views demonstrating areas of increased T<sub>2</sub> signal and LGE in the midwall of the lateral segments (**arrowheads**) in a patient who received their second SARS-CoV-2 vaccination 5 days earlier. **(B)** Patient 2: short-axis and 4-chamber views demonstrating increased T<sub>2</sub> signal and LGE in the midwall and subepicardial layer throughout the left ventricle (**arrowheads**) in a patient who received their second SARS-CoV-2 vaccination 7 days earlier. **(C)** Patient 3: short-axis views demonstrating increased T<sub>2</sub> signal and LGE in the mid wall and subepicardial layer of the mid-posterolateral segment (**arrowheads**) in a patient who received their second SARS-CoV-2 vaccination 6 days earlier. **(D)** Patient 6: 4-chamber view demonstrating areas of increased T<sub>2</sub> signal and LGE in the subepicardial apical and apical lateral segments (**arrowheads**).