


CASE REPORT

A characteristic rash caused by Shiitake mushrooms – An emerging concern?

Thiviyani Maruthappu^{1,2}  | Zahra Hader³¹Department of Dermatology, Royal London Hospital, Barts Health NHS Trust London, London, UK²Queen Mary, University of London, London, UK³Department of Dermatology, Queen Elizabeth Hospital, Birmingham, UK**Correspondence**

Thiviyani Maruthappu, Department of Dermatology, Royal London Hospital, Barts Health NHS Trust London, UK.
Email: thiviyani.maruthappu@nhs.net

Abstract

Shiitake mushroom dermatitis is a striking rash that can present as an emergency. Despite the dramatic appearance, the rash is an idiosyncratic reaction which resolves spontaneously and does not progress to anaphylaxis.

1 | INTRODUCTION

The consumption of raw or undercooked Shiitake mushrooms can lead to a dramatic rash known as “Shiitake mushroom dermatitis” or “Flagellate dermatitis.” Although striking, the rash resolves spontaneously. This presentation is likely to become more common widespread consumption of Shiitake mushrooms as medicinal compounds and nutritional supplements.

Lentinus edodes, known as Shiitake, is one of the most consumed species of mushroom worldwide; in addition, it has been extensively studied for the potential therapeutic actions of its bioactive compounds.¹ More broadly, mushrooms have been used for their medicinal properties for over 5000 years, particularly in Traditional Chinese Medicine.² Shiitake contains tocopherols and phenolic compounds such as *p*-hydroxybenzoic, *p*-coumaric, and vanillic acid, which contributes to its antioxidant effects.³ Furthermore, several studies have demonstrated extracts of *Lentinus edodes* have antitumor and antimicrobial properties.¹ Their increasing popularity has led to inclusion in supplements and beverages where they are consumed either in their dried form or as an infusion of fresh mushrooms. However, the consumption of raw or undercooked shiitake can be associated with the development of a characteristic, but self-limiting rash in susceptible individuals.⁴ We report a case of “Shiitake mushroom dermatitis” which developed after the consumption of mushroom tea.

2 | CLINICAL OBSERVATIONS

A 32-year-old male patient with no prior health concerns presented to the emergency dermatology clinic with a widespread rash. The rash had developed spontaneously and had spread rapidly over a 24-hour period. Despite the dramatic appearances, it was only mildly itchy. On examination, he had multiple erythematous curvilinear streaks with a cross-hatched pattern distributed over the trunk and limbs (Figure 1). There was no facial involvement and no angioedema of the oral mucosa or urticaria to suggest progressing anaphylaxis. He had no gastrointestinal symptoms or other systemic signs. His blood pressure, pulse, and oxygen saturations were all within normal parameters. Investigations including full blood count, urea and electrolytes and liver function and inflammatory markers (C-reactive protein and erythrocyte sedimentation rate) were all normal.

On further questioning, the patient had consumed Mushroom tea at a health food café approximately 24 hours previously. The listed ingredients included Shiitake mushroom. The classical appearances of the rash led to a diagnosis of “Shiitake mushroom dermatitis.” The rash is also described as “Flagellate dermatitis” because of the resemblance to “whipped” skin.⁴ The patient was treated with moderate potency topical steroids applied to the affected sites and the rash resolved fully over 2 weeks. He was advised that further consumption of raw or undercooked Shiitake mushrooms could lead to a similar eruption in the future.

This is an open access article under the terms of the Creative Commons Attribution-NonCommercial-NoDerivs License, which permits use and distribution in any medium, provided the original work is properly cited, the use is non-commercial and no modifications or adaptations are made.

© 2021 The Authors. *Clinical Case Reports* published by John Wiley & Sons Ltd.

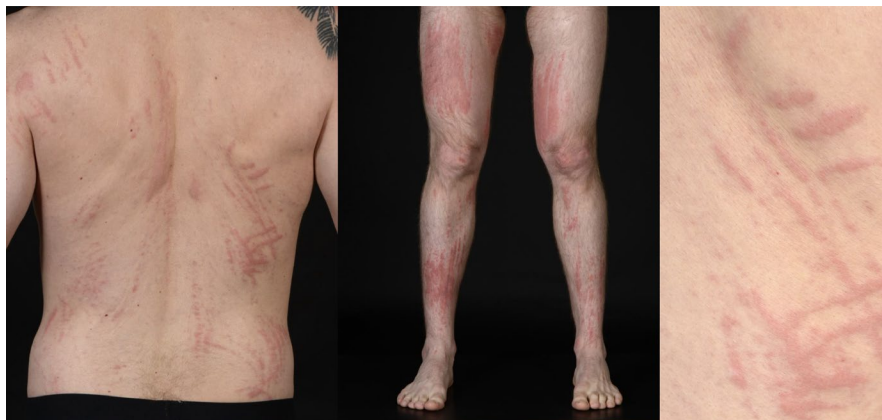

FIGURE 1 Widespread curvilinear and cross-hatched erythematous streaks present over the trunk A, and lower limbs B, without urticaria. C, The characteristic “flagellate” pattern of dermatitis on the back

3 | DISCUSSION AND CONCLUSION

Shiitake mushroom dermatitis is a rare idiosyncratic skin rash caused by a toxic or hypersensitive reaction to Lentinan, a bioactive component of shiitake mushrooms found in the cell wall.⁵ Lentinan is a thermolabile polysaccharide which decomposes upon heating; therefore, well-cooked shiitake mushrooms can usually be safely eaten. Studies have shown that a skin rash develops when shiitake mushrooms are cooked at 100°C but not when cooked at 150°C, explaining why our patient developed this rash after consuming mushroom tea made with boiling water.⁶

Lentinan has been used intravenously to study its antitumor properties; however, only 9 out of 519 patients developed flagellate dermatitis.⁷ The exact mechanism by which Lentinan causes this eruption remains to be elucidated, however it has been postulated that Lentinan-induced secretion of Interleukin-1, TNF α , nitric oxide, and other inflammatory cytokines leads to vasodilatation and hemorrhage in the epidermis, which presents as this characteristic rash.^{6,8}

Affected individuals should avoid consuming undercooked shiitake mushrooms in the future. The rash typically occurs 2-5 days after consuming shiitake mushrooms and spontaneously resolves after 10-14 days with conservative management; however, antihistamines and topical or oral corticosteroids are often also used. A skin biopsy if performed can show epidermal spongiosis and a perivascular lymphocytic infiltrate.⁴ Other causes of a flagellate dermatosis include docetaxel, dermatomyositis, and adult-onset Still's disease and bleomycin, the latter may also exhibit mucosal involvement. Although the majority of cases are confined to the skin, some individuals may have systemic effects such as vomiting and tachycardia.⁶

Clinicians should be aware of this dramatic rash, particularly with the increasing popularity of Shiitake mushrooms, and distinguish that this is a self-limiting idiosyncratic

toxin-mediated reaction rather than an anaphylactic or urticarial eruption. The patient was advised to avoid future intake of raw or undercooked Shiitake mushrooms.

CONSENT STATEMENT

Published with written consent of the patient.

ORCID

Thiviyani Maruthappu  <https://orcid.org/0000-0002-3528-8222>

REFERENCES

1. Bisen PS, Baghel RK, Sanodiya BS, Thakur GS, Prasad GBKS. *Lentinus edodes*: a macrofungus with pharmacological activities. *Curr Med Chem*. 2010;17:2419-2430.
2. Halpern GM. Medicinal mushrooms. *Prog Nutr*. 2010;12:29-36.
3. Carneiro AAJ, Ferreira ICFR, Dueñas M, et al. Chemical composition and antioxidant activity of dried powder formulations of *agaricus blazei* and *Lentinus edodes*. *Food Chem*. 2013;138:2168-2173.
4. Stephany MP, Chung S, Handler MZ, et al. Shiitake mushroom dermatitis: a review. *Am J Clin Dermatol*. 2016;17:485-489.
5. Wang X, Xu X, Zhang L. Thermally induced conformation transition of triple-helical lentinan in NaCl aqueous solution. *J Phys Chem B*. 2008;112:10343-10351.
6. Nguyen A, Gonzaga M, Lim V, Adler M, Mitkov M, Cappel M. Clinical features of shiitake dermatitis: a systematic review. *Int J Dermatol*. 2017;56(6):610-616.
7. Hanada K, Hashimoto I. Flagellate mushroom (shiitake) dermatitis and photosensitivity. *Dermatology*. 1998;197:255-257.
8. Chu EY, Anand D, Dawn A, Elenitsas R, Adler DJ. Shiitake dermatitis: a report of 3 cases and review of the literature. *Cutis*. 2013;91:287-290.

How to cite this article: Maruthappu T, Hader Z. A characteristic rash caused by Shiitake mushrooms – An emerging concern?. *Clin Case Rep*. 2021;9:e04181. <https://doi.org/10.1002/ccr3.4181>